Republic of Iraq

Ministry of higher education and scientific research

Hila university

Medical laboratory techniques

Histomorphological study of the kidneys on the mice

By

Malak Kadem Abdullah

Zahraa Hussam Ali

zainab dhahir mohsin

Baneen Salm AbdZied

Nahla Qasim Al-Moussawi

Retag Abbas Nazol

Buraq eyad noor

supervised by :

Asst.Lectn .Aqeel muslim al.shammary

1445

2024

Abstract

The kidneys of the mice were bean – shaped, smooth, reddish-brown color were covered by a thin connective tissue capsule that was adherent to sub capsular connective tissue occasional fibroblast. The mice kidneys lay alongside the vertebral column in the abdominal cavity the right kidney was situated more cranially than the left kidney. The mean weight of the right kidney was 1.1gm while, the left was 0.96gm. The mean length, width and thickness right kidney were 1.28cm, 0.88 and 0.81cm respectively while those of the left one were mean length, width and thickness were 1.23cm, 0.85 and 0.79cm.The kidney consists of two regions the cortex outer and medulla inner, the basic unit of the mice kidney is the nephron, each of nephron can be sub divided into number of distinct parts in the cortex and medulla. The nephron forming(renal corpuscle the first part of nephron is consists from glumerulus and Bowman's capsule, the proximal convoluted tubules, loop of Henle thus consists of ascending and descending limb of loop of Henle and distal convoluted tubules). The collecting tubules are not part of the nephron.

Introduction

The mice is one of the most widely used research animals in urinary physiology. The mice also is useful in assessment of toxicologic insult to the urinary system. Mice were initially used for experimental purposes since the half of the nineteenth century. Several strains have been developed for studying genetic diseases, neuroanatomy, nutritional disorders, diabetes, hypertension, and others. The mice is the most important animal used as a model for biological experiments in research laboratories worldwide. (Pannabecker et al., 2004)

The urinary system of mammals is consists of the paired kidneys, renal pelvises ureters, urinary bladder, and urethra. The kidneys are highly vascularized, compound tubular glands that function to maintain the composition of body fluids at a constant level and to remove excretory wastes. (William J and Linda M. 2000). Urine produced in the kidneys. The kidneys also regulate the fluid and electrolyte balance of the body and are the site of production of the hormones rennin and erythropoietin. Renin participates in the regulation of blood pressure and erythropoietin is a growth factor glycoprotein that stimulates the production of erythrocytes. (Mohamed, B.M. 2010)

According to.El-Salkh et al., (2008), the kidney of the mammalian species has typical bean-shaped appearance characteristic of the unipolar mammalian kidneys. The kidney consists of superficial capsule, outer cortex and inner medulla. The

outer cortex is highly vascular; the inner medulla is slightly thick and less vascular. Both cortex and medulla are built up of different tubule structures. The nephron is the functional unit of the kidney; each nephron consists of corpuscle, proximal convoluted tubules, loop of Henle, distal convoluted tubules and collecting tubules. Bowman's capsule is formed of two thin cellular layers, an inner visceral layer and an outer parietal one, which is a simple squamous epithelium resting on basal lamina. The visceral layer is formed of flattened epithelium.

Literature review

the kidneys are two reddish-brown bean-shaped blood-filtering organs They are located on the left and right in the retroperitoneal space, and in adult humans are about 12 centimetres (4+1⁄2 inches) in length They receive blood from the paired renal arteries; blood exits into the paired renal veins. Each kidney is attached to a ureter, a tube that carries excreted urine to the bladder.

The kidney participates in the control of the volume of various body fluids, fluid osmolality, acid-base balance, various electrolyte concentrations, and removal of toxins. Filtration occurs in the glomerulus: one-fifth of the blood volume that enters the kidneys is filtered. Examples of substances reabsorbed are solute-free water, sodium, bicarbonate, glucose, and amino acids. Examples of substances secreted are hydrogen, ammonium, potassium and uric acid. The nephron is the structural and functional unit of the kidney. Each adult human kidney contains around 1 million nephrons, while a mouse kidney contains only about 12,500 nephrons. The kidneys also carry out functions independent of the nephrons. For example, they convert a precursor of vitamin D to its active form, calcitriol; and synthesize the hormones erythropoietin and renin.

Material and method

Five male mice , weighing 150 to 200gm were obtained from animal house the Department of physiology, Veterinary College, Baghdad University. The animals were sacrificed under anesthesia. Its extremities were fixed to the dissection board with drawing pins. A vertical midline incision was done from the xiphoid process down to the pubic symphysis under the skin, abdominal muscles to the abdominal cavity, the viscera were retracted and the kidneys were exposed. Kidneys were released from their fatty connective tissue covering and gently removed, weighed by balance*and measured (length, width and thickness) by vernier caliper**.

The kidneys were cut along the mid dorsal plane and immediately fixed in 10% neutral formalin. The tissue was washed in tap water. And dehydrated in ascending grades of ethyl alcohols, cleaned in xylene and finally embedded in paraffin wax at 60 C° using (Hestion -ATP7000 tissue processor-Germany) (Akhundov and Federove, 1995). The paraffin sections at 5-6μm in thickness using (digital microtom(Hestion ERM 4000 Germany) were prepared and stained with Haematoxylin and Eosin according to (Charmi, A.*et al*., 2009) and PAS (Mochiduk and Harada, 2007) stain.

Results and Discussions

Morphometric observation:

The kidney of the mice were bean – shaped, smooth and possess convex and concave borders, each of the kidney had dorsal and ventral surface, medial and lateral borders the lateral border were convex while, the medial border was concave and indented of the hilus, an upper and lower pole. This is in agreement with onyeanus et al., (2009) the kidneys of african gaint rat and wistar rat were bean shape and smooth. The hilus and sides were surrounded by adipose tissue, the mice kidneys lay alongside the vertebral column in the abdominal cavity and suprarenal glands situated above their poles. The right kidney was situated more cranially than the left; this result is similar to the David M. M. (2000) the right kidney is located more cranial than the left kidney. Was related to the liver while, the left was related to the stomach, pancreas, descending colon, spleen and small intestine. This result is similar to the result of Young, (1975) the paired kidneys of the two investigated rodents were bean shape and dark red bodies located in dorsal wall of abdominal cavity.

The mean weight of the right kidney was 1.1gm while, the left was 0.96gm. The mean length, width and thickness right kidney were 1.28cm, 0.88 and 0.81cm respectively while those of the left one were mean length, width and thickness were 1.23cm, 0.85 and 0.79cm. This study different to the Gulnaz. H. et al., (2010)

the mean weight of kidneys 0.95g and the length of kidney rat the right 1.35cm and the left 1.49cm

Histological observations:

The mice kidneys were reddish-brown color were covered by a thin connective tissue capsule (fig.1 & 2) that was adherent to sub capsular connective tissue (fig.2) occasional fibroblast (fig.1) that venous sinuses containing red blood corpuscles. This is in agreement with El-Beltagy, A. (2002) each kidney is surrounded by a capsule of connective tissue which may contain a distinct layer of smooth muscle in its deepest portion. And with the El-Salkh et al., (2008), each kidney is enclosed by a fibroconnective tissue capsule.

The histological section on the each kidneys show. The kidney consists of two regions the cortex outer and medulla inner, the cortex and medulla are arranged into more pyramidal shape called renal pyramids, the apex of the each pyramid is called renal papilla the basic unit of the rat kidney is the nephron, each of nephron can be sub divided into number of distinct parts in the cortex and medulla. The nephron forming(renal corpuscle the first part of nephron is consists from glumerulus and Bowman's capsule, the proximal convoluted tubules, loop of Henle thus consists of ascending and descending limb of loop of Henle and distal convoluted tubules)

The cortex were consists from renal corpuscles, proximal convoluted tubules and distal convoluted tubules. The renal corpuscle is a round or irregular structure shape formed of glomerula which is enveloped by Bowman's capsule. The bowman capsule is formed of two thin cellular layer, the outer parietal layer and inner visceral layer. The parietal layer consist of a flat single layer squamous epithelium thus layer enclosing a narrow space,(fig 4) the urinary space which is continuous with the lumen of proximal convoluted tubule. The visceral layer is surrounded the glomerula capillaries the visceral space of renal corpuscle attached with arteries of glomerula (fig 4). This research coincided with El-salkh B. A. et al., (2008) the renal corpascule is a spherical structure formed of glomerulus which is enclosed by Bowman's capsule. The proximal convoluted tubule and distal convoluted the convoluted tubules are the initial and terminal parts of the nephron. The proximal convoluted tubule arises from the arterial epithelium of Bowman's capsule of the urinary space of the renal corpuscle, the proximal tubule exibit a small, uneven lumen and a single layer of cuboidal cells with eosinophilic, granular cytoplasm. A brush border lines the cells (fig. 1, 2, 3). This research not similar to Junqueira L. C. (1998) the proximal convoluted tubules are lined withcuboidal or columnar epithelial but agreement with the tubule is more than the distal convoluted tubule. The distal convoluted tubule were the second tubules of the cortex, the distal tubule is characterizes different from proximal tubules in that

the cells of lining was of cuboidal type epithelia with round and large nuclei possess neither brush border. The distal convoluted tubules tend to be rather shorter than the proximal convoluted tubules and are fewer in number in the cortex (fig 1, 4). Part of the distal convoluted tubule in contact with glomerular root has rather modified appearance than the rest of these tubules; this region is identified as the macula densa. This research similar with Basuony M. I. (1997) the distal convoluted tubule is fewer in number and may be recognized by the pale cuboidal epithelial cells. And with William J and Linda M. (2000) the distal convoluted tubules have a smooth internal surface, and their lack a brush brder.

The medulla of each kidney is formed from collecting tubules, thick and thin parts of the loops of Henle, the thin limb had a distinct rounded lumen (fig 3). It could be clearly distinguished from the other parts of the nephron on the bases of its low lining epithelia squmouse cells the ground cytoplasm was homogenous eosiophilic in this cells. This limb thinner wall resembles the capillaries or small venues in their lumina.

The thick descending portion in medulla similar to the proximal convoluted tubules in cortex togather the thick ascending portion of medulla similar distal convoluted tubules in cortex. The ascending limb of loop of Henle appears large in size than that of the descending limb and is enclosing a wider lumen (fig 3). This is agreement with Junqueira L. C. (1998) the henles loop consisting of thick

descending limb, which is very similar in structure to the proximal convoluted tubule, a thin descending limb, a thin ascending limb, and a thick ascending limb which is very similar in structure to the distal convoluted tubules. The collecting tubules are not part of the nephron. These tubules are lined by cuboidal epithelium with round nuclei and basophilic cytoplasm (fig 3). The research coincided with William J and Linda M. (2000) the epithelial cells of the collecting tubules are pale and very form cubiodal near the distal convoluted tubules. The epithelial cells of the collecting tubules are pale and very from cuboidal near the distal tubule to columnar close to the papilla, cell boundaries are normally clearly defined compare with the cells of the proximal and distal convoluted tubules as progress towered the renal papilla, the collecting tubule become the terminal portion of these tubules are lined by columnar or psedostritifed epithelium and is called papilla duct. The renal pelvis appeared as adilated cavity of the proximal end of ureter logded in the sinus and facing the renal papilla.

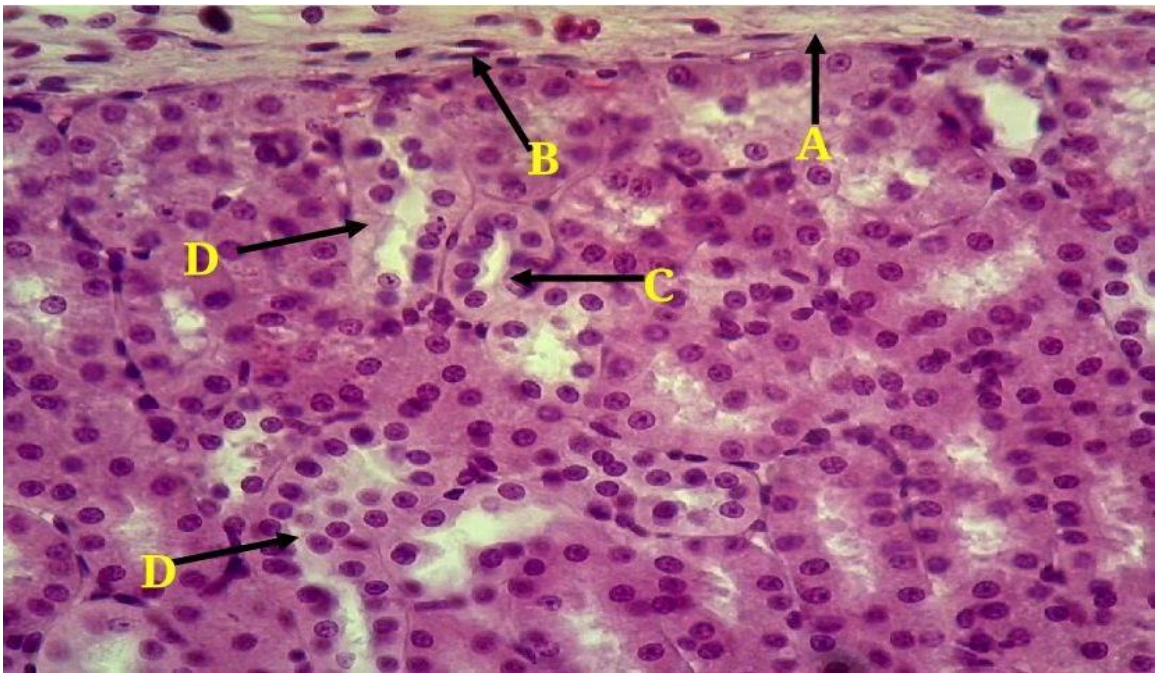

Figure (1): A- Capsule … B- Fibroblast cell … C- Proximal tubule … D- Distal tubule … (400 X H&E)

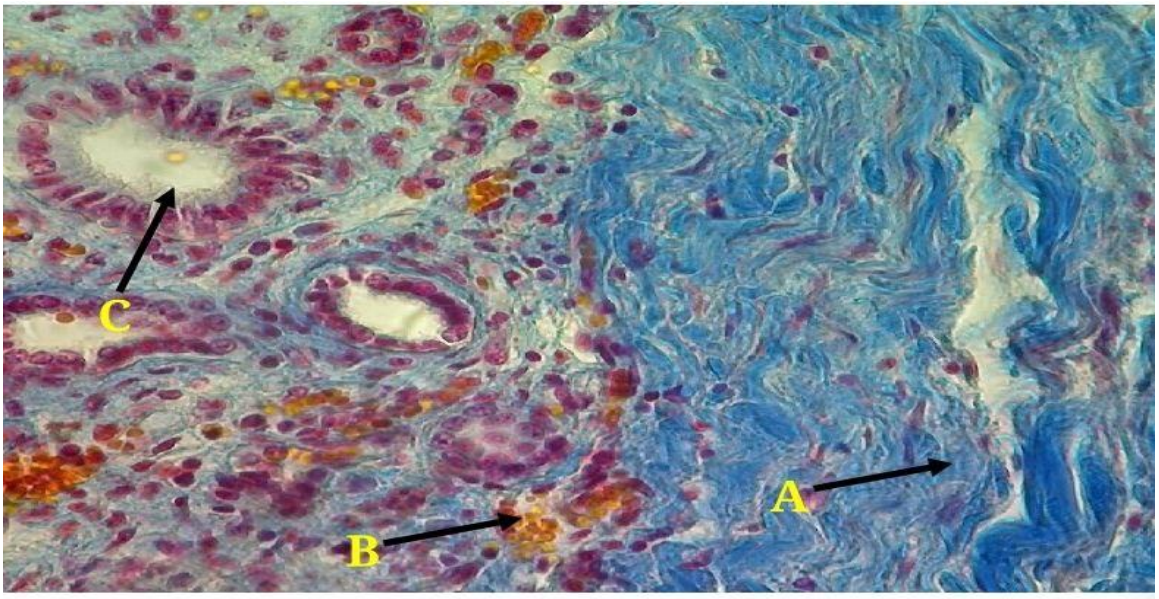

Figure (2) A- Capsule … B- Sub capsular region … C- Proximal tubule. (400 X PAS)

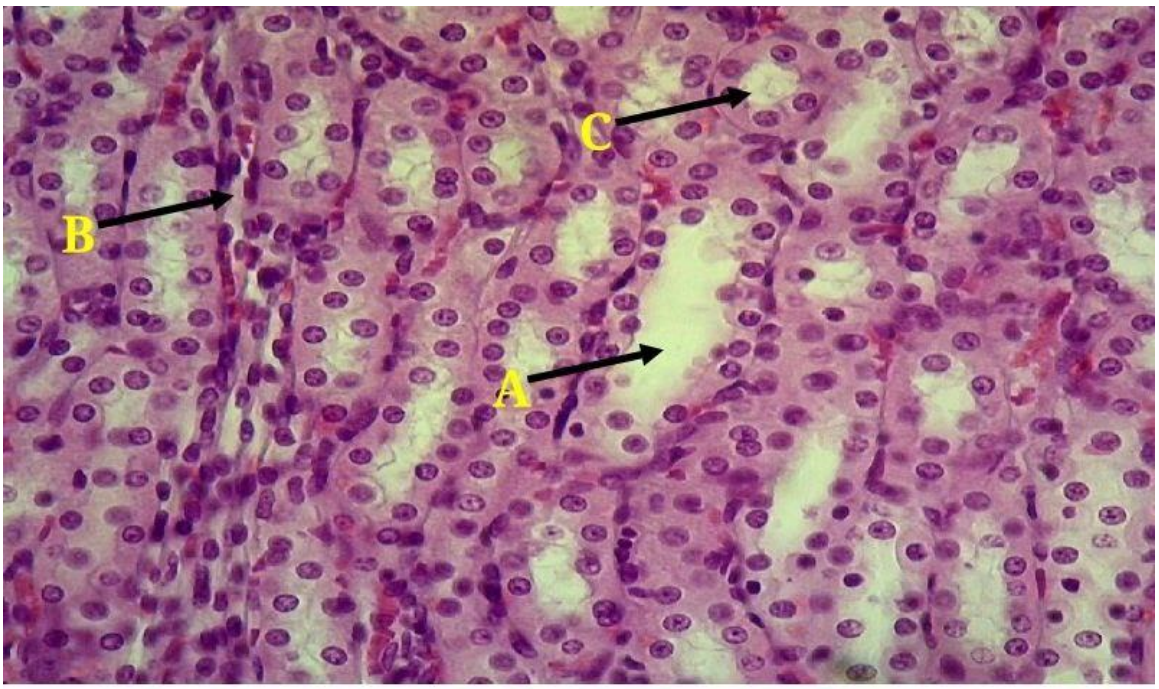

Figure (3) A-Collecting tubule … B-Thin limb … C- thick descending limb.

(400 X H&E)

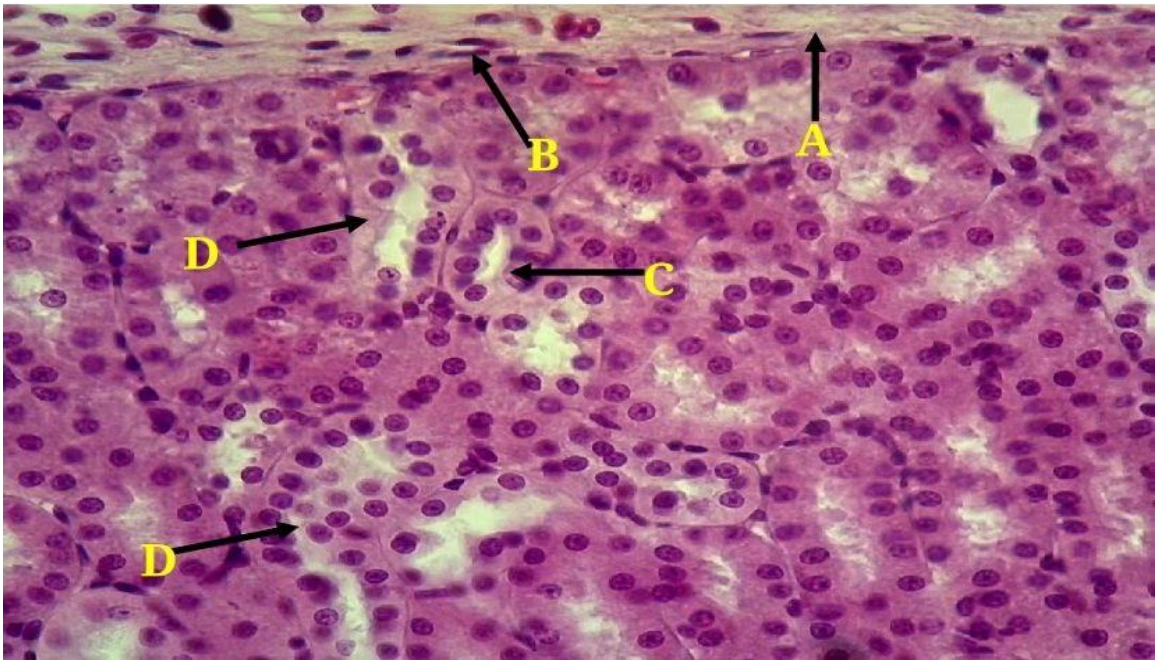

Figure (4): A- glomerula … B-Visceral layer … C-Parietal layer.

D-Distal tubule … E-Proximal tubule. (400 X H&E)

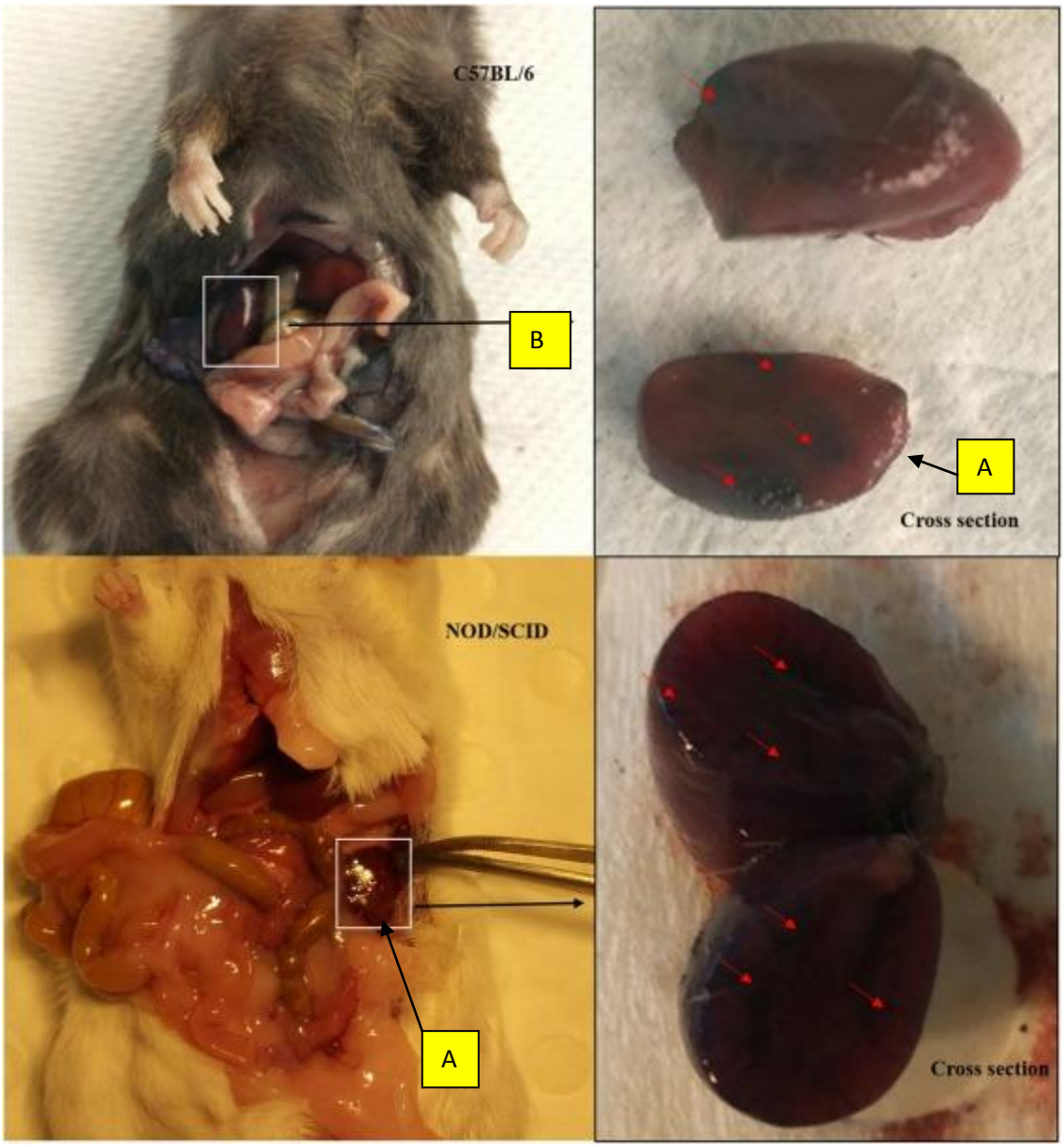

Figure (5):(A) show the left kidney , (B) show the right kidney .

Conclusion

1- The mice kidneys lay alongside the vertebral column in the abdominal cavity the right kidney was situated more cranially than the left kidney

2- The mean weight of the right kidney was 1.1gm while, the left was 0.96gm. The mean length, width and thickness right kidney were 1.28cm, 0.88 and 0.81cm respectively while those of the left one were mean length, width and thickness were 1.23cm, 0.85 and 0.79cm

3- The nephron forming(renal corpuscle the first part of nephron is consists from glumerulus and Bowman's capsule, the proximal convoluted tubules, loop of Henle thus consists of ascending and descending limb of loop of Henle and distal convoluted tubules). The collecting tubules are not part of the nephron**.**

recommendation

1-comparative study of kidney with another animals.

2- pre and postnatal developmental study of kidney and used electron microscope

References

-Akhundov, MM. and K.E. Fedorov, 1995. Effects of exogenous estradiol on the formation of ovaries in juvenile sterlet Acipenser ruthenus. J. Ichthyol., 35: 109-120 (in Russian, English).

-Besuony M I (1997). Ecological variability and kidney structure of eight rodents.Egypt. J. Histol, 20(2):417-434

-Boshra A. El- Salkh, Zaki T. Zaki, Mohammad I. Basuony and Hanaa A. Khidr (2008). Anatomical, Histological And Histochemical Studies On Some Organs Of True Desert Rodents In The Egyptian Habitats. The Egyptian Journal of Hospital Medicine (2008) Vol., 33: 578– 306.

-Charmi, A., M. Bahmani, M.M. Sajjadi and R. Kazemi, (2009). Morpho-histological study of kidney in farmed juvenile beluga, Huso huso (Linnaeus, 1758). Pak. J. Biol. Sci., 12: 11-18.

-David M. M. (2000): Laboratory animal medicine and science series II.Health Sci. Coni.Edu. Resources. Washington Uni.

-El-Beltagy, A. (2002): studies on functional comparative anatomy of the kidney in some small mammals. M.Sc.Thesis, Mansora Fac .of Sci.,Mansora Uni.

-Gulnaz, M. Tahir, B. Munir and Sami, M. (2010): Protective effects of garlic oil on acetaminophen induced nephrotoxicity in male albino rats. Department of Anatomy, University of Health Sciences, Lahore

-Junqueria L. C. (1998): Basic histology. Ninth edition. Rio de Janeiro.

-Mochiduk, E. and T. Harada, 2007. Periodic acid-schiff. Staining of the Kidney.

Mohamed, B. M. (2010). The protective role of ellagic acid extracted from pomegranate pulp (Punica granatum L.) on liver and kidney functions in rats

treated with lead acetate. Msc. a thesis submitted to the college of veterinary medicine university of Baghdad, Baghdad –Iraq.

-Onyeanusi B.I, Adeniy A. A, Ayo J. O, Ibe G. S and Onyeanusi C. G. (2009): A comparative study on the urinary system of the African Giant rat and the wistar rat. Pakistan journey Nutrition (817) 1043-2047.

-Pannabecker, T.L., Abbott, D.E., and Dantzler, W.H. (2004). Three dimensional Functional reconstruction of inner medullar thin limbs of Henle's loop. Am. J. Physiol. Renal Physiol. 286, F38–F45.

-William J. Bacha, Jr and Linda M. Bacha. (2000): Color atlas of veterinary histology. 2nd Edi. Lippincott Williams & Wilkins.

-Young Z J (1975): The Life of Mammals; Their anatomy and Physiology, second edition, claredom press Oxford.