Anatomy and physiology as related to dental prosthesis

In order to construct a prosthesis a dentist require an understanding and a thorough knowledge of the anatomy and physiology of the supporting structures to assure successful results.

Osteology

The osseous structures not only support the denture but have a direct relation on the impression making procedure, position of teeth and the contours of the finished denture.

It is quite essential to have knowledge of the tissues that support the maxillary and the mandibular dentures. These tissues also help the dentures in obtaining their retention and stability. There are certain tissue areas or regions in the maxillary and mandibular edentulous foundations, which are better suited to bear the stresses due to mastication, and are called as *stress bearing areas*. While there are other tissue areas which are not quite suited to take up these stresses, either due to their anatomy or due to the structures that lie beneath them and are called *stress relief areas*. The structures which limit the extension of the maxillary and mandibular complete dentures are called *border-limiting areas*.

The mucous membrane that lines the oral cavity varies in character in different zones and denture border depends on the function of the different zones. The sub-mucosa, which is a connective tissue, attaches the mucosa to the underlying structures. The submucosa varies in composition depending on whether the mucosa is firmly or loosely attached to the bony structure and whether there is muscle tissue between itself and the underlying bone. The blood vessels present in the submucosa supply blood to the edentulous foundation and the nerves innervate it.

Factors that influence the form and size of the supporting bone include the following:

1. The original size and arch form before extractions.
2. The severity of periodontal disease.
3. Amount of alveoloplasty at the time of tooth extraction.
4. Forces developed by the surrounding musculature.
5. Forces accruing from the wearing of dental prostheses.
6. The relative length of time different parts of the jaws have been edentulous.
7. Unknown genetic predisposition to bone resorption.

STRUCTURES RELATED TO THE MAXILLARY AND MANDIBULAR DENTURE EDENTULOUS FOUNDATION

These structures can be divided into two categories:
1. Supporting structures: These are the structures that support the denture
2. Border limiting structures: These are the structures that limit the border extent of the denture (maxillary and mandibular denture).

Osteology of the oral cavity: the maxilla:

The maxillary denture is supported by two pairs of bone the maxillae and the palatine bones whereas the mandibular denture is supported by one bone the mandible. There are two maxillae each consisting of a central body and four processes: alveolar, frontal, zygomatic and palatine. Some area of the body and two of the processes are involved in the support of the maxillary denture.

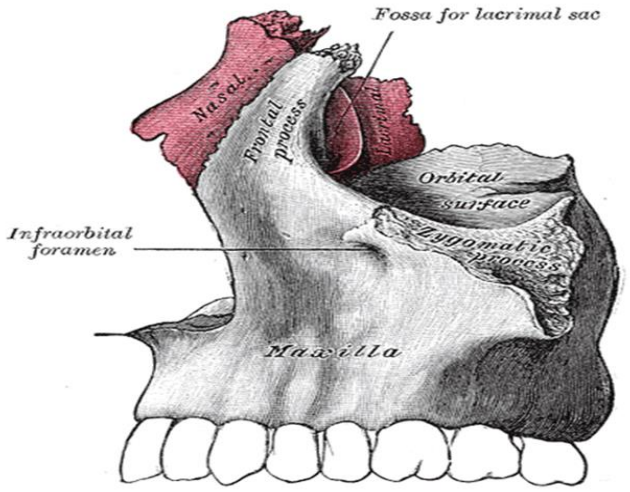

Supporting Structures in the Maxillary Edentulous Foundation

1. Zygomatico-alveolar crest (malar process).
2. Alveolar process
3. The palatine bone
4. Palatine process of the maxilla
5. The incisive fossa
6. The pterygoid hamulus
7. Maxillary tuberosity
8. The greater palatine foramen
9. Cuspid eminence.

Zygomatico-alveolar crest (malar process):

This is located opposite the 1st molar region some denture require relief over this area to prevent soreness and aid in retention especially in sever resorbed ridge.

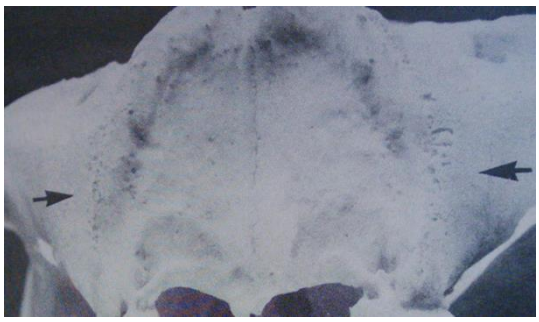

Alveolar process:

It arises from the lower surface of the maxilla. It consists of two parallel plates of cortical bone which unite behind the last molar to form the tuberosity. The part of the alveolar process that remain after loss of teeth is called the residual alveolar ridge. The maxillary ridge act as a secondary stress bearing area. The slopes of the ridges do help in the stability of the denture during function. Hence, some of the stress does get transmitted through the slopes.

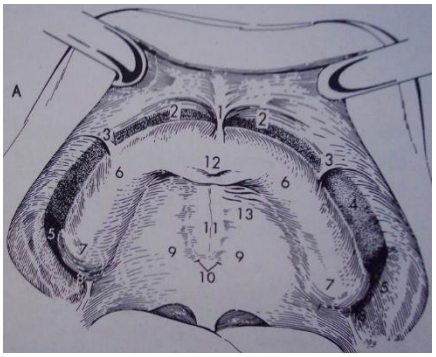

The palatine processes of maxillary bone:

They arises as horizontal plates from the body of the maxilla. The two plates unite in the mid line forming the mid palatine suture. Sometime overgrowth of bone seen in this area called torus palatinus. The hard palate resist resorption (primary stress bearing area**).**

The area of sutural joint (mid palatal raphe) is covered by firmly adherent mucous membrane to the underlying bone with little submucosal tissue. There is, therefore, no resiliency in this region and stress cannot be applied

in this region. This is a stress relief area in the maxillary edentulous foundation.

Clinical consideration:

During final impression procedure the mid palatal raphae is relieved in order to create equilibrium between the resilient and non-resilient tissue supports.

The palatine bone:

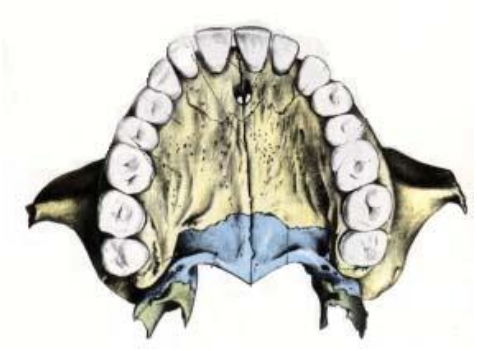

The horizontal plate of palatine bone unite with the posterior rough border of the horizontal palatal process of maxillae. The posterior border of palatine bone unite at midline forming the posterior nasal spine. The soft palate is attached to this posterior border. The posterior palatal seal (PPS) is placed at the junction between immovable and movable parts of the soft palate.

Posterior palatal seal area: The soft tissue area limited posteriorly by the distal demarcation of the movable and non-movable tissues of the soft palate and anteriorly by the junction of the hard and soft palates on which pressure, within physiologic limits, can be placed; this seal can be applied by a removable complete denture to aid in its retention.

Vibrating line:

An imaginary line across the posterior part of the soft palate marking the division between the movable and immovable tissues; this line can be identified when the movable tissues are functioning.

Incisive foramen:

The incisive foramen is located in the palate on the median line posterior to the maxillary central incisor. In edentulous mouth it comes nearer to the crest of the ridge as resorption progress. Failure to relieve this area may result in irritation and burning sensation at the anterior part of the palate.

Incisive Papilla

It is a pad of fibrous connective tissue anteriorly overlying the incisive foramen. The submucosa in this region contains the nasopalatine nerves and vessels.

Significance

• A stable landmark is related to the incisive foramen through which the neurovascular bundle emerge and lies on the surface of the bone.

• It is a biometric guide giving information about location of maxillary canines (a perpendicular line drawn posterior to the center of the incisive papilla to sagittal plane passes through the canines).

• It is a biometric guide giving information on positional relation of central incisors, which are about 8-10 mm anterior to the incisive papilla.

Clinical consideration:

During the impression procedure, care should be taken not to compress the papilla. This is one of the *relief areas* of the maxillary edentulous foundation. Hence the incisive papilla should be relieved.

Anterior (greater) palatine foramen:

This is located medial to the third molar at the junction of the ridge and horizontal plates of palatine bone .Rarely would a relief be required in the denture base over this area since the nerve and blood vessels are retained in a groove and covered by thick soft tissue.

Maxillary tuberosity:

It is that part of the residual ridge that extend distally from the area of the 2nd molar to the hamular notch. The *tuberosities* often are covered with dense fibrous connective tissues with minimal compressibility. In this situation, considerable support is offered to the denture. Sometimes cause problem in maxillary denture construction such as:

1. Enlargement of the tuberosity with the presence of bilateral undercuts negatively affect the insertion and removal of denture.
2. The presence of pendulous tuberosities cause a reduction in the interarch distance in the posterior region against the retro molar pad.
3. To prevent oro-antral fistula, it is important to have an occlusal radiograph before surgical resection of the tuberosity.
4. In case of severe undercuts at the tuberosity region, the undercut on the preferential chewing side should be reduced.
5. The last posterior tooth should not be placed on the tuberosity.

Hamular notch:

It is a narrow cleft of loose connective tissue, which is approximately 2 mm in extent antero-posteriorly. This structure is bounded by the maxillary tuberosity anteriorly and the pterygoid hamulus posteriorly and marks the postero-lateral limit of the upper denture. The submucosa in this region is thick and made up of loose areolar tissue. A seal can be obtained by utilizing this area as it can be displaced to a certain extent without trauma.

Significance

1. Constitutes the lateral boundary of the posterior palatal seal area in the maxillary foundation.

2. The pterygomandibular raphe attaches to the hamulus.

Clinical considerations*:* The denture should not extend beyond the hamular notch, failure of which will result in:

1. Restricted pterygomandibular raphe movement.
2. When mouth is wide open, the denture dislodges.
3. Pterygomandibular raphe may be sandwiched below the denture.



Cuspid eminence:

It is a bony elevation on the residual ridge formed after extraction of the canine located over the canine root and serve as a guide for positioning of artificial canine.

The limiting structures of the upper denture can be divided into three areas: (1) the labial vestibule, which runs from one buccal frenum to the other on the labial side of the ridge; (2) the right and left buccal vestibules, which extend from the buccal frenum to the hamular

notch; and (3) the vibrating line, which extends from one hamular notch to the other across the palate.

Osseous structures associated with the mandibular denture:

1. Coronoid process.
2. Residual alveolar ridge.
3. Buccal shelf area.
4. Mental foramen.
5. Mylohyoid ridge.
6. Genial tubercles.
7. Torus mandibularis.
8. External oblique ridge.

The mandible is the movable member of the stomatognathic system. It consist of:

A. The body of the mandible.

B. The rami: Each ramus terminate at its upper extremity into two processes, posteriorly the condyloid and anteriorly the coronoid process.

Coronoid process: It is the anterior process and continuous with the anterior border of the ramus. If the distobuccal flange of maxillary denture is too thick it will cause discomfort and dislodgment of upper denture when the mandible is protruded and move from side to side. Trimming of the flange will solve the problem.

Residual alveolar ridge:

It is that part which remain after loss of teeth. The bone underlying the crest of RR is cancellous which makes it unfavorable for resisting applied forces from a denture.

Buccal shelf area: The *buccal shelf* is the area between the mandibular buccal frenum and the anterior edge of the masseter muscle. Medially it is bound by the crest of the ridge and laterally by the boney external oblique ridge and distally by the retromolar pad. The buccinators muscle fibers attach horizontally along the boney oblique ridge. As resorption of the ridge occurs, the buccal shelf does not resorb because of its muscle attachments on the posterior and lateral borders. The alveolar ridge of the

mandible is significantly medial to the inferior border of the mandible; therefore, as the ridge resorbs, the denture-bearing surface becomes flatter and widens towards the buccal shelf. The shelf is dense cortical bone and lies at right angles to vertical occlusal forces, and is therefore a primary stress-bearing area for the denture.

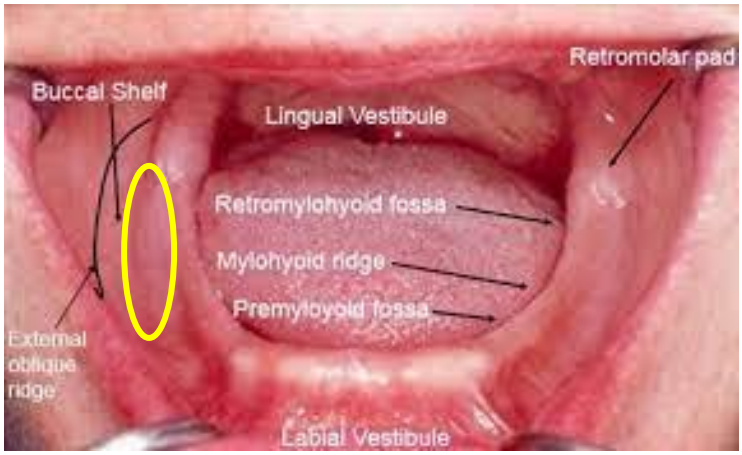

Mental foramen:

It is located on the lateral surface of the mandible between 1st and 2nd premolar half way between the lower border and alveolar crest. The *mental nerve* exits the *mental foramen* below the alveolar ridge, but with continued resorption of the ridge, the mental foramen can become positioned at the crest of the ridge and be compressed by the denture. This causes pain or even altered sensation in the lip (numbness in the lower lip).

Mylohyoid ridge:

It runs along the lingual surface of the mandible. Anteriorly the ridge lies close to the inferior border of mandible while posteriorly, it lies flush with the residual ridge. The thin mucosa over the mylohyoid ridge may get traumatized and should be relieved. The area under this ridge is an undercut.

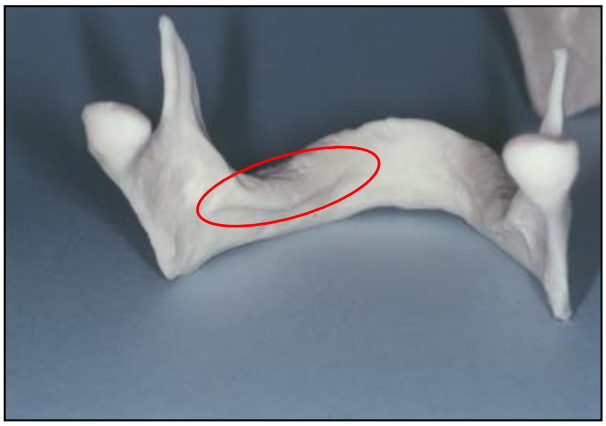

Genial tubercles:

Also called mental spines, 2- 4 in number situated on the lingual surface of the body of mandible in the mid line. They represents the muscle attachment of the genioglossus and geniohyoid muscle .it is usually seen below the crest of the ridge.

Significance

• In a severely resorbed ridge, it is seen above the residual alveolar ridge and hence, it should be relieved.

• The mucosa covering the genial tubercle is thin and tightly adherent to the underlying bone.

Clinical consideration:

It should be relieved with a spacer, failure of which leads to ulceration.

Mandibular tori

Mandibular tori are lingual bilateral or unilateral prominences of cortical bone in the premolar area. But they may extend posteriorly to the molar area. Small tori may only require relief in the denture. Large tori require removal before a denture can be fabricated.

External oblique ridge:

It is a ridge of dense bone extended from just above the mental foramen superiorly and distally to be continuous with the anterior border of the ramus. In most individuals it is the anatomic guide for lateral end of the buccal flange of lower denture.

Retromolar pad:

The retromolar pad is a triangular pad of tissue at the distal end of the residual ridge. The anterior portion of the triangle is keratinized tissue of the remnant gingiva of the third molar called the pear-shaped pad. The posterior aspect of the triangle is composed of thin, non-keratinized epithelium; loose connective tissue; glandular tissue; fibers of the temporalis tendon and of the buccinators and superior constrictor muscles; and the pterygomandibular raphe. The underlying bone is dense cortical bone because of the muscle attachments and is resistant to resorption. The denture should cover the retromolar pad because of the support and absence of long-term cortical bone resorption.

Maxillary and Mandibular Stress-Bearing Areas

Maxillary

1° firm tuberosities
1° hard palate on either side of palatal raphe
2° alveolar ridge
2° rugae

Mandibular

1° buccal shelves
1° retromolar pads
2° alveolar ridge

Areas Requiring Relief in Final Impression

2° stress-bearing areas
Palatal torus
Median palatal raphe
Mandibular tori
Retromylohyoid ridge
Undercuts or sharp boney prominence on ridges.

The pattern of bone resorption:

The maxilla resorb upward and inward to become progressively smaller (centripetal). While the mandible resorb downward and outward to become gradually wider (centrifugal). This progressive change of the mandible and maxillae makes many edentulous patients appear to be prognathic.

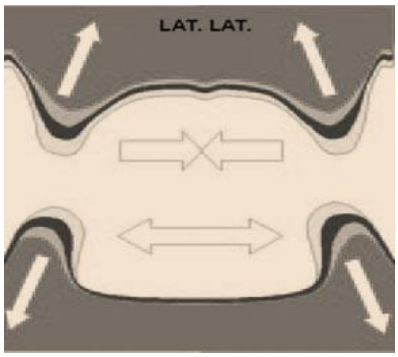

Thinking Notes/ The mean denture bearing area for edentulous maxillae are 23cm^2 while for mandible 12cm^2 in contrast with 45cm^2 area of PDL in each dental arch.

The masticatory loads recorded for the natural teeth are about 20 Kg while maximum forces of 6 Kg during chewing have been recorded with complete denture. In fact, maximal bite forces appear to be five to six times less for complete denture wearer than person with natural teeth.

Anatomy and physiology related to prosthodontics

Myology

Muscles of facial expression

The zygomaticus major, zygomaticus minor, levator labii superioris, levator labii superioris alaeque nasi, levator anguli oris, depressor anguli oris, risorius, platysma, incisivus superioris, incisivus inferioris, orbicularis oris, mentalis and buccinator muscles are responsible for the expression seen in the lower half of the face.

Functions of muscles of facial expression

1. Laughing
2. Smiling
3. Frowning
4. Their actions reflect the mood and emotional status of an individual.
5. When these muscles are relaxed, the face lacks expression.

The perioral muscles of facial expression

Why we study these muscles?

1. *The perioral muscles do not insert into bone so they need support from teeth for proper function.*
2. *Incorrect positioning of the teeth or incorrect contour of denture base can affect the normal tonicity of theses muscle and can affect adversely the facial expression.*
3. *Lack of support allows sagging of the soft tissues of the face, while stretching inhibits the normal contraction of the facial muscles and results in changes in muscle tone.*

The insertion of these various muscles around the oral cavity opening is very important, where they partly insert into the connective tissue of the skin and partly into the mucous membrane of the lips.

The area which is situated laterally and slightly above the corner of the mouth known as the **muscular node or the (modiolus)**, which is a concentration of many fibers of this group of muscles. Here the labial flange of the maxillary denture should be reduced in thickness, so as not to effect the stability of the upper denture. Sometimes, the mandibular first premolar should be arranged properly on the crest of residual ridge to avoid any interference with this modiolus.

Mentalis muscle

Functions related to prosthodontics

1. Contraction of this muscle is capable of dislodging mandibular denture.
2. It can dictate the level of extension of the labial flange of mandibular denture below the crest of the ridge.
3. Render the lower vestibule shallower when it contract.
4. Surgical repositioning of the mentalis muscle is sometimes advisable.

The incisivus labii superioris and inferioris muscles

Their actions on the vestibular fornix (fold) are similar to that of the mentalis muscles. They are small muscles, and their action alone would rarely dislodge a denture. However, their presence beneath the mucous membrane might present problems associated with flange extension and denture retention.

Buccinators muscle

It does not directly dislodge the denture because it contracts in a line parallel to the plane of occlusion.
Its fibers parallel to the plane of occlusion but run at right angle to the fiber of masseter, when masseter activated it push the buccinators muscle medially against denture border in the area of the retro molar pad, so the denture should be contoured to accommodate this interaction between these two muscles. This contour is known as ***masseter groove***.

Orbicularis oris muscle

- It is the sphincter muscle of the mouth. The upper lip is supported by the six anterior teeth and not the denture border.
- In normal occlusion the superior border of lower lip is supported by incisal third of the maxillary anterior teeth, if not so, the lower lip would be caught by the anterior teeth during occlusal contact.
- When the muscles of the lips are relaxed, the lips become flaccid. This can happen with jaw open therefore, it is important for dentist to make sure that the action of this muscle are recorded when making impression for dentures
- If this muscle is stretched, the angles of the mouth are easily irritated when an impression tray is inserted.

Suprahyoid muscles (*digastric, stylohyoid, geniohyoid, Mylohyoid*)

* Elevation of the hyoid bone and the larynx and depression of the mandible.
* Geniohyoid and Mylohyoid may influence the lingual border of the mandibular denture.
* Mylohyoid muscles constitute the muscular floor of the mouth. It elevate the hyoid bone, tongue and the membranous floor of the mouth during swallowing. If the denture extend below and under the mylohyoid line, it will impinge on mylohyoid muscle, and can affect it action.

  Mylohyoid muscle acts

  1. Elevate the floor of the mouth in the first stage of deglutition.
  2. Elevate the hyoid bone.
  3. Depress the mandible.

Infra hyoid muscle (*sternohyoid, omohyoid, Sternothyroid and thyrohyoid)*

- No particular significance in complete denture prosthodontics with respect to any influence on denture border.
- They are important for they are a part of the kinetic chain of mandibular movement. Their action is to fix the hyoid bone so that the suprahyoid muscles can act on the mandible.

Muscles of mastication

1. Masseter
2. Temporalis
3. Medial Pterygoid
4. Lateral Pterygoid

Functions of these muscles

- Masticatory and non-masticatory movement of the mandible.
- In complete denture, the non-masticatory movement and the contacting of the teeth during these movement are probably of more concern than the masticatory movements.
- In recording jaw relation, centric relation is obtained with aid of posterior fibers of temporalis muscles.

Pterygomandibular raphe

A tendinous band lies between the pterygoid hamulus superiorly and the mandible in the area of retromolar pad inferiorly. It is the point of attachment for the buccinators muscles laterally and superior pharyngeal constrictor muscles medially.

Muscles of the soft palate

The tensor veli palatini, levator veli palatini, muscular uvulae, and palatoglossus are the muscles of the soft palate.

Tensor veli palatini: This slender muscle when stretched can influence the denture contour in the hamular notch area.

Levator veli palatini: It elevates the soft tissues during swallowing as well as helps in determining the position of the vibrating line when developing a posterior palatal seal for a maxillary denture.

Palatoglossus: When the two palatoglossi contract, they draw the tongue and soft palate toward each other. This action also exerts lateral pressure on the lingual extension of a mandibular denture.

Why study muscle of soft palate?

Since there is a need to determine the vibrating line which is located on soft palate.
The patient says Ah when the patient closes both nostrils and blow gently. The air will force the soft palate to flux inferiorly at the junction of movable and non-movable parts of soft palate.

Soft palate can be classified into:

- Class I: horizontal with little muscular movement. In this case more tissue coverage is possible for posterior palatal seal.
- Class II: soft palate makes 45 degree angle to the hard palate. Tissue coverage for posterior palatal seal is less than that of class I condition.
- Class III: soft palate makes 70 degree angle to the hard palate. Tissue coverage for posterior palatal seal is minimum.

Tongue

The tongue is a muscular structure composed of intrinsic and extrinsic muscles fibers. The intrinsic muscles originate and insert within the tongue and responsible for change in shape. While the extrinsic muscles originate in structure outside the tongue and can move the tongue as well as alter its shape.

Function related to prosthetic dentistry

It is located in the floor of the mouth and is in intimate contact with the lingual flanges of mandibular denture. The denture flange must be contoured to allow the tongue to have its normal wide range of functional movement, that's why the patient should be asked to move his tongue to the left and right as well as protruding it anteriorly in muscle trimming procedure during lower impression making as well as asked to moisture his lips.

Muscle physiology

The human body is very adjustable, capable of adapting to changes in the environment. By means of Sensory nerve endings the body is notified of the changes and by the **effectors**, it adjust to these changes.

The effectors of the body are the muscle and glands.

The muscle involved in denture complete function are the skeletal muscle which are controlled by CNS that passes through a synapsis, then efferent nerve will be activated which lead to muscle contraction called reflex (voluntary action).

The oral cavity has many sensory nerve fiber receptors; many of these are associated with periodontium, when teeth lost these receptors are lost.

Muscle contraction is of two types

1. Isometric contraction occur when the muscle does not shorten during contraction
2. Isotonic contraction occur when the muscle shortens, but the tension remains the same.

In the mandible both isotonic and isometric contraction occurred. Isotonic to move the mandible and isometric to brace the mandible when teeth contact.

When load applied on muscle elongate with limit, the greater the load the greater the stretch, this is of importance during recording of jaw relation.

Oral mucous membrane

Much of mucous membrane either helps support a complete denture directly or comes in contact with it intermittently.
Oral mucosa could be classified into:
1. The masticatory mucosa.
2. The lining mucosa.
3. Specialized mucosa.

The masticatory mucosa is keratinized stratified Squamous epithelium. In edentulous patients covers the crest of residual ridge (here it is firmly attached to the underlying structure), and the hard palate.
The lining mucosa is non-keratinized Stratified Squamous epithelium. It is found in the lips, cheeks, vestibule spaces and ventral surface of the tongue. Usually the lining mucosa comes into contact with the denture borders. The submucosal structure may be either tightly or loosely attached to underlying structures.
The specialized mucosa covers the dorsum of the tongue; here the mucosa is keratinized including the papillae on the upper surface of the tongue.
Oral mucosa of soft palate is stratified squamous epithelium non-keratinized. The Sub mucosa here have numerous gland supporting membrane, it is a transition between loosely and fixed type of mucosa.

Salivary glands and saliva

Saliva is secreted by 3 different main exocrine glands:
1. A serous secretions by the parotid gland.
2. A mixed but mostly serous secretion by the submandibular glands.
3. A mixed but mostly mucous secretions by the sublingual glands.

Some other smaller glands are located in the mucosa of the tongue, lips and palate.
The viscosity of saliva is important. A thick ropy saliva can cause some problems:

1. Very thick saliva can force the dentures out of their correct position.
2. Complicates impression making by forming voids in the impression surface while the impression material sets.
3. Causing the patients to gag while impression are made and after the new denture are installed.

On the other hand, a lack of saliva (xerostomia) cause some problems:

1. Reduced retention of denture.
2. Sticking of cheeks and lips to the denture base in an uncomfortable manner.
3. Formation of sore spot under the denture, which is very annoying to the patient.
4. Lack of oral hygiene.

Physiologic factors affect salivation

1. Agreeable taste stimuli result in profuse salivation.
2. A smooth surface inserted into the mouth (Ex: polish surface of denture) will result in an increase in salivation.
3. When a patient is dehydrated salivation decreases.
4. Emotional and other psychological stimuli excite the autonomic nervous system, and in turn, the function of the body organs are altered.
5. As one ages, the saliva becomes more viscous in consistency (increase in mucin).

Functions of saliva

1. Contain ptyalin enzyme (type of amylase enzyme) that starts digestion process of starchy foods.
2. Lubricant for the mucosa and surface of the denture.
3. Protective agent (antifungal and antibiotics activities).
4. Aids in retention of removable prostheses.
5. Mechanical cleansing.

Diagnosis and treatment planning for Cr/Co RPD

Lec:-3 seineen salam

The dentist duty is to provide any dental treatment that patient needs, both the need perceived by the patient and those demonstrated through clinical examination and patient interview. Although similarity have been noted between partially edentulous patient a significance differences exist making each patient and the ultimate treatment plan unique.

description of each patient uniqueness occurs through patient interview and clinical examination. These include four distinct processes:-

1. Understanding the patient desire or chief concern complain
2. Ascertaining the patient dental need through a diagnostic clinical examination.
3. Developing treatment plane that reflects the best management of desire and need.
4. Executing appropriately sequenced treatment with planed follow up.

Patient interview

The interview, an opportunity to develop connection with the patient, involves listening to and understanding the patient's chief complaint or concern about his or her oral health.

The chief complaint is referred to the illness as described by the patient word. This can include clinical symptoms of pain, difficulty with function, concern about appearance, problems with an existing prosthesis, or any combination of symptoms related to the teeth, periodontium, jaws, or previous dental treatment. It is important to listen carefully to what the patient has stated is the reason for presenting for evaluation; this is because all subsequent information gathered will be used to discuss these concerns and to relate whether the proposed treatment will affect the patient in any way. Such a discussion at the outset of patient care helps to outline realistic expectations.

It is mandatory that the dentist clearly understand what brings the patient to the clinic.

Failure to do so leads to the chance that the patient will be unhappy with the treatment result, as it might not see the correction for its chief complain. With experience, this subtle point becomes a major component of a clinician's management focus.

The patient interview (and clinical examination) should follow a sequence that includes:

1. Chief complaint and its history
2. Medical history review
3. Dental history review, especially related to previous prosthetic experience(s)
4. Patient expectations

After the previous point being discussed, the time come to make a decision for the most appropriate type of prosthodontics treatment and this must be done in company with the patient by using a communication model termed (shared decision making)

The objectives of prosthodontic treatment

The objectives of prosthodontic treatment must be maintain which include -:

1. The best method of restoring the lost function within the limits of tissue tolerance of the patient .
2. Maintain or improve on the appearance of the mouth. As the first objective is satisfied, so the 2nd requirement is comfort in an esthetically pleasing manner. (esthetically pleasing restoration (
3. The preservation and maintenance of the health of the remaining teeth and oral tissues (which will enhance the removable partial denture design).

Oral examination

It should include visual and digital examinations of teeth and surrounding structure with mouth mirror, periodontal probe and tweezers.

Sequence of oral examination

1) Reliefs of pain discomfort and caries lesion by placements of temporary fillings, preliminary examination to determine the need for management of acute needs and whether prophylaxis is required to conduct a thorough oral examination.
2) A thorough and complete oral prophylaxis .best doing prophylaxis to obtain:-
    - Teeth free from accumulation of calculus and debris.
    - Accurate diagnostic cast of dental arch can be done
3) Complete intraoral radiograph

The objectives of a radiographic examination are:-

a. To locate areas of infection and other pathosis that may be present.

b. To reveal the presence of root fragments, foreign objects, bone spicules, and irregular ridge formations.

c.to reveal the presence and extent of caries and the relation of carious lesions to the pulp and periodontal attachment;

d.to permit evaluation of existing restorations as to evidence of recurrent caries, marginal leakage, and overhanging gingival margins;

e.to reveal the presence of root canal fillings and to permit their evaluation as to future prognosis (the design of the partial denture may hinge on the decision to retain or extract an endodontically treated tooth);

f. to permit an evaluation of periodontal conditions present and to establish the need and possibilities for treatment;

g. to evaluate the alveolar support of abutment teeth, their number, the supporting length and morphology of their roots, the relative amount of alveolar bone loss suffered through pathogenic processes, and the amount of alveolar support remaining

4) Impression for making accurate diagnostic cast to be mounted for occlusal examination, mounting preferably on semiadjastable articulator.
5) Examination of teeth and residual ridge by instrument and visual means *Visual examination will reveal many of the:-*

1. signs of dental disease consideration of caries susceptibility is of primary importance The number of restored teeth present signs of recurrent caries initial examination,

2. examination of periodontal disease, gingival inflammation, the degree of gingival recession, and mucogingival relationships should be observed

3. The number of teeth remaining, the location of the edentulous areas, and the quality of the residual ridge will have a definite bearing on the proportionate amount of support that the partial denture will receive from the teeth and the edentulous ridges.

4. Tissue contours may appear to present a well-formed edentulous residual ridge, however, palpation often indicates that supporting bone has been resorbed and has been replaced by displaceable, fibrous connective tissue. Such a situation is common in maxillary tuberosity regions. The removable partial denture cannot be supported adequately by tissues that are easily displaced. In preparing the mouth this tissue should be recontoured or removed surgically, unless otherwise contraindicated. A small but stable residual ridge is preferable to a larger unstable ridge for providing support for the denture.

5. The presence of tori or other bony exostoses must be detected and an evaluation of their presence in relation to framework design must be made. Failure to palpate the tissue over the median palatal raphe to ascertain the difference in its displaceability as compared with the displaceability of the soft tissues covering the residual ridges can lead to a rocking, unstable, uncomfortable denture and to a dissatisfied patient. Adequate relief of the palatal major connectors must be planned, and the amount of relief required is directly proportionate to the difference in displaceability of the tissues over the midline of the palate and the tissues covering the residual ridges. Or select major connector design not interferes with the presence of tori.
6. During the examination, not only each arch but also its occlusal relationship with the opposing arch must be considered separately.

A situation that looks simple when the teeth are apart may be complicated when the teeth are in occlusion. For example, an extreme vertical overlap may complicate the attachment of anterior teeth to a maxillary denture. Extrusion of a tooth or teeth into an opposing

edentulous area may complicate the replacement of teeth in the edentulous area or may create occlusal interference which will complicate the location and design of clasp retainers and occlusal rests.

Such findings subsequently will be evaluated further by careful analysis of mounted diagnostic casts.

Such an examination will not provide sufficient information to allow a definitive diagnosis and treatment plane. For this purpose, a complete charting (case sheet) that includes all previous information

7. Determination of height of the floor of the mouth to locate inferior borders of lingual mandibular major connectors. Two methods used in determining the of the floor of the mouth
   - ✓ Direct method
   - ✓ Indirect method

A diagnostic cast should be an accurate reproduction of the teeth and adjacent tissues. In a partially edentulous arch this must include the edentulous spaces because these also must be evaluated in determining the type of denture base to be used and the extent of available denture-supporting area.diagnostic cast made through an impression making with alginate and cast pour with dental plaster but some time with dental stone bitter than plaster because it's not easily abraded.

<u>Diagnostic casts serve several purposes as an aid to diagnosis and treatment planning. Some of these are as follows:</u>

a. Diagnostic casts are used to supplement the oral examination by permitting a view of the occlusion from the lingual, as well as from the buccal aspect.
b. Diagnostic casts are used to permit a topographic survey of the dental arch that is to be restored by means of a removable partial denture. The cast of the arch in question may be surveyed individually with a cast surveyor to determine the parallelism or lack of parallelism of tooth surfaces involved and to establish their influence on the design of the partial denture .

c. Diagnostic casts are used to permit a logical and comprehensive presentation to the patient of present and future restorative needs, as well as of the hazards of future neglect. Occluded and individual diagnostic casts can be used to point out to the patient (a) evidence of tooth migration and the existing results of such migration; (b) effects

of further tooth migration; (c) loss of occlusal support and its consequences; (d) hazards of traumatic occlusal contacts; and (e) cariogenic and periodontal implications of further neglect .

d. Can be used in the fabrication of individual trays .
e. Diagnostic casts may be used as a constant reference as the work progresses. Penciled marks indicating the type of restorations, the areas of tooth surfaces to be modified, the location of rests, and the design of the partial denture framework, as well as the path of placement and removal, all may be recorded on the diagnostic cast for future reference .
f. Unaltered diagnostic casts should become a permanent part of the patient's record because records of conditions existing before treatment are just as important as are preoperative roentgenograms. Therefore diagnostic casts can be used as permanent record.

Interpretation of Examination Data

As a result of the oral examination and diagnosis, certain data should be recorded, much of which are based on decisions that are the result of the diagnosis and reflect the patient's present and predictable health status. These are as follows:

1) Roentgenographic interpretation

Many of the reasons for roentgenographic interpretation during oral examination are outlined and are considered in greater detail in other texts. The aspects of such interpretation that are the most pertinent to partial denture construction are those relative to the prognosis of remaining teeth that may be used as abutments.

The quality of the alveolar support of an abutment tooth is of primary importance because the tooth will have to withstand greater stress loads when supporting a dental prosthesis. Abutment teeth providing total abutment support to the prosthesis, be it either fixed or removable, will have to withstand a greater load and especially greater horizontal forces. Abutment teeth adjacent to distal extension bases are subjected not only to vertical and horizontal forces but to torque as well because of the movement of the tissue supported base .

2) Value of interpreting bone density

Its importance to the dentist when evaluating the quality and quantity of the alveolar bone are the height and the quality of the remaining bone structure

Roentgenographic evaluation of bone quality is often necessary. Optimum bone qualities are ordinarily expressed by normal sized interdental trabecular spaces, The normal interproximal crest is ordinarily shown by a relatively thin white line crossing from the lamina dura of one tooth to the lamina dura of the adjacent tooth.

Roentgenographic findings should serve the dentist as an adjunct to clinical observations. Therefore roentgenographic findings should always be confirmed by clinical examination.

Root morphology

The morphologic characteristics of the roots determine to a great extent the ability of prospective abutment teeth to resist successfully additional rotational forces that may be placed on them. Teeth with multiple and divergent roots will resist stresses better than teeth with fused and conical roots, because the resultant forces are distributed through a greater number of periodontal fibers to a larger amount of supporting bone

Periodontal considerations

An assessment of the periodontium in general and abutment teeth in particular must be made before prosthetic restoration. One must evaluate the condition of the gingiva, looking for adequate zones of attached gingiva and the presence or absence of pockets. The condition of the supporting bone must be evaluated and mobility patterns recorded. If mucogingival involvements, osseous defects, or mobility patterns are recorded, the causes and potential treatment must be determined. Qral hygiene habits of the patient must be determined, and efforts made to educate the patient relative to plaque control. In addition, the patient must be advised of the importance of regular maintenance appointments after treatment. The most decisive evidence of oral hygiene habits is the condition of the mouth before the initial prophylaxis. Good or bad oral hygiene is basic to the patient's nature, and although it may be influenced somewhat by patient education ,.

Mucous membrane consideration:

Mucous membrane attach to bone compose of two layer

- Mucosa
- Sub mucosa

Types of Mucous membrane

a. Lining mucosa. (Stratified Sequemouse epithelium none keratinized Sub mucosa loosely or tight attach to the underlying mucosa lip, cheek, under side of tongue, usually comes in contact with denture border. (masticatory mucosa (keratinized stratified Sequemouse epithelium.

Mucosa of soft palate
Stratified Sequemouse epithelium non keratinized
Sub mucosa with numerous gland supporting membrane
It is a transition between loosely and fixed type of mucosa.
In the mandibular arch the distal end of the gingival area is well marked apear shaped area papilla .It is, pale, easy distinguish from retromolar pad firm, soft red

Need for extraction

Need for extraction of teeth for the following reasons

1. If the tooth cannot restore to a state of health, extraction may be unavoidable.
2. A tooth may be removed if its absence will permit amore serviceable and less complicated partial denture design.
3. A tooth may be extracted if it is so anesthetically located as to justify its removal to improve appearance.

Indications for RPD

There are several specific indications for the use of removable partial denture-:

1) The most common situations are partial edentulous space Cl I and Cl II which have an edentulous space on the opposite side of the arch is often conveniently present to aid in the required retention and stabilization of the partial denture.
2) The replacement of teeth recent extraction cannot be accomplished satisfactory with fixed restoration.
3) Along span may be totally tooth supported if the abutments and the means of transferring the support to the denture are adequate and if the denture framework is rigid.
4) Need for bilateral stabilization
5) The removable partial denture may act as a periodontal splint through its effective cross arch stabilization of teeth weakened by periodontal disease.
6) Excessive loss of residual bone

7) Economic considerations

The Recommended Infection Control Practices for Dental Treatment

1. Gloves should be worn in treating all patients.
2. Masks should be worn to protect oral and nasal mucosa from splatter of blood and saliva.
3. Eyes should be protected with some type of covering to protect from splatter of blood and saliva
4. Sterilization methods known to kill all life forms should be used on dental instruments. Sterilization equipment includes steam autoclave, dry heat oven, chemical vapor sterilizers, and chemical sterilants.
5. Attention should be given to cleanup of instruments and surfaces in the operatory. This includes scrubbing with detergent solutions and wiping down surfaces with iodine or chlorine (diluted household bleach solutions).
6. Contaminated disposable materials should be handled carefully and discarded in plastic bags to minimize human contact. Sharp items, such as needles and scalpel blades, should be contained in puncture-resistant containers before disposal in the plastic bags.

Differential diagnosis for fixd or removable partial denture

Although replacement of missing teeth by means of partial denture either tooth or implant supported is generally the method of choice, there are many reasons why a removable partial denture may be bitter method of treatment for specific patient. The choice of treatment must meet the economic limitations and personal desires of the patient. although uncommon, unilateral RPD in place of fixed partial denture. This type of prosthesis places excessive stresses on abutment teeth .possibly more important, the risk for aspiration is significant if such prosthesis dislodge during use. For these reasons, the use of unilateral RPD is strongly discouraged.

Types of RPD base material

1) **Gold alloy**
2) **Chromium cobalt alloy**
3) **Titanium**

Preparation of the Mouth to Receive a RPD

Evaluation of a patient's existing intraoral conditions for a removable partial denture prosthesis is an essential part of treatment planning.
The patient needs may be divided into the primary disciplines of dentistry: Surgery, Periodontics, Endodontics, Prosthodontics, and Orthodontics.
Surgically, the teeth, bone, and soft tissues should be evaluated to determine the need for surgical intervention.
Surgical considerations include:
(1) Structurally compromised teeth that may require extraction,
(2) Malposition or supraerupted teeth that may require extraction,
(3) Enlarged tuberosity that may require soft - or hard - tissue reduction,
(4) Exostoses and tori that may require removal or alveoloplasty, and
(5) Displaceable tissue, hyperplastic tissue, or an epulus that may require excision.
The periodontal status of the patient should be evaluated with regard to periodontal disease and plaque control. Periodontal disease control should be initiated when appropriate prior to the initiation of the definitive prosthodontic treatment.

As part of the evaluation process of the remaining teeth, a decision should be made with regard to the appropriateness of salvaging teeth through the use of endodontics. For example, an extruded or supraerupted tooth may be saved from extraction through endodontic therapy, reduction of the occlusal surface to realign the tooth into the proper plane of occlusion, and a crown.

Evaluate the mouth from a prosthodontic perspective, including caries detection and identifying defective restorations, structurally compromised teeth, occlusal plane discrepancies, malocclusion, and need for modification. Occasionally teeth may need to have crowns placed to correct these problems. In addition, during the surveying process of treatment planning for removable partial denture design, teeth should be evaluated for

acceptable crown contours, and the need for enameloplasty to correct tooth contours, create rest seats, and develop guide planes.

Tooth modification may be both subtractive as well as additive.
In addition to the tooth modification discussed above, surveyed crowns may be fabricated from gold and metal ceramic materials that have the desired modifications incorporated in them.
Preparation of mouth for RPD. It forms the second phase of treatment, the term of mouth preparation includes all procedure done to modify the existing oral condition of the patient to facilitate proper placement and functioning of the prosthesis.
Preparation of mouth for RPD include two parts

1. Preprosthetic mouth preparation: - done to remove any hindrance into the prosthetic treatment. Also done along with diagnosis and treatment planning.
2. Preprosthetic mouth preparation: is done to facilitate prosthetic treatment and done after partial denture design.

PREPROSTHETIC PROCEDURES

a. Relief of pain & infection.
b. Oral surgical procedures.
c. Conditioning of abused & irritated tissue
d. Periodontal therapy.
e. Correction of occlusal plane.
f. Orthodontic correction.
g. Splinting weakened teeth.
h. Reshaping teeth.
i. Preparation of rest and guiding planes

The Relief of pain & infection, the following condition should be treated in this phase of mouth preparation:

- Potential emergency condition like acute pain,abscess etc.
- Carious teeth with pain and discomfort.
- Asymptomatic teeth with deep carious lesions are excavated and filled with an intermediate restorative materials.

- Gingival disease like ANUG, AHGS, Gingival abscess etc.
- Calculus and plaque accumulation should be removed and preventive dental hygiene programs should be initiated and mentioned.

Oral surgical preparation.

The longer the time between surgery and impression procedure, the more complete the healing and consequently the more stable the denture bearing area. A variety of oral surgical technique can prove beneficial to the clinician in preparing the patient for pre prosthetic replacements.

The most common oral condition or changes in which surgical intervention indicated are:

- Extraction of teeth with poor prognosis
- Removal of residual roots.
- Extraction of impacted teeth **:**All impacted teeth should be considered for removal .this applies equally to the impaction in edentulous area ,as well as to those adjacent to abutment teeth
- Severely mal posed teeth the loss of individual teeth or group of teeth may lead to extrusion, mesial drifting, or combinations of mal positioning of remaining teeth. In most instances the alveolar bone supporting extruded teeth will be carried occlusaly as the tooth continues to erupt. Orthodontics may be useful in correction many occlusal discrepancies. But for some patients, such treatment may not be practical because of lack of teeth for anchorage of the orthodontics appliance or for other reasons. In such a situation individual teeth or groups of teeth and their supporting alveolar bone can be surgically repositioned. This type of surgery can be accomplished in an outpatient setting and should be given serious consideration.

EXTRACTION OF TEETH

- ❖ Planed extractions should occur early.
- ❖ Each tooth must be evaluated concerning its strategic importance and its potential contribution to the success of the RPD.
- ❖ The extraction of non-strategic teeth that would present complications or those whose presence may be detrimental to the design of the partial denture is a necessary part of the overall treatment plan.

Removal of Residual roots

- Generally, all retained roots or root fragments should be removed .This is particularly true if they are in close proximity to the tissue surface or if there is evidence of associated pathology.
- Residual roots adjacent to abutment teeth may contribute to the progression of periodontal pockets and compromise the result from sub sequent periodontal therapy

Indication for extraction:-

a. Where teeth can complicate /compromise the treatment.
b. Orthodontic treatment cannot correct mal alignment.
c. When teeth interfere with placement of a major connector.

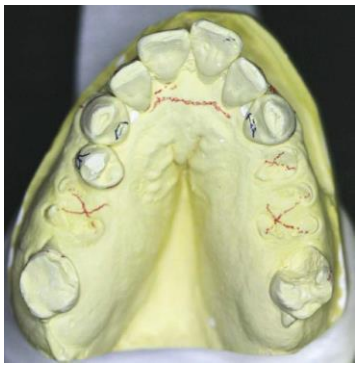

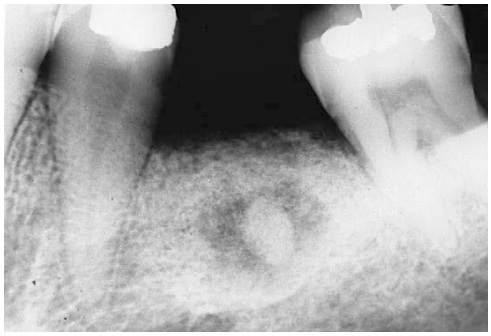

Cyst and odontogenic tumor.

The diagnosis may appear obvious from clinical and radiographic examinations the dentist should confirm that diagnosis through appropriate consultation and if necessary biopsy the area and submit the biopsy to pathologist.

Exostosis and tori.

Ordinarily the mucosa covering bony protuberance (Exostosis and tori) is extremely thin and friable. Patients' denture components in proximity to this type of tissue may cause irritation and chronic ulceration. Although





modification of denture design can, at time, accommodate for exostosis more frequently this result in additional stress to the supporting elements and compromised function. Surgical removal of tori bony exostosis can be done.

Hyperplasic tissue.

Hyperplasic tissues are seen in the form of fibrous tuberosity, soft tissue, fold of redundant tissue in the vestibule or floor of the mouth and palatal pappilomatosis. All these forms of excess tissue should be removed surgically .Always some form of surgical stent considered for these patients so that the period of healing will be more comfortable.



Muscle attachment and freni

As a result of the loss of alveolar bone height, muscle attachments may insert in or near the alveolar crest. The mylohyoid, buccinators, mentalis and genioglossus muscle are those most likely to introduce problem of this nature beside that the attachments of the muscles themselves, the mentalis and genioglossus muscles occasionally produce bony protuberance at their attachment that may also interfere with partial denture design .The comfort and function of the RPD can enhanced through repositioning of attachment especially mylohyoid muscle however repositioning of genioglossus muscle is more difficult to reposition. The maxillary labial and lingual freni are more probably to most frequent source of frequent interference with denture design.

Bony spine and Knife edge ridge

Sharp bony spicules should be removed and knife like crest gently rounded. These procedures should be carried out with minimum bone loss if, however, the correction of a knife edge alveolar crest results in insufficient ridge support for the denture base, the dentist should restore the vestibular deepening for correction of the deficiency polyps, papillomas and All abnormal soft tissue lesions should be excised and submitted for pathologic examination before the fabrication of RPD.

Hyperkeratosis, erythroplasia and ulceration

All abnormal white, red, or ulcerative lesions should be investigated regardless of their relationship to proposed denture base framework.

Dentofacial-deformity

A patient with Dentofacial deformity may have multiple missing teeth. Correction of the jaw deformity can simplify the dental rehabilitation. Surgical correction can be made in horizontal, sagittal or facial planes.

Mandible and maxilla may be positioned anteriorly or posteriorly, and their relationship to the facial planes may be surgically altered to achieve improved appearance. Replacement of missing teeth and development of a harmonious occlusion are very difficult in treating those patients

Osseo integrated devices

A number of implant device for replacement of teeth have been introduce. Titanium implant was designed to provide a direct titanium-to bone interface(Osseo integrated).The implant are placed using clean &controlled oral surgical procedure and are allowed to heal before surgical exposure and fabrication of a dental prosthesis.







Augmentation of alveolar bone

Hydroxyl appetite has been used as a material for augmentation of deficient alveolar bone, this material display a lack of toxicity and demonstrates no inflammatory or foreign body responses. This material provide increase in ridge width and height and also provide a matrix for new bone formation .it also non resorbable.

Conditioning of abused and irritated tissues

Should be treated before impression making → the tissue contour may change according to tissue healing.

<u>Causes</u>

a. ill-fitting dentures,

b. nutritional disturbances,

c. Diabetes

d. Blood dyscrasia.

Symptoms

→ Inflammation and irritation of soft tissues in the denture bearing areas.

→ Distortion of normal anatomical structures like incisive papillae, rugae, and retromolar pads.

→Burning sensation in the residual ridge, tongue, cheeks and lips

These conditions are usually associated with ill-fitting or poorly occluded RPD. So these conditions should be treated before relining or making a new RPD.



<u>The treatment procedure includes good home care by:</u>

- Rinsing the mouth three times daily with prescribed saline solutions
- Massaging the residual ridge area, palate and tongue with a soft tooth brush
- Removing the prosthesis at night
- Using a prescribed therapeutic multiple vitamins along with a prescribed high protein low carbohydrate diet.

MAXIMIUM BENEFIT FROM USING TISSUE CONDITIONING MATERIAL By:-

- Eliminating deflective or interfering occlusal contact of old dentures

- Extending denture base to proper form to enhance support, retention and stability.
- Relieving the tissue side of denture base sufficiently (2mm) to provide space for even thickness and distribution of the material.
- Applying the material in amount sufficient to provide support and a cushioning effect.
- Following manufacturer directions.

The conditioning procedure should be repeated until the supporting tissue display an undistorted and healthy appearance

Uses of tissue conditioning material

These are elastopolymers that continue to flow for extended period of time permitting distorted tissue to rebound and assume their normal form, these materials apparently have a smoothing effect on irritated mucosa and because they are soft, occlusal forces are probably more evenly distributed

Periodontal preparation

This procedure is over formed simultaneously with the oral surgical procedure It should completed before restorative procedure, because the success of this restoration depend on the health and integrity of the supporting structure of the remaining teeth .therefore ,the periodontal health of the teeth especially the abutments must be evaluated and corrective measures taken before RPD construction

Abutment teeth preparation

After several steps of mouth preparation of RPD construction (surgery, periodontal treatment, endodontic and tissue conditioning). The abutment teeth may be prepared to provide support, stabilization. Reciprocation and retention for RPD.

Classification of abutment teeth preparation

- Those abutment teeth that require only minor modification to their coronal portion.

- Those that are to have restoration other than crowns.
- Those that are to have crowns.

<u>The sequences of abutment tooth preparation on sound enamel or existing restoration are as follow:-</u>

- Proximal surface parallel to the path of placement should be prepared to provide guiding planes.

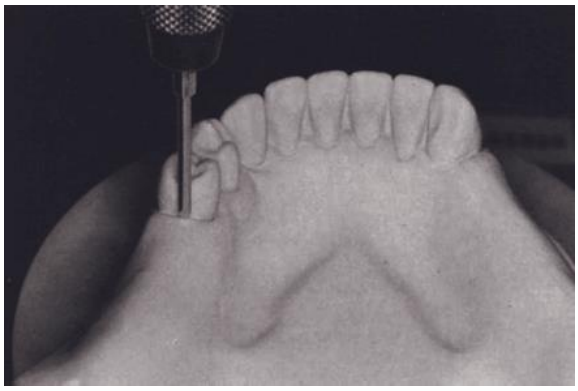



- tooth contours should be modified, lowering the height of contours so that:
  - The origin of circumferential clasp arm may be placed well below the occlusal surface, preferably at the junction of the middle and gingival thirds.
  - The retentive clasp terminals may be placed in the gingival third of the crown for better esthetic and better mechanical advantages.
  - Reciprocal clasp arm may be placed on and above a height of contour that is no higher than the cervical portion of the middle third of the After alterations of axial contours are accomplished and before rest seat preparation are instituted, an impression of the arch should be made in an irreversible hydrocolloid and a cast poured in a fast setting stone. This cast can be returned to the surveyor to determine the adequacy of axial alterations before proceeding with rest seat preparation. If axial surface require additional axial recontouring. it

can be performed during the same appointment and without compromise.

- Occlusal rest areas should be prepared that will direct the occlusal force along the long axis of the abatement
- crown of the abatement teeth.

<u>The procedure of rest seat preparation on sounds enamel surface:-</u>

- Round bur No.8 used to lower the marginal ridge and established the out line of the rest seat.
- Round bur No.6 used to slightly deepen the floor of the rest seat of the rest seat inside this lowered marginal ridge. This provides for an occlusal rest that satisfied the requirements that the rest be placed so that any occlusal force will be directed axially and that there will be the least possible interference to occlusion with the opposing teeth.
- The floor of the rest seat should incline towered the center of the tooth so that the occlusal forces are centered over the root apex.
- The marginal ridge must be lowered so that the angle formed by the occlusal rest with the minor connector will with stand above the occlusal surface of the abutment tooth as little as possible and above interface with opposing teeth. Simultaneously sufficient bulk must be provided to prevent a weakness in the occlusal rest at the marginal ridge. The marginal ridge must be lowered and yet not be deepest part of the rest preparation. To permit occlusal stress to be directed towered the center of the abutment tooth, the angle formed by the floor occlusal rest with the minor connector should be less than 90 degree. In other ward the floor of the occlusal rest should incline slightly from the lowered marginal ridge towered the center of the tooth

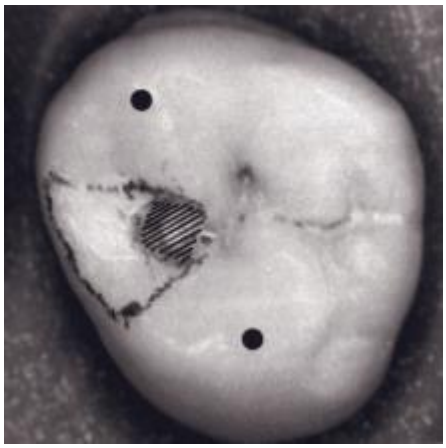

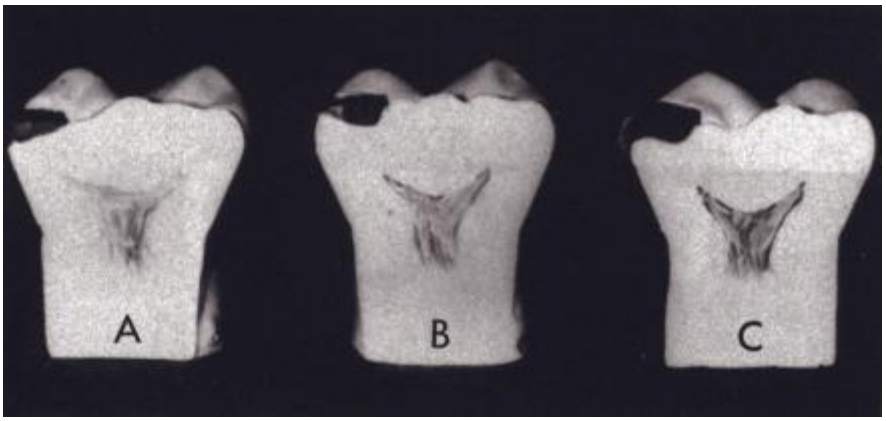



a b

The cingulum rest seat preparation requires a prominent cingulum. The preparation is a chevron or inverted “ V ” - shape mesiodistally (a), and a concave “ V ” - shape buccolingually (b).

Digital partial dentures and rapid prototyping procedure

The fabrication of computer-aided dental prostheses has become common practice in dentistry.

Computer-aided design and computer-aided manufacturing (CAD-CAM) technology have been applied to the fabrication of not only inlays and crowns but also complex fixed and removable dental prostheses.

For a removable prosthesis, due to the nature of the mode of an intraoral scanner that stitches narrow areas, it is difficult to scan the distally extended flat and broad edentulous area, and a functional impression is not possible as the technique is image-based. Therefore, at present, a digital concept in which the metal structure for a partial denture is designed in a virtual space based on the data obtained by scanning a definitive cast fabricated with a conventional functional impression is used.

Unlike the existing method, where a wax pattern is made on a definitive cast, a removable partial denture (RPD) is designed on a computer.

Based on this design, a 3-dimensional (3D) pattern is printed using rapid prototyping, with a resin that can be eliminated. The pattern subsequently undergoes investment, elimination, and casting, thereby completing the fabrication of a digital RPD framework.

A digital fabrication method has various advantages over conventional methods. In particular, electronic surveying performed in the virtual space,

the scan data, may determine the path of insertion and removal and control the undercut amount through computation in a more straightforward and accurate way than the conventional surveying.

Thus, an undercut with a desired gauge may be formed quantitatively at the position where the end of a retaining arm will be positioned. This information can be used for the fabrication of surveyed crowns and the framework of the RPD. Additionally, the design data may be saved for future use should there be a need to refabricate or modify the prosthesis. In addition, the total time of prosthesis fabrication is substantially reduced by eliminating some processes, including cast duplication and investment cast fabrication. In addition, multiple prosthesis patterns may be simultaneously produced in a short time frame. These advantages highlight the benefits of the digital over the conventional method.

Although different methods to generate a digital RPD have been described,8-11 studies to evaluate whether such methods can produce sufficient accuracy for clinical use have been limited. A previous study and analyzed the errors generated in the design process of a digital RPD and the accuracy within the oral cavity after completion of the prosthesis; however, that was a preliminary study performed in a small number of participants. Thus, its clinical effectiveness and accuracy could not be assessed, and an analysis of the accuracy of the digital RPD on a larger number of participants was needed.

on the basis of Intraoral functional impressions, including border molding, were made, on the basis of which a definitive cast was obtained Subsequently, the cast was scanned using a laboratory scanner files were extracted and loaded onto the CAD software

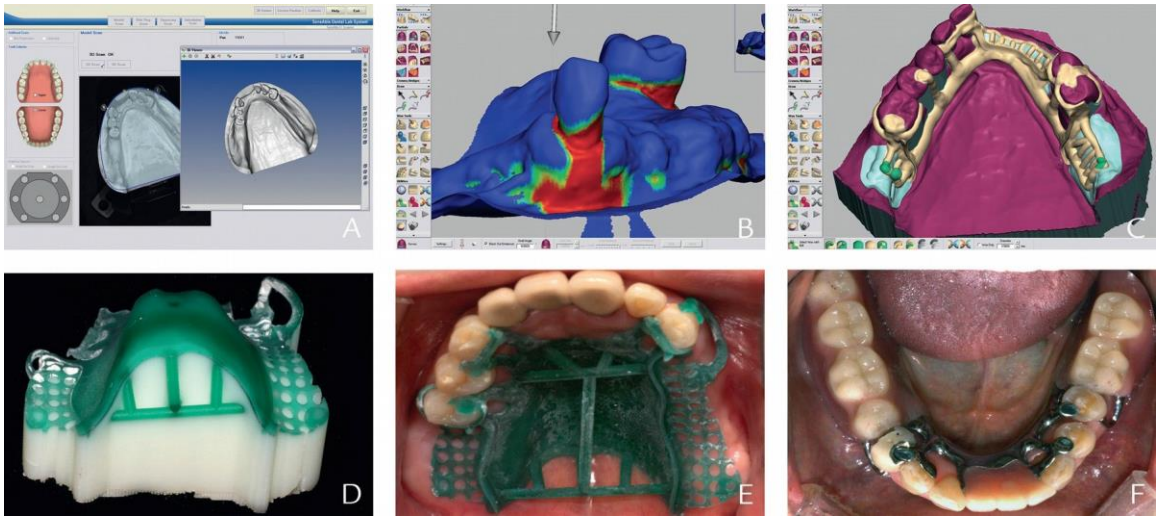

The framework of the RPD was designed by setting a surveying axis and computing the undercut to determine an ideal path of insertion and removal, the appropriate components, including the major connector, clasps, rests, proximal plates, and finish line, were designed.

Based on the completed design, a pattern was printed in resin (VisiJet M3 Dentcast; 3D Systems) using a rapid prototyping machine (ProJet DP 3000; 3D Systems); the pattern was invested, eliminated, and cast to generate the RPD framework.

The RPD was completed by using the conventional method, using heat polymerized resin and artificial teeth. After adjustments were made to ensure that the rests were seated on the rest seats of the abutment teeth, the denture was delivered to the participant.

Advantages highlight the benefits of the digital over the conventional method.

A digital fabrication method has various advantages over conventional methods. In particular, electronic surveying performed in the virtual space, on the basis of the scan data, may determine the path of insertion and removal and control the undercut amount through computation in a more straightforward and accurate way than the conventional surveying.
the design data may be saved for future use should there be a need to refabricate or modify the prosthesis.
the total time of prosthesis fabrication is substantially reduced by eliminating some processes, including cast duplication and investment cast fabrication.


Roland
monoFab
SRM-20

Fitting the removable partial denture framework

Why should a clinician be concerned with the fit of the framework? The rationale for having the clinician take responsibility for the fit of the framework is the same as the clinician taking responsibility for ensuring a single crown fits to the highest clinical standards suggested through the literature, so as to provide the patient with the highest quality of care over the long term.

Initial inspection

When the removable partial denture framework is returned from the dental laboratory:

1. Metal casting should be carefully inspected both off and on the master cast. Use of magnification such as dental loupes or a microscope is recommended.
2. The surface of the frame-work should be smooth and free from scratches and other defects.
3. Careful inspection should be made to ensure that the framework follows exactly the design submitted to the laboratory.
4. Ensure that all rest seats, indirect retainers, retention clasps, reciprocating clasps, major and minor connectors, and other components are present and well-constructed as requested on the design cast.
5. Metal framework components and connectors should be measured with calipers to ensure a minimum of 1.5 mm base metal alloy thickness for strength.

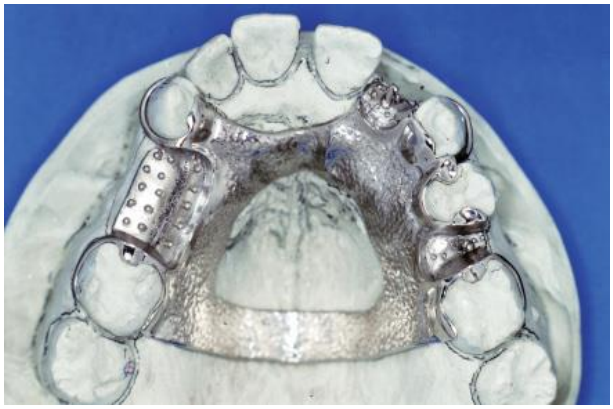

The intaglio surface of the framework should also be inspected using magnification.
Casting imperfections such as voids and nodules should be identified and removed or smoothed as indicated
There should be no voids or porosities present in high - stress areas such as where clasps and rest seats are connected to minor connectors. Internal and external finish lines should be sharp, well delineated, and less than 90 ° to provide adequate mechanical retention of the resin denture base to the metal framework.
When returned from the laboratory, all external metal components should be highly polished with the exception of the intaglio surface of the maxillary major connector, in an effort to provide close adaptation to the palatal tissue.
The internal components of the metal framework that contact tissue should have a smooth, matte - finished surface that maintains intimate soft - tissue contact.
The RPD framework should also be examined while seated on the master cast. Close scrutiny should be given to the adaptation of the major connector as well as the rest seats and clasps to the master cast. A metal frame that does not fit the master cast well will not likely fit the patient's mouth. If discrepancies are observed, the framework should be refined as needed. This step in evaluation of the framework is critical, comparable to when one inspects the accuracy of fit of a single - unit casting on a master die in fixed prosthodontics.

Methods and procedures for fitting the framework

A. Laboratory inspection

The initial fitting of the framework should first occur in the dental laboratory well before the patient arrives for the clinical appointment.
Initially, the internal surface of the Framework should be examined for obvious casting nodules, polishing paste, or other debris, which should subsequently be removed with a straight - shank round bur.
The metal framework should be inspected next while seating the framework on the master cast. If heavy rubbing against the cast or excessive seating pressure is required, the framework should be relieved to achieve smooth insertion onto the master cast. Close observation should be given to the full seating and adaptation of the major connector, clasps, rest seats, and indirect retainers.

The framework should sit passively on the master cast without wedging or impinging on the abutment teeth. If not fully seated, the internal surface of the framework should be painted with a disclosing medium such as chloroform and rouge paste, or disclosing wax

The framework should then be seated on the master cast using firm pressure. After removing the framework from the cast, it should be inspected under magnification for indication of internal high spots or frictional discrepancies as detailed by the disclosing medium. Adjustments are accomplished as needed until the metal casting is completely seated.

B. Clinical procedures

Once the framework is fitted to the master cast, the casting is ready for clinical try - in.

When the clinician receives the framework from the dental laboratory, this is an opportunity to inspect the fit to the master cast. Although requests to have the removable partial denture be fabricated to completion without an additional appointment to fit the framework may be common, each patient should receive consideration based on his or her diagnosis and intraoral assessment.

For instance, fabrication of a removable partial denture in a patient Kennedy Class I with an extensive number of missing posterior teeth associated with moderate to extensive residual ridge bone loss may indicate the necessity for a separate appointment to fit the framework and need for additional clinical procedures.

If the impression technique utilized is predictable and accurate, and the dental laboratory technician and the dental laboratory provide high - quality, well - made frameworks on a consistent basis, it is the judgment of the clinician whether or not to proceed to final fabrication of the completed removable partial denture.

If the RPD is completed without verifying the fit of the framework, the risk is the difficulty in discerning a fit problem if adjustments are required for both the acrylic resin portion on the intaglio surface and the framework.

The framework should be inspected using both visual and tactile sense during seating onto the abutment teeth. Direct seating pressure should be applied to the rest seats and major connector only, as pressure applied to tissue - borne denture base areas will cause the denture to pivot and rock.

Excessive force to seat the framework should not be required. The casting should go into place in a smooth manner without binding or catching the abutment teeth. Once seated, the framework should be inspected for complete

stability. The casting should fit passively without rocking or teetering. All major and minor connectors should be checked with magnification for close adaptation to the teeth and tissues.

In addition to the disclosing mediums previously mentioned, disclosing wax can be used to ensure there are no interferences causing binding or incomplete seating of the casting.



Common areas to inspect are along guide planes, under rest seats, in the shoulder areas of clasps, and on minor connectors.



Adjustment should continue to be made with high - speed diamond burs, carbide burs, or abrasive stones until the casting is fully seated. If the casting still will not go into place after several attempts at fitting the framework, a decision should be made to remake the framework.
A framework that fits the master cast but not the mouth indicates that the master cast is inaccurate and a new impression should be made to initiate the remake of the framework.

Occlusal evaluation

The framework should then be evaluated for clearance during patient articulation. Initially, remove the framework from the patient's mouth and ask him or her to occlude. Analyze the bite closely, and observe whether opposing cusps fit into wear facets or if opposing canines fully articulate together.

If open spaces are observed, the framework is elevated in occlusion and must be adjusted. When both maxillary and mandibular frameworks are being tried, they should be done individually before they are done together. Common areas of occlusal interferences are on rest seats, clasp shoulders, and minor connectors. Thin articulating marking paper, or disclosing wax can be used to discern high spots on the metal frame. Often it is difficult to mark and visualize highly polished areas, so a matte finish with micro - abrasion may be desired in these occluding areas. Disclosing wax can also be easily visualized when used to check occlusion





Metal calipers should be used routinely after adjustments to ensure at least 1.5 mm thickness of metal remains along rest seats, clasps, and minor connectors. Metal less than 1.5 mm in thickness will likely fracture or deform under function and necessitate remake.

The framework should be adjusted as needed until there is no contact of the metal against opposing teeth, prostheses, soft tissues, or metal frameworks. The adjusted areas should be repolished as needed. Following these adjustments, the patient should report occlusal stability and comfort. Further clinical procedures should be continued only after these criteria are strictly met.

Clinical procedures after fitting the framework

1. ***Corrected or altered cast***
This impression procedure is often required when the removable partial denture involves long - span distal extensions or long - span anterior edentulous areas



2. Maxillomandibular records
3. ***Facebow transfer***
4. ***Interocclusal records***
5. Wax try - in







Impression materials and techniques for RPD

Making the master impression for fabrication of a removable partial denture (RPD) prosthesis is accomplished once the remaining teeth in the partially edentulous arch have been modified. The modifications, including intracoronal and extracoronal restorations and/or enameloplasty to enhance extracoronal contours, should follow the treatment plan derived after careful analysis, design, and prescription for the prosthesis.

Classification of impression technique

1. PRIMARY IMPRESSION

An impression made for the purpose of diagnosis or for the construction of a tray.

2. **Secondary or definitive impression**

An imprint that record the entire functional denture bearing area to ensure maximum support, retention and stability for the denture during use.

Primary purpose to record accurately the tissues of the denture bearing areas, in addition to recording functional width and depth of the sulci.

Secondary impression CLASSIFIED INTO:-

1. Conventional techniques
2. Selective pressure techniques
3. Functional techniques
4. Reline and rebases techniques

Conventional technique also known as Anatomical or Mucostatic impression techniques:-the surface contour of the ridge is recorded at its resting form (no occlusal load) (soft or less viscous alginate impression material)

Disadvantages: In free end saddle dentures, distal end will show tissue ward movement under occlusal recommended for tooth supported partial dentures Kennedy class III and IV these are bounded saddles.

Selective pressure technique

Techniques to achieve selective pressure impression Kennedy Class I. Altered cast technique

Functional dual impression technique or Applegate

Selection of impression material

It is important to make an accurate impression in order to ensure the accuracy of the resulting master cast. The elastomeric impression materials available for use for the final impression include a range of materials from irreversible hydrocolloid (alginate) to vinylpolysiloxane or polyether impression materials. The range of choices varies according to the preference of the clinician.

Impression material

1. Rigid Impression material

a. Plaster of Paris

Now elastic materials have completely replaced the impression plaster,

Modified impression plasters are used by many dentists to record maxillomandibular relationships. Also used for recording impression of edentulous area without under cut.

b. Metallic Oxide Paste

They are not used as primary impression materials and should never be used for impressions that include remaining natural teeth. They are also not to be used in stock impression trays.

Metallic oxide pastes, being rigid substances, can be used as secondary impression materials for complete dentures and for extension base edentulous with custom acrylic impression tray which has being properly designed and attached to the partial denture framework.

Metallic oxide pastes can also be used as an impression material for relining distal extension denture base

2. Thermo-plastic impression material

It cannot record minute details accurately because they undergo permanent distortion during with drawl from undercut

Modeling Plastic

This material is most often used for border correction (border molding) of custom impression trays for Kennedy Class I and II removable partial denture bases.

Modeling plastic is manufactured in two different colors the red (red-brown) material in cake form record impression for edentulous area & green

modeling plastics are obtainable in stick form for use in border molding an impression

Impression Waxes and Natural Resins

use in recording the functional or supporting form of an edentulous ridge.

The impression waxes also may be used to correct the borders of impressions made of more rigid materials

3. Elastomeric impression Materials include the following

1. Polysulphide
2. Polyether
3. Silicone
   a. Additional polymerizing silicone
   b. Condensation polymerizing silicone.

polysulphide Impression Material used for removable partial denture impressions and especially for secondary corrected or altered cast impression

Reversible Hydrocolloids (agar-agar):-

1. It is used primarily as impression materials for fixed restorations. They demonstrate acceptable accuracy when properly use
2. Fluid at high temp and gel on reduction temperature
3. Acceptable accuracy when properly used.
4. border control of impressions made with these materials is difficult
   Main use is in fabrication of refractory cast in duplication procedure.
   It required special equipment (cooling tray) if being used as an intra-oral impression material.

Irreversible hydrocolloid

1. Irreversible hydrocolloids are used for making diagnostic casts, orthodontic treatment casts, and master casts for removable partial denture.
2. Dimensionally unstable, it can be used in presence of moisture are hydrophilic;
3. A pleasant taste and odor; and are nontoxic, no staining.
4. These material have allow strength provide less surface details than other material

Differences between reversible and irreversible hydrocolloid

The principal differences between reversible and irreversible hydrocolloids are as follows:

1. Reversible hydrocolloid converts from the gel form to a sol by the application of heat. It may be reverted to gel form by a reduction in temperature. This physical change is reversible.

2. Irreversible hydrocolloid becomes a gel via a chemical reaction as a result of mixing alginate powder with water. This physical change is irreversible.

use of irreversible hydrocolloid material — alginate — has been advocated based on multiple factors such as: the material is used widely in most dental practices, there is ease of handling and manipulation by support personnel, and it is relatively inexpensive and does not require special equipment in the office in most instances.

The key disadvantage in use of this material relates to the handling characteristics, in that there is a relatively short time period in which the material is accurate. The short period of time for predictable accuracy of alginate is based on the physical properties such as syneresis; the loss of fluid occurs in a short period of time and can affect the accuracy of the master cast. If managed properly, alginate impression material is cost - effective when pouring the master cast can be accomplished immediately after the impression is removed and disinfected. This implies the master cast is poured in the office in a timely fashion — less than 12 – 14 minutes from removal — rather than shipping the impression to an off - site dental laboratory for fabrication of the master cast at a later time.

The vinylpolysiloxane or polyether impression materials may be the impression material of choice since under the right conditions, either

maintains accuracy for a longer period of time when compared to alginate impression material. The ultimate goal is to obtain an accurate cast for fabrication of a removable partial denture prosthesis.

Important Precautions to Be Observed in the Handling of Hydrocolloid Impressions

1. Impression should not be exposed to air because some dehydration will inevitably occur and result in shrinkage.
2. Impression should not be immersed in water or disinfectants, because some imbibition will inevitably result, with an accompanying expansion
3. Impression should be protected from dehydration by placing it in a humid atmosphere or wrapping it in a damp paper towel until a cast can be poured. To prevent volume change, this should be done within 15 minutes after removal of the impression from the mouth
4. Exudates from hydrocolloid have a retarding effect on the chemical reaction of gypsum products and results in a chalky cast surface. This can be prevented by pouring the cast immediately or by first immersing the impression in a solution of accelerator, if an accelerator is not included in the formula.

STEPS IN IMPRESSION MAKING

a. Position of patient & dentist (Dentist should stand & patient should sit upright)
b. Tray selection
c. Mixing the material & loading into the tray
d. Impression making & removal
e. Inspecting, cleaning & disinfecting the impression

Occlusal plane should be parallel to the floor

MAXILLARY IMPRESSION- dentist should stand at the right rear of the patient.

MANDIBULAR IMPRESSION- dentist should stand at the right front of the patient.

Tray selection

The choice of an impression tray can include stock impression trays both made of metal or the more rigid plastics available. The use of rigid plastic impression trays can be advantageous since most are intended to be disposable and do not require additional dental assistant time for cleaning after use. Stock impression trays are available as rim - lock or other mechanical retention design such as perforated trays, and both can be modified for use intraorally to meet the anatomical features of the patient. The prime consideration in tray selection is to choose one with the absolute rigidity that must be afforded by the tray material.

The step-by-step procedure and important points to observe in the making of a hydrocolloid impression are as follows:

1. Select a suitable, sterilized, perforated or rim-lock impression tray that is large enough to provide a 2- 4 to -mm thickness of the impression material between the teeth and tissues and the tray.

2. Build up the palatal portion of the maxillary impression tray with wax or modeling plastic to ensure even distribution of the impression material and to prevent the material from slumping away from the palatal surface. At this time, it is also helpful to pack the palate with gauze that has been sprayed with a topical anesthetic. This will serve to anesthetize the minor salivary glands and mucous glands of the palate and thus prevent secretions as a response to smell or taste or to the physical presence of the impression material. If gelation occurs next to the tissues while the deeper portion is still fluid, a distorted impression of the palate may result, which cannot be detected in the finished impression. This may result in the major connector of the finished casting not being in contact with the underlying tissues. The maxillary tray frequently has to be extended posteriorly to include the tuberosities and the vibrating line region of the palate. Such an extension also aids in correctly orienting the tray in the patient's mouth when the impression is made.

3. The lingual flange of the mandibular tray may need to be lengthened with wax in the retromylohyoid area or to be extended posteriorly, but it rarely

ever needs to be lengthened elsewhere. Wax may need to be added inside the distolingual flange to prevent the tissues of the floor of the mouth from rising inside the tray.

4. Place the patient in an upright position, with the arch to be impressed nearly parallel to the floor.

5. When irreversible hydrocolloid is used, place the measured amount of water (at 70°F) in a clean, dry, rubber mixing bowl (600-mL capacity). Add the correct measure of powder. Spatula move rapidly against the side of the bowl with a short, stiff spatula. This should be accomplished in less than 1 minute. The patient should rinse his or her mouth with cool water to eliminate excess saliva while the impression material is being mixed and the tray is being loaded.

6. In placing the material in the tray, avoid entrapping air. Have the first layer of material lock through the perforations of the tray or rim-lock to prevent any possible dislodgment after gelation.

7. After loading the tray, remove the gauze with the topical anesthetic and quickly place (rub) some of the impression material on any critical areas using your finger (areas such as rest preparations and abutment teeth). If a maxillary impression is being made, place the material in the highest aspect of the palate and over the rugae.

8. Use a mouth mirror or index finger to retract the cheek on the side away from you as the tray is rotated into the mouth from the near side.

9. Seat the tray first on the side away from you, next on the anterior area, while reflecting the lip, and then on the near side, with the mouth mirror or finger for cheek retraction. Finally, make sure that the lip is draping naturally over the tray.

10. Be careful not to seat the tray too deeply, leaving room for a thickness of material over the occlusal and incisal surfaces.

11. Hold the tray immobile for 3 minutes with light finger pressure over the left and right premolar areas. To avoid internal stresses in the finished

impression, do not allow the tray to move during gelation. Any movement of the tray during gelation will produce an inaccurate impression.If, for example, you allow the patient or the assistant to hold the tray in position at any time during the impression procedure, some movement of the tray will be inevitable during the transfer and the impression will probably be inaccurate. Do not remove the impressionfrom the mouth until the impression material has completely set.

12. After releasing the surface tension, remove the impression quickly in line with the long axis of the teeth to avoid tearing or other distortion.

13. Rinse the impression free of saliva with slurry water, or dust it with plaster, and rinse gently; then examine it critically. Spray the impression thoroughly with a suitable disinfectant and cover it immediately with a damp paper towel. A cast should be poured immediately into a disinfected hydrocolloid impression to avoid dimensional changes and syneresis. Circumstances often necessitate some delay, but this time lapse should be kept to a minimum. A delay of 15minutes will satisfy the disinfection requirements and should not be deleterious if the impression is kept in a humid atmosphere

Step-by-Step Procedure for Making a Stone Cast from a Hydrocolloid Impression The step-by-step procedure for making a stone cast from the impression is as follows:

1. A more abrasive-resistant type IV stone should be used to form removable partial denture casts. Have the measured dental stone at hand, along with the designated quantity of room temperature water, as recommended by the manufacturer. A clean 600-mL rubber mixing bowl, a stiff spatula, and a vibrator complete the preparations. A No. 7 spatula also should be within reach.

2. First, pour the measure of water into the mixing bowl and then add the measure of stone. Spatulate thoroughly for 1 minute, remembering that a weak and porous stone cast may result from insufficient spatulation. Mechanical spatulation under vacuum is preferred. After any spatulation

other than in a vacuum, place the mixing bowl on the vibrator and knead the material to permit the escape of any trapped air.

3. After removing the impression from the damp towel, gently shake out surplus moisture and hold the impression over the vibrator, impression side up, with only the handle of the tray contacting the vibrator. The impression material must not be placed in contact with the vibrator because of possible distortion of the impression.

4. With a small spatula, add the first cast material to the distal area away from you. Allow this first material to be vibrated around the arch from tooth to tooth toward the anterior part of the impression. Continue to add small increments of material at this same distal area, with each portion of added stone pushing the mass ahead of it. This avoids the entrapment of air. The weight of the material causes any excess water to be pushed around the arch and to be expelled ultimately at the opposite end of the impression. Discard this fluid material. When the impressions of all teeth have been filled, continue to add artificial stone in larger portions until the impression is completely filled.

5. The filled impression should be placed so that its weight does not distort the hydocolloid impression material. The base of the cast can be completed with the same mix of stone. The base of the cast should be 16 to 18 mm (23 to34 inch) at its thinnest portion and should be extended beyond the borders of the impression so that buccal, labial, and lingual borders will be recorded correctly in the finished cast. A distorted cast may result from an inverted impression.

6. As soon as the cast material has developed sufficient body, trim the excess from the sides of the cast. Wrap the impression and cast in a wet paper towel, or place it in a humidor, until the initial set of the stone has taken place. The impression is thus prevented from losing water by evaporation, which might deprive the cast material of sufficient water for crystallization. Chalky cast surfaces around the teeth are often the result of the hydrocolloid’s acting as a sponge and robbing the cast material of its necessary water for crystallization.

7. After the cast and impression have been in the humid atmosphere for 30 minutes, separate the impression from the cast. Thirty minutes is sufficient for initial setting. Any stone that interferes with separation from the tray must be trimmed away with a knife.

8. Clean the impression tray immediately while the used impression material is still elastic.

9. Trimming of the cast should be deferred until final setting has occurred. The sides of the cast then may be trimmed to be parallel, and any blebs or defects resulting from air bubbles in the impression may be removed. Master casts and other working casts are ordinarily trimmed only to remove excess stone.

Possible Causes of an Inaccurate and/or a Weak Cast of a Dental Arch

The possible causes of an inaccurate cast are as follows:

1. Distortion of the hydrocolloid impression (a) by use of an impression tray that is not rigid; (b) by partial dislodgment from the tray; (c) by shrinkage caused by dehydration;(d) by expansion caused by imbibition (this will be toward the teeth and will result in an undersized rather than oversized cast); and (e) by attempting to pour the cast with stone that has already begun to set.

2. A ratio of water to powder that is too high. Although this may not cause volumetric changes in the size of the cast, it will result in a weak cast.

3. Improper mixing. This also results in a weak cast or one with a chalky surface.

4. Trapping of air, either in the mix or in pouring, because of insufficient vibration.

5. Soft or chalky cast surface that results from the retarding action of the hydrocolloid or the absorption of necessary water for crystallization by the dehydrating hydrocolloid.

6. Premature separation of the cast from the impression.

7. Failure to separate the cast from the impression for an extended period.

TECHNIQUE USED FOR INDIVIDUAL IMPRESSION TRAYS:-

1. Outline the extent of the tray on the cast with a pencil. The tray must include all teeth and tissues that will be involved in the removable partial denture.

2. Adapt one layer of baseplate wax over the tissue surfaces and two layers over the teeth of the cast to serve as a spacer for impression material. The wax spacer should be trimmed 2 to 3 mm short of the outline drawn on the diagnostic cast. Wax covering the posterior palatal seal area should be removed so that intimate contact of the tray and tissue in this region may serve as an aid incorrectly orienting the tray when the impression is made. Expose portions of the incisal edges of the central incisors to serve as anterior stops when placing the tray in the mouth. Bevel the wax so that the completed tray will have a guiding incline that will help position the tray on the anterior stop. Other cast undercuts should be blocked out with wax or modeling compound. NOTE:

Adapt an additional layer of baseplate wax over the teeth if the impression is to be made in irreversible hydrocolloid. This step is not necessary if the choice of impression material is a rubber-base or silicone type of material.

3. Paint the exposed surfaces of the cast that may be contacted by the light polymerized resin tray material with a model release agent (MRA) to facilitate separation of the polymerized tray from the cast.

4. Remove the VLC tray material from the light-proof pouch and carefully cut the desired length with a knife or scalpel. Adapt the VLC material to the

cast and trim it with a knife. Be sure not to thin the material over the teeth or the posterior border area.

5. Attach a handle by molding excess VLC material into the desired shape and blend it into the tray material in the cast. With some materials, a paper clip or similar wire may be shaped and used to reinforce the handle. Alternatively, some manufacturers make prefabricated metal custom tray handles that may be easily adapted. Place the cast with the adapted tray in the light polymerizing and process according to the manufacturer's directions—usually a maximum of 1 minute.

7. Remove the cast from the unit and gently remove the tray from the cast. Peel the softened wax out of the tray while the wax is still warm.

8. Paint the entire impression tray with the manufacturer's air barrier coating material and return the tray to the unit turnstile for additional polymerizing, tissue side up.

9. When the polymerizing cycle is completed, remove the tray from the unit and clean it with a brush and water.

10. Perfect the borders of the tray with rotary instruments (vulcanite burs, acrylic-resin trimmers, etc.), and slightly polish the external surface of the tray.

11. Place perforations (No. 8 bur size) in the VLC resin tray at 5-mm (316-inch) intervals, with the exception of the alveolar groove areas, if an irreversible hydrocolloid impression material is to be used .

12. The finished tray must be sanitized and tried in the mouth so that any necessary corrections to the tray can be accomplished before the impression is made.

Secondary impression(Same as that for diagnostic impression).

In this procedure paint or inject impression material in critical areas:

- Rest preparation
- Hard palate
- Peripheral extensions

SPECIAL IMPRESSION PROCEDURES

a.Anatomic form:- The anatomic form is the surface contour of the ridge when it is not supporting an occlusal load

b. Functional Form of Ridge:- The functional form of the residual ridge is the surface contour of the ridge when it is supporting a functional load

Procedure

A custom impression tray is constructed over a preliminary cast

Functional impression of distal extension ridge is made. Patient applies some biting force with occlusion rims

Then an Alginate impression is made with the 1st impression held in its functional position with finger pressure

Mc LEAN'S PHYSIOLOGIC IMPRESSION

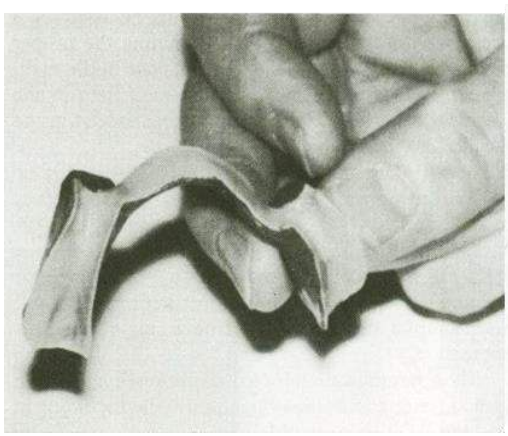

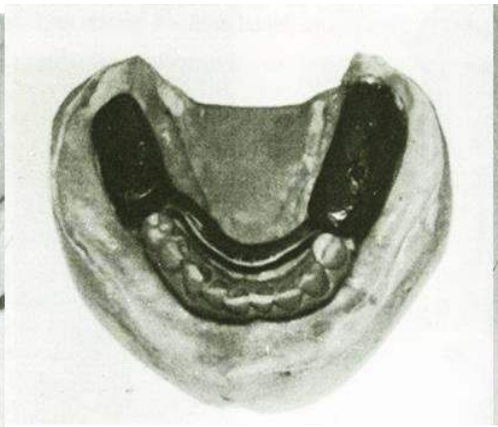

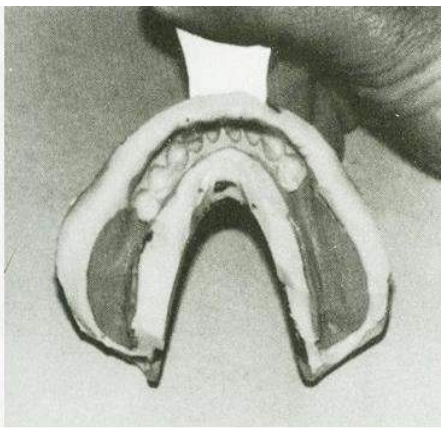

HINDEL'S MODIFICATION

Main difference of this with Mc Lean's is that

- impression of edentulous ridge is not made under pressure but is an anatomic impression made at rest with ZOE paste.
- As the hydrocolloid impression was being made finger pressure was applied through holes in the tray to the anatomic impression.

<u>Disadvantages of these methods</u>

- Constantly compressed residual ridge is prone to excessive bone resorption.
- If the clasp do not hold the partial denture, the denture will be pushed slightly occlusally by the tissue causing premature contacts (TISSUE REBOUND)

The Recommended Infection Control Practices for Dental Treatment

1. Gloves should be worn in treating all patients.
2. Masks should be worn to protect oral and nasal mucosa from splatter of blood and saliva.
3. Eyes should be protected with some type of covering to protect from splatter of blood and saliva
4. Sterilization methods known to kill all life forms should be used on dental instruments. Sterilization equipment includes steam autoclave, dry heat oven, chemical vapor sterilizers, and chemical sterilants.
5. Attention should be given to cleanup of instruments and surfaces in the operatory. This includes scrubbing with detergent solutions and wiping down surfaces with iodine or chlorine (diluted household bleach solutions).
6. Contaminated disposable materials should be handled carefully and discarded in plastic bags to minimize human contact. Sharp items, such as needles and scalpel blades, should be contained in puncture-resistant containers before disposal in the plastic bags.

Support for the Distal Extension Denture Base

Support: resistance to vertical components of masticatory force in a direction toward the basal seat

All partial dentures have two things in common:

1- They must be supported by oral structures and
2- They must be retained against reasonable dislodging forces.

Support can be classified according to **Cradock**:

1. Dental support
2. Mucosal support
3. Mixed: dental and mucosal/ mucosal and dental support

Designing Support

a- Tooth ***support***: When abutment teeth available at both ends of the denture base (bounded saddle). It most commonly obtained by occlusal rests.

b- Mucosa ***support***: (mucoperiosteum covering residual alveolar bone). It allows varying degree of displacement.

The amount of displacement (tissue ward movement) will depend on:
1- The amount of pressure applied.
2- The nature of the mucosa (thickness).
3- Area covered by the denture (the wider the area the less the displacement).
4- Fit of the denture base.

5- Type of impression (anatomical, functional, or selective pressure).

c-*Tooth-mucosa support:* (Bilateral free end saddle). Posterior tissue support, and anterior tooth support.
In the class III PD three components are necessary, support provided by rests, the connectors (stabilizing components) and the retainers. An anatomical impression is the only needed to record the anatomic form of the teeth and residual ridge in tooth born RPD.

*The distal extensions PD does not have the advantage of total tooth supported because one or more bases are extensions covering the residual ridge distal to the last abutment, but in this situation, the support comes from both the teeth and the underlying ridge tissues rather than from teeth alone.

*This is a composite support, and the prostheses must be fabricated so that the resilient support provided by the edentulous ridge is coordinated with the more stable support offered by the abutment teeth.

*The distal extension removable partial denture must depend on the residual ridge for some support, stability, and retention. Indirect retention, to prevent the denture from lifting away from the residual ridge, should also be incorporated in the design.

In addition provision must be made for three other factors:

1- Best support must be obtained from the resilient tissues that cover the edentulous ridges. This is accomplished by the impression technique more than by the PD design. The area covered by the pd base is a factor in such support.
2- The method of direct retention must take into account the inevitable tissueward movement of distal extension

base(s) under the stress of mastication and occlusion. Direct retainers must be designed so that the occlusal loading will result in the direct transmission of this load to the long axis of the abutment teeth.

3- The PD, with one or more distal extension denture bases, must be designed so that movement of the unsupported and un retained end away from the tissues will be prevented by indirect retainer.

The main problems which might occur in tooth-tissue support are:

1- Mucosa is resilient and displaceable and can lead to unstable prostheses.
2- Difficult to record mucosa at resting and at displaced condition simultaneously.
3- In distal ERPD under function compresses the mucosa and act as class I lever thus it cause damaging to the abutment teeth, the solution is to record tissue in the functional form so the denture not exert additional stress to the abutment teeth.

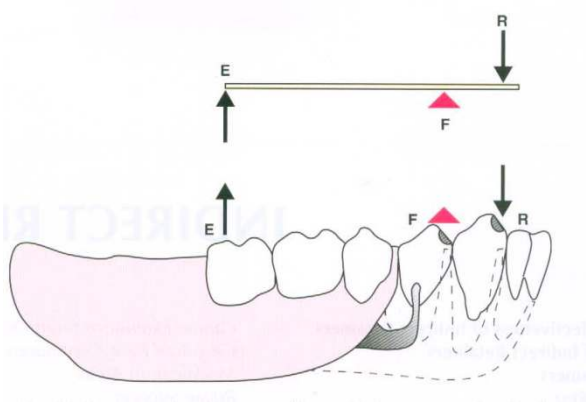

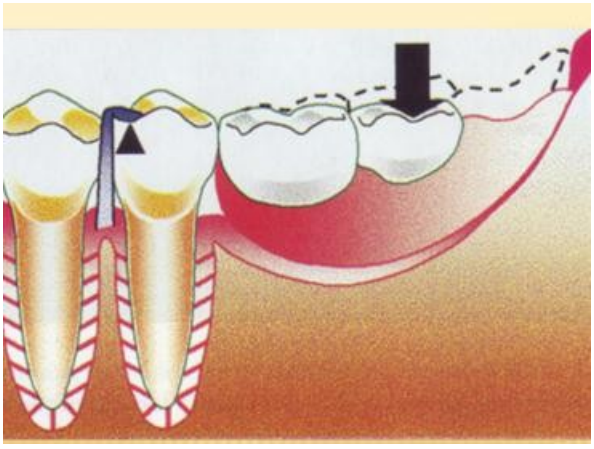

<u>Factors infuencing the support of a distal extension denture base</u>

<u>1- Quality of the residual ridge.</u>
<u>2- Extent of residual ridge coverage by the denture base.</u>
<u>3- Type and accuracy of impression registration.</u>
<u>4- Accuracy of denture base.</u>
<u>5- Design of the the partial frame work.</u>
<u>6- Total occlusal load applied,</u>

<u>1-Quality of the residual ridge for good support</u>.

- The ideal residual ridge to support a denture base would consist of cortical bone that covers

relatively dense cancellouse bone with abroad rounded crest and high vertical slopes, and covered by firm, dense fibrous connective tissue.

- Buccal self-area (bounded by the external oblique line and crest of alveolar ridge) in the lower ridge as primary stress bearing area, because it is covered by relatively firm, dense, fibrous connective tissue supported by cortical bone, while the crest is mostly cancellous not good for support. While in maxillary ridge the crest is primary stress bearing area.
- Slopes of the ridge can resist horizontal forces.

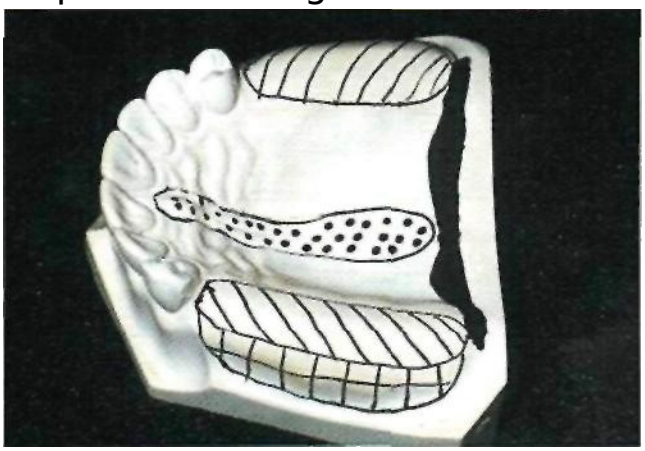

Crest of maxillary residual ridge *(diagonal lines/* is primary supporting region for maxillary distal extension denture base. Buccal and palatal slopes may furnish limited vertical support to denture base. It seems logical that their primary role is to counteract horizontal rotational tendencies of denture base. *Dotted portion* outlines incisive papilla and median palatal raphe. Relief must be provided for these regions, especially if tissues covering palatal raphe are less displaceable than those covering crest of residual ridge.

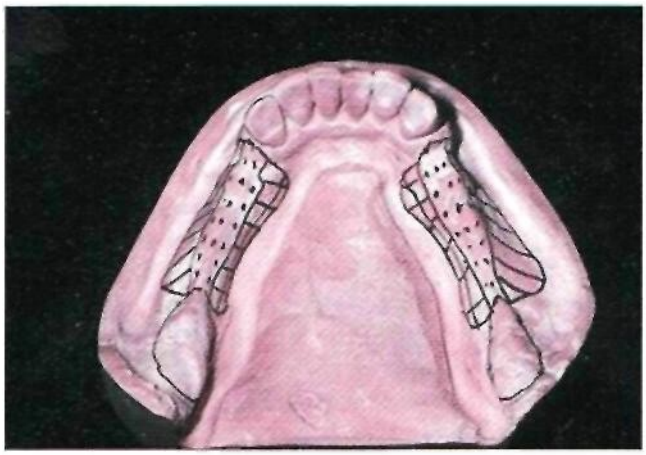

Dotted portion outlines cresi of residual ridge, which should be recorded in its anatomic form in impression procedures. Similarly, retromolar pads should not be displaced by impression. Buccal shelf regions *(diagonal lines*' serve as primary support and therefore additional pressures may be placed on these regions for vertical support of denture base. Lingual slopes of residual ridge *tcross-hatched)* may furnish some vertical support to restoration; however, these regions principally resist horizontal rotational tendencies of denture base and should be recorded by impression in undisplaced form.

2- Extent of residual ridge coverage by the denture base.

The broader the residual ridge coverage the greater the distribution of the load, which results in less load per unit area. A denture base should cover as much of the residual ridge as possible and be extended the maximum amount within the physiological tolerance of the limiting border structures or tissue lead to better distribution of load and better withstanding of vertical and horizontal forces.

The longer the edentulous area covered by the denture base, the greater the potential lever action on the abutment teeth.

- Flat ridge will provide good support, poor stability.
- Sharp spiny ridge will provide poor support, poor to fair stability.
- Displaceable tissue on ridge will provide poor support and poor stability.

The DERPD derives its support from the residual ridge with its fibrous connective tissue covering. The length and contour of residual ridge significantly influence the amount of available support and stability.



Comparison of two removable partial dentures for same patient. A, A distal extension base that is adequately extended, as it covers both the buccal shelf and retromolar pad. B, Underextension of this base results in less support to the prosthesis from the residual ridge, which can cause increased instability of the prosthesis.

3-Type and accuracy of impression registration.

The residual ridge may be said to have two forms:

1- The anatomic form: The anatomic form is the surface contour of the ridge when it is not supporting an occlusal load. The anatomic form and the relationship of the remaining teeth in the dental arches, as well as the surrounding soft tissue, must be recorded accurately so that the denture will not exert pressure on those structures.

2- The functional form of the residual ridge is the surface contour of the ridge when it is supporting a functional load. The support form of the soft tissues underlying the DE base of the PD should be recorded so that firm areas are used as primary stress- bearing areas and readily displaceable tissues are not over loaded, only in this way can maximum support of the PD base be obtained.

*McLean and others recognized the need to record the tissue that supports a distal extension removable partial denture base in its functional form, or supporting state, and then relate them to the remainder of the arch by means of a secondary impression. This was called ***a functional impression*** because it recorded the ridge relation under simulated function.

Many of the requirements and advantages that are associated with the distributed stress denture apply equally well to the functionally or physiologically based denture. Some of these requirements are:

(1) Positive occlusal rests; (2) an all-rigid, nonflexible framework; (3) indirect retainers to acid stability; and (4) well-adapted, broad coverage bases.

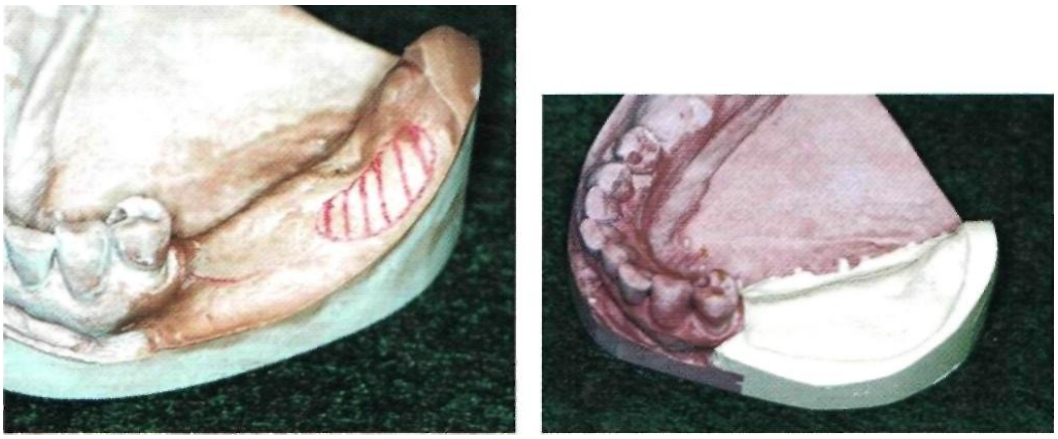

Comparison of anatomic and functional ridge forms. A, Original mandibular cast showing left residual ridge area recorded in its anatomic form. Buccal shelf region is outlined. B, Same cast after left residual ridge area has been repoured to its functional form as recorded by secondary impression.

4- accuracy of denture base.

- Distal extension base is enhanced by intimacy of contact of the tissue surface of the base and the tissue that covers the residual ridge. The tissue surface of the denture base must optimally represent a true negative of the basal seat regions of the master cast.
- In addition, the denture base must be related to the removable partial denture framework in the same manner as the basal seat tissue was related to the abutment teeth when the impression was made. Every precaution must be taken to ensure this relationship when the altered cast technique of making a master cast is used.

5- Design of the the partial frame work.

*Some rotation movement of a distal extension base at the distal abutment is inevitable under functional loading.

*The greatest movement takes place at the most posterior extent of the denture base, the retromolar pad region of the mandibular residual ridge and the tuberosity region of the maxillary residual ridge therefore are subjected to the greatest movement of the denture base

*use of more anterior or mesial rest is suggested as it allow vertical ridge loading,

Permit greater ridge area for support, transfer stress to anterior abutment.

*Incorporation of indirect retainer.

*Incorporation of RPI system in free end suddle which make stress release.

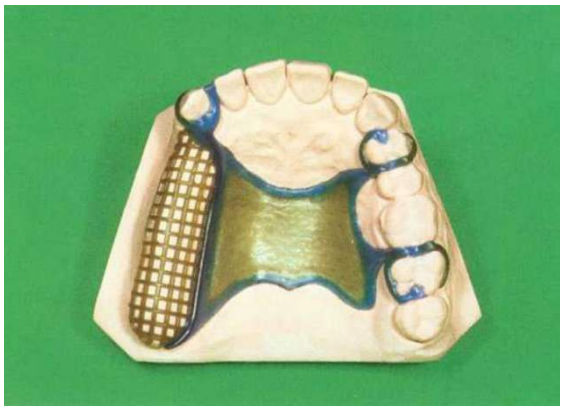

A typical framework for restoring a unilaterally shortened maxillary arch. A maximally extended denture base combined with a wide palatal strap helps resist rotation.

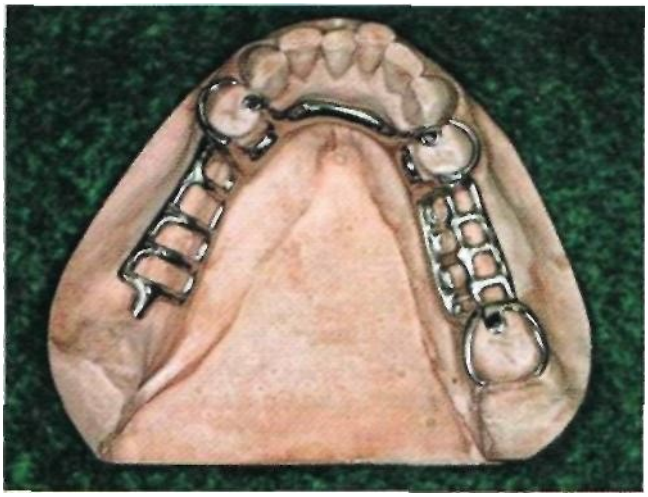

Occlusal rest is placed on mesioocclusal surface of left mandibular first premolar, which will move point of rotation anterior to conventionally placed disto-occlusal rest if contact of proximal minor connector on distal guiding plane is designed to release under function. Occlusal rest is connected to lingual bar by minor connector, which contacts small mesiolingual prepared guiding plane.

6. Total occlusal load applied,

- Patients with distal extension removable partial dentures generally orient the food bolus over natural teeth rather than prosthetic teeth, because of: 1-) the more stable nature of the natural dentition. 2-) The proprioceptive feedback they provide for chewing, and 3-) the possible nociceptive feedback from the supporting mucosa.
- This has an effect on the direction and magnitude of the occlusal load to the removable partial denture, and thus on the load transferred to the abutments.
- The support from the residual ridge should be optimized and shared appropriately with the remaining natural dentition.
- The ***number*** of artificial teeth, the ***width*** of their occlusal surfaces, and their ***occlusal efficiency***

influence the ***total occlusal load*** applied to the removable partial denture.

- The ***reduction of the size of the occlusal table reduces the vertical and horizontal forces*** that act on the removable partial dentures and lessens the stress on the abutment teeth and supporting tissue.

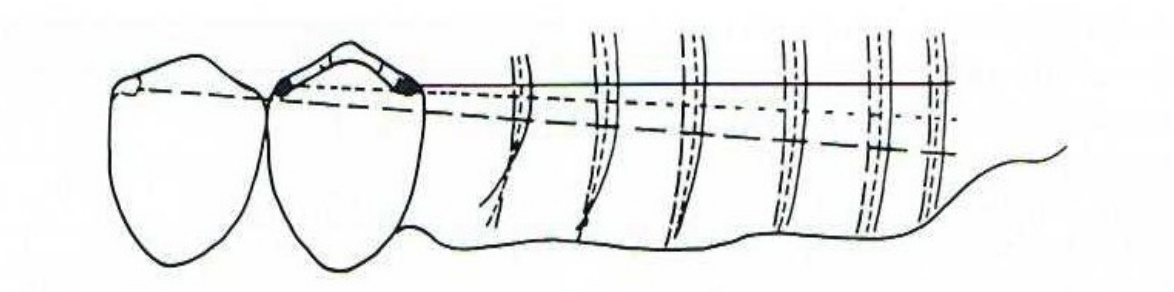

Figure 16-6 If rotation of distal extension base occurs around nearest rest; as rest is moved anteriorly, more of residual ridge will be used to resist rotation. Compare vertical arcs of long-dash broken line with arcs of solid line. (See also Figure 10-4.)

- **ANATOMIC FORM IMPRESSION**

* The anatomic form impression is a one-stage impression method using an elastic impression material that will produce a cast that does not represent a functional relationship between the various supporting structures of the partially edentulous mouth. It will only represent the hard and soft tissue at rest.

* With the removable partial denture in position in the dental arch, the occlusal rest(s) will fit the rest seat(s) of the abutment teeth, whereas the denture base(s) will fit the surface of the mucosa at rest.

* When a masticatory load is applied to the extension base(s) with a food bolus, the rest(s) will act as a definite stop, which will limit the part of the base near the abutment tooth from transmitting the load to the underlying anatomic structures.

* The distal end of the base(s) that is able to move more freely, however, will transmit more of the masticatory load to the underlying extension base tissue and will transmit more torque to the abutment teeth through the rigid removable partial denture framework.

* A removable partial denture fabricated from a one-stage impression, which only records the anatomic form of basal seat tissue, places more of the masticatory load on the abutment teeth and that part of the bone that underlies the distal end of the extension base.

METHODS FOR OBTAINING FUNCTIONAL SUPPORT FOR THE DISTAL EXTENSION BASE

The objective of any functional impression technique is to provide maximum support for the removable partial denture bases.

- This allows for the maintenance of occlusal contact between both natural and artificial dentition.
- Minimum movement of the base, which would create leverage on the abutment teeth.
- Some tissueward movement of the distal extension base is unpreventable and dependent on the six factors listed previously, it can be minimized by providing the best possible support for the denture base.

- No single impression material can record both the anatomic form of the teeth and tissue in the dental arch and, at the same time. The functional Form of the residual ridge. Therefore some secondary or corrected impression method must be used.
- Methods for obtaining functional support for either should satisfy the two requirements for providing adequate support to the distal extension removable partial denture base. These are (1) that it records and relates the supporting soft tissue under some loading and (2) that it distributes the load over as large an area as possible.

Selective Tissue Placement Impression Method

- Soft tissue that covers basal seat areas may be placed, displaced, or recorded in their resting or anatomical form. Placed and displaced tissue differs in the degree of alteration from their resting form and in their physiological reaction to the amount of displacement. For example, the palatal tissue in the vicinity of the vibrating line can be slightly displaced to develop a posterior palatal seal for the maxillary complete denture and will remain in a healthy state for extended periods. On the other hand, this tissue develops an immediate inflammatory response when it has been overly displaced in developing the posterior palatal seal.
- Oral tissues that have been overly displaced or distorted attempt to regain their anatomic form. When they are not permitted to do this by the denture bases, the tissues become inflamed and their physiological functions become impaired, accompanied by bone resorption. Tissues that are minimally displaced (placed) by impression procedures for

definitive border control respond favorably to the additional pressures placed on them by the resultant denture bases if these pressures are intermittent rather than continuous.

- ***The selective tissue placement impression method*** *is based on these* ***clinical observations****:*
  ***** The histological nature of tissue that covers the residual alveolar bone.
  * The nature of the residual ridge bone.
  * And its positional relationship to die direction of stresses that will be placed on it.
  It is further believed that by use of specially designed individual trays for impressions, denture bases can be developed that will use those portions of the residual ridge that can withstand additional stress and at the same time relieve the tissue of the residual ridge that cannot withstand functional loading and remain healthy.

Occlusal Relationship for Removable Partial Denture

And Recording Jaw Relationship of RPD

The fourth phase in the treatment of patients with removable partial dentures is the establishment of a functional and harmonious occlusion. Occlusal harmony between a removable partial denture and the remaining natural teeth is a major factor in the preservation of the health of their surrounding structures**.**

In removable partial dentures, occlusal stresses can be transmitted directly to the abutment teeth and other supporting structures because of the attachment of the removable partial denture to the abutment teeth.

Failure to provide and maintain adequate occlusion on the removable partial denture is primarily a result of:

1. Lack of support for the denture base,
2. The fallacy of establishing occlusion to a single static jaw relation record.
3. An unacceptable occlusal plane.

In establishing occlusion on a removable partial denture, the influence of the remaining natural teeth is usually such that the occlusal forms of the teeth on the removable partial denture must be made to conform to an already established occlusal pattern. Occlusal adjustment or restoration may have altered this pattern. However, the pattern present at the time the removable partial denture is made dictates the occlusion on the removable partial denture.

In order to successfully build an artificial occlusion that will fulfil the needs of the patient, the needs must be determined during the diagnostic phase of treatment.

Objective in RPD occlusion is harmony between natural and artificial dentition. Stable RPD will cause fewer undesirable changes in its supporting structures. Occlusion is one of the most important factors in developing a stable RPD.

The establishment of satisfactory occlusion for RPD should include:-

1. Analysis of the existing occlusion.

2. Correction of the existing occlusal disharmony.
3. Recording of centric relation or an adjusted centric occlusion.
4. Harmonizing of eccentric jaw movements for a functional eccentric occlusion.
5. Correction of occlusal discrepancies created by the fit of the framework and during processing of the removable partial denture.

Desirable occlusal contact relationships for various RPD:

The following occlusal arrangements are recommended to develop a harmonious occlusal relationship among removable partial dentures and to enhance stability of the removable partial dentures:

1. Simultaneous bilateral contacts of opposing posterior teeth must occur in centric occlusion.
2. Occlusion for tooth-supported removable partial dentures may be arranged similar to the occlusion seen in a harmonious natural dentition, since stability of such removable partial dentures results from the effect of the direct retainers at both ends of the denture base
3. Bilateral balanced occlusion in eccentric positions should be formulated when a maxillary complete denture opposes the removable partial denture. This is accomplished primarily to promote the stability of the complete denture. However, simultaneous contacts in a protrusive relationship do not receive priority over appearance, phonetics, and/or a favorable occlusal plane.
4. Working side contacts should be obtained for the mandibular distal extension denture. These contacts should occur simultaneously with working side contacts of the natural teeth to distribute the stress over the greatest possible area. Masticatory function of the denture is improved by such an arrangement.
5. Simultaneous working and balancing contacts should be formulated for the maxillary bilateral distal extension removable partial denture whenever possible. Such an arrangement will compensate in part for the unfavorable position the maxillary artificial teeth must occupy in relation to the residual ridge, which is usually lateral to the crest of the ridge. Working side contacts can be obtained without resorting to excessively steep cuspal

inclinations.

6. Only working contacts need to be formulated for either the maxillary or mandibular unilateral distal extension removable partial denture. Balancing side contacts would not enhance the stability of the denture because it is entirely tooth supported by the framework on the balancing side.
7. In the Kennedy Class IV removable partial denture configuration, contact of opposing anterior teeth in the planned intercuspal position is desired to prevent a continuous eruption of the opposing natural incisors, unless they are otherwise prevented from extrusion by means of a lingual plate, auxiliary bar, or by splinting. Contact of the opposing anterior teeth in eccentric positions can be developed to enhance incisive function but should be arranged to permit balanced occlusion without excursive interferences.
8. Balanced contact of opposing posterior teeth in a straightforward protrusive relationship and functional excursive positions is desired only when an opposing complete denture or bilateral distal extension maxillary removable partial denture is placed.
9. Artificial posterior teeth should not be arranged farther distally than the beginning of a sharp upward incline of the mandibular residual ridge or over the retromolar pad. To do so would have the effect of shunting the denture anteriorly.

   A harmonious relationship of opposing occlusal and incisal surfaces alone is not adequate to ensure stability of distal extension removable partial dentures. In addition, the relationship of the teeth to the residual ridges must be considered.

   Bilateral eccentric contact of the mandibular distal extension removable partial denture need not be formulated to stabilize the denture. The buccal cusps, however, must be favorably placed to direct stress toward the buccal shelf, which is the primary support area in the mandibular arch. In such positions the denture is not subjected to excessive tilting forces.

Occlusion in RPD's (Requirements):

1. Whatever is the treatment of choice, it must be capable of function within the pattern of the patient's own functional requirements.

2. The combined occlusal patterns of natural and artificial teeth must be adjusted to function harmonically with other parts of the masticatory system.
3. When posterior teeth of one jaw are brought into contact with their antagonists in centric occlusion, they should touch simultaneously with no deflective occlusal contacts,
4. Opposing, contacting teeth should glide freely and without cuspal interference throughout the functional range of occlusal movement.
5. Attempts to create artificial occlusal surfaces should be preceded by the elimination of any occlusal discrepancies in the natural teeth.
6. Artificial posterior teeth should be smaller bucco-lingualy than the natural teeth which they replace.
7. Artificial teeth should be arranged so the tongue will not be inhibited nor will the shape of the palatal vault be substantially altered.
8. The horizontal jaw position to which the RPD's will be constructed-centric relation or centric occlusion, when these factors do not coincide in the remaining natural teeth – is an important decision which must be made prior to the construction of the restorations.

Methods for establishing occlusal relationship

a) Direct apposition of cast.
b) Interocclusal records with posterior teeth remaining.
c) Occlusal relations using occlusion rims on record base.
d) Jaw relations records made entirely on occlusion rims.
e) Establishing occlusion by the recording of occlusal pathways.

Five methods of establishing occlusal relationships for RPDs, vary from simple apposition of opposing casts by occluding sufficient remaining natural teeth to the recording of jaw relations (vertical and horizontal) in the same manner as for completely edentulous patient. It is necessary that the use of face-bow for mounting of maxillary cast in relation to the condylar axis of articulating instrument are acceptable for a RPD when needed.

The horizontal jaw relation (planned intercuspal position or centric relation) in which the restoration is to be fabricated should have been determined during diagnosis and treatment planning.

Recording Jaw Relationships for RPD

For the purpose of jaw relationships and their registration partially dentate patients can be divided into two categories:-

1. Patients without an occlusal stop to indicate the correct intercuspal position or vertical dimension of occlusion.
2. Patients with occlusal contact in the intercuspal position.

A. Direct apposition of casts

The first method is used when sufficient opposing teeth remain in contact to make the existing jaw relationship obvious, or when only a few teeth are to be replaced on short denture bases and no evidence of occlusal abnormalities is found. With this method, opposing casts may be occluded by hand. The occluded casts should be held in apposition with rigid supports attached with sticky wax to the bases of the casts until they are securely mounted in the articulator.



B. Interocclusal records with posterior teeth remaining

A second method, which is a modification of the first, is used when sufficient natural teeth remain to support the removable partial denture (Kennedy Class III or IV) but the relation of opposing natural teeth does not permit the occluding of casts by hand. In such situations, jaw relations must be established as for fixed restorations with some type of interocclusal record.

The least accurate of these methods is the interocclusal wax record. The bulk, consistency, and accuracy of the wax will influence the successful recording of centric relation. Therefore a definite procedure for making interocclusal wax records is given as follows:

A uniformly softened, metal-reinforced wafer of baseplate or set-up wax is placed between the teeth, and the patient is guided to close in centric relation. The wax then is removed and immediately chilled thoroughly in room-temperature water. It should be replaced a second time to correct the distortion that results from chilling and then again chilled after removal.

Any excess wax is removed, in these cases a contact between upper and lower natural teeth occurs at acceptable vertical dimension.

A wax record can be further corrected with a freely flowing occlusal registration material, such as a metallic oxide paste, which is used as the final recording medium. The occlusal registration material then is mixed and applied to both sides of the metal-reinforced wax record. It is quickly placed, and the patient is assisted to close into centric relation, which will be guided by the previous wax record. After the occlusal registration material has set, the corrected wax record is removed and inspected for accuracy. Some of the advantages of using a metallic oxide paste over wax as a recording medium for occlusal records include:

1. Uniformity of consistency.
2. Ease of displacement on closure.
3. Accuracy of occlusal surface reproduction.
4. Dimensional stability.
5. The possibility of some modification in occlusal relationship after closure, if it is made before the material sets.
6. Reduced likelihood of distortion during mounting procedures.

C. **Occlusal relations using occlusion rims on record base:**

Indications:-

1. When one or more distal extension areas are present.
2. When a tooth- supported edentulous space is large.
3. When opposing teeth do not meet.

In these instances occlusion rims on accurate bases are used where the occlusal surface of a rim opposes standing teeth, a layer of modelling wax approximately 2mm depth is added to occlusal surface of the rim, and the wax is thoroughly softened by using a hot wax knife. The rim is seated in the mouth and the mandible guided carefully into closure until maximal intercuspal contact for natural teeth occurs.



D. Jaw relation records made entirely on occlusion rims

Indications:-

1. When an opposing maxillary complete denture is to be made concurrently with a mandibular removable partial denture.
2. Used in those rare situation in which the few remaining teeth do not occlude and will not influence eccentric jaw movements.
3. When either arch has only anterior teeth present.

In any of these situations, jaw relation records are made entirely on occlusion rims. The occlusion rims must be supported by accurate jaw relation record bases. Here, the choice of method for recording jaw relations is much the same as that for complete dentures. Either some direct inter- occlusal method or a stylus tracing may be used. As with complete denture fabrication, the use of a face bow, the choice of articulator, the choice of method for recording jaw relations, and the use of eccentric positional records are optional, based on the training, ability, and desires of the individual dentist.

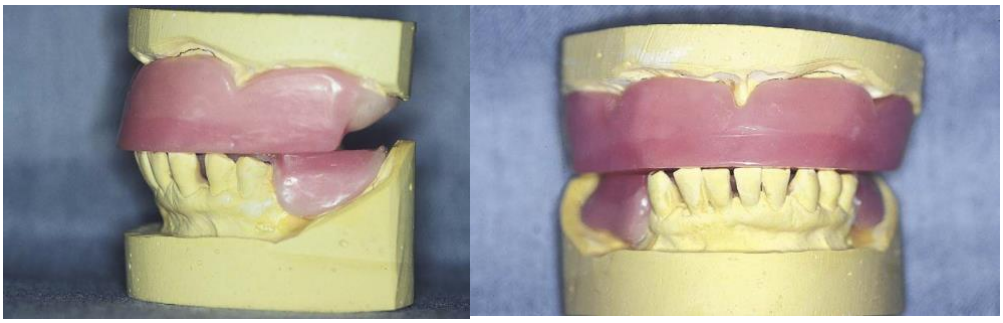

Summary of desirable contacts relationship for various RPD

Arch to Be Treated with RPD	Opposing Arch Occlusion	Recommendation (Default)
Kennedy Class I (bilateral distal extension) or Class II (unilateral distal extension)	Complete denture	Full (working, non-working, protrusive) balanced occlusion
Kennedy Class I	Kennedy Class I RPD	Working, non-working balanced occlusion
Mandibular Kennedy Class I or II	Natural or restored dentition	Working balanced occlusion
Maxillary Kennedy Class I	Natural or restored dentition	Working, non-working balanced occlusion
Maxillary Kennedy Class II	Natural or restored dentition	Working balanced occlusion
Kennedy Class III (tooth borne)	Complete denture	Full balanced occlusion
Kennedy Class III	Natural or restored dentition	Anterior/canine guidance
Kennedy Class IV	Complete denture	Full balanced occlusion
Kennedy Class IV (short span)	Natural or restored dentition	Anterior/canine guidance
Kennedy Class IV (long span)	Natural or restored dentition	Protrusive balanced occlusion or full balanced occlusion

E. Establishing Occlusion by the Recording of Occlusal Pathways

The fifth method of establishing occlusion on the removable partial denture is the registration of occlusal path- ways and the use of an occluding template rather than a cast of the opposing arch. When a static jaw relation record is used, with or without eccentric articulatory movements ,the prosthetically supplied teeth are arranged to occlude according to a specific concept of occlusion. On the other hand, when a functional occlusal record is used, the teeth are modified to accept every recorded eccentric jaw movement. These movements are made more complicated by the influence of the remaining natural teeth. In the partially edentulous arch in which RPD is to be fabricated, a hard inlay wax is placed over the stable denture base and patient is asked to carry out all extremes of mandibular movement. Inform the patient that the occlusion rim must be worn for 24 hours or longer. It should be worn constantly, including at nighttime, except for removal during meals. With wearing and biting into a hard wax occlusion rim, a record is made of all extremes of jaw movement.

<u>Advantages of functionally generated pathways</u>

1. Harmonious occlusion.
2. No recording of complex mandibular movement required.
3. Recovery of lost vertical dimension of occlusion.
4. Errors in occlusion are minimized.
5. Eliminate the need of complex articulator (simple hinge articulator is enough).

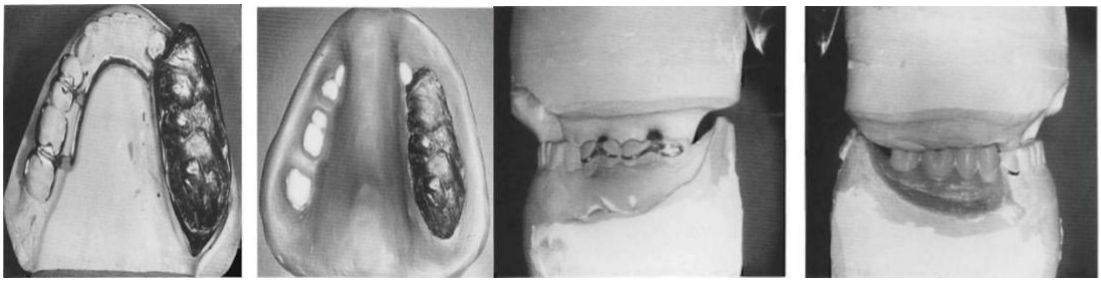

(Functional pathways and uses occluding template rather than a cast of opposing arch for teeth arrangement).

<u>Interocclusal records</u>

An interocclusal record or occlusal registration is usually necessary to orient the maxillary and mandibular diagnostic or master casts to each other properly.

Three widely separated tripod points of occlusal contact are necessary to relate the two casts accurately. These contact points may be tooth-to-tooth or tooth-to-interocclusal recording material. A stable orientation of the opposing casts may exist if sufficient teeth remain, and in these patients no interocclusal relation recording is necessary. It is suggested, however, that orientation lines be drawn on the casts to guarantee proper cast alignment in the future. An interocclusal recording will be necessary if insufficient teeth remain to allow a stable cast-to-cast relationship. Some mention must be made of the ridge on which the record bases are formed. If the prosthesis is to be tooth supported or if a distal extension base is to be made on the anatomic ridge form, the bases will be made to fit that form of the residual ridge. But if a distal extension base is to be supported by the functional form of the residual ridge, it is necessary that the recording of jaw relations be deferred until the master cast has been corrected to that functional form.

When a recording is necessary, a record base, occlusion rim, and occlusal recording material are needed to make the recording accurately. It has been suggested that the record base be fabricated using auto-polymerizing acrylic resin, although they often are fabricated of light polymerized resin. The record base must be made on the cast to be attached to the articulator. The occlusion rims most often are made using hard baseplate wax.

Excellent occlusal recording materials include:

1- zinc oxide eugenol impression material,
2- plaster impression material,
3- modeling compound,
4- polyether,
5- Polyvinyl siloxane.
6- Wax records made in edentulous areas with or without the support of record bases may not be sufficiently stable to be acceptable.

The interocclusal recording is most often made after fabrication of the removable partial denture framework. Following the fitting of the framework and the making of a corrected cast impression (if indicated), the record base is fabricated on the edentulous areas of the

framework/master cast. Occlusion rims are added, and an occlusal recording material is used to make the record. The cast is oriented to the opposing cast with the recording, and desired denture teeth are selected. This fabrication is followed by a trial insertion appointment.

Try-in of removable partial denture

(This may be at the fourth visit or according to clinical requirements).

This is the last stage at which modifications can be made before the wax is replaced by acrylic. A careful routine must be followed to prevent any mistakes continuing through to the finished dentures. The replacement of anterior teeth often represents an important event in the life of an individual.

Although many patients identify improved function as the primary reason for seeking treatment, a sense of esthetics always remains. A patient may be dissatisfied with a prosthesis even if it meets all functional and biologic requirements. Therefore, if anterior teeth are to be replaced, an esthetic try-in is essential. A try-in appointment allows the patient to view the prosthesis and provide feedback. This appointment also allows the practitioner to evaluate the esthetic and phonetic characteristics of the prosthesis and to make appropriate changes in the arrangement of teeth.

An additional indication for the appointment is to verify the accuracy of jaw relation records made during the previous appointment. If there is any doubt regarding the accuracy of the articulator mounting, a try-in appointment should be scheduled.

The trial dentures should firstly be examined on the mounted casts in respect of:-

1. Adaptation of partial dentures on the casts.
2. Occlusion.
3. Position of artificial teeth with regard to adjacent natural ones.
4. The arrangement of anterior teeth.
5. Extension and contouring of wax flanges.

In the mouth the trial dentures should be examined in respect of:-

1. Adaptation of the dentures. Comfort, and function of the appliance.
2. Vertical dimension including the vertical dimension of occlusion and rest.
3. Occlusion, check centric jaw relation and centric occlusion. Prove the centric record and take new occlusal registration.
4. Evaluate the shade, mold, and arrangement of the teeth. (Esthetic and phonetic).
5. Appearance. Modify positions of teeth and incisal edges of anterior teeth to achieve a pleasing result.

6. Ask for patient's comments on appearance. Show the patient the dentures in the mirror and ensure that they are satisfied.
7. Note any changes on the laboratory prescription.

Esthetic try-in

The patient should be seated in a treatment room that provides a quiet, relaxed atmosphere. This helps to alleviate the tension that may develop as the patient views the tooth arrangement for the first time.

The dentist should evaluate the positions of anterior teeth and assess lip support. There is a tendency to position the artificial teeth lingual to the positions occupied by the natural teeth. If anterior teeth have been missing for 6 months or more, the patient may report a sensation of abnormal fullness at the upper lip. A short period of accommodation usually will eliminate this problem.

A. Teeth length:

Tooth length should be carefully evaluated. If all anterior teeth are being replaced and the upper lip is of normal length, the edges of the central incisors should be visible when the lip is relaxed. When the lip is drawn upward (e.g., in an exaggerated smile), the gingival contours of the denture base should be minimally evident.

B. Short space:

If an anterior edentulous space has been decreased by drifting of the teeth, a decreased number of teeth should not be placed. This technique usually results in an abnormal appearance. Instead, attempts should be made to rotate or overlap the denture teeth in order to achieve an acceptable esthetic result.

C. Large space:

If the anterior edentulous space is relatively large, diastemata may be incorporated into the tooth arrangement. If this is to be accomplished, the patient should be informed of potential difficulties associated with interdental spacing. Spacing complicates oral hygiene procedures, increases the likelihood of food impaction, and may create difficulties with phonetics.

D. Overlap of the anterior teeth:

Attention should be paid to the horizontal and vertical overlap of the anterior teeth. If some natural anterior teeth remain, the overlap should be duplicated. If no natural teeth remain, care should be taken to avoid excessive vertical overlap without accompanying horizontal overlap. This

could result in the application of undesirable forces to the artificial teeth and associated soft tissues.

E**.** Vertical alignment of the teeth:

Vertical alignment of the teeth also should be evaluated. A slight deviation from the vertical can produce an acceptable esthetic result, but a significant deviation can create esthetic difficulties. The practitioner should pay particular attention to the maxillary midline. This midline must be examined for its vertical alignment and for its midface position. Any error in the position of the maxillary midline can be extremely distracting.

F. Tooth shade:

Verification of tooth shade should be accomplished during the evaluation process. The presence of natural teeth makes shade selection and patient acceptance a critical component of removable partial denture therapy. To ensure selection of an appropriate shade, the prosthesis should be viewed using a variety of light sources (e.g., natural, fluorescent, and incandescent).

Tooth position: The positioning of any posterior is compare with the position of the remaining natural teeth.



The arrangement of the anterior should be harmonize with the abutment. The appearance may need to be modified, if incisal wear is present on the natural teeth it should be simulated on the denture.

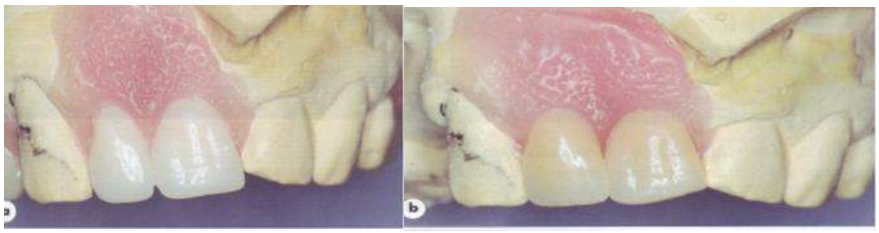

The shade, mould and arrangement of the artificial teeth should harmonize with the natural teeth. The incisal edges of the natural anterior

teeth tend to follow the curve formed by the lower lip when smiling. Reproduction of this relationship when positioning artificial anterior teeth can contribute significantly to a pleasing appearance.

(The incisal edges of the natural anterior teeth tend to follow the curve formed by the lower lip when smiling).



Denture base consideration

A. Wax flanges should be of a thickness and extension corresponding to the amount of bone resorption in the area so that they only replace the tissue that has been lost, restoring the former contour of the alveolar ridge. Mesial and distal borders should be thin so that the flange blends with the adjacent mucosa, thus avoiding food trapping and promoting patient comfort.

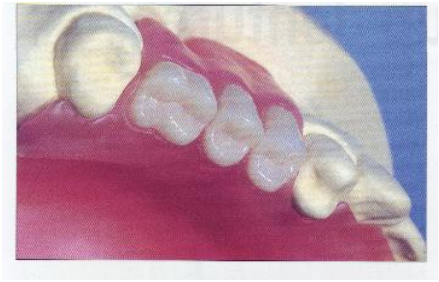

B. If the path of insertion and withdrawal permits, the lateral borders of any anterior flange should be thinned and should terminate over the convexities produced by the roots of the abutment teeth. This arrangement should also permit the labial flange to restore the papilla of the abutment tooth next to the edentulous space. The positioning and contour of papillae and gingival margins around the artificial teeth should harmonise with those of the adjacent natural teeth.



C. A common error, which creates a poor appearance, is to place the gum margin of the artificial maxillary premolars at a lower level than that of the adjacent natural teeth . This may be overcome by careful waxing up and by the selection of an artificial tooth of appropriate crown length .

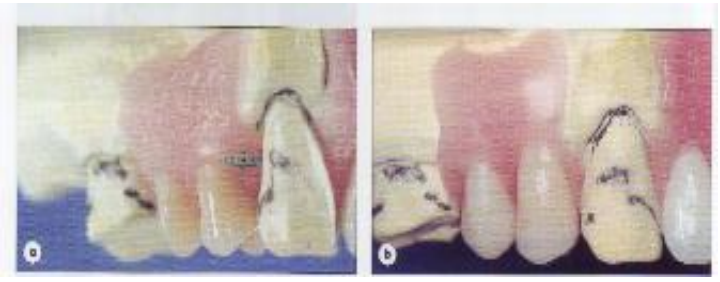

D. The borders of mucosa, or partially mucosa-supported saddles, should extend to the full depth of the sulci recorded on the cast. This is so that the occlusal forces may be distributed as widely as possible and so that the adjacent musculature may be utilized to reinforce the retention and stability of the prosthesis.



E. If the chosen path of insertion and withdrawal for the denture does not eliminate undercuts on the labial or buccal sides of the ridge, the flanges should be thinned as they pass over the survey line and end approximately 1mm beyond it.

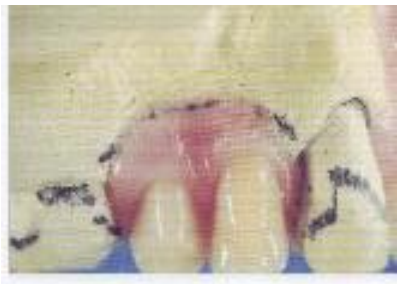

The patient evaluation

The patient should stand several feet from a wall mirror to examine the teeth critically. The use of a hand mirror should be discouraged because the patient's attention will be focused on individual teeth and not on the

overall effect of the prosthesis. The patient's remarks should be noted, and required changes should be made. Arrival at mutual acceptance by the patient and dentist frequently demands a high level of communicative skill combined with psychological insight.

Phonetics evaluation

As fricative (" f " and " v ") sounds are made by the patient, the maxillary incisors touch the wet - dry line of the lower lip. As the patient makes the " s " sound, the maxillary and mandibular incisors should just miss contact (less than 1 mm is ideal). However, in some instances, patients are able to provide the proper air escape at slightly greater distances. These patients are generally skeletal Class II patients.

(Maxillary incisors contact wet - dry line of lower lip when making the " f " sound).

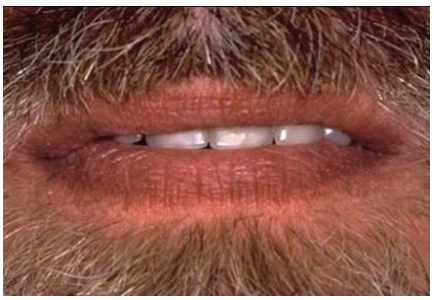

(In making the " s " sound, the maxillary and mandibular incisors are out of direct incisal contact, with generally less than 1 mm of space between incisal edges).

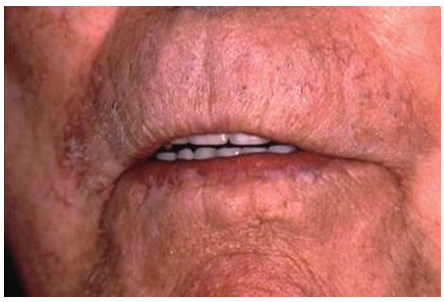

Verification of Jaw Relation

The jaw relation only needs to be verified in limited instances:

1. If problems were encountered during jaw relation procedures and there is any doubt regarding the accuracy of the articulator mounting.
2. If the partial denture is opposed by a complete denture.
3. If all posterior teeth in both arches are being replaced.
4. If there are no opposing natural teeth in contact and verification of the occlusal vertical dimension is necessary.

A dentist should never complete a prosthesis without confidence in the accuracy of the jaw relation records and the articulator mounting. A considerable amount of unnecessary work can be avoided if the `practitioner pays close attention to detail throughout these procedures. To ensure accuracy, it is essential that the practitioner evaluate the mounting using additional jaw relation records . As a result, the importance of a face-bow transfer becomes particularly evident at this stage of treatment. For a mounting to accept additional jaw relation records, the arc of rotation for the articulator must be the same as the arc of rotation for the patient's mandible.

Making a polyvinylsiloxane verification record

The patient is instructed to open the mouth moderately. The fingers of one hand are positioned to permit visualization of the dental arches . The polyvinylsiloxane registration material is mixed and introduced into the patient's mouth . The operator's remaining hand is then positioned on the facial surfaces of the mandibular anterior teeth, and the patient is guided into the prescribed closure . This position is maintained until the polyvinylsiloxane material has reached a suitable consistency.

When the recording medium has set, the patient is instructed to open the mouth. The record and removable partial denture (or dentures) are removed from the oral cavity. The record is carefully examined to determine its acceptability. There should be no signs of penetration through the record. If the record is acceptable, it is properly trimmed using a surgical scalpel.



Polyvinylsiloxane is expressed onto the mandibular occlusal surfaces.



The operator's dominant hand is properly positioned and used to guide mandibular closure.



The record is trimmed using a surgical scalpel.

Choice of tooth materials

Acrylic resin pontics are the teeth of choice for most patients. Current cross - linked polymers resist abrasion and are compatible with opposing occlusal surfaces of enamel or metal. However, if the RPD pontics oppose porcelain restorations, consideration should be given to more wear - resistant materials such as metal occlusal surfaces or porcelain denture teeth. Since porcelain teeth are attached to the denture base by mechanical retention, they require additional interocclusal space when compared to acrylic resin denture teeth, which have the ability to bond to the denture base. Some patients also report unnatural sounds — for example, "clacking" — when porcelain denture teeth oppose each other. Other, recommend that custom glass ceramic occlusal surfaces be fabricated and cemented to prepared acrylic resin denture teeth in order to reduce the wear caused by opposing ceramic occlusal surfaces.

Horizontal jaw relationship

seineen salam ١١ lec

❖ **The correct horizontal relationship for fabricating complete dentures is always the centric relation position.**

- **Centric occlusion**: The occlusion of the opposing teeth when the mandible is in centric relation.
- **Centric relation**: The maxillomandibular relationship in which the condyles articulate with the thinnest a vascular portion of their respective disks with the complex in the anterior-superior position against the shapes of the articular eminencies.
- It is restricted to a purely rotary movement about the transverse horizontal axis.

Centric relation is located by detecting the only retruded position of the mandible to the maxilla in which a clinician can obtain a purely vertical hinge movement of the mandible in relation to the maxilla.

❖ **The clinician must be able to manipulate the patient's mandible to the centric relation position, as it is:**

1) the starting reference point for complete denture fabrication,

repeatable and it can be verified, and is a functional position for denture occlusion.

2) Complete dentures should always be fabricated so their initial and complete final occlusal position is coincident with the centric relation; this position then becomes the centric occlusion position for the patient.
3) Because the centric relation position is somewhat dependent on head posture, the head should be held fairly upright.

❖ The position of the dentist's hands

- The position of the dentist's hands is an important factor in making accurate centric relation records and maintaining record bases in their correct position.
- The non-dominant hand is inverted and placed in the mouth so that the soft tissue of the thumb and index fingers lies on the opposing buccal surfaces of the maxillary and mandibular occlusion rims, between the occlusal surfaces in the first molar region.



- The other hand is used to help guide the patient to centric relation position. Care should be exercised to avoid displacing the mandibular record base in the posterior direction.
- Because it is sometimes difficult to get the patient into the CR position, it is a good idea to practice this position with the patient prior to attempting to make the recording.
- Therefore, the patient should be close to the correct OVD prior to attempting to achieve the CR position.
- It is advisable to instruct the patient to "let your jaw relax, close slowly

❖ Methods must be used to position the jaw in centric relation.

1. Having the patient completely relax the mandible while the clinician gently shakes the mandible up and down.

2. Placing the tip of the tongue in the top and back of the mouth.

3. Telling the patient to ".Stick out the upper teeth."

4. Tipping the chair and patient back to allow gravity to help position the mandible.

5. Using a mirror so that the patient can see the CR mandible position.

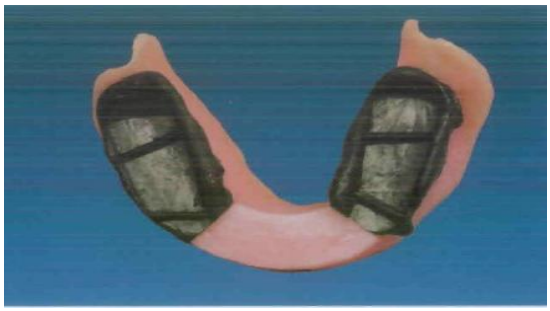

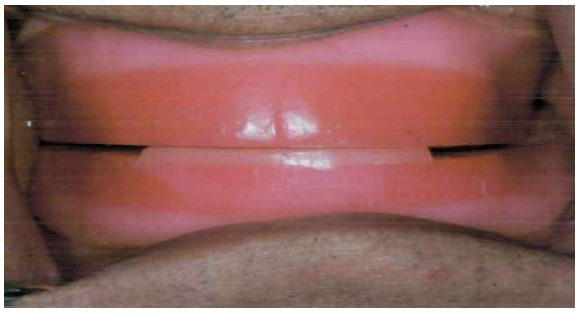

- The maxillary master cast has now been properly placed on the articulator using a face-bow recording.
- The mandibular occlusion rim has been adjusted so that there is unrestricted contact with the maxillary occlusion rim at the correct occluding vertical dimension, and it is in centric relation.
- This horizontal relationship will now be captured with some type of recording material.
- Because we must make the recording at the correct OVD, space must now be created to allow room for the record material**.**

Once the maxillary cast is properly positioned, the occlusion rims are placed on their respective casts, and the records are seated together. Observe the casts for possible contact in the posterior areas. If they make contact, the cast must be trimmed until there is no cast-to-cast contact.

Pre-prosthetic Surgical Considerations

Treatment methods to improve the patient's denture foundation and ridge relations are usually either nonsurgical or surgical in nature, but can be a combination of both methods.

NONSURGICAL METHODS

Nonsurgical methods of edentulous mouth preparation include the following methods;

1. Rest for the Denture-Supporting Tissues

Rest for the denture-supporting tissues can be achieved by removal of the dentures from the mouth for an extended period or the use of temporary soft liners inside the old dentures. Both procedures allow deformed tissue of the residual ridges to return to normal form. Clinical reports and experience also support the merits of regular finger or toothbrush massage of denture-bearing mucosa, especially of those areas that appear edematous and enlarged.

2. Occlusal Correction of the Old Prostheses

An attempt should first be made to restore an optimal vertical dimension of occlusion to the dentures presently worn by the patient with an interim resilient lining material. This step enables the dentist to prognosticate the amount of vertical facial support that the patient can tolerate, and it allows the presumably deformed tissues to recover.

3. Good Nutrition

A good nutritional program must be emphasized for each edentulous patient. This program is especially important for the geriatric patient whose metabolic and masticatory efficiency may be compromise.

SURGICAL METHODS

Frequently, certain conditions of the denture bearing tissues require edentulous patients to be treated surgically. These conditions are the result of unfavorable morphological variation the denture bearing area or, more commonly, result from long term wear of ill-fitting dentures. It is often far easier to make alterations in the prosthetic techniques and materials used than to subject the patient to a surgical intervention. The key consideration is whether a good prosthodontic prognosis will result from the surgical outcome.

Surgical Guides (Templates)

When moderate amounts of bone recontouring are required and the treatment plan requires a degree of precision in the amount and location of bone to be removed, surgical guides are excellent adjuncts. Using a duplicated diagnostic cast, the areas of concern are modified to achieve the ideal ridge form. A clear rigid guide is then fabricated using a vacuum-formed technique. During the surgical procedure, after recontouring has been accomplished, the surgical guide is placed over the area with the flap repositioned, and areas of soft tissue blanching are observed. These blanching areas represent areas where additional removal of bone and recontouring are still required. This procedure is repeated until no blanching exists and the surgical guide is stable when seated. Soft tissue trimming, if necessary, can now be done.

Commonly Used Preprosthetic Procedures

1. Ridge alveoloplasty with or without extractions for recontouring of the knife edged ridge or other ridge deformity or contour problems.
2. Intraseptal alveoloplasty.
3. Maxillary tuberosity reduction.
4. Recontouring of palatal and lateral exostosis and contour problems these include: mandibular tori removal; maxillary tori removal; mylohyoid ridge reduction; and genial tubercle reduction.
5. Soft tissue procedures might include maxillary tuberosity soft tissue reduction, maxillary labial frenectomy, mandibular lingual frenectomy, and excision of redundant tissue.

Ridge Alveoloplasty with Extraction

After extraction of a tooth or teeth, the clinician must make a determination about the appropriateness of the remaining ridge contour to fit into the preprosthetic plan, and if the recontouring will be made at the time of the extraction or at a later time. If more than finger compression is needed, a full thickness flap should be elevated to a point apical to the area in need of recontouring . Depending on the amount of recontouring needed, a bone file may be sufficient to produce the desired contours. For greater recontouring, a side cutting rongeur or handpiece and acrylic resin bur can be used, when using these burs, always use copious irrigation to avoid overheating the bone and subsequent bony necrosis. Irrigation also cleans the flutes of the bur and carries away debris. After bulk recontouring, a bone file is used to "fine tune" the recontoured bone.



Intraseptal Alveoloplasty

When the ridge has acceptable contour and height but presents an unacceptable undercut, which extends to the base of the labial vestibule, the intraseptal alveoloplasty might be considered. This procedure is best accomplished at the time of extraction or early in the postoperative healing period. After extraction of the teeth, the crestal tissue is slightly elevated to fully expose the extraction sockets. Using a small rongeur or handpiece and bur, the intraseptal bone is removed to the depth of the socket. After adequate removal

of bone, finger pressure is applied in a constant, controlled manner until the labiocortical plate is greenstick fractured **(**a greenstick fracture is a partial thickness fracture where only cortex and periosteum are interrupted on one side of the bone but remain uninterrupted on the other**)** and can be positioned palatally, narrowing the crest and eliminating the undercut. A bone file can be used to smooth roughened edges, and the site can be irrigated. The crestal soft tissue can now be approximated and closed with interrupted or continuous sutures. Ideally, a surgical stent or soft-tissue-lined immediate denture can be inserted to maintain the repositioned bony segment until the initial stages of healing have taken place, at about two weeks after the procedure.

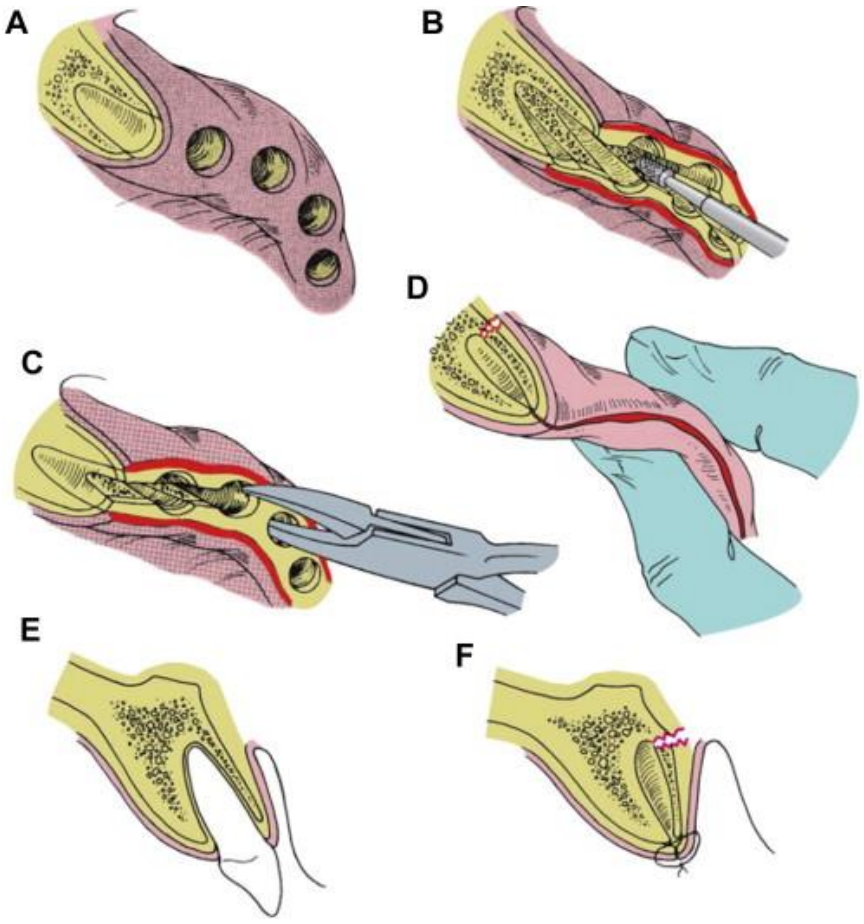

Edentulous Ridge Alveoloplasty

For routine elimination of sharp (knife-edged) ridges and removal of undesirable contours, undercuts, or prominences, direct vision and frequent palpation until the desired endpoint is reached will be sufficient. When the mandibular or maxillary edentulous ridges require multifocal, moderate, or greater amounts of recontouring, use of diagnostic casts to identify areas of concern, and fabrication of surgical guides, are recommended. In this way, the clinician has a model with the specific areas outlined to assist in the exact orientation once tissues are reflected and if necessary, a surgical guide to assist with the detailed removal and recontouring of the bone. The edentulous ridge alveoloplasty begins with identification of the areas of concern. A full thickness flap is designed and implemented to fully expose the targeted areas. Using bone files/rasps, rongeurs handpiece, and burs or combinations, the targeted areas are recontoured. Digital palpation with the flap in place is done until the desired endpoint is achieved. The site is irrigated and close primarily with an interrupted or continuous suture technique.

Buccal Exostosis

This approach can be used on either arch and for irregularities on the palatal aspect of the maxillary alveolus. A crestal incision is made to extend beyond the margins of the areas requiring recontouring. A full thickness flap is elevated to completely expose the involved area. When an envelope flap will not provide the necessary exposure without placing tension on the flap, a releasing incision, as described earlier, may be incorporated into the flap design. For gaining access to a palatal exostosis, make the incision longer and reflect more tissue to gain enough relaxation in the flap. Because of the greater palatine and incisive branch anastomosis, vertical releases in the palate area not recommended. Once the irregularity is exposed, the tissue is elevated and protected, and the appropriate instrument is used to recontour the bone to the desired endpoint. The area is palpated through the flap to confirm adequate

reduction or recontouring. When completed, the area is irrigated and closed.

Maxillary Tuberosity Reductions

Maxillary hyperplasic tuberosities present real problems for gaining appropriate interarch distance posteriorly. The tuberosities can be hyperplasic in the horizontal or vertical planes, and may involve osseous hyperplasia, soft tissue hyperplasia, or both. To identify the hard tissue and soft tissue component that requires recontouring, a panoramic radiograph will usually suffice. This will provide information about the hard and soft tissue contributions and the overall contour of the tuberosity and proximity to the maxillary sinus. It is important to remember that maxillary sinuses may pneumatize into the tuberosity areas. A crestal incision is made from a point anterior to where the recontouring will start, over and up behind the tuberosity. Tissue must be elevated on both the buccal and palatal aspects to fully expose the tuberosity. After making sure that all soft tissue is protected, instrumentation can start. The tuberosity can be recontoured with bone file, rongeur, or bur if a great deal of bone needs to be removed, again as in other procedures, a surgical guide may be necessary. If the maxillary sinus has pneumatized, care must be taken when removing the bone and the sinus membrane may become exposed. However, this is not a problem as long as the membrane is intact.



Mandibuiar Tori

In the dentate arch, tori pose few, if any, problems. *Occasionally tori can be large enough to interfere with tongue mobility and speech, and the thin mucosa overlying the tori may be chronically irritated or injured when eating certain foods. In the edentulous arch*, tori may pose significant interference when wearing a removable prosthesis and *often must be removed*.

After all tori have been removed and bone smoothed, the flap is repositioned and the lingual plate palpated to confirm achieving the desired contours.



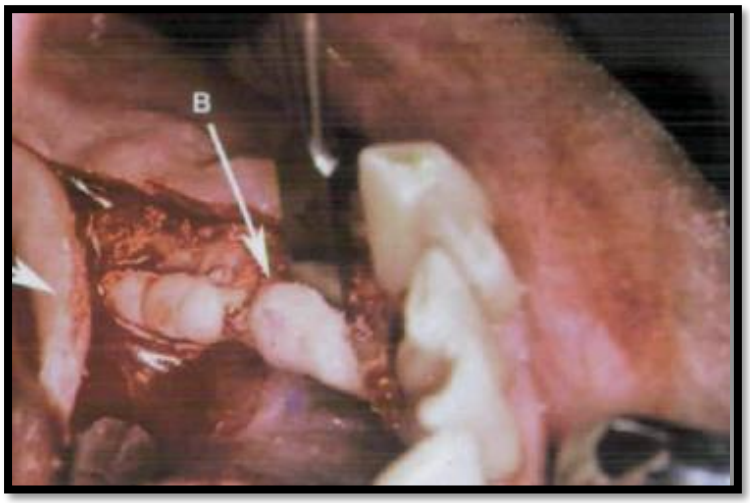

Maxillary Tori

Maxillary tori may pose a significant problem in the fabrication and wearing of a maxillary complete denture. The tori may be especially problematic when it is positioned more posteriorly, creating problems with posterior palatal seal of the prosthesis

A midline incision is placed over the torus with oblique releasing incisions at each end. When the tori are multilobulated and pedunculated, elevation of the thin mucosa may be difficult. After the torus is exposed, adequate flap control for best visualization is important. An excellent method of keeping the flaps open is to suture the margin of the flap to the crest of the ridge on the same side. For some larger pedunculated multilobulated tori, a midcrestal incision with elevation of the entire palatal mucosa is recommended. This dissection must stay subperiosteal to avoid injury to the palatal blood supply. The desirable end point is for the palatal vault to be smooth and confluent with no undercuts or elevations.

Hematoma formation in the palate under the flap is a great concern.

Excellent methods of applying pressure are with the placement of a temporary denture with soft reline material over the surgical site or with a well-fitting, surgical guide with soft reline placed over the area. The pressure should be maintained for several days. The patient can remove the appliances for local wound care and oral rinsing.

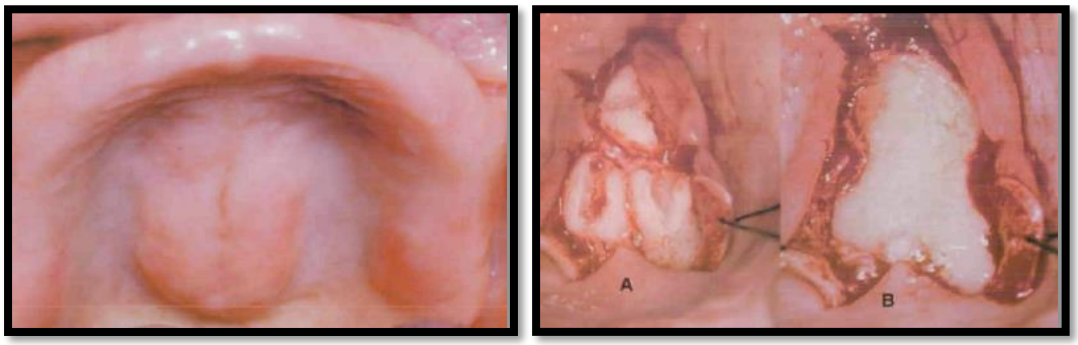



Mylohyoid Ridge Reduction

In the mandibular post-extraction ridge remodeling sequencing, the alveolar bone and external oblique ridge resorb because of lack of stressing and functional remodeling. The mylohyoid ridge, which supports the attachment of the mylohyoid muscle, remains relatively intact, and becomes a prominent feature in the posterior mandible. After providing profound anesthesia, a midcrestal incision is made anterior to the site of ridge reduction and carried posteriorly gradually deviating toward the buccal, to avoid potential injury to the lingual nerve. The flap is elevated to expose the mylohyoid ridge and attached muscle. Using sharp dissection, the tendenous attachments of the mylohyoid muscle are stripped.

When completed, the area should be copiously irrigated and closed primarily with interrupted or continuous sutures. Once the flap has been closed, ideally a denture with a soft reline is placed to allow for the lingual flange to help with *displacement* of the detached mylohyoid muscle.

Genial Tubercle Reduction

In the post-extraction ridge remodeling of the anterior mandible, the alveolar ridge and tooth-bearing areas resorb because of lack of stressing and functional loading. The superior pair of genial tubercles provides insertion for the paired genioglossus muscles, while the lower paired tubercles provide insertion for the paired geniohyoid muscles. Because of the constant movement of the tongue and stressing of the tubercles once the alveolus has

resorbed and remodeled, the genial tubercles can become very prominent structures in the anterior mandible and impede proper seating of the denture.

The clinician must be aware that this surgical site lies between two moving structures—the tongue and the lip. Therefore this is an area that may be prone to wound dehiscence. Making this a very difficult surgery. With exposure of the bone and protection of the flap, the bone height can be reduced with the instrument of choice to the desired level. The wound is copiously irrigated and closed primarily.

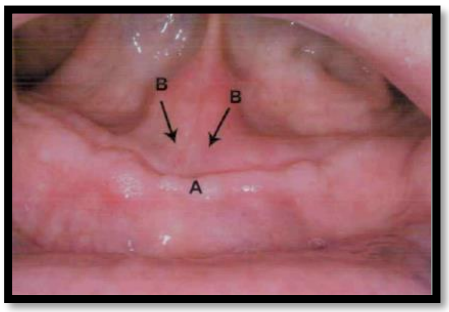

Pre-prosthetic Surgical Considerations

Treatment methods to improve the patient's denture foundation and ridge relations are usually either nonsurgical or surgical in nature, but can be a combination of both methods.

NONSURGICAL METHODS

Nonsurgical methods of edentulous mouth preparation include the following methods;

1. Rest for the Denture-Supporting Tissues

Rest for the denture-supporting tissues can be achieved by removal of the dentures from the mouth for an extended period or the use of temporary soft liners inside the old dentures. Both procedures allow deformed tissue of the residual ridges to return to normal form. Clinical reports and experience also support the merits of regular finger or toothbrush massage of denture-bearing mucosa, especially of those areas that appear edematous and enlarged.

2. Occlusal Correction of the Old Prostheses

An attempt should first be made to restore an optimal vertical dimension of occlusion to the dentures presently worn by the patient with an interim resilient lining material. This step enables the dentist to prognosticate the amount of vertical facial support that the patient can tolerate, and it allows the presumably deformed tissues to recover.

3. Good Nutrition

A good nutritional program must be emphasized for each edentulous patient. This program is especially important for the geriatric patient whose metabolic and masticatory efficiency may be compromise.

SURGICAL METHODS

Frequently, certain conditions of the denture bearing tissues require edentulous patients to be treated surgically. These conditions are the result of unfavorable morphological variation the denture bearing area or, more commonly, result from long term wear of ill-fitting dentures. It is often far easier to make alterations in the prosthetic techniques and materials used than to subject the patient to a surgical intervention. The key consideration is whether a good prosthodontic prognosis will result from the surgical outcome.

Surgical Guides (Templates)

When moderate amounts of bone recontouring are required and the treatment plan requires a degree of precision in the amount and location of bone to be removed, surgical guides are excellent adjuncts. Using a duplicated diagnostic cast, the areas of concern are modified to achieve the ideal ridge form. A clear rigid guide is then fabricated using a vacuum-formed technique. During the surgical procedure, after recontouring has been accomplished, the surgical guide is placed over the area with the flap repositioned, and areas of soft tissue blanching are observed. These blanching areas represent areas where additional removal of bone and recontouring are still required. This procedure is repeated until no blanching exists and the surgical guide is stable when seated. Soft tissue trimming, if necessary, can now be done.

Commonly Used Preprosthetic Procedures

1. Ridge alveoloplasty with or without extractions for recontouring of the knife edged ridge or other ridge deformity or contour problems.
2. Intraseptal alveoloplasty.
3. Maxillary tuberosity reduction.
4. Recontouring of palatal and lateral exostosis and contour problems these include: mandibular tori removal; maxillary tori removal; mylohyoid ridge reduction; and genial tubercle reduction.
5. Soft tissue procedures might include maxillary tuberosity soft tissue reduction, maxillary labial frenectomy, mandibular lingual frenectomy, and excision of redundant tissue.

Ridge Alveoloplasty with Extraction

After extraction of a tooth or teeth, the clinician must make a determination about the appropriateness of the remaining ridge contour to fit into the preprosthetic plan, and if the recontouring will be made at the time of the extraction or at a later time. If more than finger compression is needed, a full thickness flap should be elevated to a point apical to the area in need of recontouring . Depending on the amount of recontouring needed, a bone file may be sufficient to produce the desired contours. For greater recontouring, a side cutting rongeur or handpiece and acrylic resin bur can be used, when using these burs, always use copious irrigation to avoid overheating the bone and subsequent bony necrosis. Irrigation also cleans the flutes of the bur and carries away debris. After bulk recontouring, a bone file is used to "fine tune" the recontoured bone.



Intraseptal Alveoloplasty

When the ridge has acceptable contour and height but presents an unacceptable undercut, which extends to the base of the labial vestibule, the intraseptal alveoloplasty might be considered. This procedure is best accomplished at the time of extraction or early in the postoperative healing period. After extraction of the teeth, the crestal tissue is slightly elevated to fully expose the extraction sockets. Using a small rongeur or handpiece and bur, the intraseptal bone is removed to the depth of the socket. After adequate removal

of bone, finger pressure is applied in a constant, controlled manner until the labiocortical plate is greenstick fractured **(**a greenstick fracture is a partial thickness fracture where only cortex and periosteum are interrupted on one side of the bone but remain uninterrupted on the other**)** and can be positioned palatally, narrowing the crest and eliminating the undercut. A bone file can be used to smooth roughened edges, and the site can be irrigated. The crestal soft tissue can now be approximated and closed with interrupted or continuous sutures. Ideally, a surgical stent or soft-tissue-lined immediate denture can be inserted to maintain the repositioned bony segment until the initial stages of healing have taken place, at about two weeks after the procedure.

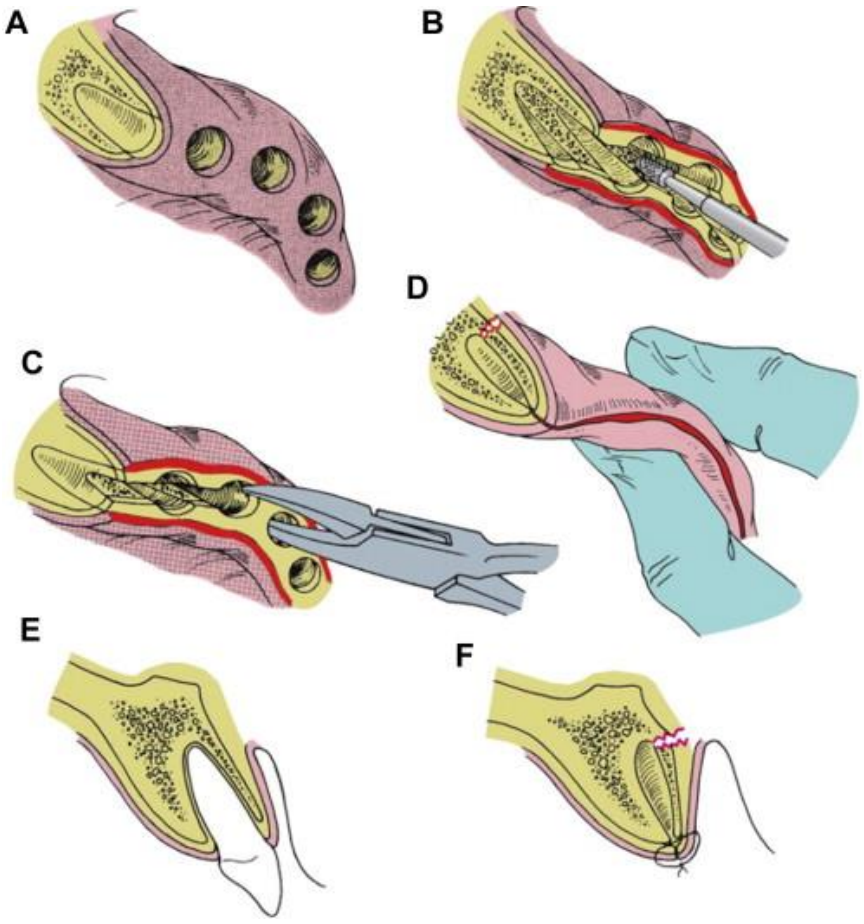

Edentulous Ridge Alveoloplasty

For routine elimination of sharp (knife-edged) ridges and removal of undesirable contours, undercuts, or prominences, direct vision and frequent palpation until the desired endpoint is reached will be sufficient. When the mandibular or maxillary edentulous ridges require multifocal, moderate, or greater amounts of recontouring, use of diagnostic casts to identify areas of concern, and fabrication of surgical guides, are recommended. In this way, the clinician has a model with the specific areas outlined to assist in the exact orientation once tissues are reflected and if necessary, a surgical guide to assist with the detailed removal and recontouring of the bone. The edentulous ridge alveoloplasty begins with identification of the areas of concern. A full thickness flap is designed and implemented to fully expose the targeted areas. Using bone files/rasps, rongeurs handpiece, and burs or combinations, the targeted areas are recontoured. Digital palpation with the flap in place is done until the desired endpoint is achieved. The site is irrigated and close primarily with an interrupted or continuous suture technique.

Buccal Exostosis

This approach can be used on either arch and for irregularities on the palatal aspect of the maxillary alveolus. A crestal incision is made to extend beyond the margins of the areas requiring recontouring. A full thickness flap is elevated to completely expose the involved area. When an envelope flap will not provide the necessary exposure without placing tension on the flap, a releasing incision, as described earlier, may be incorporated into the flap design. For gaining access to a palatal exostosis, make the incision longer and reflect more tissue to gain enough relaxation in the flap. Because of the greater palatine and incisive branch anastomosis, vertical releases in the palate area not recommended. Once the irregularity is exposed, the tissue is elevated and protected, and the appropriate instrument is used to recontour the bone to the desired endpoint. The area is palpated through the flap to confirm adequate

reduction or recontouring. When completed, the area is irrigated and closed.

Maxillary Tuberosity Reductions

Maxillary hyperplasic tuberosities present real problems for gaining appropriate interarch distance posteriorly. The tuberosities can be hyperplasic in the horizontal or vertical planes, and may involve osseous hyperplasia, soft tissue hyperplasia, or both. To identify the hard tissue and soft tissue component that requires recontouring, a panoramic radiograph will usually suffice. This will provide information about the hard and soft tissue contributions and the overall contour of the tuberosity and proximity to the maxillary sinus. It is important to remember that maxillary sinuses may pneumatize into the tuberosity areas. A crestal incision is made from a point anterior to where the recontouring will start, over and up behind the tuberosity. Tissue must be elevated on both the buccal and palatal aspects to fully expose the tuberosity. After making sure that all soft tissue is protected, instrumentation can start. The tuberosity can be recontoured with bone file, rongeur, or bur if a great deal of bone needs to be removed, again as in other procedures, a surgical guide may be necessary. If the maxillary sinus has pneumatized, care must be taken when removing the bone and the sinus membrane may become exposed. However, this is not a problem as long as the membrane is intact.



Mandibuiar Tori

In the dentate arch, tori pose few, if any, problems. *Occasionally tori can be large enough to interfere with tongue mobility and speech, and the thin mucosa overlying the tori may be chronically irritated or injured when eating certain foods. In the edentulous arch*, tori may pose significant interference when wearing a removable prosthesis and *often must be removed*.

After all tori have been removed and bone smoothed, the flap is repositioned and the lingual plate palpated to confirm achieving the desired contours.



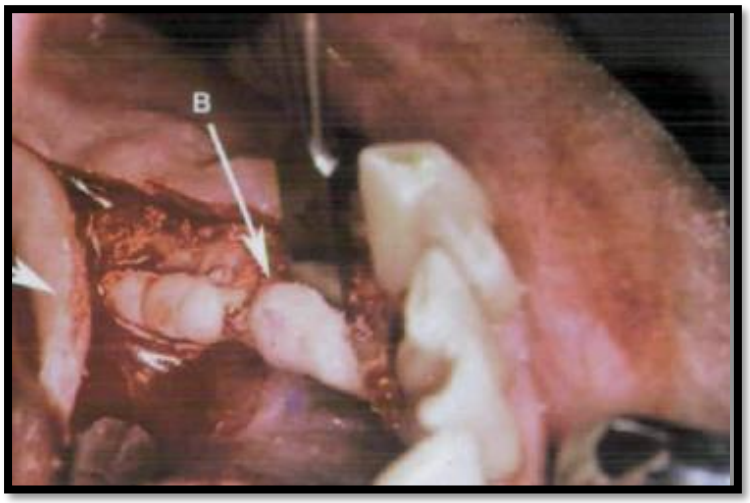

Maxillary Tori

Maxillary tori may pose a significant problem in the fabrication and wearing of a maxillary complete denture. The tori may be especially problematic when it is positioned more posteriorly, creating problems with posterior palatal seal of the prosthesis

A midline incision is placed over the torus with oblique releasing incisions at each end. When the tori are multilobulated and pedunculated, elevation of the thin mucosa may be difficult. After the torus is exposed, adequate flap control for best visualization is important. An excellent method of keeping the flaps open is to suture the margin of the flap to the crest of the ridge on the same side. For some larger pedunculated multilobulated tori, a midcrestal incision with elevation of the entire palatal mucosa is recommended. This dissection must stay subperiosteal to avoid injury to the palatal blood supply. The desirable end point is for the palatal vault to be smooth and confluent with no undercuts or elevations.

Hematoma formation in the palate under the flap is a great concern.

Excellent methods of applying pressure are with the placement of a temporary denture with soft reline material over the surgical site or with a well-fitting, surgical guide with soft reline placed over the area. The pressure should be maintained for several days. The patient can remove the appliances for local wound care and oral rinsing.

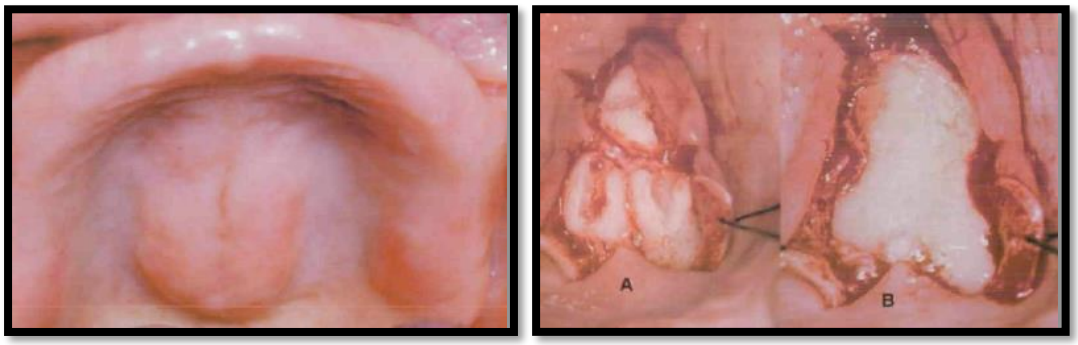



Mylohyoid Ridge Reduction

In the mandibular post-extraction ridge remodeling sequencing, the alveolar bone and external oblique ridge resorb because of lack of stressing and functional remodeling. The mylohyoid ridge, which supports the attachment of the mylohyoid muscle, remains relatively intact, and becomes a prominent feature in the posterior mandible. After providing profound anesthesia, a midcrestal incision is made anterior to the site of ridge reduction and carried posteriorly gradually deviating toward the buccal, to avoid potential injury to the lingual nerve. The flap is elevated to expose the mylohyoid ridge and attached muscle. Using sharp dissection, the tendenous attachments of the mylohyoid muscle are stripped.

When completed, the area should be copiously irrigated and closed primarily with interrupted or continuous sutures. Once the flap has been closed, ideally a denture with a soft reline is placed to allow for the lingual flange to help with *displacement* of the detached mylohyoid muscle.

Genial Tubercle Reduction

In the post-extraction ridge remodeling of the anterior mandible, the alveolar ridge and tooth-bearing areas resorb because of lack of stressing and functional loading. The superior pair of genial tubercles provides insertion for the paired genioglossus muscles, while the lower paired tubercles provide insertion for the paired geniohyoid muscles. Because of the constant movement of the tongue and stressing of the tubercles once the alveolus has

resorbed and remodeled, the genial tubercles can become very prominent structures in the anterior mandible and impede proper seating of the denture.

The clinician must be aware that this surgical site lies between two moving structures—the tongue and the lip. Therefore this is an area that may be prone to wound dehiscence. Making this a very difficult surgery. With exposure of the bone and protection of the flap, the bone height can be reduced with the instrument of choice to the desired level. The wound is copiously irrigated and closed primarily.

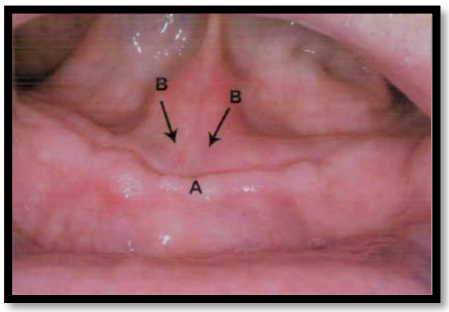

Trial denture for removable complete denture

Trail denture: a preliminary arrangement of artificial teeth that has been prepared for placement into the patient's mouth to evaluate esthetics, phonetics, and maxillomandibular relationships.

Trial base: an interim material or device representing the base of a removable denture or maxillofacial prosthesis; used for making maxillomandibular relationship records and for the waxing of the trial denture.

Trial placement: the process of placing a trial denture in the patient's mouth for evaluation.

Importance of trial denture

1. It is the last opportunity to evaluate many of the previous steps already accomplished.
2. Permits the patient to assess the appearance of the denture.
3. Identification and correction of any errors before the dentures are finished.

Objective of try-in procedure

1. To verify the maxillomandibular records which were made without teeth
    a) To check for acceptance of established vertical dimension.
    b) Verify that centric occlusion and centric relation coincide.
2. To determine the position of teeth and denture base are compatible with surrounding oral tissues.
3. To evaluate tooth selection and arrangement for esthetic requirement.
4. To make additional interocclusal maxillomandibular records if needed for further adjustment of the articulator e.g. protrusive interocclusal record.

Aspects of Try-In stage

a. Extra oral examination on articulator which include the accuracy of the cast, denture base, teeth and their relation.
b. Intra oral examination which include check the trail denture separately and together inside the patient mouth.

A- Extraoral examination of the trial dentures

The master Cast

- As the finished denture is processed on the master cast. So the master cast should be:
  a. good shape.
  b. Free from air bubbles or scratches.
  c. Free from wax debris which lead to improper adaptation of the trail denture bases leading to false relationships.
  d. If there are any undercuts present in the cast, these undercut should be relieved to avoid scratching of the cast by the trail denture bases.

The trial denture bases

- Check the following:
  1. The trial denture bases must be stable.
  2. The borders of the trial denture base should be smooth, round, and have no sharp edges.
  3. Also the border should be shaped to conform to the depth and width of the sulci.

On the articulators

- The mounted cast is checked for:
  a) Maintaining of the vertical dimension of occlusion
     1. Top of the incisal pin is flush with the upper member of the articulator.
     2. The incisal pin is in contact with the incisal table.
  b) The mounting rings are firmly screwed in their position.
  c) Moving of the articulator smoothly from centric to eccentric position without cuspal interlocking.
  d) The trial denture bases lie properly on their casts and the teeth meet evenly in centric relation.

The teeth

1. It is the dentist responsibility to select the proper shade, and shape of the teeth and determine that the teeth are set correctly.
2. Elimination of the excess wax is done to avoid the false teeth relationships or overlook the occlusion.
3. The relation of both upper and lower teeth to the opposing ridges must be checked: if there is excessive anterior tooth contact on the articulator,

should be corrected to avoid the excessive forces on the maxillary anterior ridge which causing bone destruction in that area that is already a target for bone loss.

4. Denture occlusion:

The occlusion of the teeth in on the articulator should meet the following in the class I jaw relationship:

- The upper anterior teeth overlap the lower anterior teeth by about 1-2mm, in both horizontal and vertical planes.

B-Trial denture assessment in the mouth

- The denture should be assessed individually for:
  1. Physical retention
  2. Stability
  3. Extension of denture bases
  4. Relationship to the neutral zone
- The denture should than be assessed together for:
  1. VD
  2. CR position
  3. Esthetic
  4. Phonetics
- Establishment of the posterior palatal seal.

Physical retention

If the prognosis for retention in the upper jaw is good, dislodgement should be expected to be difficult. In the case of the lower denture, retention is often poor because of the relatively small denture-bearing area and the difficulty in obtaining an efficient border seal.

It is noted that the retention of the trial denture is less than that of completed denture, due to:

a. Absence of a posterior palatal seal.
b. Poor adaptation of the trial denture base to the tissues.

The trial denture should stay in position when the mouth is opened. Looseness of the upper trial denture makes it impossible to carry out an accurate assessment of the occlusion {may use denture fixative} especially, in patients with unfavorable anatomical factors.

- Loss of retention may be include absence of a border seal resulting from:

1. Under-extension.

2. Inadequate width of flange.
3. Ineffective seal at the posterior border.
4. Poor fit of the denture base.

Stability

It is tested by applying pressure in a tissue ward direction with the ball of the index finger in the premolar and molar regions on each side alternately.

This pressure must be directed at right angles to the occlusal surface where displacement does occur.

Causes of instability

1. Warpage of the denture base.
2. Posterior teeth set buccal to the underlying alveolar ridge
3. Hard unrelieved area in the midline e.g. torus palatinus.

Extension of denture bases

The accuracy with which the denture borders conform to the depth and width of the sulci must be determined.

a. The posterior border of the upper trial denture base should extend from the hamular notch of the other along the vibrating line of the soft palate.
b. The lower denture should cover the retro molar pad to buttress the denture against the backward pressure of the lower lip.

If marked over-extension of the denture flanges is present, stretching of the sulcus tissues will occur when the denture is inserted into the mouth and their subsequent elastic recoil will cause dislodgement of the denture. Therefore, if the denture is displaced immediately after being seated, over-extension should
be suspected.

The presence of under-extension is determined primarily by intra-oral examination, when the depth of the sulcus will be seen to be greater than that of the denture flange. Correction of any under-extension will usually entail taking a new impression in the trial denture. Failure to do this will result in reduced physical retention of the finished dentures and inadequate distribution of load to the tissues.

Relationship to the neutral zone

The positioning of teeth in the neutral zone is of particular importance in the case of the lower denture because the physical retention is relatively weak. Identification of the neutral zone will have been attempted while shaping the record block at the earlier visit and now the trial denture must be checked to see if that assessment was correct and has been transferred accurately to the denture. When the lower denture is inserted, it should remain in place when the mouth is half open and the tongue is positioned so that its tip lies just behind
the lower anterior teeth.

Assessment of denture together intraorally

Vertical dimension of occlusion

The vertical dimension of occlusion and rest must be evaluated because the final position of the anterior and posterior teeth will depend on the amount of space available vertically. The factors that govern the final determination of vertical relation depends on careful consideration of the following:

1. Occlusion: compare to previous VDO at two skin points.
2. Upper/lower teeth and gingival visibility.
3. Facial profile and proportions mid/lower face.
4. Relaxed facial posture.
5. Interarch space with breathing, swallowing, speaking.
6. Patient perception of jaw position.

Correction of the occlusal vertical dimension

Occlusal vertical dimension too small

When the freeway space is too large, it is corrected by adding the appropriate thickness of wax to the occlusal surfaces of the posterior teeth on one of the dentures, adjusting the wax to produce an even occlusion at the desired occlusal vertical dimension and then re-recording the jaw relationship in the retruded contact position**.**

Occlusal vertical dimension too large

When the freeway space is too small, or absent altogether, teeth will have to be removed from one of the dentures and be replaced with a wax rim before the new recording can be made.

Evaluation of centric jaw relation

Intra Oral Observation of Intercuspation

Patient is guided into CR by a thumb placed on the anteroinferior portion of the chin and index finger bilaterally on the buccal flanges of the lower denture.
Any Error in CR will be apparent when teeth slide over each other.

Extra oral articulator method

Process:

1. Impression material (e.g. Aluwax) is placed over mandibular posterior teeth.
2. wax sealed – denture placed in mouth – just wax portion is immersed in water bath of 130oF for 30 secs – denture placed back in pts mouth - mandible guided into CR so that upper teeth makes contact with the wax – denture removed & chilled in ice water & returned back to patients mouth for re-checking.
3. CR is confirmed – Trial dentures are then locked in articulator – opposing teeth should fit in the indentation in every way (anteriorly, posteriorly, laterally & vertically) if the original CR was correct.
4. If it does not fit, mandibular cast should be separated & remounted with last occlusal record.
5. The new mounting is again checked to prove or disprove its correctness.
6. Do not remount the upper cast because the face-bow transfer will be destroyed.

Esthetic evaluation of trial denture:

1. Central or midline: stand in front of the patient some distance away, a wrong center line will be obvious, but if in doubt any aids can be used like dropping an imaginary line from the midpoint on the inter-pupillary line, the contact area between the two central incisors should coincide with this line.
2. Anterior plane: this may be observed from some distance away from the patient, and any tendency for this plane to slope markedly up or down should be noted and corrected.
3. Size, form and shade of teeth: the size of six upper anterior teeth should approximately the width between the corners of the mouth. The form should be in harmony with the face form, but not necessarily identical with the outline of the face. The color of the teeth should blend with the face so the teeth do not become the main focal point of the face. The concept of the influence of sex, age and personality must be considered when developing harmony among teeth form, arrangement and the patient.
4. Lip support and profile: the upper lip should be adequately and properly supported by the upper anterior teeth. The labial surfaces of central incisors will be about 8-10 mm in front of the middle of incisive papilla. The

further the papilla is located labially, the greater the maxillary ridge resorption and the further the anterior teeth must be positioned. In many instances the inclination of anterior teeth is similar to that of the profile of the face.

5. Amount of tooth visible: the amount of upper anterior teeth seen during speech and facial expression depend on the length of upper lip. In long lip no teeth are visible, the teeth are shown in smiling only. While in short lip, full crown may be visible below the upper lip even at rest. On smiling, large amount of denture base in addition to teeth are visible. For the lower teeth must be leveled with the corner of the mouth when the patient opens slightly.
6. Regularity of teeth: few natural teeth exhibit perfection, and to perfect a set up in the incisor region especially in persons of middle age, try to avoid that the teeth looks artificial. Therefore, a little irregularity is usually desirable like rotating and overlapping the teeth to give an irregular appearance.
7. Harmony of the incisal edge of maxillary anterior teeth with smiling line of lower lip: usually the incisal plane of maxillary anterior teeth follows the contour of the lower lip during smiling.
8. Buccal corridor: usually a buccal corridor should be evident between the teeth and cheek. Wide upper arch cause crowding appearance and obliterating of corridor, while narrow upper arch causes an increase in the buccal corridor which looks like a dark space between teeth and cheek.

Evaluation of the phonetics

Labiodental sounds (f, v)

- F&v are between the upper incisors and the posterior one third of the lower lip.
- Affected by the anteroposterior position of upper anterior teeth and their length.
- If upper anterior short, v sound will be more like an f.
- If upper anterior long, f sound will be more like v.

Linguoalveolar sound <u>(t, z, s,d,v,l,ch,sh)</u>

During pronunciation of sibilants like “z, s, ch”, teeth will come close together but do not touch. Silverman’s closest speaking space is used for determining proper vertical dimension. Clattering of teeth indicates excess vertical height. “S” resembles “Sh” or whistling sound when there is insufficient degree of jaw separation.

Bilabial sounds (p,b ,m)

“P”, “B”, “M” help in determining the correct degree of jaw separation. When the vertical dimension is too high, the patient will not be able to purse his lips together and consequently the articulation of these sounds may be distorted.

Incorporation of posterior palatal seal area

The patient is asked to keep the mouth open and say ‘ah’. A two lines are drawn with indelible pencil in the patient’s mouth across the palate extending from one hamular notch to the other that the detect the anterior and posterior vibrating line. The trial base is inserted into the patient’s mouth so that the indelible markings are transferred to the trial base. The trial base is seated on the master cast to transfer the markings marked in the patient’s mouth to the cast. The area between the anterior and posterior vibrating line is scraped in the master cast to a depth of 1 to 1.5 mm on either side of the mid palatine raphe. In the region of the mid-palatine raphe, it should be only 0.5 to 1mm in depth.

Patient’s role in trial denture

1. To record their wishes and expectations.
2. The patient agreement of any alteration in form from the previous dentures.
3. The patient, and any accompanying person, should agree on the acceptability of the trial dentures and that the patient is happy to proceed to completion.

Technician’s role in trial denture

1. To have replicated the registration records faithfully.
2. To place teeth according to prosthodontic norms.
3. To provide stable bases.
4. To ensure that balanced occlusion/articulation is provided, according to the prescription by the clinician.

5. To have articulated casts appropriately and to have set condylar angles to any prescription given.
6. To ensure waxwork is complementary to the age and personality of the patient.

Anatomy of the TMJ and Mandibular Movement

Temporomandibular joint (TMJ): Is the articulation of the condyloid process of the mandible and the interarticular disk with the mandibular (glenoid fossa) of the temporal bone. The TMJ consist of the following parts:

1. The mandibular or glenoid fossa.
2. The condyle or head of the mandible.
3. The articular disc or "Meniscus" which is found between the condyle and the glenoid fossa. It divides the synovial joint or TMJ into upper (superior) and lower (inferior) compartments.
4. Synovial cavity.

How does the TMJ move during function:-

Replacement dentures must work in harmony with the patients TMJ which consist of the condyles which articulate with the temporal bones and are located in the elliptical concave depressions called the glenoid fossae in which they travel forward, from side to side, and in some instances slightly backward. Between the dome- shaped concavities in the temporal bones and the condyles are interposed the interarticular fibrocartilages, the meniscus, which are attached at their margins to the articular capsules. The meniscus divides the joint into upper and lower compartments. Normally the movements in the upper compartment is chiefly gliding anteroposterior motion in which the condyles and the cartilage move as a unit, the movement in the lower compartment is hinge like. Therefore, condylar paths are the controlling factor in the mandibular movements. These movements are results of action of muscles of mastication, suprahyoid, and infrahyoid muscles.

Temporomandibular joint

The ligaments that effect the movement of the mandible consist of:

1. Tempro mandibular and capsular ligaments.
2. Sphenomandibular ligament.
3. Stylomandibular ligament.

The mandibular bone has specific relationships to the bones of the cranium. The mandible is connected to the cranium at the two temporomandibular joint by the temporomandibular and capsular

ligaments. The sphenomandibular and Stylomandibular ligaments also connect the bones in such a way as to limit some motions of the mandible.

The muscles that control the movement of the mandible may be considered in 3 groups:

1. Closing muscles.
2. Gliding muscles.
3. Opening muscle.

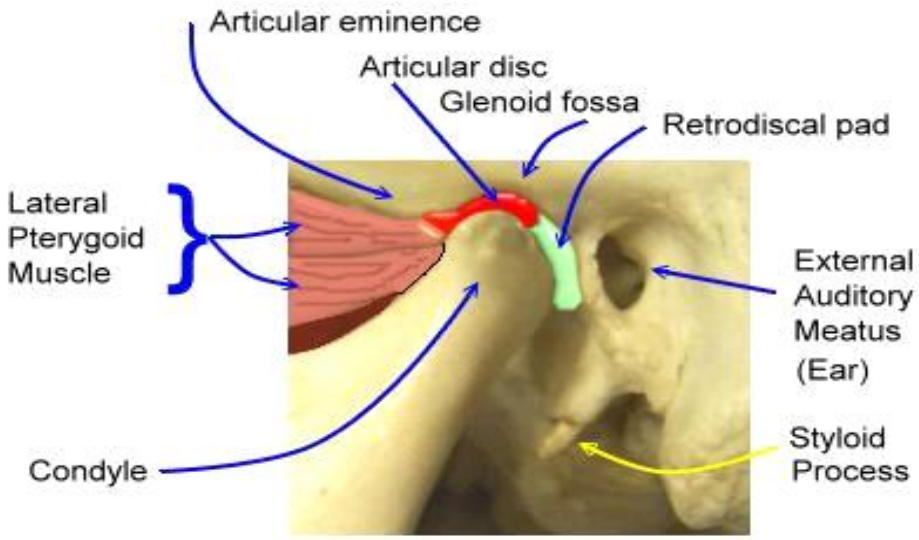

The closing muscles include

- The masseter muscle (muscle of mastication)
- The temporal muscle =
- The medial pterygoid muscle.

The direction of their fibers is essentially vertical, their origin is superior to their insertion on the mandible.

The gliding muscles include:

Lateral pterygoid muscles (muscle of mastication). The actions of these muscles are to pull the mandible forward if they both contract simultaneously, or to pull the mandible laterally if they contract individually.

The opening muscles:

- Suprahyoid muscles their origin below the mandible
- Infrahyoid muscles action-downward and backward

The teeth could not occlude or disoccludes without the action of four (paired) muscles of mastication that make it all possible.

The masseter, temporalis & medial pterygoid muscles supply the power for pulling the mandible against the maxillae (elevating &closing mandible).

*The lateral pterygoid muscles connect the mandible to the lateral pterygoid plate in such a way as to act as the steering mechanism for the mandible & act to protrude the jaw or to move it laterally.

* While the muscles that depress the mandible (open) consist of three groups, suprahyoid muscle and platysma, infrahyoid muscles, and lateral pterygoid muscles.

Prosthodontic treatment has a direct relation to the structures of the temporomandibular articulation, since occlusion is one of the most important parts of treatment of the patients with complete dentures. The temporomandibular joints affect the dentures and likewise the dentures affect health and function of the joints.

The muscles of mastication

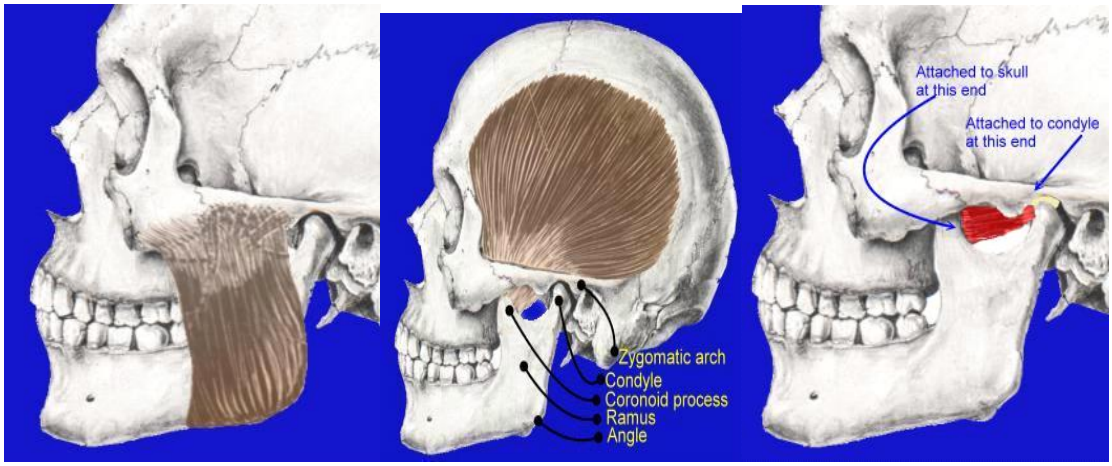

Masseter and the Temporalis muscle, lateral pterygoid, Medial Pterygoid muscles

Mandibular axes

There are three axes around which the mandibular movements takes place in horizontal, sagittal and frontal planes. These axes include the followings:

1. **Hinge axis:** or transverse horizontal axis:
   An imaginary line around which the mandible may rotate within the sagittal plane. (During the opening and closing movement).

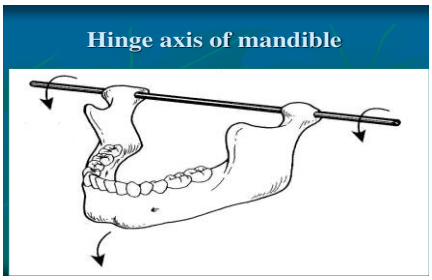

2. **Sagittal axis of the mandible :**
   An imaginary anteroposterior line around which the mandible may rotate when view in the frontal plane.

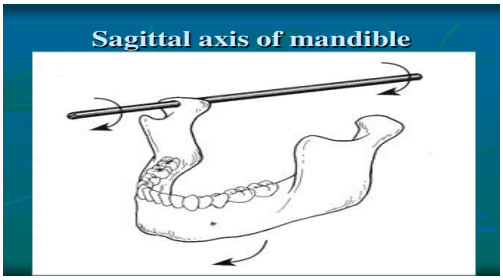

3. **Vertical axis of the mandible:**
   An imaginary line around which the mandible may rotate through the horizontal plane.

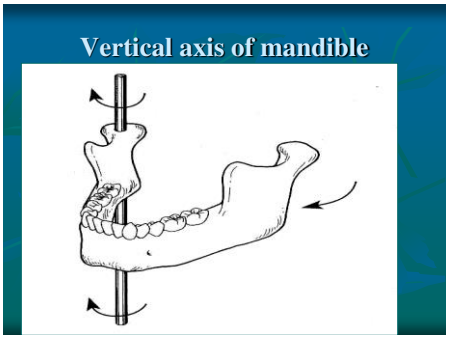

Mandibular Movements

Movement of the condyle occur along the posterior slop of the articular eminence and extend as far forward as its crest. In some instances, movements may involve part of the anterior slope.

*Mandibular movements are related to three planes of the skull---the horizontal, frontal, and sagittal. The mandible rotates in each of the three planes of space. The point of intersection of the three axes is called the center of rotation.

Mandibular movements may be ***divided*** into two types either ***basic*** or ***functional*** movement.

1. Basic movements: This movement occurs at the level of TMJ it may be divided into two types:

a- Rotational movement:

The rotational movement occurs between the condyle and the inferior surface of the articular disk, i.e. in the lower compartment of the TMJ. Centric relation which is called uppermost, rearmost, midmost or most posterior position is purely rotary movement about the transverse horizontal axis. It is reproducible and consistent movement therefore, it is beneficial in maxillomandibular relationship recording.

b- Translatory or gliding movement: It take place in the upper compartment of the TMJ, i.e. between the superior surface of the articular disk and the glenoid fossa.

Mandibular movement, except the opening and closing in its most posterior position (posterior terminal hing movement) are combination of rotation and translation, and referred to as functional movements.

2- Functional movement: All mandibular movements except the terminal hinge movement, are combination of rotational and translational, are most frequently and are referred to as being functional movement. They are including:

- *Opening and closing movements*
- *Symmetrical forward and backward movements.*
- *Asymmetrical side wise movement or lateral movement.*

- The opening and closing movements are considered the most important mandibular movements and they are divided into.
- Habitual movement.
- Border movement.

Take place within three dimensional limits the mandible can move about (10 mm laterally), open about (50 to 60 mm), protrude approximately (9mm), and retrude about (1 mm). These limits described by Posselt in 1952 and which are known as border movements of the mandible. *It's the most extreme positions to which the jaw is able to move in any direction.* The border positions are limited by nerves, bones, muscles, teeth (if present) and ligaments.

Border movements, subdivided into:

- Anterior border movement, appear as one arc in the sagittal plane, the condyles rotate and translate in this movement.
- Post border movement, appear as two arcs in the sagittal plane, the condyles rotate in the opening and closing up to the point of terminal hinge opening and translate to the point of maximal opening

In the sagittal plane



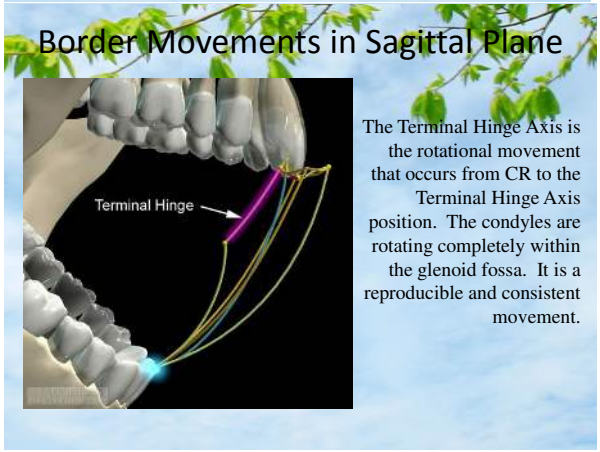

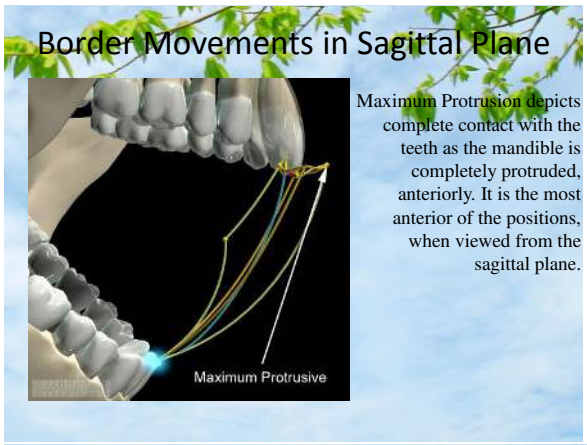



Sagittal plane movements:-

A map of the boundary of the movements of mandible when viewed from one side of the head, it is tracing of the maximum vertical and anteroposterior movements of the mandibular central incisors.It includes

1- Maximum intercuspation or centric occlusion (CO) this border position is usually defined as that point where the teeth best interdigitate.

2- If the mandible is retruded farther to its posterior most superior, most terminal hinge position, the limits of movement and the border position are determined by structures of the T.M.J.

Some have also referred to this position as (Centric relation) CR. It has been defined in a number of different ways.

Extreme Movements in the Sagittal Plane

A characteristic **'*Beak tracing*'** is formed while recording border movements in the sagittal plane. Here, the patient is instructed to move the mandible from **centric relation (CR)** to **centric occlusion (CO)**, then to the **edge to edge relationship (ER)** guided by the incisal guidance, progress further forward to the **maximum protrusive (MP)** position and then arc downward to the **maximum mouth opening (MMO) position**. Once this position is reached the operator should guide the mandible backward and close the mouth. While closing the mouth the mandible arcs upward (**RAT-rotation after translation**) around a transverse axis passing through the mandibular foramen. Consecutively the condyle translates back to the centric relation position where the mandible continues to arc upwards around the **true hinge axis** passing through the condyle **(THA).**

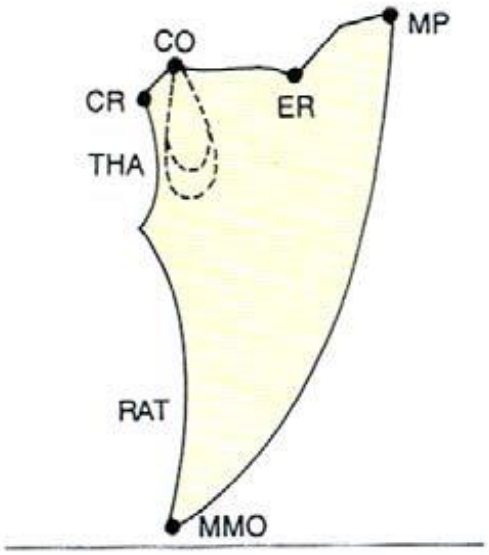

Extreme Movements in the Horizontal Plane

Border movements recorded in the horizontal plane produced a characteristic **'*Diamond tracing*'**. While recording the tracing, the patient is instructed to move his mandible from the centric relation position (CR) to the maximum right lateral (MRL) position to the maximum protrusive (MP) position, to the maximum left

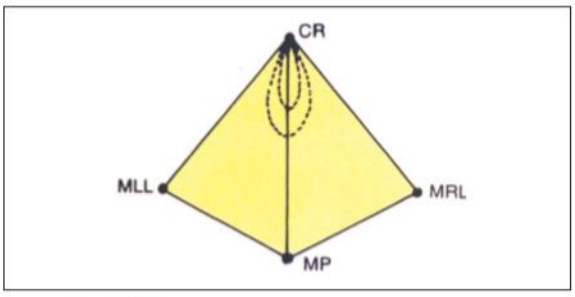

Fig. 9.19: Diamond tracing. Border movement recorded in the horizontal plane

lateral (MLL) position and return to centric. An arrow point tracing formed using Gothic arch tracers should and will coincide with this pattern.

Extreme Movements in the Coronal Plane

Border movements produced in this plane produce a characteristic **'shield tracing**'. Here the patient is instructed to move his mandible from centric occlusion (CO) to canine-guided disocclusion on the right side (RD) and then to the maximum right lateral position (MRL) then arc downwards to the maximum mouth opening position (MMO). From this position, the patient is instructed to arc upward to the maximum left lateral position (MLL), return medially to canine guided disocclusion on the left side (LD) and then return to centric occlusion (CO).

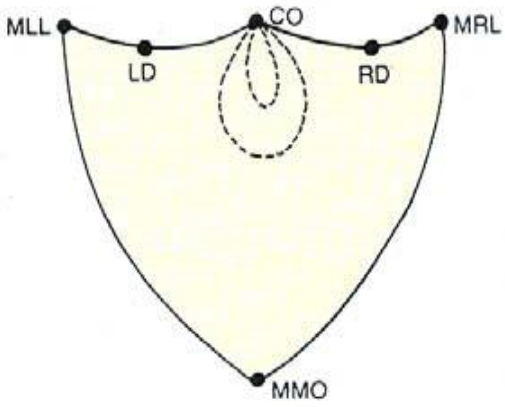

Envelope of Motion

When we combine the border movements of all the three planes, we get a three-dimensional space within which mandibular movement is possible. This three-dimensional limiting space is called the *envelope of motion.* It was first described by Posselt in 1952.

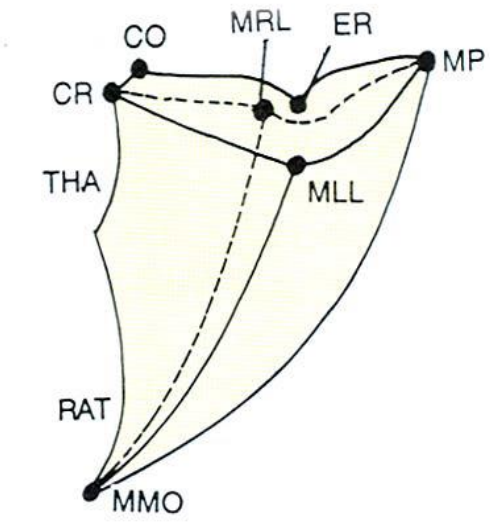

Four movements of prime importance to complete denture service are:-

1- The hinge like movement used in opening and closing the mouth for the introduction of food.

2- A protrusive movement used in the grasping and incision of food.

3- Right or left lateral movements for use in the reduction of fibrous as well as other types of food and

4- Bennett movement – the bodily side shift of the mandible which when it occurs, may be recorded in the region of the advancing and (balancing) non-working side.

Functional mandibular movements include all natural or characteristic movements occurring during mastication, swallowing, speech and yawning.

- Parafunctional movements: - movements that occur in the clenching, tapping or grinding of the teeth.

Jaw Registration of Condylar Movements

What is it and why do we record it?

It is a recording of the paths/positions of the condyles during border movements that are recorded in order to program the articulator to simulate the patient's condylar movements

How is it recorded ?

1. Pantographic tracing to program a fully-adjustable articulator
2. Interocclusal records to program a semi-adjustable articulator

Face bow record
CR record
Protrusive record
Lateral record

Articulator: Mechanical Systems used to Replicate Mandibular Movement**.**

Types of articulators:

Class I- a simple holding instrument capable of accepting a single static registration; vertical motion is possible (e.g. .non-adjustable).

Class II-an instrument that permits horizontal as well as vertical motion, but does not orient the motion to the temporomandibular joints.
Class III-an instrument that simulates condylar pathways by using averages or mechanical equivalents for all or part of the motion; allow for orientation of the casts relative to the joints and may be arcon or non-arcon instruments (e.g. semi-adjustable)
Class IV-an instrument that will accept three-dimensional registrations; allow for orientation of the casts relative to the joints and simulation of mandibular movements (e.g. fully adjustable).

Third visit in complete denture construction (clinical step)
Occlusal plane orientation, vertical dimension, face-bow transfer, centric relation.

Objectives of this visit

- Occlusal plane: - To determine the horizontal and vertical level of the teeth.

- Vertical dimension: - To determine the amount of space between the rims with jaws at rest and with the wax rims in occlusion.

- Face-bow transfer: - To record the position of the jaws as related to the opening axis of the mandible and transfer this position so that the casts on the articulator will have the same relationship to the opening axis of the patient.

- Centric relation: - To record the most posterior position of the mandible to the maxilla and transfer this position to the articulator.

Face-bow transfer :-A face-bow is a caliper- like device used to record the patient's maxilla/ hinge axis relationship and to transfer this relation to the articulator during mounting of the maxillary cast.
If the face-bow transfer procedure properly done, the arc of closure on the articulator should duplicate that exhibited by the patient.
A face-bow transfer could be used when:-

- Cusped posterior teeth are selected.
- Balanced occlusion in eccentric positions is desired.
- Interocclusal check records are used for verification of jaw relationships.

Some authors reported that if cuspless teeth and a monoplane occlusion are selected, a face-bow transfer is unnecessary. Other recommend the use of face-bow, even for cuspless teeth to provide more accurate placement of casts in the articulator than would be obtained by simply placing arbitrarily.

There are two types of face-bow, the ***kinematic and the arbitrary.***

The kinematic face-bow is used to accurately locate the hinge axis, it is attached to a clutch which is in turn attaches to the mandibular teeth. As the mandible makes opening and closing movement, the condyle styli move in an arc. The kinematic face-bow generally not used for CD fabrication because the resiliency of the soft tissues make precise location of the rotational centers almost impossible.
Several varieties of arbitrary face-bows are available. All are based on an average location of the hinge axis. It is located over measured points on the face or by some type of earpiece. One average measurement places the rotational point 13mm anterior to the distal edge of the tragus of the ear, along a line from the superior-inferior center of the tragus to the outer canthus of the eye. The condyle styli of the face-bow are then placed directly over the dots. This technique is used with Hanau H-2 and Dentatus articulators.

Facebow Registration

- On a <u>fully adjustable articulator</u>, the "true hinge axis" must be located
- On a <u>semi-adjustable articulator</u>, the "arbitrary hinge axis" is used, and this is determined by the manufacturer of the facebow and articulator system.



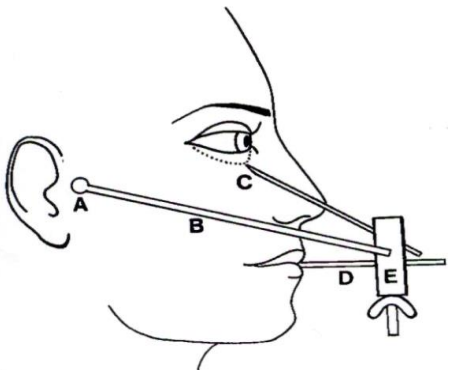

In order to understand the maxillomandibular relation and concepts of occlusion we have to study the mandibular movements.

Recording the mandibular movements affected by TMJ, muscular involvements, neuromuscular regulation of mandibular motion, and ligaments.

Lec ١٠ Prosthodontic Repairs of fractured partial dentures

seineen salam

Deciding to repair or remake an existing RPD is sometimes difficult. Consider before proceeding to treatment:

- The patient's financial status.
- The patient's physiological age.
- The frequency of appointments, which represents production time.
- The patient's medical status.
- The degree of difficulty of the impression - making procedures.
- The associated dental laboratory fees.

Some or all of these factors may influence the decision whether to repair or remake the prosthesis. Frequently, it is more expedient to remake an RPD than to devote the time, effort, and dental laboratory fees necessary to repair a framework that is marginally acceptable and may require replacement in the near future.
Simple repairs or additions to an RPD can usually be accomplished with or without impressions. Many times, simple repairs can be accomplished in the dental office without outside dental laboratory support or expense.

Denture base repair

Various types of RPD base breakage may occur, ranging from the complete loss of a denture base border segment to the fracture or loss of a portion of the denture base proper. In the former example, complete loss of a segment of the denture base border will require a rebasing or relining impression procedure.

1. When an entire portion of the denture base is missing, the denture base must be corrected with autopolymerizing acrylic resin, stick compound, or both so that the impression material can be accurately carried into place. A reline impression using an elastomeric impression material is made; the RPD acts as a tray.



2. The completed impression is boxed and poured with dental stone to secure a master cast.
3. The new denture flange segment is repaired with either autopolymerizing or heat - cured acrylic resin. Heat - cured acrylic resin repairs are best accomplished by a dental laboratory service.
4. When the fractured segment of the RPD denture base is still available, the repair is a relatively simple in - office procedure. The fractured pieces are approximated and joined with sticky wax.

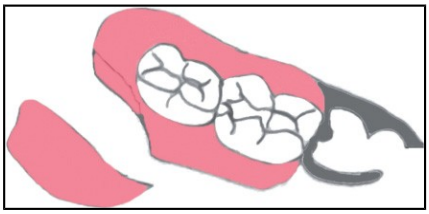

The tissue surface of the RPD is poured with dental stone. When the master cast is sufficiently hard, the RPD is removed and the junction of the segments is enlarged to approximately 2 – 3 mm in width. A separating medium is applied to the working cast, and the RPD segments are replaced on the stone cast; the space of 2 – 3 mm created between the segments is for the repair acrylic resin.

Autopolymerizing acrylic resin is added in a“salt and pepper” fashion (sprinkled on) to the space between the approximating segments. The acrylic resin monomer and polymer should be applied alternately until the repair site is slightly overfilled. For a denser repair with less internal porosity, the RPD still on the dental stone cast should be placed in a temperature – controlled For a denser repair with less internal porosity, the RPD still on the dental stone cast should be placed in a temperature – controlled pressure bath at 30 p.s.i. at about 120 ° F for30 minutes.

The repair site is trimmed and finished with acrylic burs mounted in a low - speed handpiece. Polishing is carried out in a manner, using the various grades of conventional pumice and finally acrylic resin polish.

Repair of fractured denture teeth

There are two basic types of denture teeth used in RPD treatment: dental porcelain and acrylic resin.
The procedure for repair and replacement of acrylic resin denture teeth is as follows:

1. If an acrylic resin denture tooth is dislodged from a new RPD, the common cause is an incomplete chemical bond between the acrylic resin denture tooth and the acrylic resin denture base. This incomplete chemical bond may be caused by wax residue or oils left between the two acrylic resins when the RPD was processed.
2. Therefore, the denture tooth can normally be reseated in the denture base and autopolymerizing acrylic resin may be used to repair the RPD. Processing, finishing, and polishing are the same as described for the repair of the denture base.

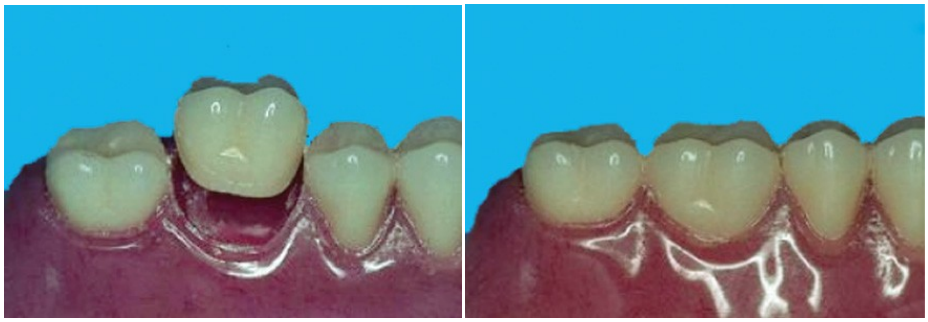

3. When the acrylic resin denture tooth is abraded or fractured, a similar series of steps may be accomplished. The fractured or abraded tooth must be carefully cut out to create space in the denture base for a similarly sized new denture tooth. This should be accomplished at slow speed with an acrylic bur.
4. A new denture tooth is selected, adjusted to fit the repair site, and checked to ensure that there is adequate room for the autopolymerizing acrylic resin.
Occasionally the anterior denture teeth are positioned against the residual ridge to eliminate a denture flange. In these instances, when an anterior denture tooth is fractured, an impression must be made with the RPD in place and the repair must be carried out to completion on a dental stone cast.
When denture teeth are repaired on an RPD, the occlusion of the RPD in centric and eccentric positions must be carefully checked and adjusted as necessary.

Complex repairs

There are many complex repairs or modifications that can be made to a defective RPD. These include

(1) Repair or replacement of a clasp assembly or any part thereof,
(2) Repair of a major or minor connector, and
(3) Repair of the RPD after the loss of an abutment tooth.

All complex repairs require the use of proper impression procedures by the dentist. The most frequent type of component breakage on an RPD is the fracture of one or more parts of the clasp assembly (i.e., fracture of one or more clasp arms, the occlusal rest, or the area between the minor connector and the major connector). The cause of the fracture should be determined and corrected. If the design of the RPD was inadequate and stress on the RPD framework or parts of it was too great, then a new design and RPD are indicated.

More commonly the fracture of the framework is caused by
a patient or dentist mishandling the chromium- cobalt alloy (such as dropping the prosthesis, bending it on a dental lathe, or adjusting the clasp arm beyond the elastic limit of the metal).

A clasp arm is the RPD component that is most subject to fracture, and it can be repaired by either of two techniques:

(1) By embedding an18 - gauge wire into the denture base of the RPD as a substitute clasp arm.
(2) By constructing a new clasp assembly and soldering or welding it to the existing RPD framework**.** The procedure for repair of a broken clasp arm using a wire is presented as a repair that may be accomplished in the dental office on a selected basis.

1. The buccal retentive clasp of an RPD is usually the most commonly fractured or deformed framework component. An 18 gauge platinum - gold - palladium (PGP) or wrought wire can be used as an effective substitute to replace this retentive arm on the RPD.
2. The fractured RPD is placed in the patient's mouth and the position and fit are verified. An irreversible hydrocolloid (alginate) impression of both the RPD and the natural teeth is made in a stock tray. Ensure the RPD has not been dislodged from the natural teeth or pulled loose from the alginate impression**.**



3. This impression is poured immediately with dental stone to create a working cast on which the repair will be completed.

4. The fractured portion of the clasp arm is removed from the RPD framework. An area is created in the acrylic resin denture base.

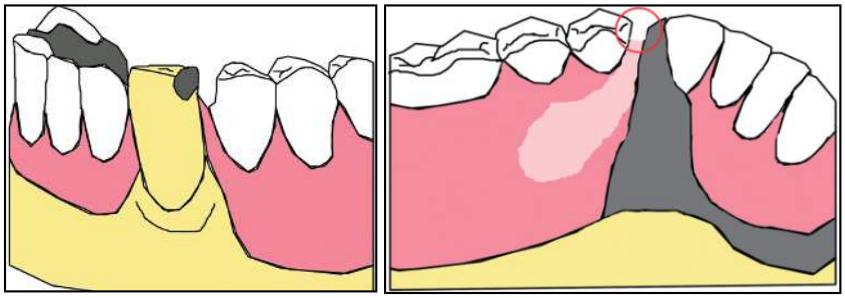

The 18 - gauge PGP or wrought wire is contoured to fit the contours of the dental stone replica of the abutment tooth, using orthodontic pliers. A retention loop is fashioned in the distal end of the wire so that it can be mechanically bound into the acrylic resin denture base.
The completed 18 - gauge PGP or wrought wire is secured in place with sticky wax on the dental stone abutment tooth**.**

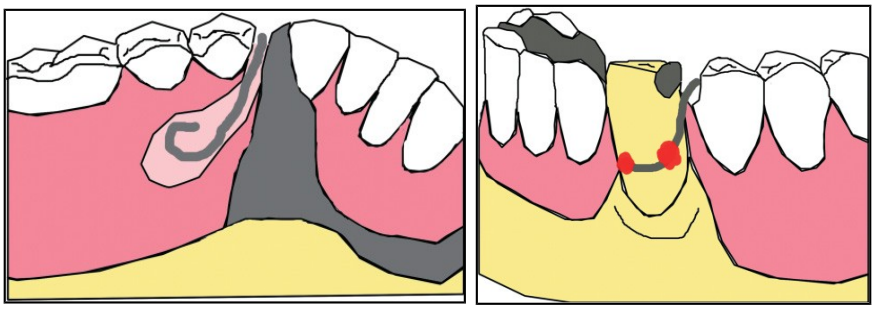

Autopolymerizing acrylic resin can be added in “salt and pepper” fashion to complete the mechanical retention of the wire in the denture base.
The RPD, 18 - gauge PGP or wrought wire, and autopolymerizing acrylic resin are cured in a temperature - and pressure – controlled curing unit in warm water (about 120 ° F) for 30 minutes at 30 p.s.i.

The RPD is now ready for careful removal from the repair cast.

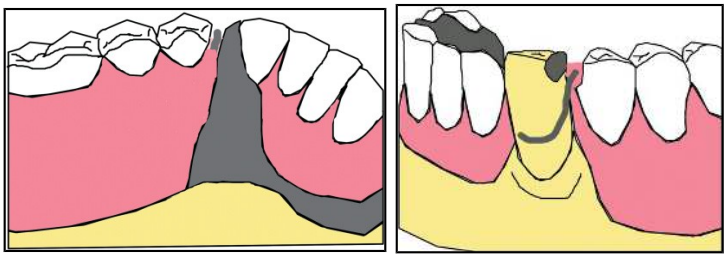

The new buccal retentive arm and acrylic resin are finished and polished. The RPD is checked intraorally for proper contact of the 18 - gauge PGP or wrought wire arm into the retentive undercut. Adjustments are made when necessary to the wire to increase or decrease the frictional retention of the arm.

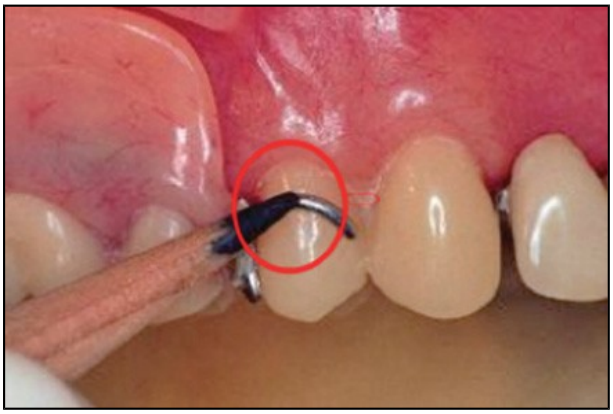

Additional repair methods for replacing a lingual reciprocal arm, broken occlusal rests, and replacing teeth that are extracted are possible. Even fractured major connectors may be repaired. Additionally, fractured abutment teeth or other teeth in contact and in support of the RPD can be restored under an existing RPD.
However, each of these procedures is complex and often time - consuming. One should carefully consider the value of attempting such repairs and modifications. It is important to understand and evaluate the conditions that led to the need for the repair. It is often more prudent to correct the conditions and remake the RPD than to repair a prosthesis of marginal use and function. It is beyond the scope of this discussion to elaborate on these procedures. However, there are many excellent publications that describe these advanced clinical and laboratory procedures in depth.