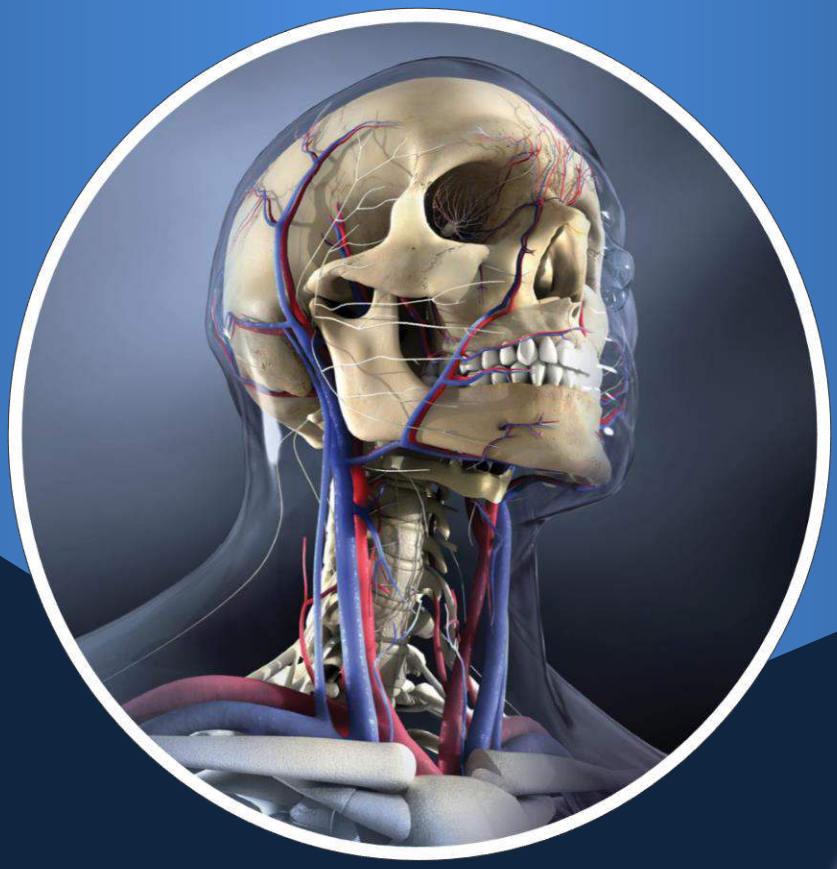

Oral Surgery

Third Stage

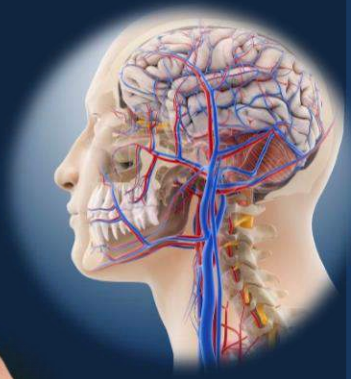





Zaid A. Abdullah

B.D.S., MSc

Zaid A. Abdullah
B.D.S., MSc

Lecture 1

Extraction of Teeth (Exodontia)

Difficulty will be high or if initial attempts at tooth removal confirm this, a deliberate surgical approach—not an application of excessive force—should be taken. Excessive force may injure local soft tissue and damage the surrounding bone and teeth. Such force may fracture the crown, usually making the extraction substantially more difficult than it would have been otherwise. Moreover, excessive force and haste during an extraction heightens intraoperative and postoperative patient discomfort and anxiety.

Definition: Exodontia is a painless removal of teeth from their bony socket with relatively minimal amount of trauma to the surrounding tissue, so that the wound will heal without postoperative problem. Extraction of teeth is the most important part of minor oral surgery and the most common procedures for dentist.

CLINICAL EVALUATION OF TEETH FOR REMOVAL

Clinical preoperative evaluation

a-**General evaluation includes**: -

• General impression of the patient.

• History of general diseases, Nervousness and orientation

• General oral hygiene.

• Gingival inflammation, calculus, neglected mouth.

b-**Local factors evaluation Includes**: -

• Clinical examination of the accused tooth.

• Adjoining structures.

• Access to the tooth. This includes the mouth opening, location of the tooth (e.g. buccally malposed, in standing) may present difficulty in positioning the dental forceps for extraction, so you may remove such a tooth surgically.

• Tooth mobility: The mobility of the tooth to be extracted should be assessed preoperatively, greater than normal mobility is frequently seen with severe periodontal disease, but sometimes it maybe because of the underlying pathology like neoplasm

• Condition of the tooth: - e.g.

a) Carious destruction.

b) The presence of large restoration.

c) Presence or absence of the adjoining teeth.

d) Non-vital tooth.

e) State of the supporting tissue.

f) Shape, position, long axis and size of the crown.

g) Attrition.

In general, preoperative examination may help you in: -

a) Determine the method of extraction and type of anaesthesia.

b) Reduce the time spend for extraction.

c) Reduce the intra and post-operative crisis and complications.

Radiographic examination

Preoperative clinical assessment maybe supplemented some times by preoperative radiographs, and the **positive indications** for preoperative radiograph are: -

1) History of difficult or unsuccessful extraction.

2) Crown with extensive caries, large restorations, non-vital tooth when diagnosis is not certain and tooth is malposed.

3) A tooth which is abnormally resistant to forceps extraction.

4) If after clinical examination you decide to remove the tooth surgically.

5) Any tooth which is in close relation to important or vital structures like neurovascular canal, maxillary sinus, mental nerve, nasal cavity.

6) Attrition teeth in elderly patient (maybe associated with hypercementosis).

7) If a tooth is partially erupted or completely unerupted or retained root.

8) Any tooth which has been subjected to trauma, fracture of the root and/or alveolar bone maybe present.

9) An isolated maxillary molar especially if it is unopposed and over erupted. The bony support of such a tooth is often weakened by the presence of maxillary sinus and this may predispose to certain of oro-anrtal communication or fracture of the maxillary tuberosity.

10) Whenever, underlying bony pathology is suspected e.g. cystic lesion, tumor.

11)Any systemic condition which may predispose to dental or alveolar abnormality

like: -

a) Osteitis deformans (Paget's disease), in which the roots are hypercementosed andankylosed leading to difficult extraction, infection of the socket.

b) Cleido-cranial dysostosis, for pseudo-anodontia (multiple impactions, hooked roots occur, supernumerary teeth).

c) Patient who have received therapeutic irradiation to the jaw which may have to predispose to osteoradionecrosis.

d) Osteopetrosis (marble bone disease), which cause extraction very difficult and predispose to chronic osteomyelitis.

A good radiograph and careful interpretation may give or aid the operator to many **factors** that may cause **difficult extraction**, e.g.: -

1- Abnormal number and shape of roots.

2- An unfavorable root pattern.

3- Caries extending to the root mass.

4- Fracture or resorption of the root.

5- Hypercementosis of the roots.

6- Ankylosis (there is no space in periodontal ligament), and sclerosis of the bone.

7- Gemination (the development of two teeth from one bud).

8- Impaction.

9- Bony sclerosis and pathological lesions.

Also careful interpretation of the radiograph may also reveal or show the possibility of the **following complications**: -

1) Involvement of, and damage to inferior dental nerve and mental nerve e.g. on extraction of impacted lower third molar

2) The creation of oro-antral fistula or oro-nasal communication.

3) The retention of intra-bony pathology e.g. cyst.

4) The displacement of root or tooth into maxillary sinus.

5) Fracture of maxillary tuberosity.

Indication of Extraction

Teeth are extracted for a variety of reasons.

1- Caries

Perhaps the most common and widely accepted reason to remove a tooth is that it is so severely carious that it cannot be restored. Badly carious teeth result in deterioration of oral hygiene and bad smell in addition to pain.

2- Pulpal Necrosis

A second, closely aligned rationale for removing a tooth is the presence of pulpal necrosis or irreversible pulpitis that is not amenable to endodontics. This may be result of a root canal that is tortuous, calcified, and untreatable by standard endodontic techniques.

3-Periodontal Disease

A common reason for tooth removal is severe and extensive periodontal disease. If severe adult periodontitis has existed for some time, excessive bone loss and irreversible tooth mobility will be found. In these situations, the hypermobile teeth should be extracted. Also, ongoing periodontal bone loss may jeopardize the chance for straightforward implant placement.

4- Orthodontic Reasons

Patients who are about to undergo orthodontic correction of crowded dentition with insufficient arch length frequently require the extraction of teeth to provide space for tooth alignment. The most commonly extracted teeth are the maxillary and mandibular premolars. Great care should be taken to double-check that extraction is necessary and that the correct tooth or teeth are removed if someone other than the surgeon doing the extraction has planned the extractions.

5- Malposed Teeth

Teeth that are malpositioned may be indicated for removal in several situations. If they traumatize soft tissue and cannot be repositioned by orthodontic treatment, they should be extracted. A common example of this is the maxillary third molar, which erupts in severe buccal version and causes ulceration and soft tissue trauma of the cheek.

6- Cracked Teeth

An uncommon indication for extraction of teeth is a tooth with a cracked crown or a fractured root. The cracked tooth can be painful and is unmanageable by a more conservative technique. Sometimes, cracked teeth have already undergone endodontic therapy in the past.

7- Impacted Teeth

Impacted teeth should be considered for removal. If it is clear that a partially impacted tooth is unable to erupt into a functional occlusion because of

inadequate space, interference from adjacent teeth, or some other reason, it should be considered for surgical removal.

8- Supernumerary Teeth

Supernumerary teeth are usually impacted and should be removed. A supernumerary tooth may interfere with eruption of succedaneous teeth and has the potential for causing their resorption and displacement.

9- Teeth Associated with Pathologic Lesions

Teeth that are involved in pathologic lesions may require removal. This is often seen with odontogenic cysts. In some situations, the tooth or teeth can be retained and endodontic therapy performed. However, if maintaining the tooth compromises the complete surgical removal of the lesion when complete removal is critical, the tooth
should be removed.

10- Radiation Therapy

Patients who are to receive radiation therapy for oral, head, or neck cancer should consider removal of teeth (that cannot kept in sound condition) and are in the beam of radiation therapy before treatment. Trauma (extraction) with superadded infection will lead to development of osteoradionecrosis of the jaw bone which is unpleasant complication and difficult to be treated.

11- Teeth Involved in Jaw Fractures

Patients who sustain fractures of the mandible or the alveolar process sometimes must have teeth removed. In some situations, the tooth involved in the line of fracture can be maintained, but if the tooth is injured, infected, or severely luxated from the surrounding bony tissue or interferes with proper reduction and fixation of the fracture, its removal may be necessary.

12-prosthetic consideration

Extraction of teeth are indicated for:

a) providing efficient dental prosthesis

b) To provide better design for success of partial denture, few teeth may be extracted.

c) Solitary tooth or non-strategic tooth to enable the patient to have complete denture e.g. full mouth clearance.

13- Root fragments (retained roots)

Contraindications for Removal of Teeth

Even if a given tooth meets one of the requirements for removal, in some situations, the tooth should not be removed because of other factors or contraindications to extraction. These factors are relative in their strength. In some situations, the contraindication can be modified by the use of additional care or treatment, and the indicated extraction can be performed. In other situations, however, the contraindication may be so significant that the tooth should not be removed. Generally, the contraindications are divided into two groups: **(1) systemic and (2) local.**

1- Systemic Contraindications

Systemic contraindications preclude extraction because the patient's systemic health is such that the ability to withstand the surgical insult may be compromised. So that extraction should be postponeded until the severity of the problem has been resolved and after consultation with the patient's physician, so caution is advised in the following conditions: -

1-A group of conditions called severe uncontrolled metabolic diseases. Uncontrolled diabetes and end-stage renal disease with severe uremia are part of this group.

2- Patients who have uncontrolled leukemia and lymphoma should not have teeth removed until the malignancy can be brought under control. The potential

complications are infection as a result of nonfunctioning white cells and excessive bleeding as a result of an inadequate number of platelets.

3- Patients with any of a variety of severe uncontrolled cardiac diseases should also have their extractions deferred until the disease can be brought under control. Patients with severe myocardial ischemia such as unstable angina pectoris and patients who have had a recent significant myocardial infarction.

4- Patients who have malignant hypertension should also have extractions deferred because persistent bleeding, acute myocardial insufficiency, and cerebrovascular accidents are more likely to occur as a result of stress caused by the extraction.

5- Pregnancy is a **relative contraindication** to extractions; patients who are in the first or third trimester should have their extractions deferred, if possible.

6- Patients who have a severe bleeding diathesis such as hemophilia or who have severe platelet disorders should not have teeth extracted until the coagulopathy has been corrected. Similarly, patients who take anticoagulants can have routine extractions performed when care is taken to manage the patient appropriately.

7- Patients who take or have taken a variety of medications should have surgery performed with caution or after medical consultation. Drugs to watch for include systemic corticosteroids, immunosuppressive agents, bisphosphonates, and cancer chemotherapeutic agents.

8- Uncontrolled epilepsy.

2- Local Contraindications

Several local contraindications to the extraction of teeth also exist.

1- The most important and most critical is a history of therapeutic radiation for cancer. Previous therapeutic radiation in oral and maxillofacial region for treatment of cancer lead to fibrosis and decreased vascularity of the tissue or area of extraction and end with a condition in the bone called osteoradionecrosis

2- Teeth that are located within an area of tumor, especially a malignant tumor, should not be extracted. The surgical procedure for extraction could disseminate malignant cells thereby seeding metastases.

3- Patients who have severe pericoronitis around an impacted mandibular third molar should not have the tooth extracted until the pericoronitis has been treated. Nonsurgical treatment should include irrigations, antibiotics. If the mandibular third molar is removed in the face of severe pericoronitis, the incidence of complications increases. If the pericoronitis is mild and the tooth can be removed easily, then immediate extraction may be performed.

4-The acute and uncontrolled infection. It may be difficult to extract such a tooth because the patient may not be able to open the mouth sufficiently wide, or it may be difficult to reach a state of profound local anesthesia. If access and anesthesia considerations can be met, the tooth should be removed as early as possible. Otherwise, antibiotic therapy should be started and extraction planned as soon as possible.