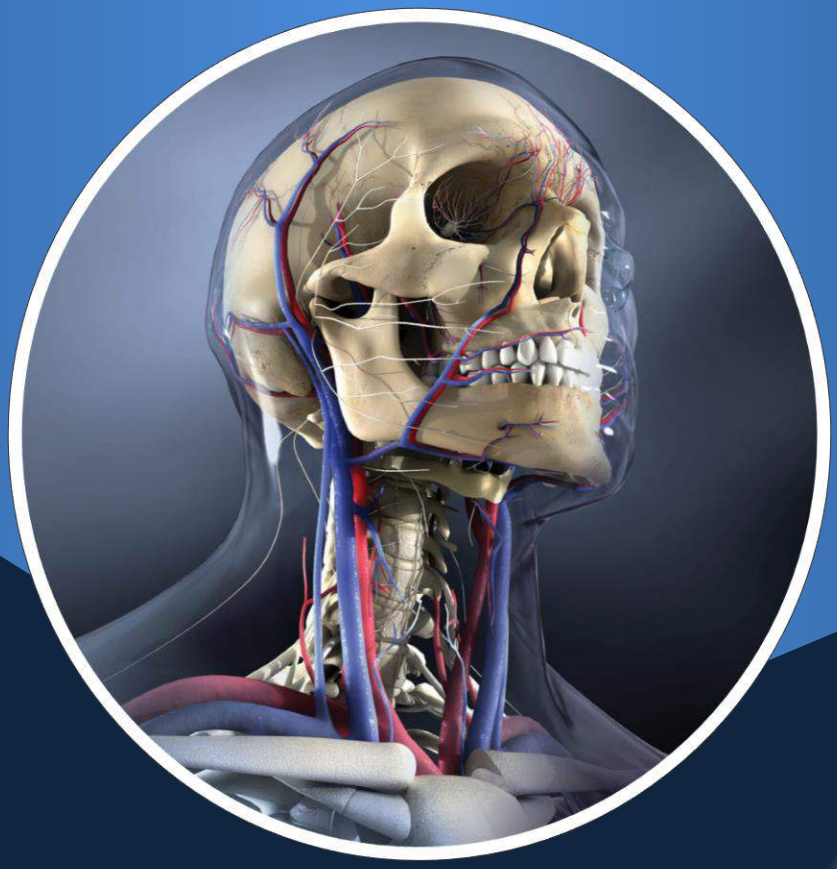

Oral Surgery

Third Stage

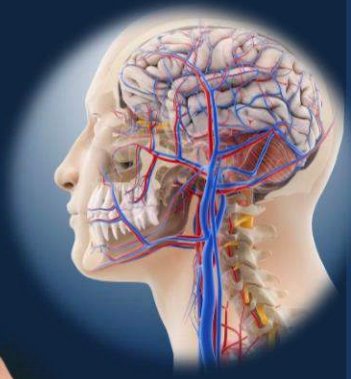





Zaid A. Abdullah

B.D.S., MSc

Zaid A. Abdullah
B.D.S., MSc

Lecture 4

Trigeminal nerve: -

The management of pain in dentistry requires a thorough knowledge of the fifth cranial nerve (fig:1). The right and left trigeminal nerves provide, among other functions, the overwhelming majority of sensory innervation from the teeth, and soft tissues of the oral cavity. The trigeminal nerve is also the largest cranial nerve. It is composed of a small motor and considerably larger sensory root. The motor root supplies the muscles of mastication and other muscles in the region. The three branches of the sensory root supply the skin of the entire face and the mucous membrane of the cranial viscera and oral cavity, except for the pharynx and the base of the tongue.

An understanding of the management of pain in dentistry requires a thorough knowledge of the fifth (V) cranial nerve. The right and left trigeminal nerves provide the majority of sensory innervation from teeth, bone, and soft tissues of the oral cavity. The trigeminal nerve is the largest of the twelve cranial nerves. It is composed of a small motor root and a larger sensory root.

The three sensory divisions of the trigeminal nerve are:

1. **The ophthalmic division (V1)** exits the skull through the superior orbital fissure into the orbit. It is the first branch of the trigeminal nerve, purely sensory and is the smallest of the three divisions.

2. **The maxillary division (V2)** exits the skull through the foramen rotundum into the upper portion of the pterygopalatine fossa. It is intermediate in size between ophthalmic and mandibular divisions. It is purely sensory in function.

3. **The mandibular division (V3)** exits the skull, along with the motor root, through the foramen ovale. Just after leaving the skull, the motor root unites with the sensory root of the mandibular division to form a single nerve trunk that enters the infratemporal fossa.

Maxillary Division (V2)

Once outside the cranium, the maxillary nerve crosses the uppermost part of the pterygopalatine fossa. It then enters the orbit through the inferior orbital fissure occupying the infraorbital groove and becomes the infraorbital nerve, which courses anteriorly into the infraorbital canal. The following is a summary of maxillary division innervation:

1. **Skin** (middle portion of the face, lower eyelid, side of the nose and upper lip).

2. **Mucous membrane** (nasopharynx, maxillary sinus, soft palate, tonsil and hard palate).

3. **Maxillary teeth and periodontal tissues**

Branches originating within the pterygopalatine fossa

The nasopalatine nerve enters the incisive canal, through which it passes into the oral cavity via the incisive foramen, located in the midline of the palate about 1 cm posterior to the maxillary central incisors. The right and left nasopalatine nerves emerge together through this foramen and provide sensation to the palatal mucosa in the region of the premaxilla.

The greater palatine nerve descends through the pterygopalatine canal, emerging on the hard palate through the greater palatine foramen (which is usually located about 1 cm toward the palatal midline, just distal to the

second molar). The nerve courses anteriorly between the mucoperiosteum and the osseous hard palate, supplying sensory innervation to the palatal soft tissues and bone as far anterior as the first premolar, where it communicates with terminal fibers of the nasopalatine nerve.

The posterior superior alveolar (PSA) nerve descends from the main trunk of the maxillary division in the pterygopalatine fossa. Commonly there are two PSA branches, but on occasion, a single trunk arises. When two trunks are present, one remains external to the bone, continuing downward on the posterior surface of the maxilla to provide sensory innervation to the buccal gingiva in the maxillary molar region. Whereas the other branch enters into the maxilla through the PSA canal to travel down the posterior wall of the maxillary sinus, providing sensory innervation to the mucous membrane of the sinus. Continuing downward, this second branch of the PSA nerve provides sensory innervation to the alveoli, periodontal ligaments, and pulpal tissues of the maxillary third, second, and first molars (with the exception [in 28% of patients] of the mesiobuccal root of the first molar).

Branches originating within the infraorbital canal

Within the infraorbital canal, the maxillary division (V2) gives off two branches of significance in dentistry: the middle superior and anterior superior alveolar nerves.

The middle superior alveolar (MSA) nerve provides sensory innervation to the two maxillary premolars and, perhaps, to the mesiobuccal root of the first molar and periodontal tissues, buccal soft tissue, and bone in the premolar region. Traditionally it has been stated that the MSA nerve is absent in 30% to 54% of individuals. In its absence, its usual innervations are provided by either the posterior

superior alveolar (PSA) or the anterior superior alveolar (ASA) nerve; most frequently the latter.

The ASA nerve, a relatively large branch, descending within the anterior wall of the maxillary sinus, it provides pulpal innervation to the central and lateral incisors and the canine, and sensory innervation to the periodontal tissues, buccal bone, and mucous membranes of these teeth.

Summary

The following is a summary of the branches of the maxillary division (only those of special significance in dental pain control):

1. Branches originating within the pterygopalatine fossa

a. Nasopalatine nerve

b. Greater palatine nerve

c. Posterior superior alveolar nerve

2. Branches originating within the infraorbital canal

a. Middle superior alveolar nerve

b. Anterior superior alveolar nerve

Mandibular Division (V3)

The mandibular division is the largest branch of the trigeminal nerve. It is a mixed nerve with two roots: a large sensory root and a smaller motor root. The two roots emerge from the cranium separately through the foramen ovale, the motor root lying medial to the sensory. They unite just outside the skull and form the main trunk of the third division. This trunk remains undivided for only 2 to 3 mm before it splits into a small anterior and a large posterior division. The areas innervated by V3 are included in the following outline:

Sensory root:

1. Skin of the temporal region, auricle, external auditory meatus, cheek, lower lip, and the lower part of the face (chin region).

2. Mucous membrane of the cheek and the tongue (anterior two thirds).

3. Mandibular teeth and periodontal tissues.

4. Bone of the mandible.

5. Temporomandibular joint.

6. Parotid gland.

Motor root: Motor fibers of the trigeminal nerve supply the following muscles:

1. Masticatory muscles

a. Masseter

b. Temporalis

c. Medial Pterygoid

d. Lateral Pterygoid

2. Mylohyoid

3. Anterior belly of the digastric

4. Tensor tympani

5. Tensor veli palatine

Branches from the Undivided Nerve

The main undivided nerve trunk gives off two branches during its 2- to 3-mm course. These are the nervus spinosus (a meningeal branch of the mandibular nerve) and the medial pterygoid nerve. The medial pterygoid nerve is a motor nerve to the medial pterygoid muscle. It gives off small branches that are a motor to the tensor veli palatini and the tensor tympani.

Branches from the Anterior Division

Branches from the anterior division of V3 provide motor innervation to the muscles of mastication and sensory innervation to the mucous membrane of the cheek and the buccal mucous membrane of the mandibular molars. The anterior division is significantly smaller than the posterior.

Branches:

1. Deep temporal nerve (to the temporalis muscle).
2. Masseter nerve (to the masseter muscle).
3. Lateral pterygoid nerve (to the lateral pterygoid muscle).
4. The long buccal nerve (also known as the buccal nerve).

The long buccal nerve emerges under the anterior border of the masseter muscle, continuing in an anterolateral direction. At the level of the occlusal plane of the mandibular third or second molar, it crosses in front of the anterior border of the ramus and enters the cheek through the buccinator muscle. Sensory fibers are distributed to the skin of the cheek. Other fibers pass into the retromolar triangle, providing sensory innervation to the buccal gingiva of the mandibular molars and the mucobuccal fold in that region. The long buccal nerve does not innervate the buccinator muscle; the facial nerve does.

Branches of the Posterior Division

The posterior division of V3 is primarily sensory with a small motor component.

1. Auriculotemporal nerve.

2. Lingual nerve.

3. Inferior alveolar nerve.

4. Mylohyoid nerve.

The lingual nerve runs anterior and medial to the inferior alveolar nerve. It then continues downward and forward, deep to the pterygomandibular raphe to reach the side of the base of the tongue slightly below and behind the mandibular third molar. Here it lies just below the mucous membrane. It then proceeds anteriorly.

looping downward and medial to the submandibular (Wharton's) duct to the deep surface of the sublingual gland, where it breaks up into its terminal branches.

The lingual nerve is the sensory tract to:

1. The anterior two-thirds of the tongue. It provides both general sensation and gustation (taste) for this region. The nerve supplies fibers for general sensation, whereas the chorda tympani (a branch of the facial nerve) supplies fibers for taste.

2. The mucous membranes of the floor of the mouth.

3. The gingiva on the lingual side of the mandible.

The lingual nerve is the nerve most commonly associated with cases of paresthesia (prolonged or permanent sensory nerve damage).

The inferior alveolar nerve is the largest branch of the mandibular division. It enters the mandibular canal through the mandibular foramen. Throughout its path, it is accompanied by the inferior alveolar artery and

vein. The nerve, artery, and vein travel anteriorly in the mandibular canal as far forward as the mental foramen, where the nerve divides into its terminal branches: the incisive and mental nerves. Once the inferior alveolar nerve enters the mandibular canal, the dental plexus serves the mandibular posterior teeth, entering through their apices and providing pulpal innervation.

The incisive nerve remains within the mandibular canal and forms a nerve plexus that innervates the pulpal tissues of the mandibular second premolar (in most instances), first premolar, canine, and incisors via the dental branches.

The mental nerve exits the canal through the mental foramen and divides into three branches that innervate the skin of the chin and the skin and mucous membrane of the lower lip.

 Bifid inferior alveolar nerves and mandibular canals have been observed radiographically in about 0.95% of people. The bifid mandibular canal is clinically significant in that it increases the difficulty of achieving adequate anesthesia in the mandible through conventional techniques.

The mylohyoid nerve branches from the inferior alveolar nerve before entry of the latter into the mandibular canal. It supplies the mylohyoid muscle. It also may provide sensory innervation to the mandibular incisors and molars in some persons (usually the mesial root of the mandibular first molar).

Osteology:

In addition to the neuroanatomy of pain control in dentistry, one should be aware of the relationship of these nerves to the osseous and soft tissues through which they course.

Maxilla:

- The maxilla has a series of eminences that correspond to the roots of the maxillary teeth. The most prominent usually is found over the canine tooth and is often referred to as the canine eminence. Superior to the canine fossa (located just distal to the canine eminence) is the infraorbital foramen.
- Bone in the region of the maxillary teeth is more porous than mandible leading to a significantly greater incidence of clinically adequate anesthesia.
- The palatal processes of the maxilla form the anterior three-fourths of the hard palate. While the horizontal plate of the palatine bone forms the posterior fourth. Along its lateral border, at the junction with the alveolar process, is a groove through which the greater palatine nerve passes from the greater palatine foramen.
- In the midline in the anterior region is the funnel-shaped opening of the incisive foramen, through which the nasopalatine nerves emerge.
- A fine suture line extends laterally from the incisive foramen to the canine teeth. The area anterior to this suture is termed the premaxilla.

Mandible:

- The buccal cortical plate of the mandible is sufficiently dense to preclude effective infiltration of anesthesia. The bone in the anterior region (incisors) is usually less dense than that over the posterior teeth, permitting infiltration anesthesia to be employed. Bone along the lingual surface of the mandible usually is dense.

- In the region of the second premolar, midway between the upper and lower borders of the body lies the mental foramen.
- Sometimes lingual foramina are located in the posterior (molar) region. Some of which may contain sensory fibers from the mylohyoid nerve that innervate portions of mandibular molars.
- The mandibular foramen, located about two-thirds the distance from the anterior border of the ramus to its posterior border. The height of mandibular foramen varies greatly, ranging from 1 to 19 mm above the level of the occlusal plane.