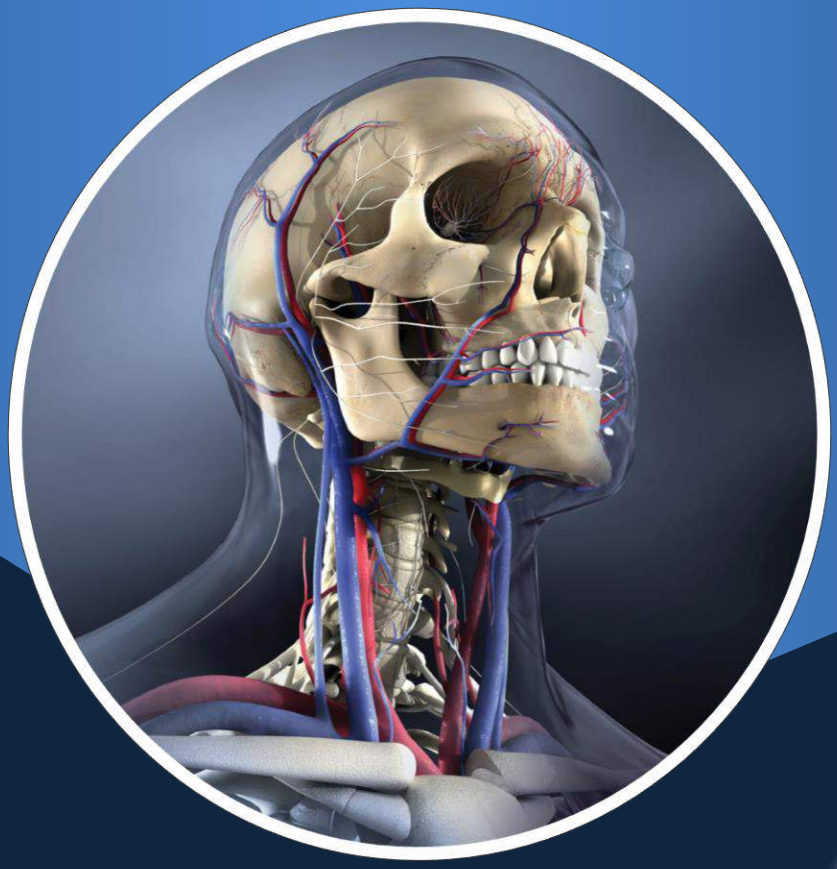

Oral Surgery

Third Stage

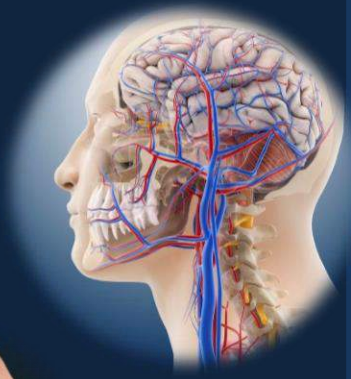





Zaid A. Abdullah

B.D.S., MSc

Zaid A. Abdullah
B.D.S., MSc

Lecture 5

Basic Techniques of Dental Local Anesthesia

A variety of techniques used in administration and deposition of local anesthesia:

1. Topical anesthesia
2. Infiltration anesthesia
3. Field block anesthesia
4. Regional block anesthesia

Selection of the technique depends on the area and the type of the surgery. In general, the infiltration anesthesia used for the maxilla and the anterior portion of the mandible, while nerve block is indicated for the posterior portion of the mandible.

A- Topical or Surface Anesthesia

Small terminal nerves in the surface area of the intact mucosa or the skin (superficial nerve ending) up to the depth of about 2 mm are anesthetized by application of topical anesthetic agent directly to the area.

This method commonly used to:

1. Obtain anesthesia of mucosa prior to injection, making the insertion of the needle less painful.
2. Prior to carrying out incision and drainage of abscesses.
3. Prior to suture removal.

Examples of topical anesthesia's preparation:

Lidocaine Spray: The active ingredient is 10% or 15% lidocaine hydrochloride in a water base, which have rapid onset (1 minute), and the duration of anesthesia is approximately 10 minutes.

Ointments: containing 5 % lidocaine hydrochloride, it takes 3 – 4 minutes to produce surface anesthesia.

Ethyl chloride spray: when sprayed on to either skin or mucosa, quickly produces anesthesia by refrigeration. This technique is of limited value but it occasionally used to produce surface anesthesia prior to the incision of fluctuant abscesses.

B- Infiltration Anesthesia

In this method, the anesthetic solution **deposited near the terminal fibers** of any nerve. It will infiltrate through the tissue to reach the nerve fibers and thus produce anesthesia of the localized area served by them.

The maxilla has thin labial / buccal cortical plate, shows sites of porosity, which aid in the absorption of the local anesthetic solution. These factors, therefore, make the maxilla more favorable for infiltration anesthesia. The mandibular bone is generally dense and has thicker cortical plates than the maxilla, particularly in the posterior region, so only the anterior part of the mandible presents sufficient porosity, which is favorable for the infiltration.

Advantages:

1. Easy and simple injection
2. Very high success rate
3. Good control of bleeding

Disadvantage: its action is limited to a small area; hence, a considerable amount of solution has to be injected with multiple penetrations when large field is to be anesthetized.

Technique: the recommended gauge of the needle is 25-30 and the recommended length is 25 mm. the bevel of the needle should be facing

the bone. The needle is inserted in the middle of the area to be operated and the point of the needle insertion is at an angle of 45 degrees to the long axis of the tooth to be anesthetized. The depth of penetration is beneath the mucous membrane into the connective tissue. This technique may require more than one needle insertions depending on the extent of the area to be anesthetized, care should be taken to avoid injury to the tissue in the following ways:

1. Avoid injecting the solution too rapidly.

2. Avoid injecting too large volume of the local anesthetic solution.

3. Avoid injecting too superficially.

These situations will result in injury to the tissue in the form of pain at the time of injection, or persistent post – injection pain.

Types of infiltration anesthesia

Based on deposition site, this technique includes:

1. **Sub-mucous injection:** the solution deposited just beneath the mucous membrane; the solution diffuses through the interstitial tissue and reaches the terminal fibers of the nerve in the area of deposition. This technique is unlikely to produce anesthesia of the dental pulp it is often employed to anesthetize the long buccal nerve prior to the extraction of mandibular molars or for soft tissue surgery.

2. **Supra-periosteal injection:** in some sites, such as maxilla, the outer cortical plate of alveolar bone is thin and perforated by tiny vascular canals. In these areas when the anesthetic solution is deposited outside the periosteum. It will infiltrate through the periosteum, cortical plate and medullary bone to the nerve fibers. By this means, anesthesia of the dental pulp can be obtained by injecting near the tooth apex. The supra-periosteal injection is the technique most frequently used in dentistry.

3. **Sub-periosteal injection:** the solution is deposited between the periosteum and the cortical plate. This technique is painful since the periosteum is firmly attached to the cortical plate.

C- Field Block

Local anesthetic is deposited **near the larger terminal** nerve branches so the anesthetized area will be circumscribed. Incision (or treatment) is then made into an area away from the site of injection of the anesthetic. Maxillary injections administered above the apex of the tooth to be treated are properly termed field blocks (although common usage identifies them as infiltration).

D- Regional block anesthesia

In this technique, the anesthetic solution deposited near the main nerve trunk, usually at a distance from the site of the surgical procedure and this will lead to blocking all impulses and produce anesthesia of the area supplied by that nerve. Example: by placing the anesthetic solution in the pterygomandibular space, near the mandibular foramen, regional block anesthesia over the whole distribution of the inferior alveolar nerve on that side is obtained.

Local anesthesia in the maxilla

❖ Anesthesia for the upper molar teeth

The pulps of the upper molars with the exception of the mesiobuccal root of the first molar are innervated by the posterior superior alveolar nerve. This nerve is also responsible for innervations of the alveolar bone, buccal gingiva in the molar region and the mucoperiosteum attached to them. Infiltration technique as follows:

1. Hold the syringe at an angle of 45 degrees with the long axis of the tooth to be anesthetized, with the bevel of the needle facing the bone.

2. Insert the needle into the mucobuccal fold over the target tooth.

3. Advance the needle for few millimeters.

4. Inject slowly, slowly withdraw the syringe and cover the needle.

5. Wait for 2-3 minutes, check for the sign and symptoms of anesthesia, and start the procedure.

❖ Posterior superior alveolar nerve block

The local anesthetic solution is deposited close to the posterior superior alveolar nerve after it leaves its bony canal.

Technique:

1. partially open the patient's mouth

2. retract the patient's cheek with your finger

3. insert the needle into the height of the mucobuccal fold opposite to the distal surface of the maxillary second molar

4. advance the needle in upward, inward and backward direction.

5. deposit 1-2 ml of the anesthetic solution

One of the disadvantages of this technique is the possibility of **damaging the pterygoid venous plexus** and the risk of hematoma formation.

❖ **Anesthesia of the upper premolar teeth:**

The mesiobuccal root of the upper first molar, both premolars, and buccal supporting tissue and mucoperiosteum related to them are innervated via the middle superior alveolar nerve. Infiltration technique is usually employed to anesthetize these structures.

❖ **Anesthesia of the upper anterior teeth:**

The upper canine, central and lateral incisors, labial supporting tissue and mucoperiosteum related to them are innervated via anterior superior alveolar never. Infiltration technique is usually employed to anesthetize these structures.

❖ **Anesthesia of the palatal tissue**

Anesthesia of the posterior portion of the palate could be achieved by infiltration technique (the solution is deposited in the palatal tissue about half way between the midline and the gingival margin of the target tooth at an angle of 45 to the bony surface), or by using greater palatine nerve block (the solution is deposited near the greater palatine foramen, located just distal to the maxillary second molar about 1 cm toward the midline).

Local infiltration of the palate will anesthetize the palatal soft and hard tissues. Anesthesia of the anterior portion of the palate could be achieved by infiltration technique, just next to the target tooth, or by nasopalatine nerve block, where the solution is deposited near the incisive foramen (located in the midline of the palate about 1 cm posterior to the maxillary central incisors).

The palatal mucoperiosteum is firm in consistency and is closely adapted to the bone, making the injection of the local anesthetic solution performed under great pressure. This may be minimized by inserting the needle with the bevel facing the bone. If the bevel faces away from bone, the sharp point of the needle would contact the periosteum, tearing it and leading to a more painful (subperiosteal) injection. Post-injection discomfort is considerably greater with subperiosteal than with supraperiosteal injections.

The **palatal injection is painful**, so it is advisable to inform the patient prior to injection. When the needle touches the bone, gently, withdraw the needle by 1 mm (to avoid painful subperiosteal injection) and deposit about 0.25 – 0.5 ml of the solution in the area to be anesthetized, withdraw the needle slowly.

❖ **The infra-orbital nerve block injection:**

This technique is **rarely used since the infiltration techniques are so effective in the maxilla,** however, it may be of value if numerous extractions or extensive surgery are to be undertaken in the maxillary incisor and canine regions. It may also be employed for anesthetizing an anterior tooth where the use of infiltration technique is precluded by the presence of infection at the site of injection.

The solution deposited at the orifice of the infra-orbital foramen passes along the canal. The ASA, MSA and the infraorbital nerve with its terminal branches will be anesthetized. The technique is performed Intra-orally. The infraorbital foramen site is palpated, the upper lip is reflected and the tip of a long needle is inserted into the height of the mucobuccal fold over the first molar with the bevel facing the bone. The needle is advanced in line with the long axis of this tooth to a depth of 1.5 – 2 cm

then 1 ml of anesthetic solution is given which is enough in most instances. The extra-oral approach is rarely used and involve direct injection through the skin to the foramen.

❖ **Maxillary nerve block**

The maxillary nerve and all its branches will be anesthetized. These blocks are used for achieving anesthesia of half of the maxilla in extensive surgery. This technique could be used for diagnostic or therapeutic purposes such as trigeminal neuralgia of the maxillary division of the fifth cranial nerve.

Local anesthesia in the mandible

❖ **Anesthesia of the lower anterior teeth**

The lower anterior teeth are supplied by the terminal branch of the inferior alveolar nerve (incisive nerve). Fortunately, the labial alveolar plate in this region is thinner and more porous than elsewhere in the mandible and because of that, the infiltration technique could be used in this area. This is achieved by deposition of about 1 ml of the solution in the labial sulcus adjacent to the target tooth to anesthetize the pulp and labial supporting tissues.

❖ **Anesthesia of the lower premolars and molars**

To extract the lower premolar and molars we should anesthetize the inferior alveolar nerve (supply the pulp of these teeth with their periodontium and the bony socket), the lingual nerve (supply the lingual soft tissue adjacent to them) and the long buccal nerve (supply the buccal soft tissue).

In children, **multiple vascular canals** **perforate** the thin labial/buccal alveolar plate. For this reason, **infiltration techniques** are **highly effective** in producing anesthesia of upper and lower deciduous teeth. Care should be taken to avoid the misjudging the length of the roots and inserting the needle too deeply into the tissue.

❖ **Inferior alveolar nerve block**

The IAN, along with its terminal branches (incisive and mental nerves) are anesthetized by this technique (anesthesia of the pulp of all mandibular teeth in the same side of injection, the skin of the chin and the skin and mucosa of the lower lip). This is achieved by the deposition of the solution around the mandibular foramen in the pterygomandibular space.

Boundaries of the pterygomandibular space

This space is bounded **anteriorly** by the **pterygomandibular raphe** and the **fibers of superior constrictor and buccinators muscles** that are inserted into it. **The posterior boundary** is formed by the **parotid gland.** The **ramus of the mandible** forms the **lateral wall** while the **medial pterygoid muscle** forms the medial wall. The **lateral pterygoid muscle** forms the **roof** of the space.

The inferior alveolar nerve block technique

The success of this technique is entirely dependent upon the accurate deposition of the solution; this technique will anesthetize the inferior alveolar nerve and its terminal branches.

Technique: the patient is seated in the chair and the headrest adjusted so that his mandibular occlusal plane is horizontal when the mouth is open. The dentist should stand in front of the patient for the right side nerve block and behind the patient for the left. The mouth should be opened

widely, the thumb of the free hand should rest on the coronoid notch and the pterygomandibular raphe should then be identified (thick soft tissue band originated from the pterygoid hamulus and inserted on the lingual aspect of the mandible in the third molar region).

The syringe should be introduced from the lower premolar teeth of the other side parallel to and 0.5-1 cm above the lower occlusal plane such that the needle penetrates laterally to the pterygomandibular raphe. The long dental needle should be advanced about 2-2.5 cm until the bone is touched lightly, the needle should then be withdrawn a millimeter or two, the local anesthetic should then be deposited slowly using most of the cartridge's solution.

The local anesthesia is deposited to the inferior alveolar nerve as it enters the mandibular foramen on the medial aspect of the ramus. The lingual nerve, which lies anteromedial to the inferior alveolar nerve is anesthetized by slowly withdrawing the syringe until approximately half the needle's length remains within the tissue, deposit few drops of the solution. The onset of the anesthesia is checked by a change of sensation in the lower lip and the tongue when compared with the other side and absence of pain during the procedure.

❖ **Long buccal nerve block**

The long buccal nerve provides sensory innervations to the buccal soft tissue adjacent to the mandibular molar teeth, vestibular mucosa and mucosa of the retromolar fossa. A long buccal nerve block is achieved by means of a sub-mucous injection in which the solution is deposited (few drops) just posterior and buccal to the last molar tooth in the arch (between the external and the internal oblique ridge). Infiltration

technique for the long buccal nerve is achieved by deposition of the solution in the muco-buccal fold adjacent to the target tooth.

❖ **The mental nerve block**

This block will anesthetize the pulp and periodontal membrane of the lower incisors, canine, first premolar and sometimes the second premolar (incisive nerve), labial mucous membrane anterior to the mental foramen and the skin of the chin and the skin and mucosa of the lower lip (mental nerve). In dentate patient, the mental foramen lies below and between apices of the lower premolar teeth, approximately halfway between the cervical margin of the teeth and the lower border of the mandible. The solution is deposited at or near the foramen (about 1 ml). In edentulous patients, the foramen may lie near the crest of the ridge because of bone resorption.

❖ **Mandibular nerve block**

The **entire mandibular** branch of the trigeminal nerve is anesthetized. The mandibular nerve could be blocked by

1. **Intra-oral approach** as in Gow-Gates mandibular nerve block and Akinosi (closed mouth) mandibular nerve block.

A. **Gow-Gates mandibular nerve block**

This technique is indicated when the **conventional inferior alveolar** nerve block is **unsuccessful**.

B. **Akinosi (closed mouth) mandibular nerve block**

It is indicated when there is **limited mandibular opening** and inability to visualize the landmarks for the inferior alveolar nerve block.

2. **Extra-oral mandibular** nerve block.

Extra-oral mandibular nerve block

This technique is indicated when there is an **acute infection** at the **site of injection** for the subdivisions of the mandibular nerve, when there is need to anesthetize the entire mandibular nerve and its branches with one single penetration and minimum amount of local anesthetic solution, and for diagnostic and therapeutic purposes as in trigeminal neuralgia.

Supplementary Injections

Sometimes these will produce local anesthesia where all other methods fail:

1. **Intra-ligamentary (periodontal) injection:** the local anesthetic solution is deposited into the periodontal ligament, using small amount of local anesthetic solution usually 0.2 ml delivered via a specifically designed system which comprises of high-pressure syringes and ultrafine needles. This technique can also be carried out by the conventional syringes; however, care should be exercised to avoid shattering of the glass cartridges. The single rooted tooth should be injected on the mesial and the distal sides while the multirooted teeth are injected over each root.

2. **Intrapulpal anesthesia:** put a cotton ball soaked in a local anesthetic solution in the cavity, wait for a minute and then a needle is inserted firmly directly into the pulp chamber or to the root canal.

3. **Intraosseous injection:** In this rarely used method, the local anesthetic solution is deposited directly into the cancellous bone adjacent to the tooth to be anesthetized. An incision is made in the mucosa and the periosteum, a small opening is made in the outer cortical layer of the bone. The needle is inserted into the opening created, and approximately

0.5–1 ml of solution is slowly injected under pressure. Anesthesia by the intraosseous method will not be of very long duration, possibly between 10 -20 minutes.

Speed of injection

Rapid injection of the solution may cause tissue distension and discomfort or actual cellular damage and pain when sensation returns, also the risk of toxic reactions is greater if a quantity of anesthetic solution is injected rapidly, a slow rate of injection is thus essential. In general, the ideal rate of injection is 1 mL/min.

Testing for anesthesia

Altered sensation in itself does not guarantee that anesthesia has been achieved, prior to extraction under local anesthesia a dental probe may be pushed into the gingival crevice on both the labio-buccal and the lingual surface of the tooth. The patient should be told that pressure might be felt and asked to state if sharpness is noted, the presence of sharpness is an indication of a further injection.