Sub mandibular region

PhD. Mustafa Fadhil
Hilla University College

Submandibular region

Area between mandible bone (superiorly) and hyoid bone (inferiorly).

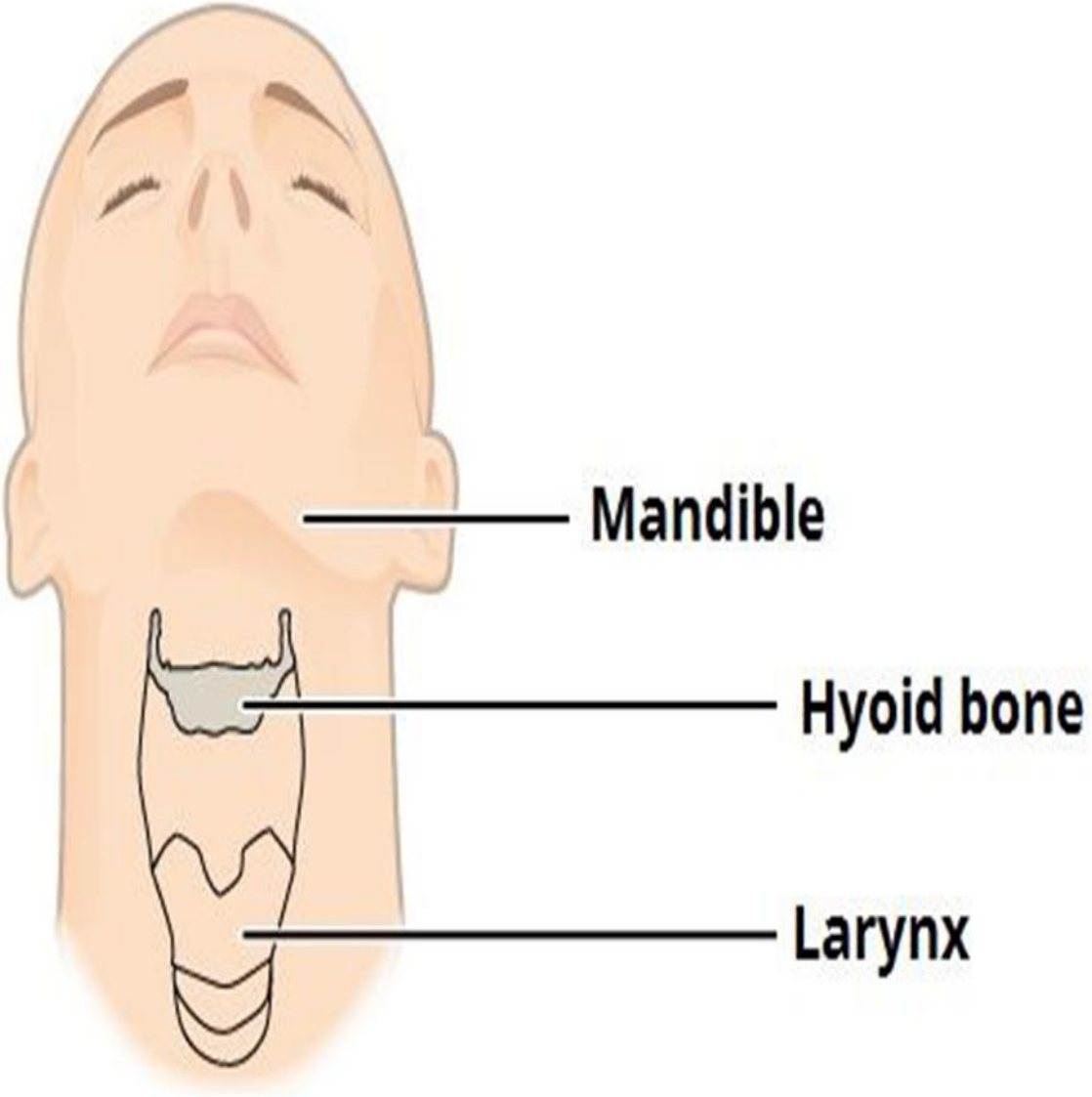

Submandibular region

The submandibular region lies under cover of the body of the mandible (between the mandible and the hyoid bone). It contains the following structures:

- **Muscles:** digastric, stylohyoid, mylohyoid, hyoglossus, geniohyoid, genioglossus, and styloglossus muscles.
- **Salivary glands:** submandibular and sublingual glands .
- **Nerves:** lingual, glossopharyngeal and hypoglossal nerves .
- **Parasympathetic ganglion:** submandibular.
- **Blood vessels:** facial artery with vein and lingual artery with vein.
- **Lymph nodes**: submandibular group.

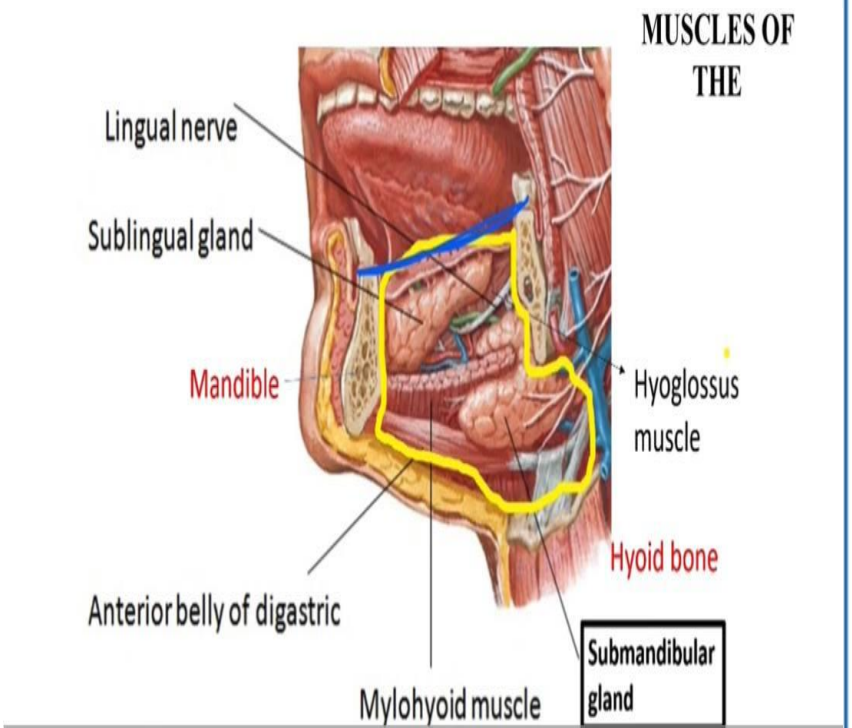

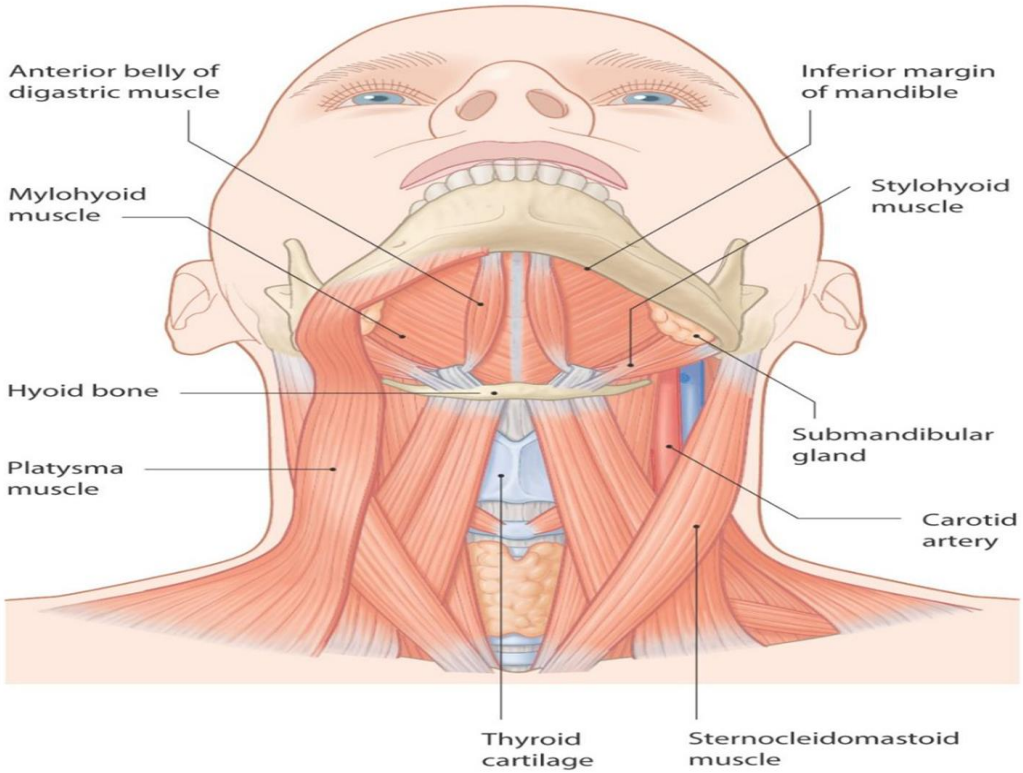

Muscle of submandibular region :

1. Digastric muscle

The digastric muscle has a posterior belly, intermediate tendon and anterior belly.

- **Origin and insertion:** The **posterior belly** arises from the medial surface of the mastoid process of the temporal bone, passes downward and forward across the carotid sheath and ends in the intermediate tendon. The **intermediate tendon** pierces يخترق the stylohyoid insertion and is held in position by a loop of deep fascia, which binds the tendon down to the junction of the body and greater cornu of the hyoid bone. The **anterior belly** runs forward and medially and is attached to the lower border of the body of the mandible near the median plane.
- **Nerve supply:** the **posterior belly** is supplied by the facial nerve while the **anterior belly** is supplied by the nerve to the mylohyoid which is a branch of the mandibular division of the trigeminal nerve.
- **Action:** depresses the mandible or elevates the hyoid bone.

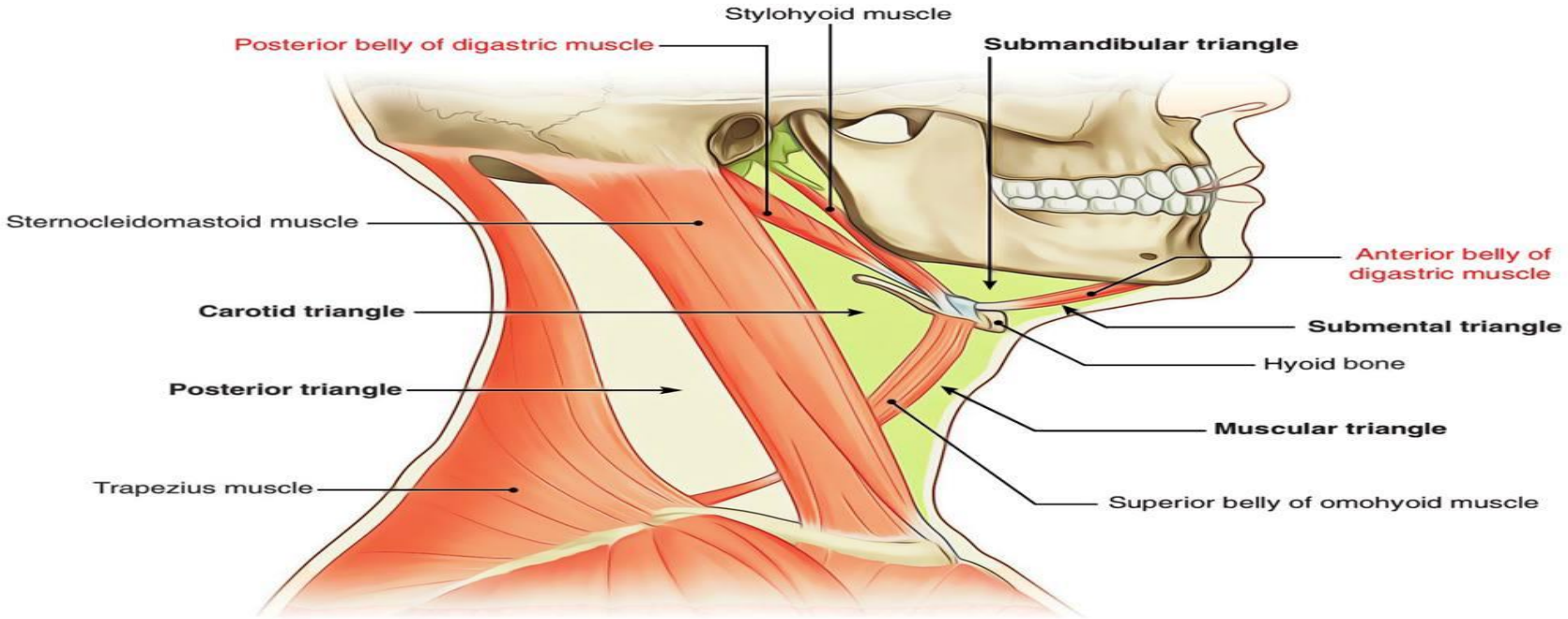

2. Stylohyoid muscle

The stylohyoid muscle is a small slip that passes along the upper border of the posterior belly of the digastric muscle.

- **Origin:** from the styloid process of the temporal bone.
- **Insertion:** the muscle passes downward and forward to inserted into the junction of the body with the greater cornu of the hyoid bone. It is pierced تخترق near its insertion by the intermediate tendon of the digastric muscle .
- **Nerve supply:** facial nerve.
- **Action:** elevates the hyoid bone.

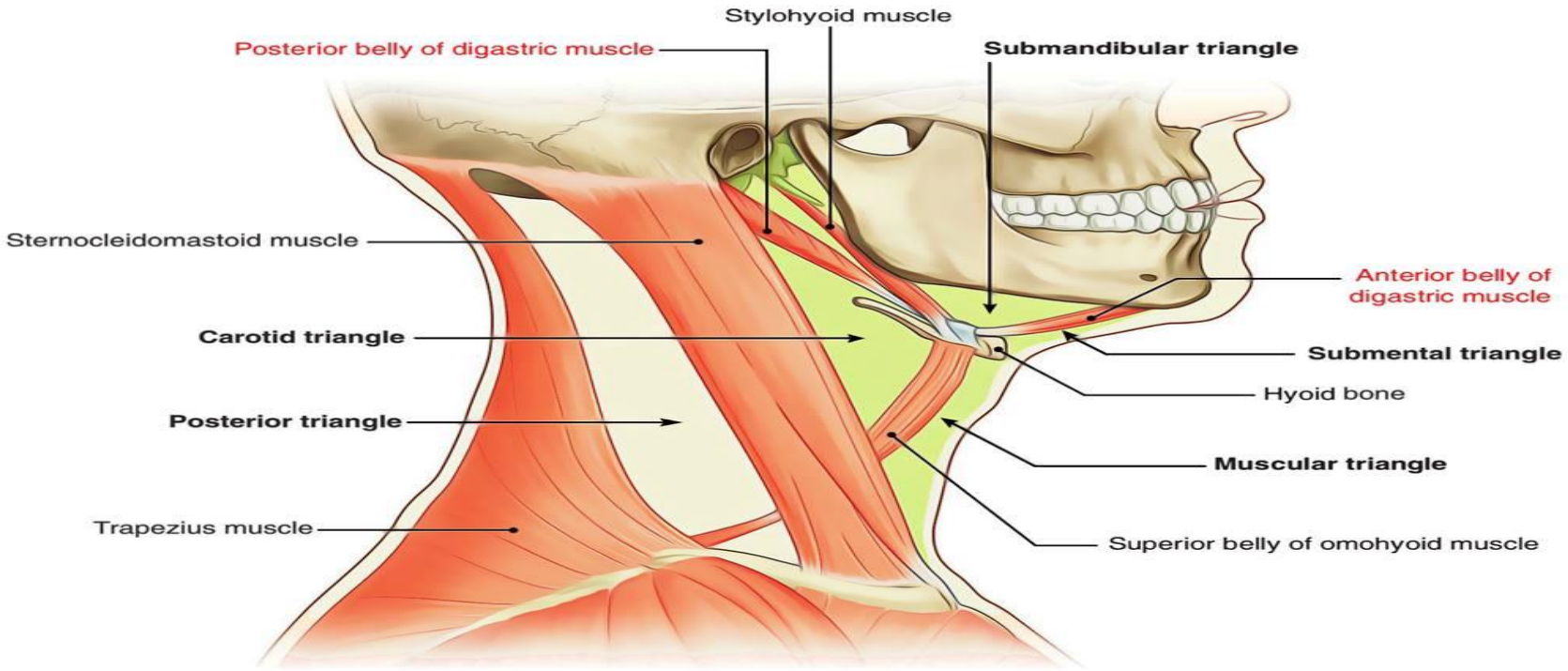

3. Mylohyoid muscle

- **Origin:** this flat, triangular sheet of muscle arises from the whole length of the mylohyoid line of the mandible.
- **Insertion:** the fibers run downward and forward. The **posterior fibers** are inserted into the body of the hyoid bone while the **anterior fibers** are inserted into a fibrous raphe, which extends from the symphysis menti to the body of the hyoid bone.
- **Nerve supply:** mylohyoid branch of the inferior alveolar nerve.
- **Action:** the two mylohyoid muscles form a muscular sheet that supports the tongue and the floor of the mouth. When the **mandible is fixed**, they elevate the floor of the mouth and the hyoid hone during the first stage of swallowing. When the **hyoid bone is fixed**, it assists in the depression of the mandible and the opening of the mouth.

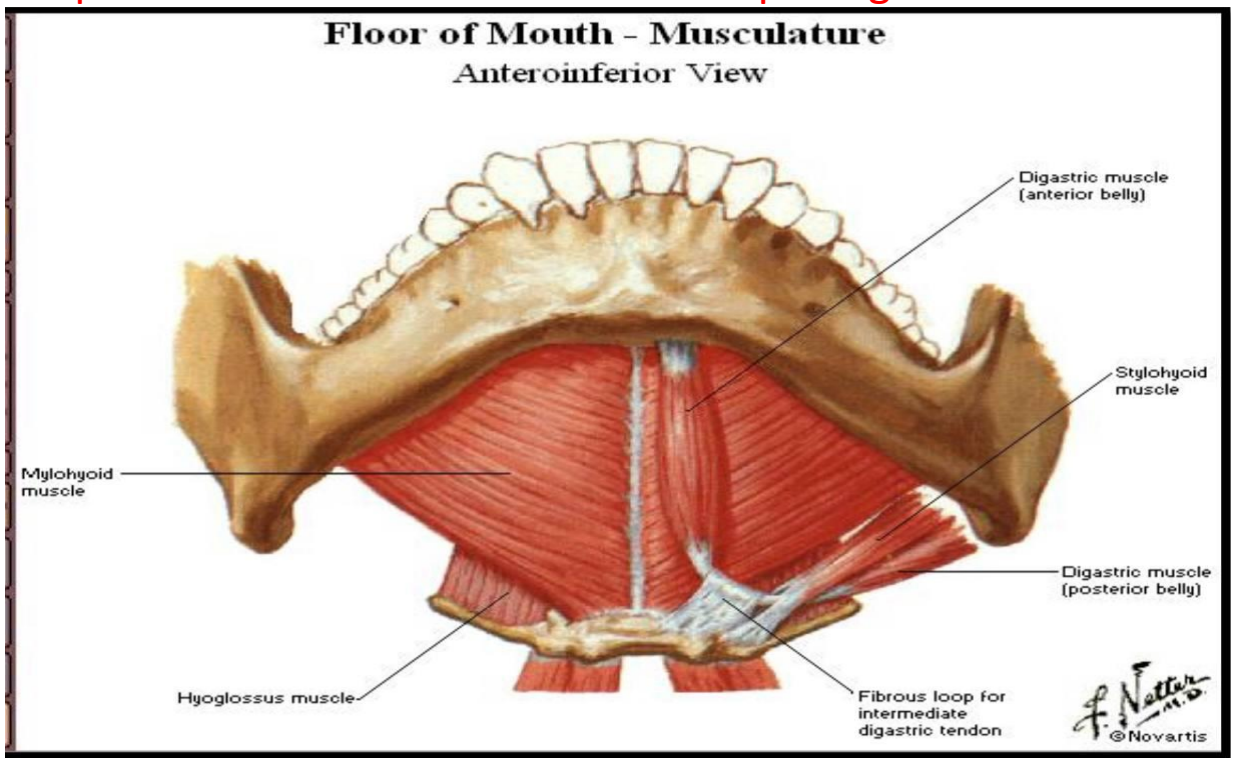

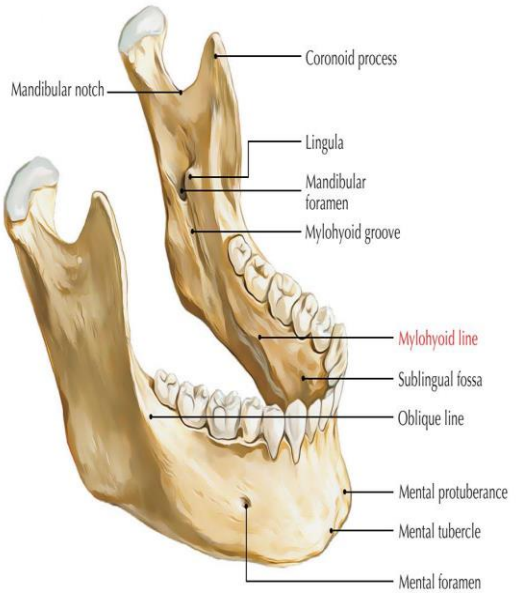

4. Hyoglossus muscle

- **Origin:** from the upper border of the body and greater cornu of the hyoid bone.
- **Insertion:** the muscle is quadrilateral and runs upward deep to the mylohyoid muscle to enter the side of the tongue. It ends when its fibers mix with those of other muscles of the tongue.
- **Nerve supply:** hypoglossal nerve.
- **Action:** depresses the tongue.

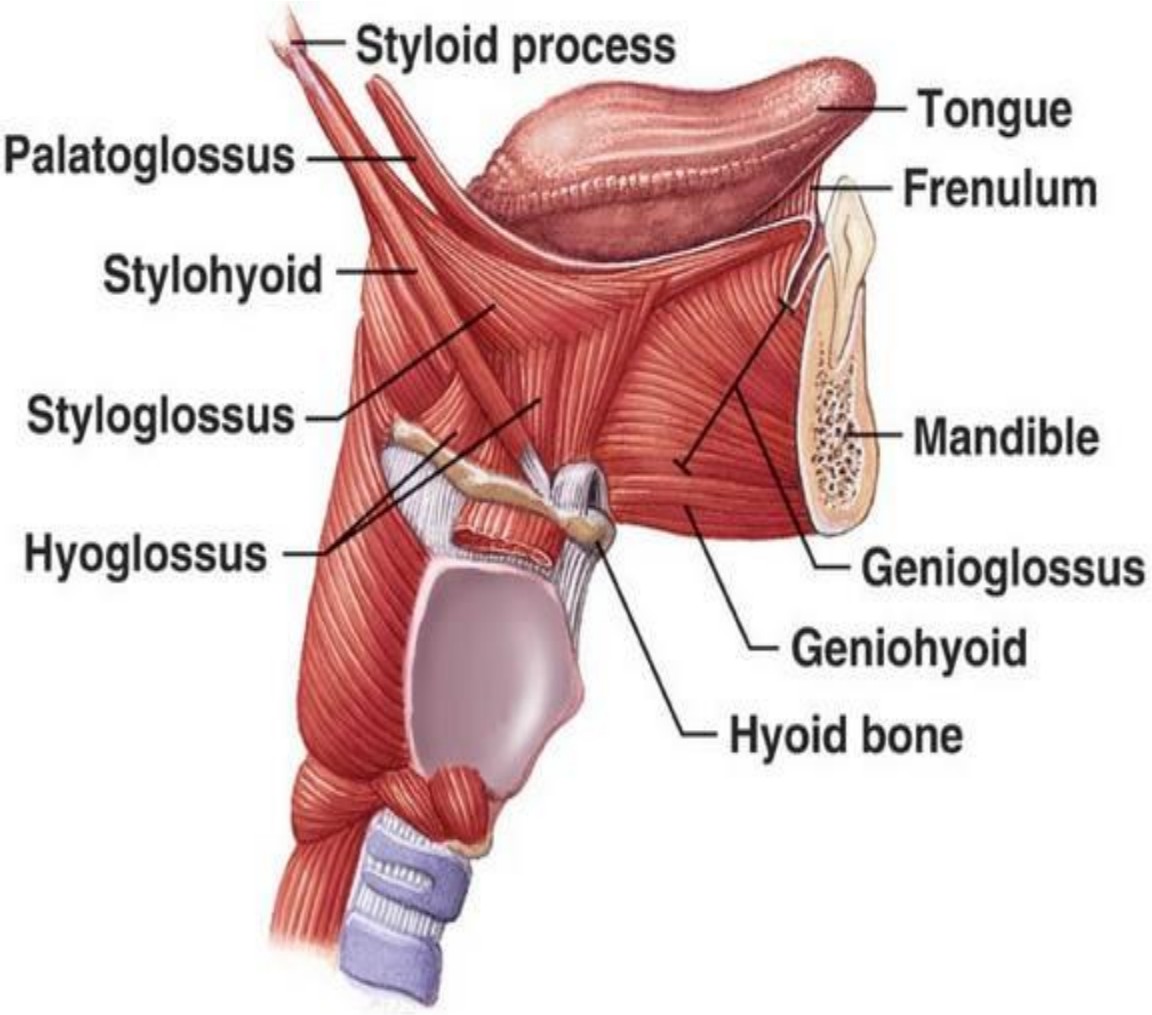

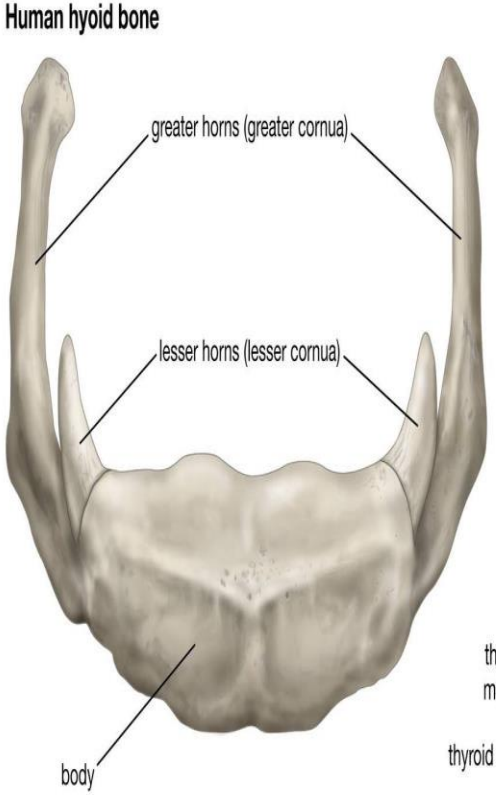

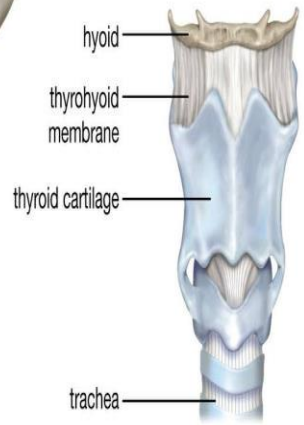

© Encyclopædia Britannica, Inc.

5. Geniohyoid muscle

- **Origin:** from the inferior mental spine behind the symphysis menti of the mandible.
- **Insertion:** it is a narrow muscle that lies above the mylohyoid and is inserted onto the anterior surface of the body of the hyoid bone. Its medial surface lies in contact with the corresponding muscle of the opposite side.
- **Nerve supply:** first cervical nerve through the hypoglossal nerve.
- **Action:** elevates the hyoid bone and draws it forward or depresses the mandible.

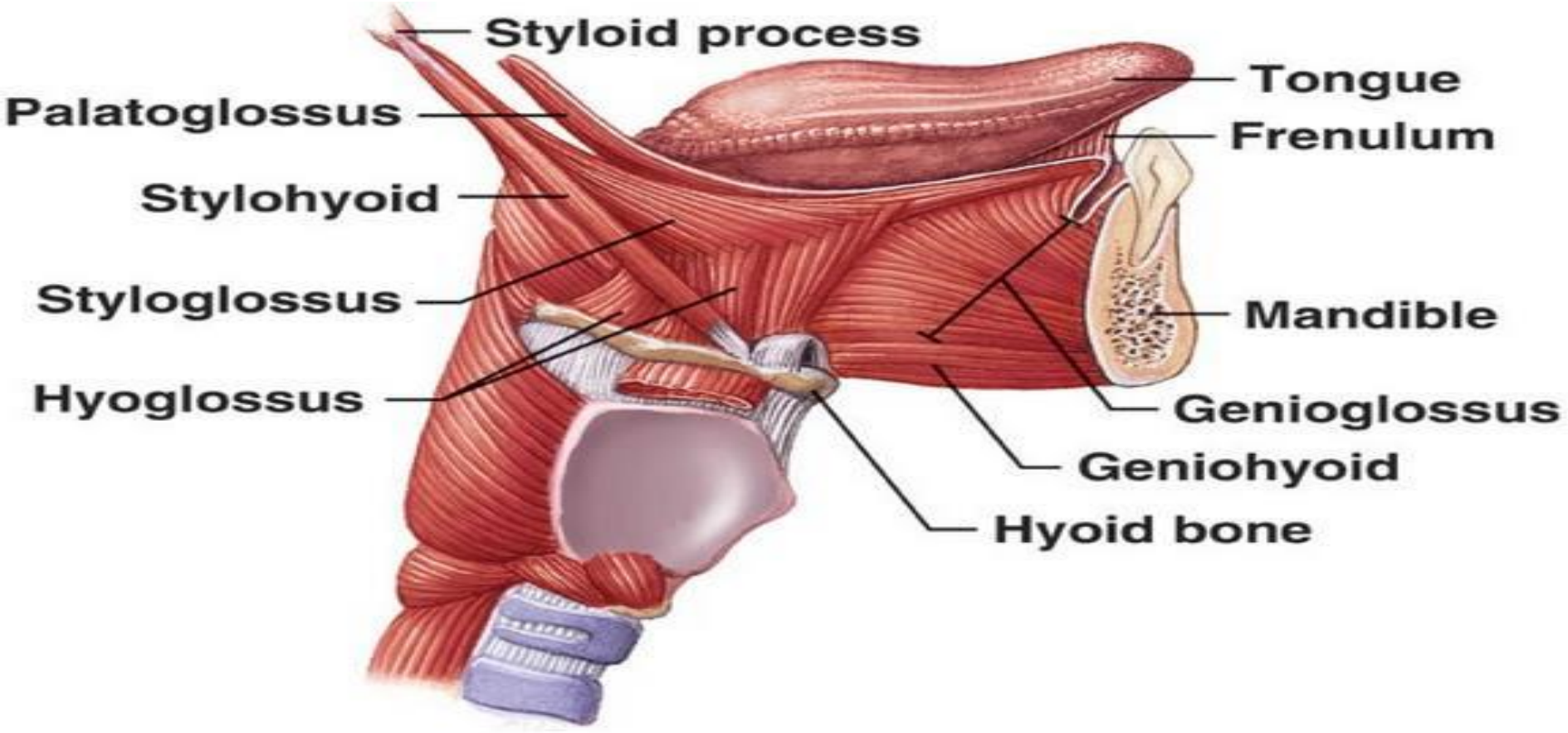

6. Genioglossus muscle :

- **Origin:** from the superior mental spine, behind the symphysis menti of the mandible .
- **Insertion:** this fan-shaped muscle widens as it extends backward into the tongue . The **superior fibers** pass to the tip of the tongue , **middle fibers** pass to the dorsum of the tongue and **a few of the inferior fibers** are attached to the body of the hyoid bone .
- **Nerve supply:** hypoglossal nerve.
- **Action:** draws the tongue forward and protrudes the tip so that it points to the opposite side, the two muscles acting in unison protrude the tongue in the midline.

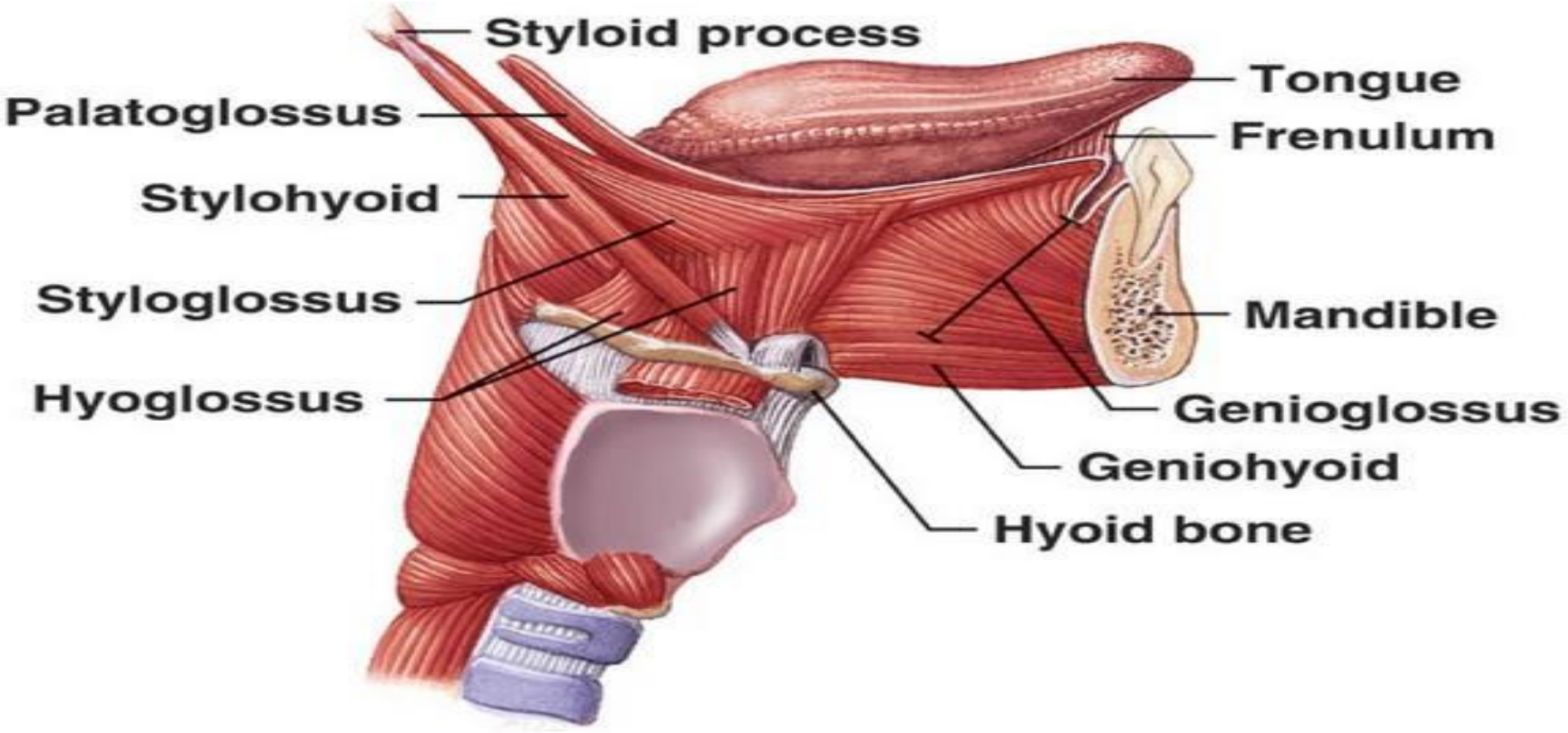

7. Styloglossus muscle:

- **Origin:** from the styloid process.
- **Insertion:** the fibers run downward and forward on the lateral surface of the superior constrictor muscle. On reaching the interval between the superior and middle constrictor muscles, the styloglossus passes forward to enter the side of the tongue.
- **Nerve supply:** hypoglossal nerve.
- **Action:** draws the tongue upward and backward.

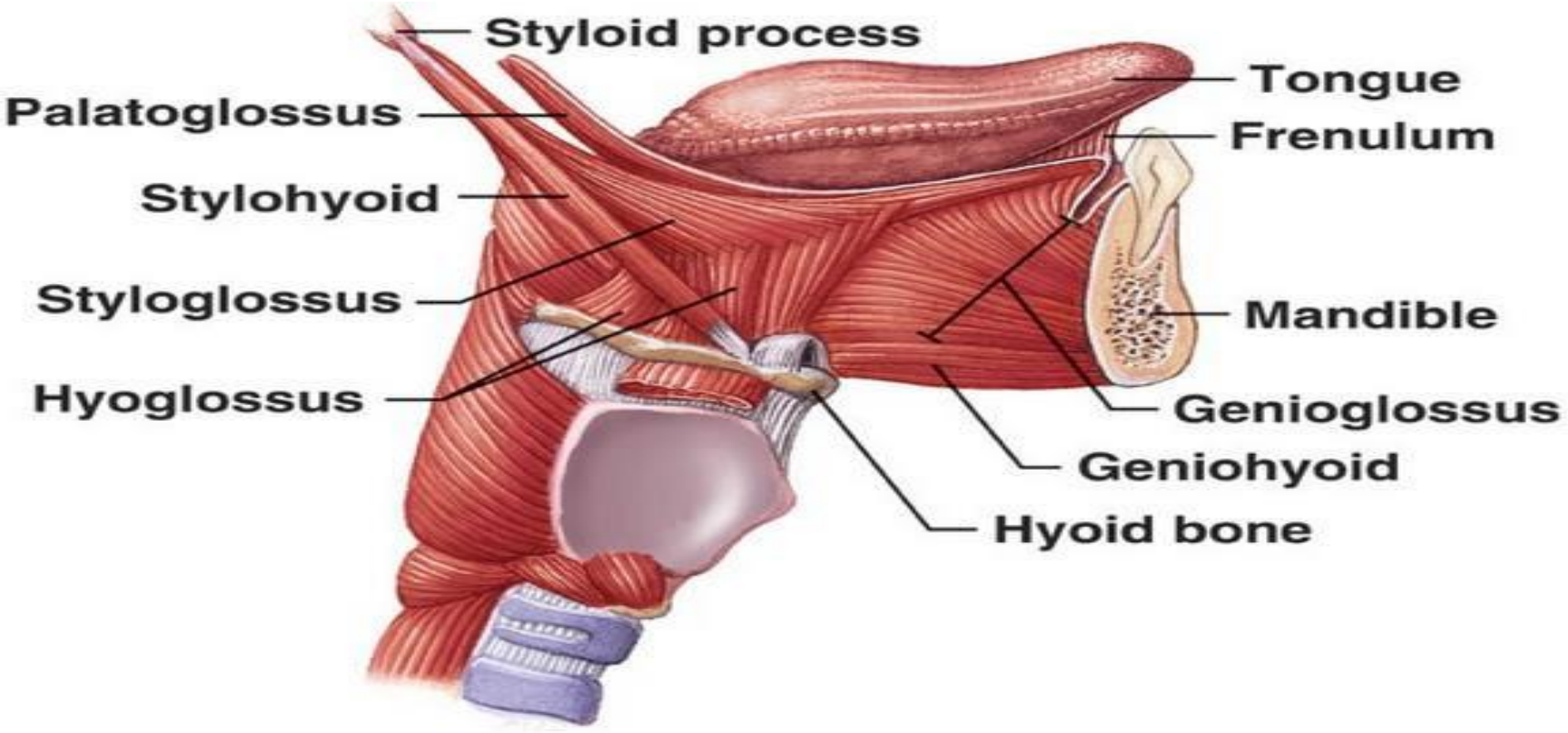

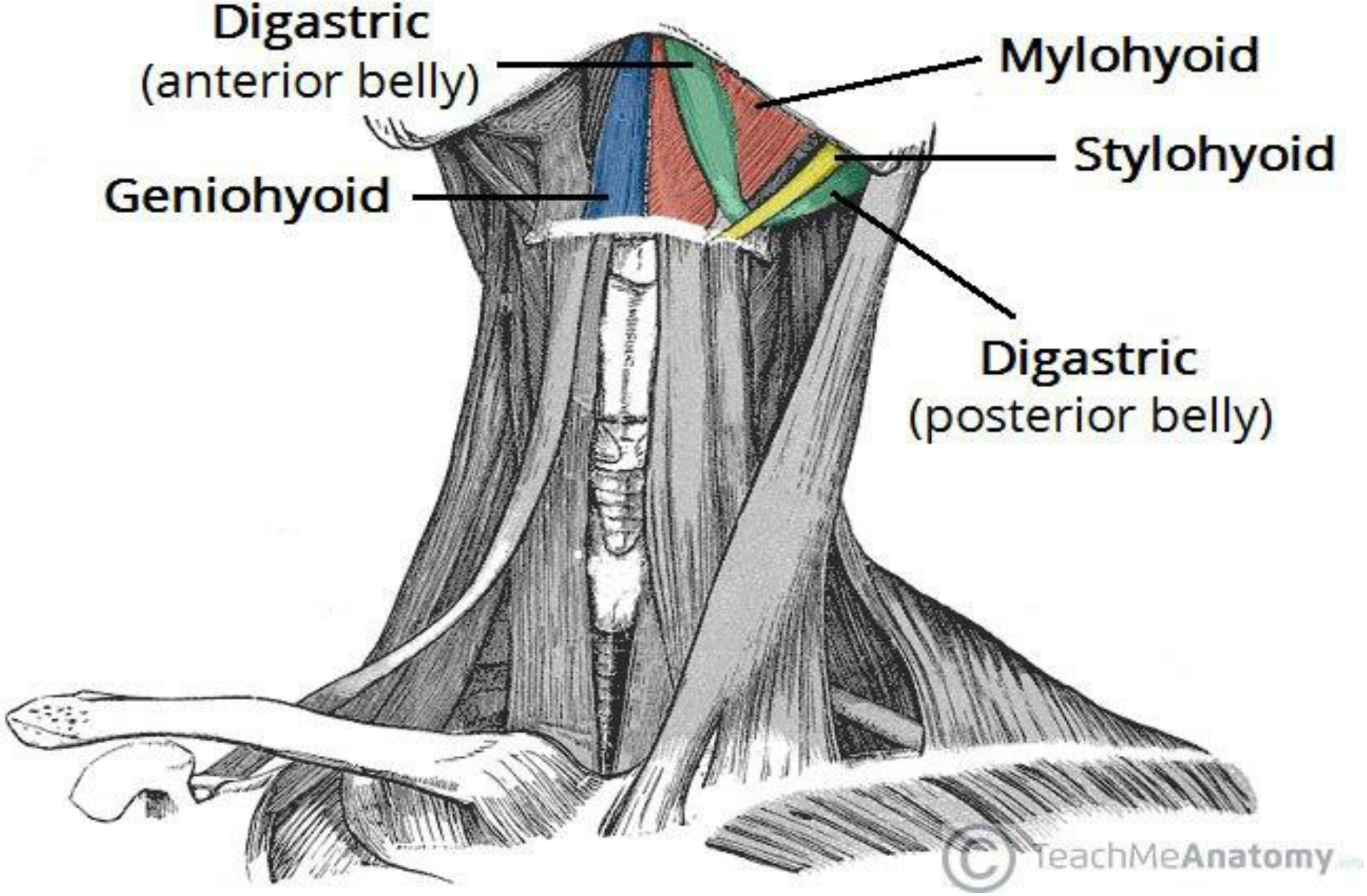
Digastric
(anterior belly)
Mylohyoid
Stylohyoid
Geniohyoid
Digastric
(posterior belly)
TeachMeAnatomy

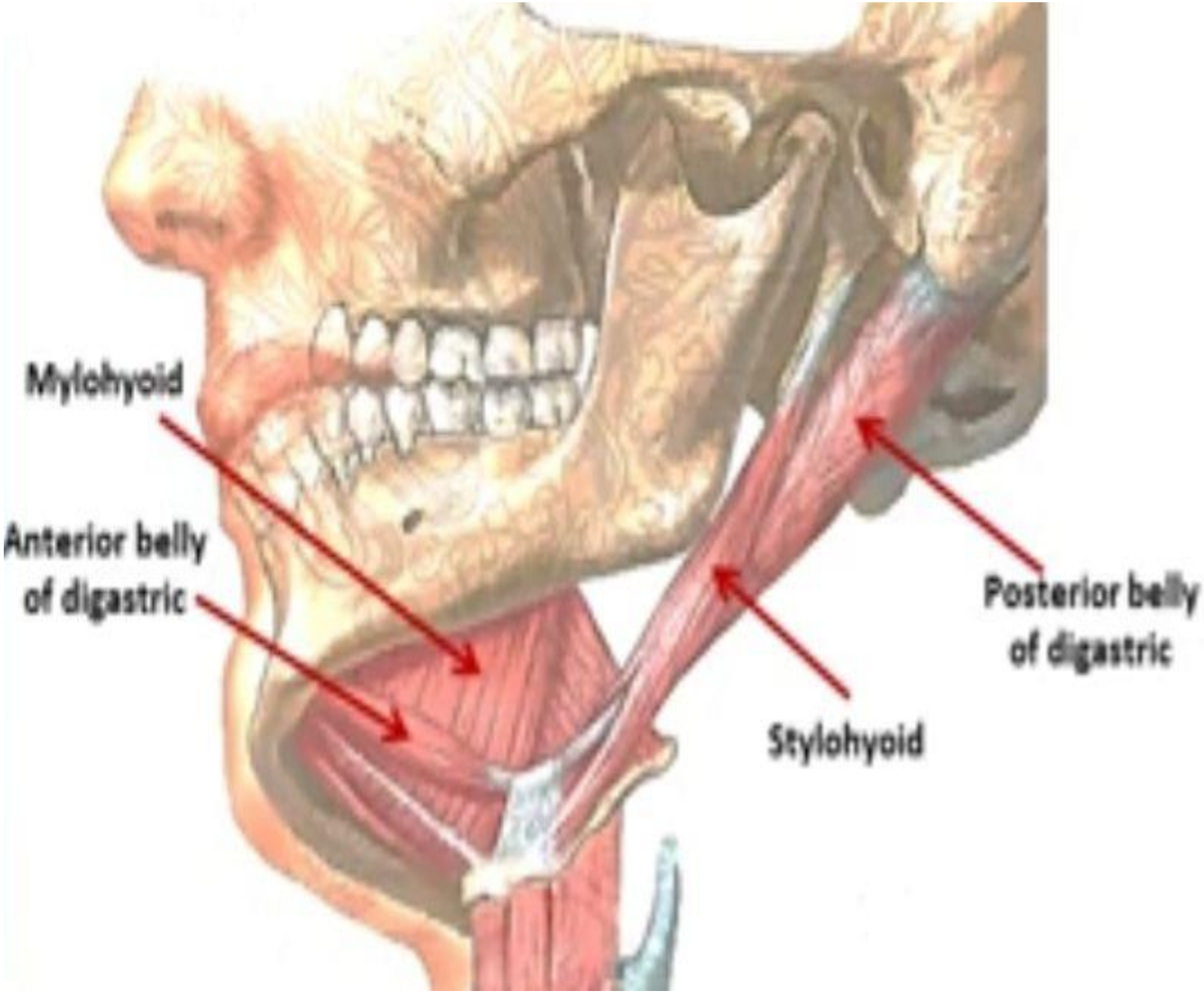
Mylohyoid
Anterior belly of digastric
Posterior belly of digastric
Stylohyoid

(a) Anterior view

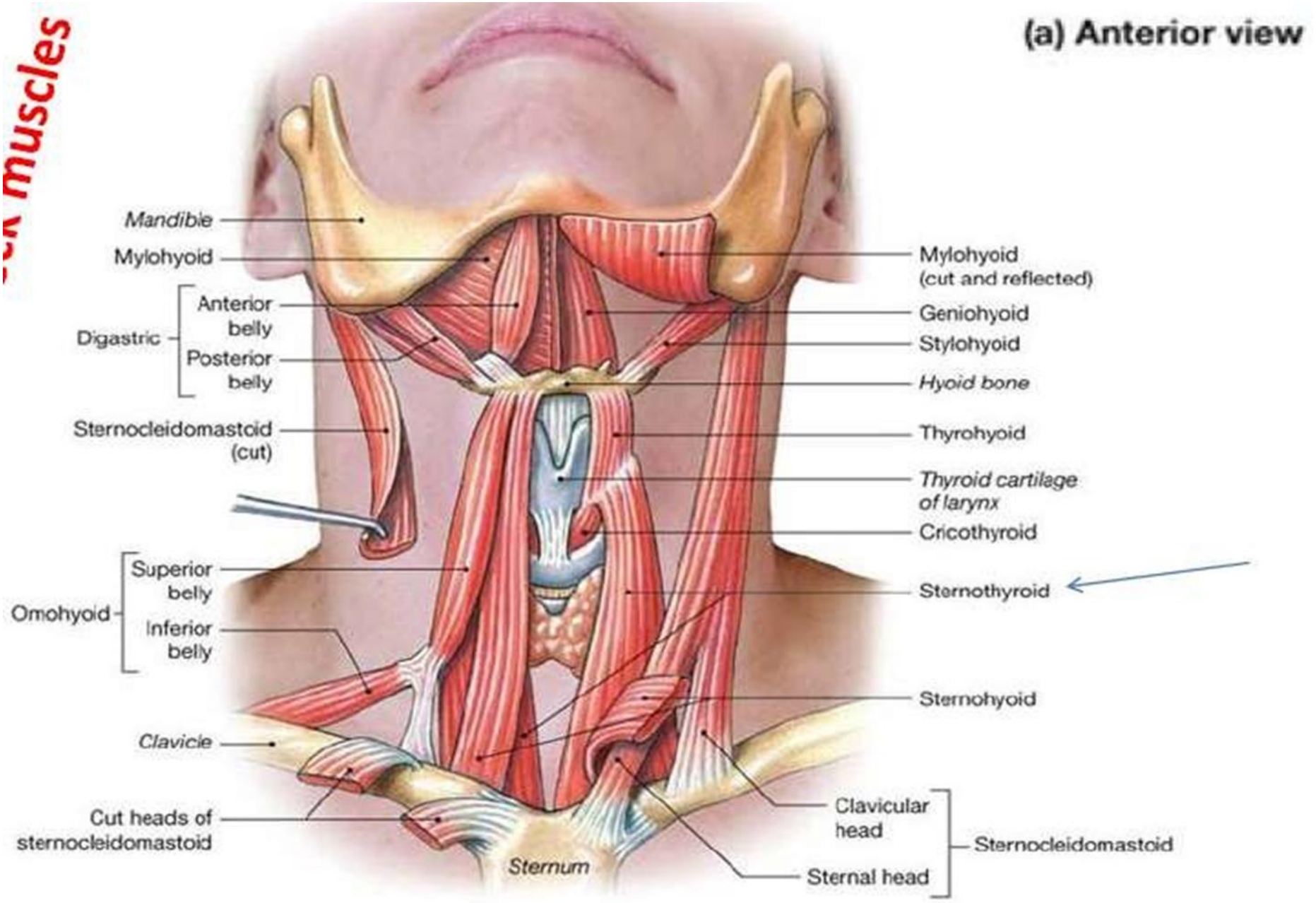

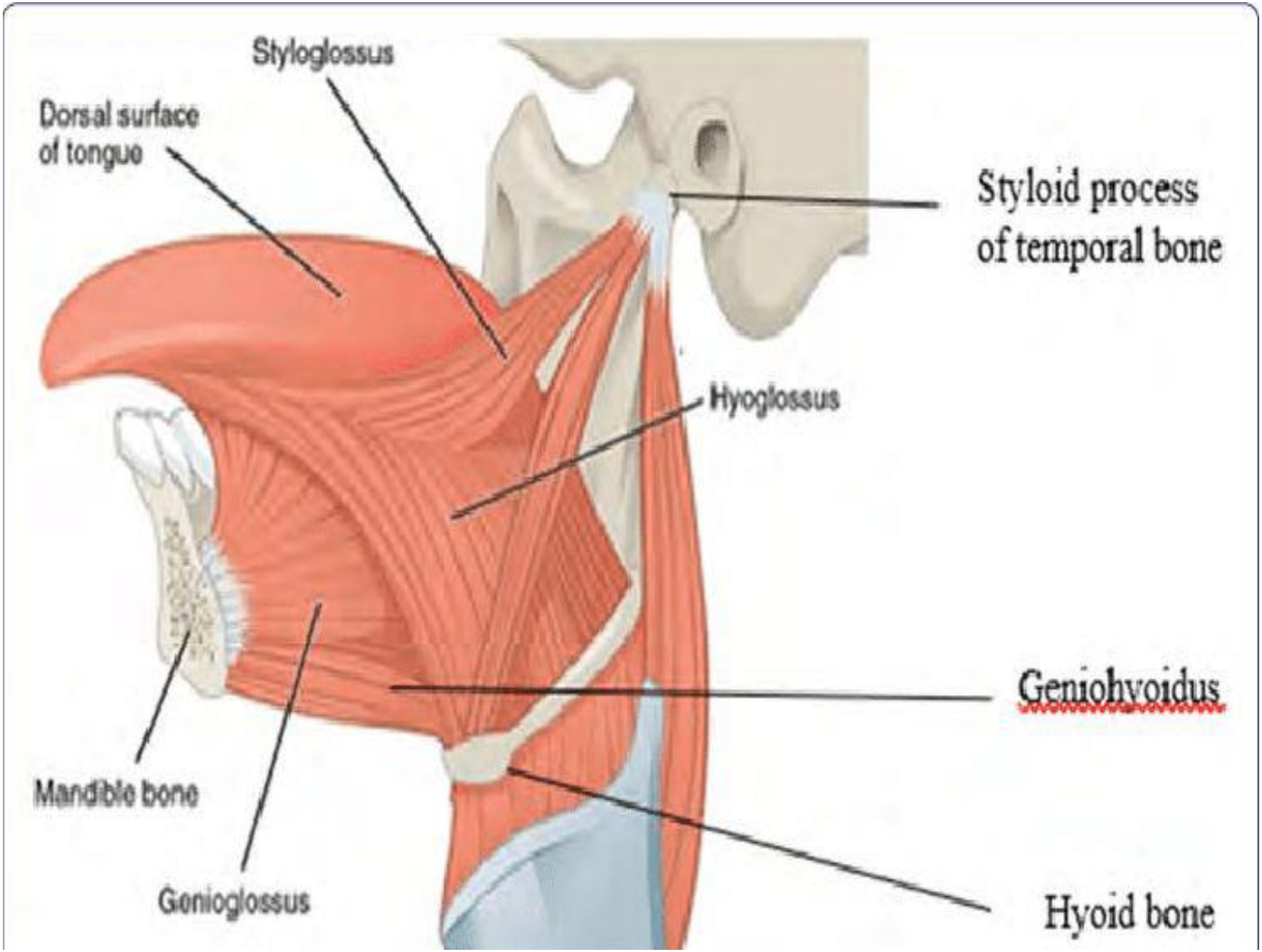
Styloglossus
Dorsal surface of tongue
Styloid process of temporal bone
Hyoglossus
Geniohyoidus
Mandible bone
Genioglossus
Hyoid bone

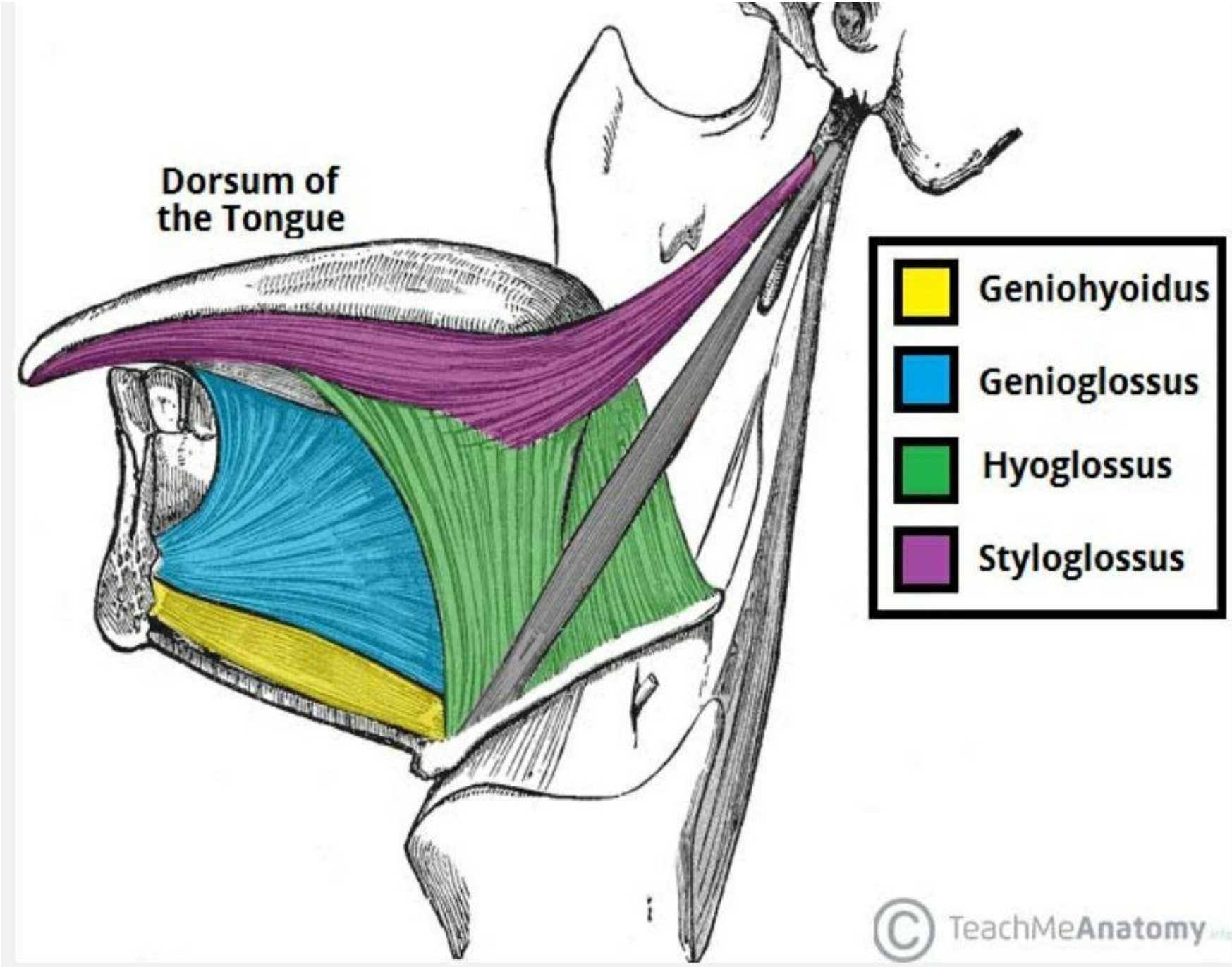
Dorsum of the Tongue
Geniohyoidus
Genioglossus
Hyoglossus
Styloglossus
© TeachMeAnatomy

Submandibular gland

The submandibular gland is a large salivary gland and is composed of a mixture of serous and mucous acini, the former predominating. It lies partly under cover of the body of the mandible and is made up of a large superficial part and a small deep part. Which are continuous with each other around the posterior border of the mylohyoid muscle.

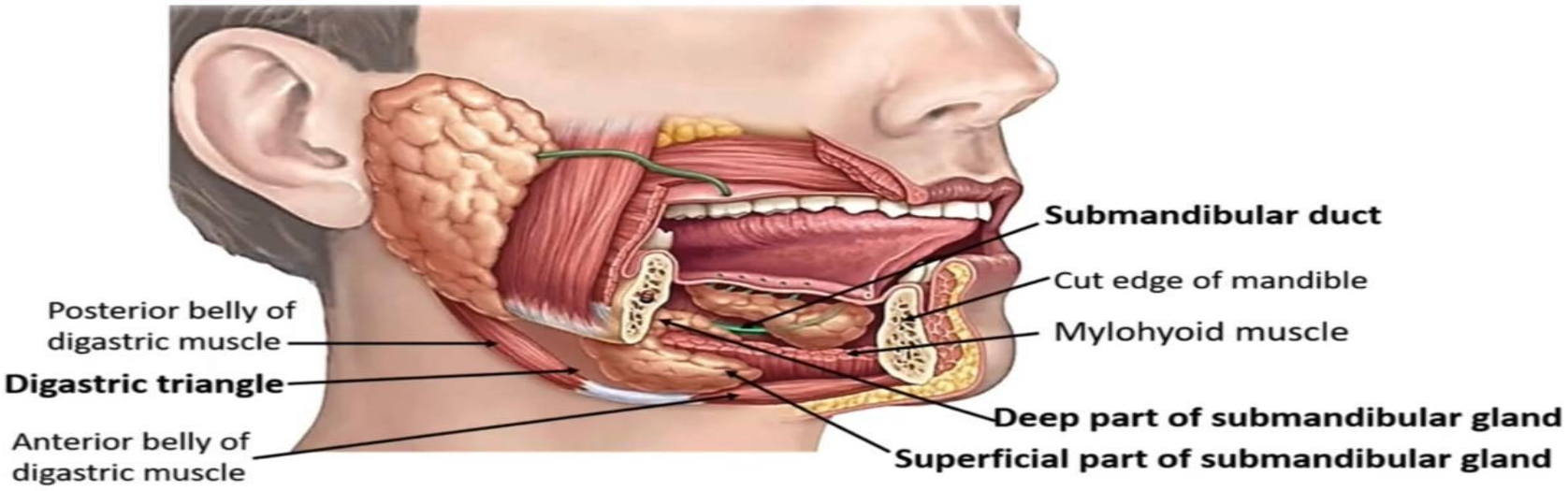

Relations of the superficial part of the gland

- Anteriorly: the anterior belly of the digastric muscle .
- Posteriorly: the stylohyoid muscle, the posterior belly of the digastric muscle and the parotid gland.
- Medially: the mylohyoid muscle , the hyoglossus muscle, the lingual nerve and hypoglossal nerve.
- Laterally: the gland lies in contact with the submandibular fossa in the medial surface of the mandible.
- Inferolaterally: it is covered by the investing layer of deep cervical fascia , the platysma muscle and skin. It is crossed by the cervical branch of the facial nerve and facial vein. The submandibular lymph nodes also lie lateral to it.
- The facial artery is related to the posterior and superior aspects of the superficial part of the gland.

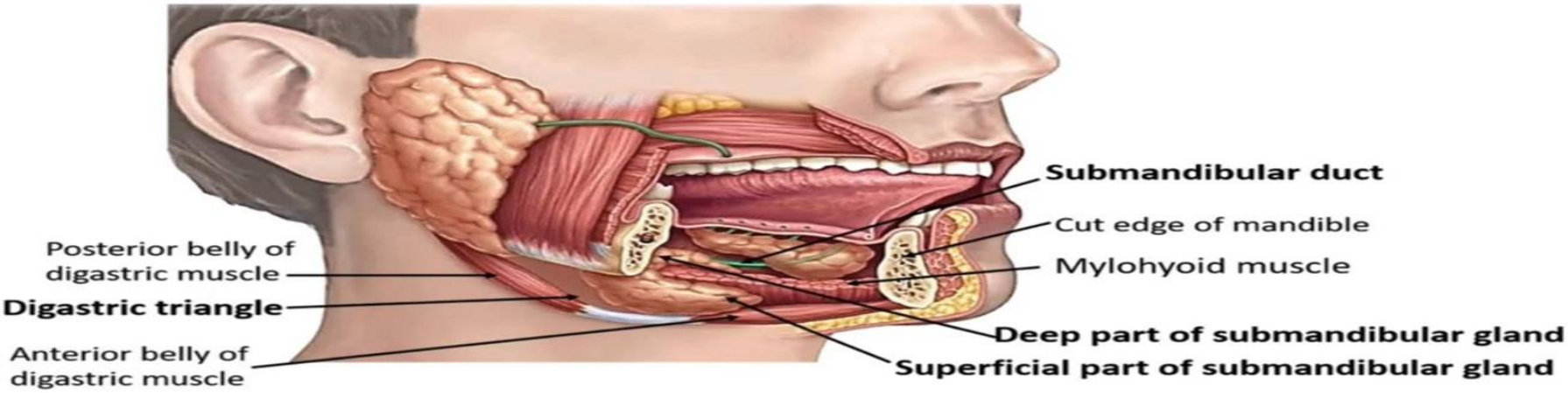

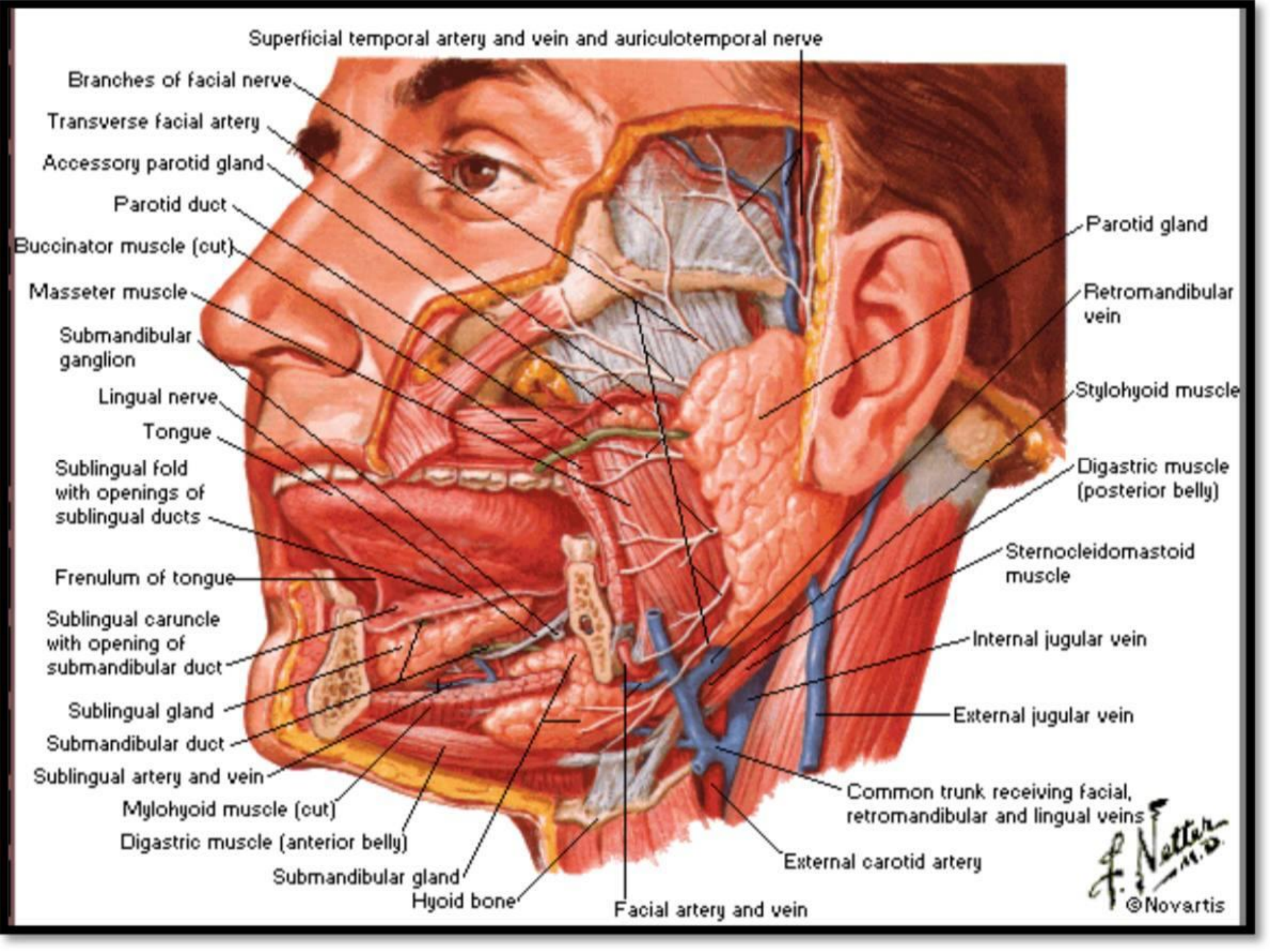
Superficial temporal artery and vein and auriculotemporal nerve
Branches of facial nerve
Transverse facial artery
Accessory parotid gland
Parotid duct
Buccinator muscle (cut)
Masseter muscle
Submandibular ganglion
Lingual nerve
Tongue
Sublingual fold with openings of sublingual ducts
Frenulum of tongue
Sublingual caruncle with opening of submandibular duct
Sublingual gland
Submandibular duct
Sublingual artery and vein
Mylohyoid muscle (cut)
Digastric muscle (anterior belly)
Submandibular gland
Hyoid bone
Facial artery and vein
External carotid artery
Common trunk receiving facial, retromandibular and lingual veins
External jugular vein
Internal jugular vein
Sternocleidomastoid muscle
Digastric muscle (posterior belly)
Stylohyoid muscle
Retromandibular vein
Parotid gland
F. Netter M.D.
©Novartis

The **deep part** of the gland extends forward in the interval between the mylohyoid (below and laterally) while the hyoglossus and styloglossus medially. Its posterior end is continuous with the superficial part of the gland around the posterior border of the mylohyoid muscle while its anterior end reaches as far as the sublingual gland.

Relations of the deep part of the gland

- Anteriorly: the sublingual gland.
- Posteriorly: the stylohyoid, the posterior belly of the digastric and the parotid gland.
- Medially: the hyoglossus and styloglossus.
- Laterally: the mylohyoid muscle and the superficial part of the gland.
- Superiorly: it is related superiorly to the lingual nerve and the submandibular ganglion, it is covered by the mucous membrane of the floor of the mouth.
- Inferiorly: the hypoglossal nerve.

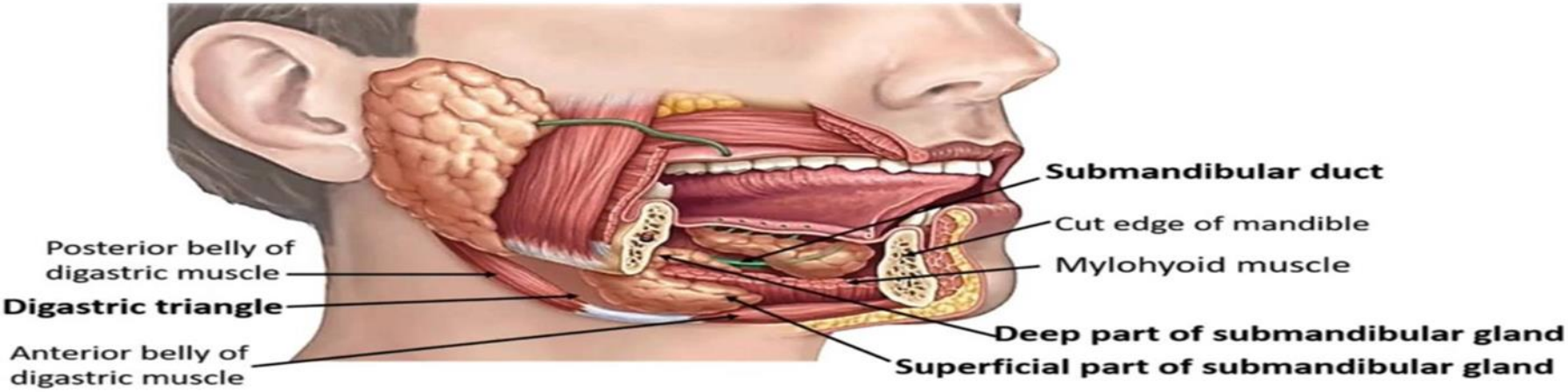

Capsules of the gland

The submandibular gland is a lobulated mass surrounded by a connective-tissue capsule. In addition, the gland is partly enclosed in a dense fibrous capsule derived from the investing layer of deep cervical fascia.

Submandibular Duct

The submandibular duct emerges from the anterior end of the deep part of the gland. It passes forward along the side of the tongue, beneath the mucous membrane of the floor of the mouth(on the hyoglossus muscle). It is crossed laterally by the lingual nerve and then lies between the sublingual gland and the genioglossus muscle. It opens into the mouth on the summit of a small papilla(sublingual papillae) , which is situated at the side of the frenulom of the tongue. Clinically, it is important to remember that the submandibular duct and the deep part of the gland can be readily palpated through the mucous membrane of the floor of the mouth alongside the tongue. Saliva can usually be seen emerging from the orifice of the duct.

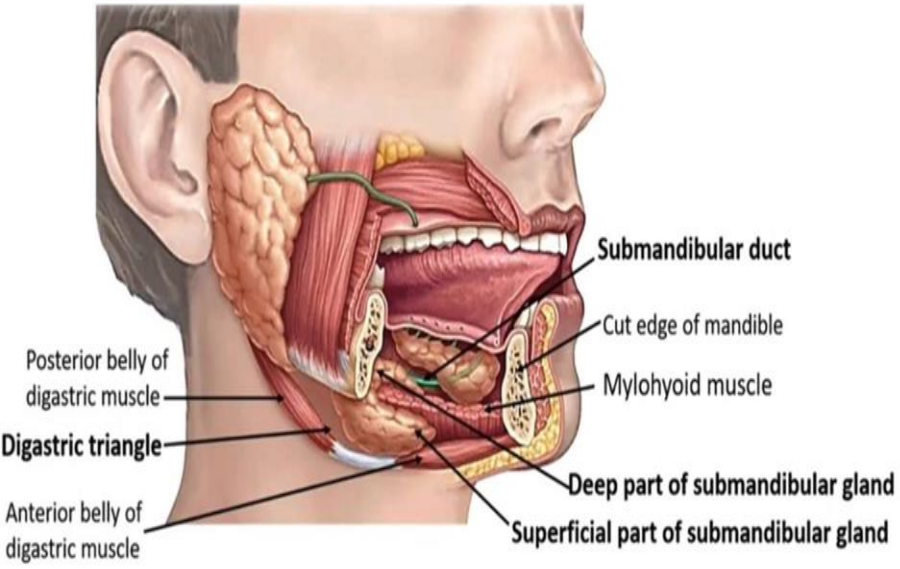

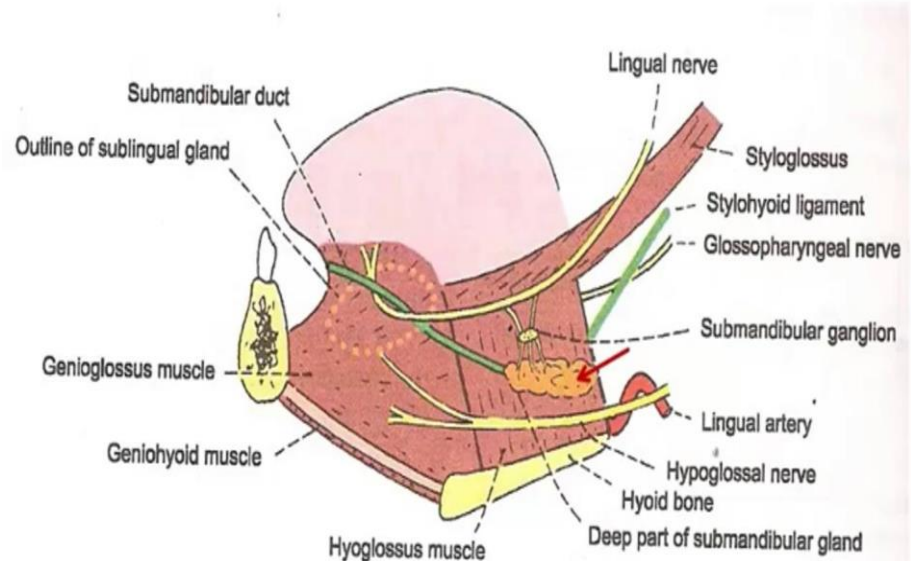

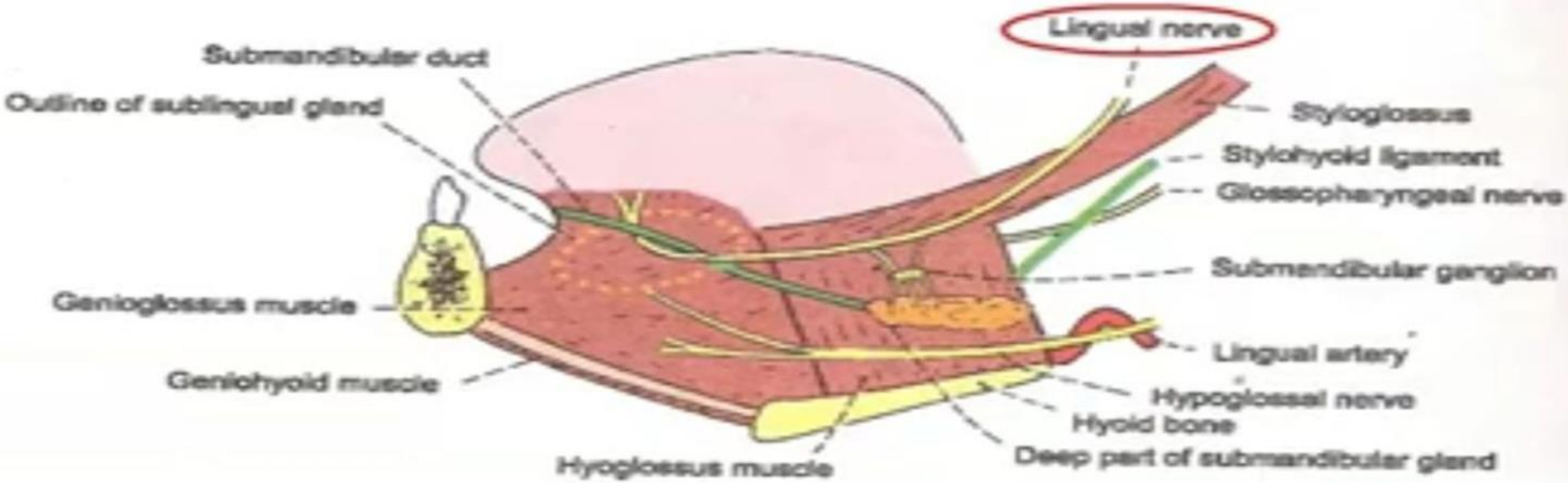
Lingual nerve
Submandibular duct
Outline of sublingual gland
Styloglossus
Stylohyoid ligament
Glossopharyngeal nerve
Submandibular ganglion
Genioglossus muscle
Lingual artery
Geniohyoid muscle
Hypoglossal nerve
Hyoid bone
Deep part of submandibular gland
Hyoglossus muscle

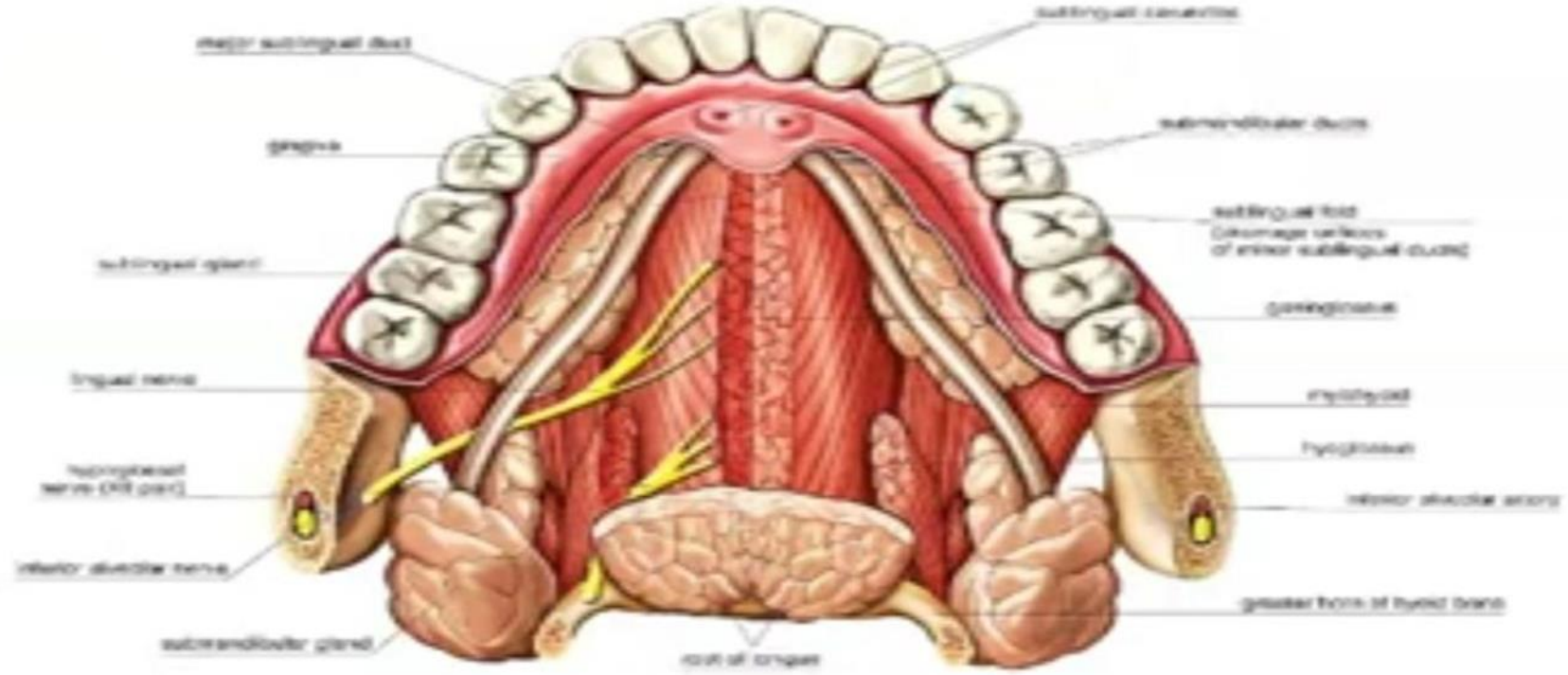

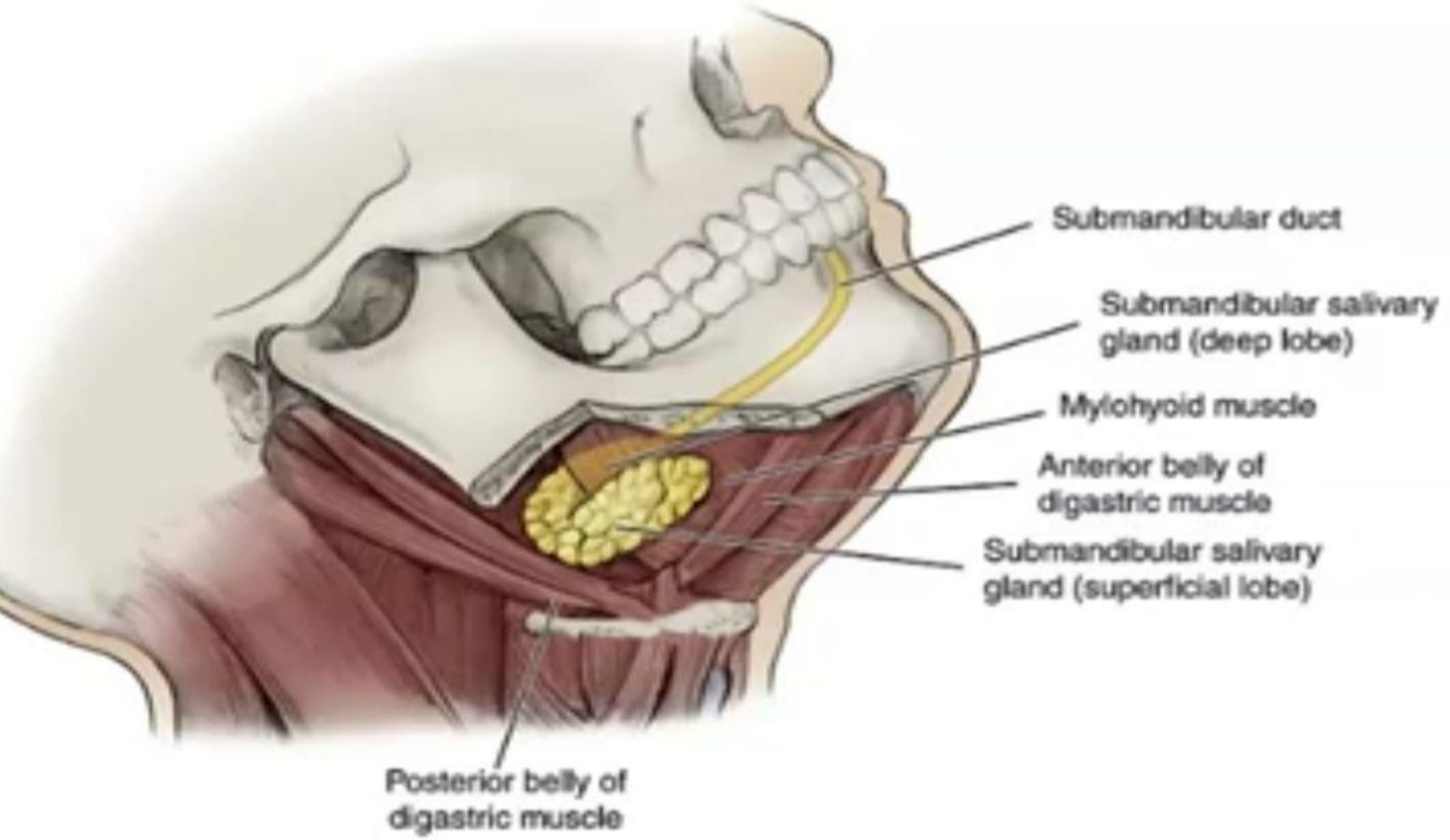
Submandibular duct
Submandibular salivary gland (deep lobe)
Mylohyoid muscle
Anterior belly of digastric muscle
Submandibular salivary gland (superficial lobe)
Posterior belly of digastric muscle

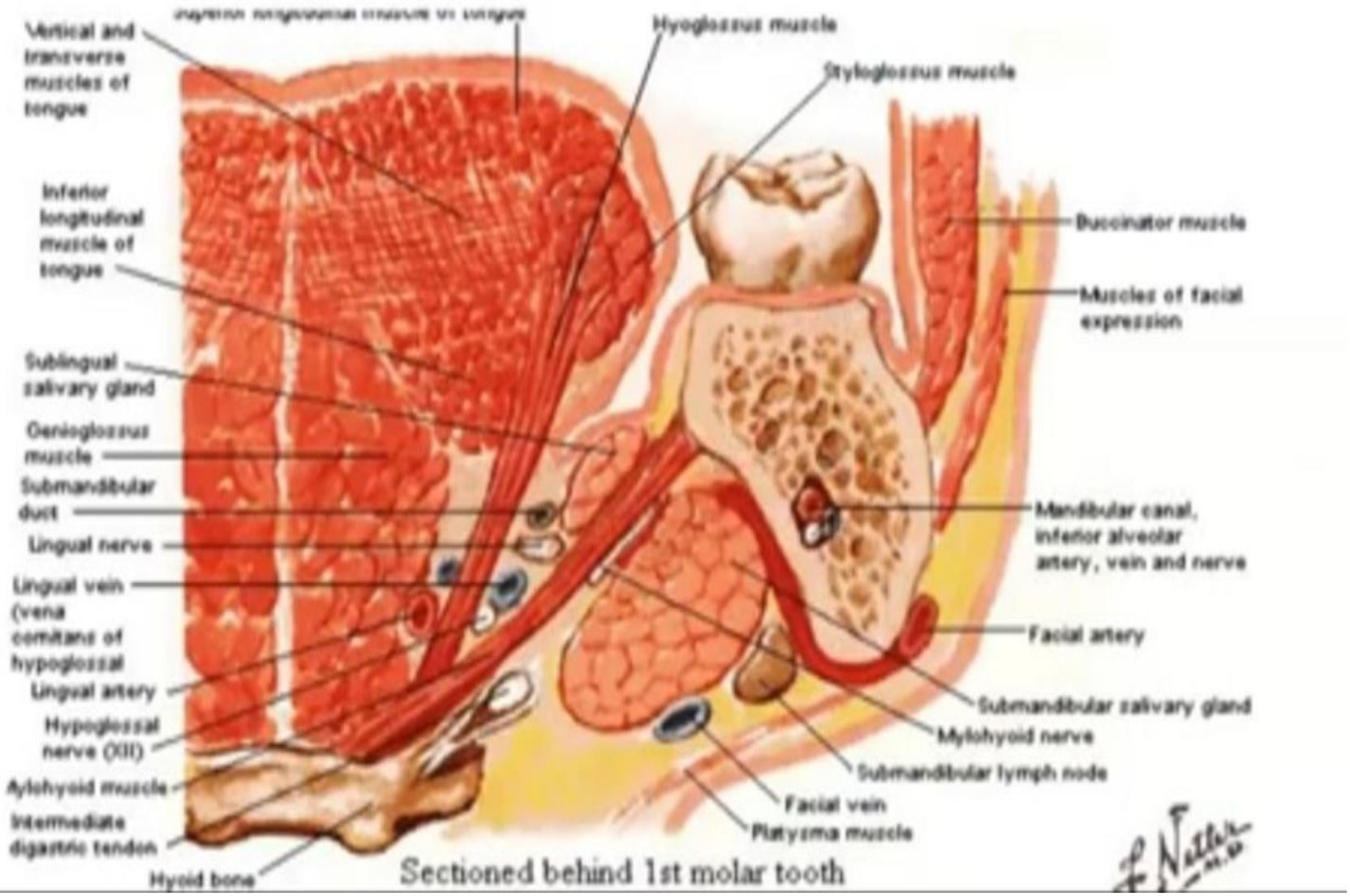
Vertical and transverse muscles of tongue
Hyoglossus muscle
Styloglossus muscle
Inferior longitudinal muscle of tongue
Buccinator muscle
Muscles of facial expression
Sublingual salivary gland
Genioglossus muscle
Submandibular duct
Mandibular canal, inferior alveolar artery, vein and nerve
Lingual nerve
Lingual vein (vena comitans of hypoglossal
Facial artery
Lingual artery
Submandibular salivary gland
Hypoglossal nerve (XII)
Mylohyoid nerve
Submandibular lymph node
Stylohyoid muscle
Facial vein
Intermediate digastric tendon
Platysma muscle
Hyoid bone
Sectioned behind 1st molar tooth

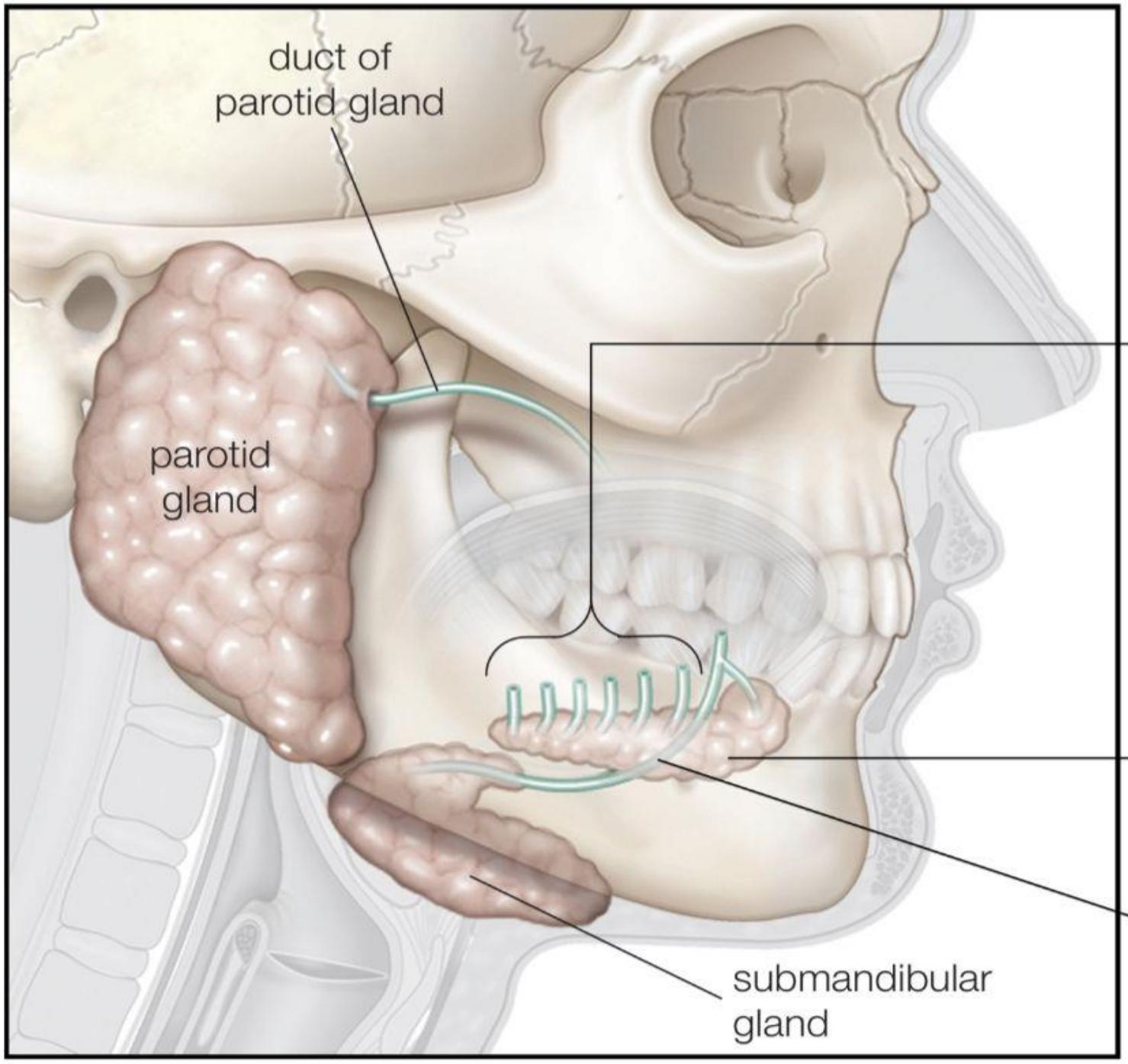
duct of
parotid gland
ducts of
sublingual
gland
parotid
gland
sublingual
gland
submandibular
duct
submandibular
gland

Sublingual gland

Type and location

The sublingual gland is the smallest of the three main salivary glands. It contains both serous and mucous acini, the latter predominating. It lies beneath the mucous membrane of the floor of the mouth, close to the midline.

It has multiple duct (8-20) open into the floor of mouth .

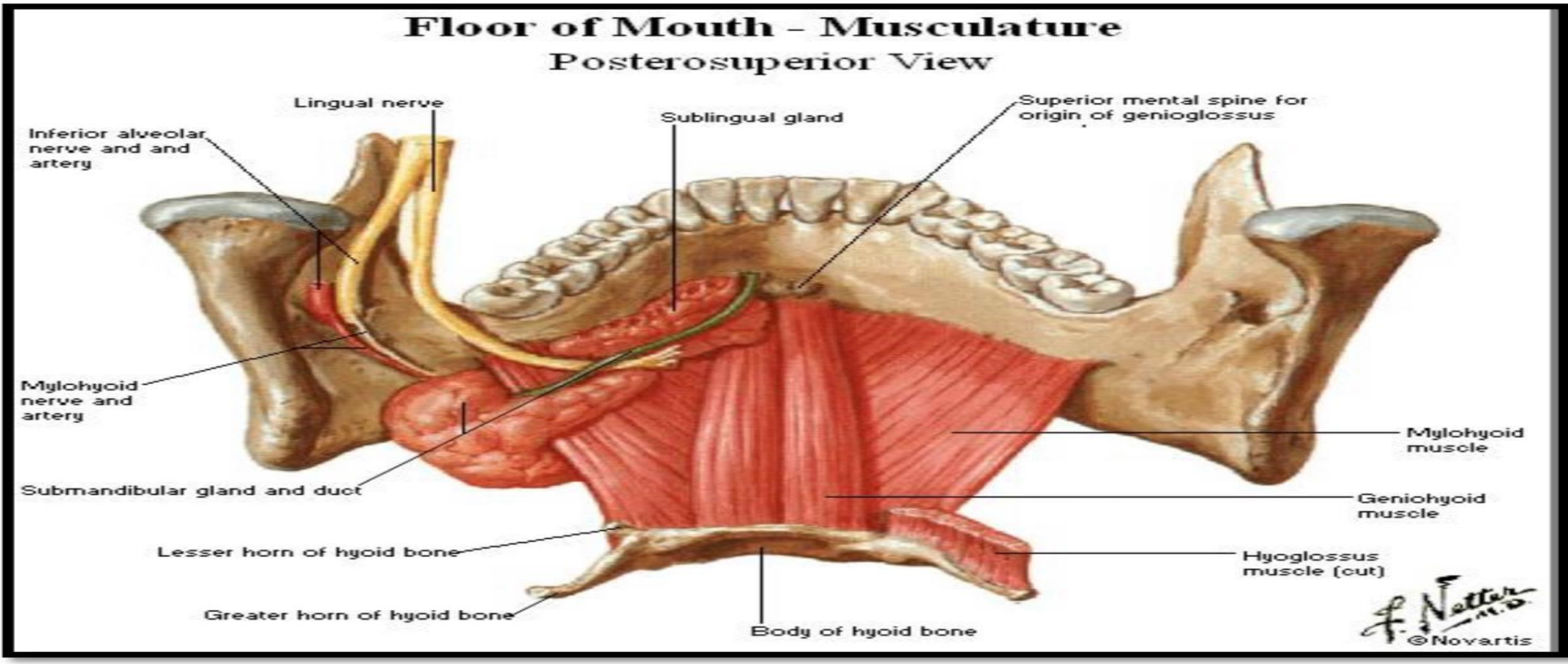

Relations of sublingual gland

- **Anteriorly**: the gland of the opposite side.
- **Posteriorly :** the deep part of the submandibular gland.
- **Medially :** the genioglossus muscle, the lingual nerve and the submandibular duct.
- **Laterally:** the gland is related laterally to the sublingual fossa of the medial surface of the mandible.
- **Superiorly:** the mucous membrane of the floor of the mouth, which is elevated by the gland to form the sublingual fold.
- **Inferiorly :** the gland is supported by the mylohyoid muscle.

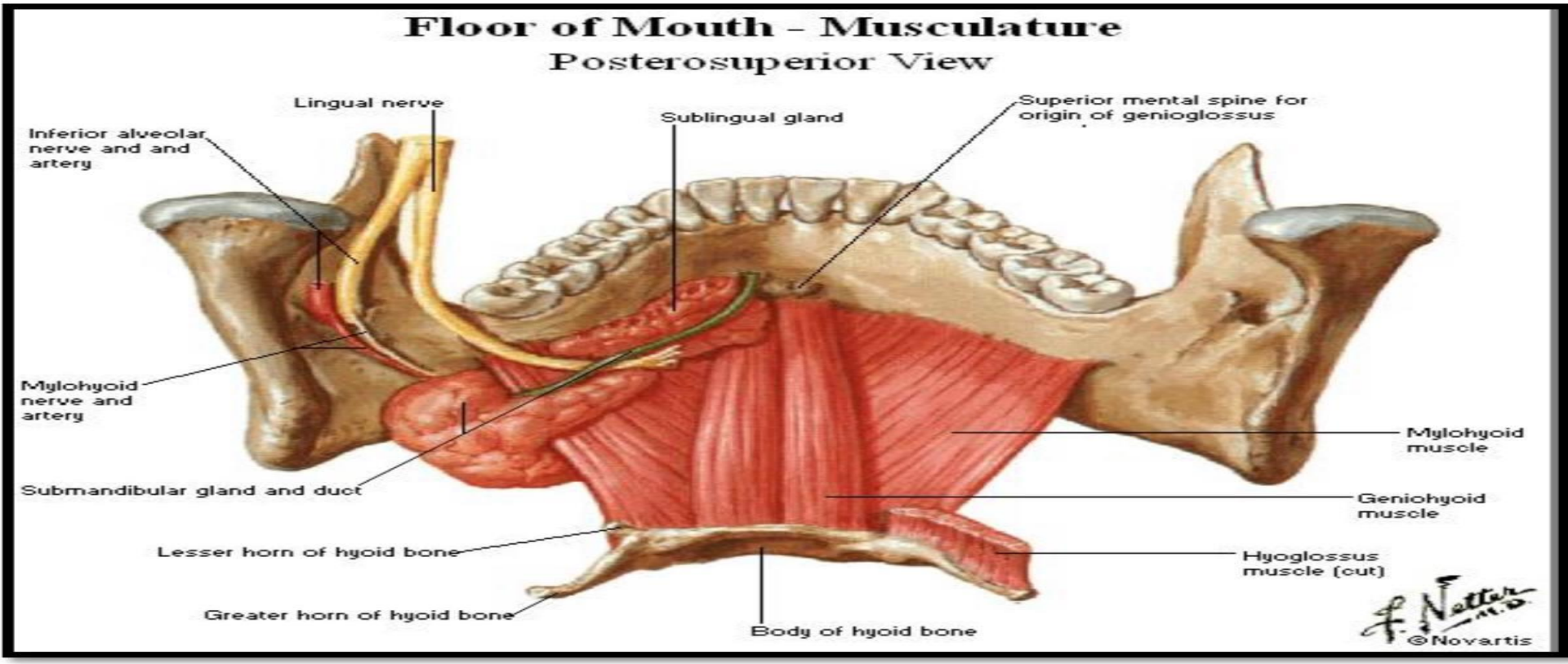

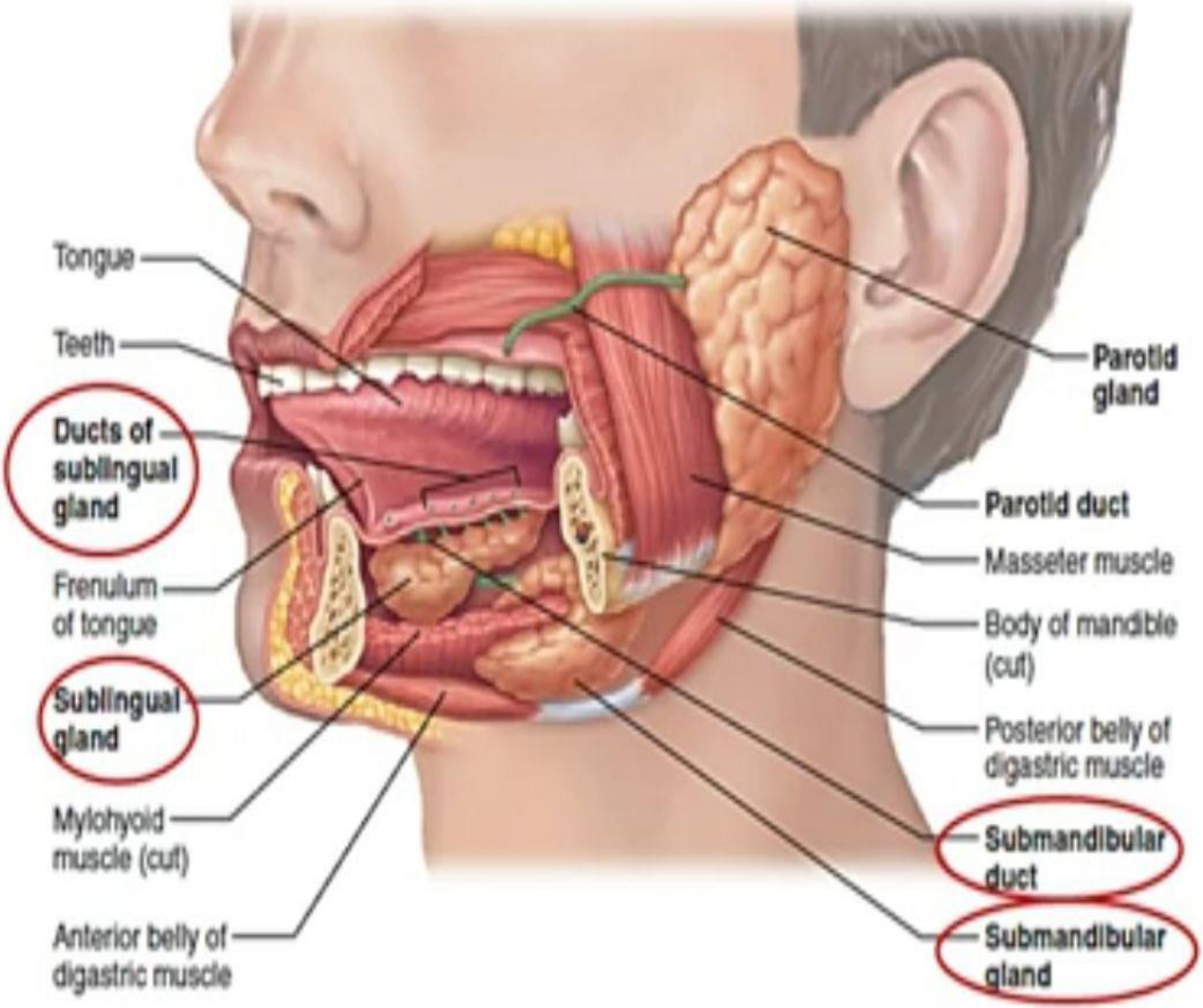
Tongue
Teeth
Ducts of sublingual gland
Frenulum of tongue
Sublingual gland
Mylohyoid muscle (cut)
Anterior belly of digastric muscle
Parotid gland
Parotid duct
Masseter muscle
Body of mandible (cut)
Posterior belly of digastric muscle
Submandibular duct
Submandibular gland

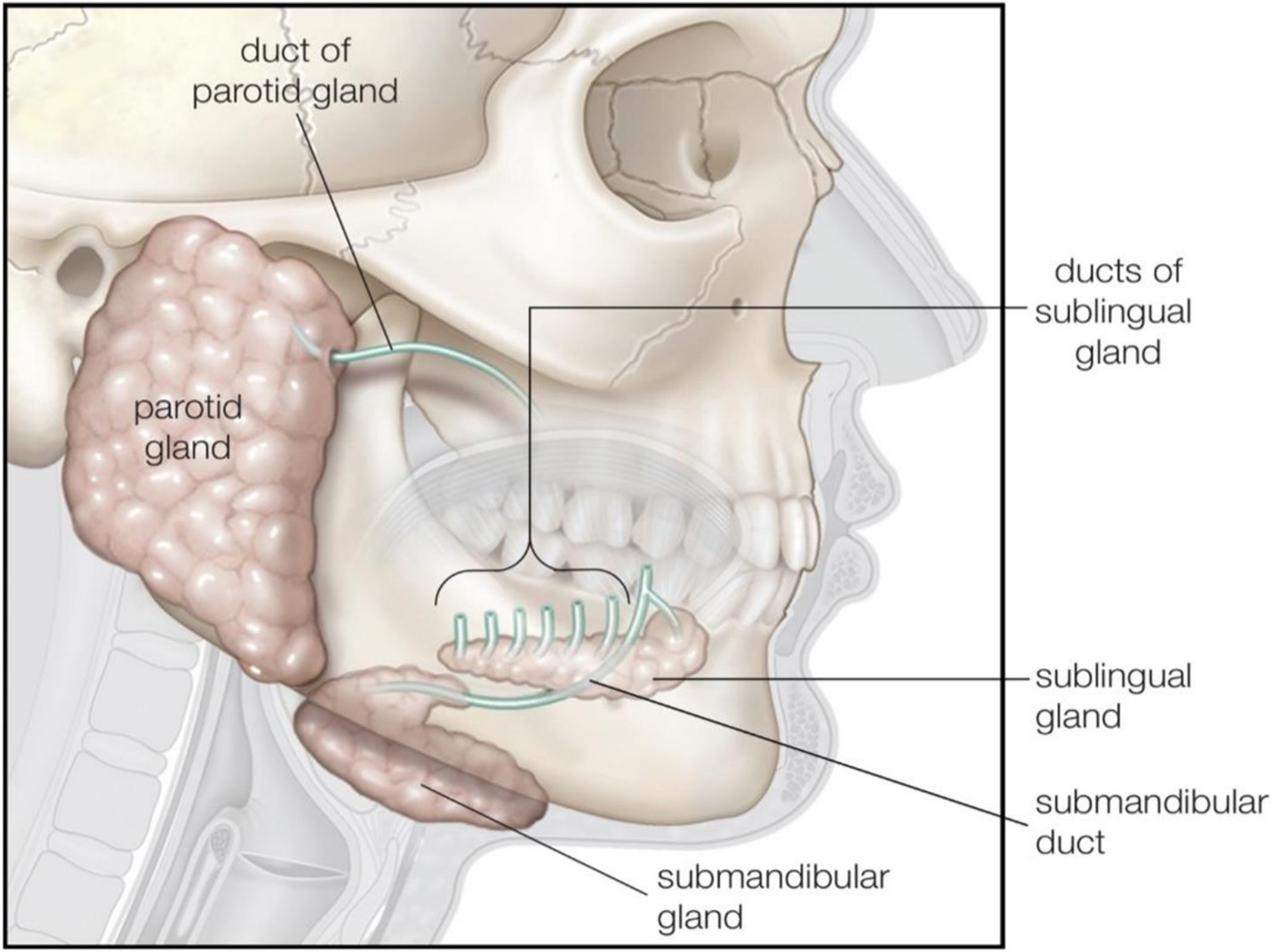
duct of
parotid gland
parotid
gland
ducts of
sublingual
gland
sublingual
gland
submandibular
duct
submandibular
gland

Thanks