Periodontal ligament (PDL)

Definition: PDL is a connective tissue structure that surrounds the root and connects it with the bone.

Structure: the periodontal ligament space has the shape of an hourglass and is narrowest at the mid root level. The width of PDL is approximately 0.25± 50 percent.

Cellular composition: cells of PDL are categorized as:

1. Synthetic cells
    a. Osteoblast
    b. Fibroblast
    c. Cementoblasts
2. Resorpative cells
    a. Osteoclasts
    b. Cementoclasts
    c. Fibroblasts
3. Progenitor cells
4. Epithelial rest of malassez
5. Connective tissue cells (mast cells and macrophages)

Synthetic cells:

1. *Osteoblasts:* covers the periodontal surface of the alveolar bone. They are responsible for the formation of alveolar bone.

2. *Fibroblasts:* the most prominent connective tissue cells (65%). The main function of the fibroblasts is the production of various types of fibers (collagen fibers, Reticulin fibers, Oxytalan fibers and Elastin fibers). Fibroblasts are also instrumental in the synthesis of connective tissue matrix.
3. *Cementoblasts:* are seen lining the cementum and are responsible for cementum deposition.

Resorpative cells:

1. *Osteoclasts:* these are the cells that resorb the bone and tend to be large and multinucleated.
2. *Fibroblasts:* they synthesize collagen and also possess the capacity to resorb and degrade the old callogen fibers.
3. *Cementoclasts:* cementum is not remodeled in the fashion of alveolar bone and periodontal ligament but that it undergoes continual deposition during life. However resorption of cementum occurs in certain circumstances by cementoclasts.

Progenitor cells: they differentiate into functional type of connective tissue cells.

Epithelial rest of Malassez: they are found close to cementum. When certain pathologic conditions are present, cells of epithelial rest can undergo rapid proliferation and can produce a variety of cysts and tumors of the jaws.

Mast cells: they play a role in inflammatory reaction.

Macrophages: they are capable of phagocytosis.

Extracellular components:

1. Fibers
    a. Collagen
    b. Oxytalan
2. Ground substances
    a. Proteoglycans
    b. Glycoproteins

Periodontal fibers: the most important elements of the periodontal ligament are the principal fibers. They are collagenous in nature and are arranged in bundles following a wavy course.

The terminal portion of these principal fibers that insert into the cementum and bone are termed *Sharpey's fibers.*

The principal fibers of the PDL are arranged in five groups:

Alveolar crest fibers: they extend obliquely from the cementum just beneath the junctional epithelium to the alveolar crest.

Function: retain tooth in socket and resist lateral movement.

Horizontal group: extends from cementum to the alveolar bone at right angle to the long axis of the tooth.

Oblique group: they are the largest group extending coronally in an oblique direction from the cementum to the bone.

Function: they resist axial directed forces.

Apical group: they radiate from the cementum of root apex to the bone.

Function: it prevents tooth tipping, resists luxation, and protects blood, lymph and nerve supply of the tooth.

Inter-radicular fibers: Extends from cementum of bifurcation areas, splaying from apical into furcal bone.

Function: it resists luxation and also tipping and torquing.

Ground substance:

The ground substance is made up of two major groups of substances:

- Glycosaminoglycans: such as hyaluronic acid, proteoglycans.
- Glycoproteins: such as fibronectin and laminin

It also has high water content (70%).

Development of principal fibers of PDL

It will be as follows

1. Small, fine brush like fibrils are detected arising from the root cementum and projecting into the PDL space.
2. Small fibers are seen on the surface of the bone but only in thin, small numbers.
3. The number and thickness of fibers originating from the bone increase and elongate. They radiate towards the loose connective tissue in the mid portion of the periodontal ligament.
4. The fibers originating from the cementum also increase in length and thickness and fuses with the fibers originating from the alveolar bone in the periodontal ligament space.

5. Following tooth eruption, the principal fibers become organized in bundles and run continuously from bone to cementum.

Structures present in the connective tissue

1. Blood vessels: periodontal ligament is supplied by branches derived from three sources dental, inter-radicular and Interdental arteries.
2. Lymphatics: lymphatic vessels follow the path of blood vessels in the periodontal ligament.
3. Nerve intervention: periodontal ligament is mainly supplied by dental branches of the alveolar nerve. The periodontal ligament has mechanoreceptors providing sense of touch, pressure, pain and proprioception during mastication.
4. Cementicles: calcified masses adherent to or detached from the root surface.

Functions of the PDL:

1. Physical
2. Formative and remodeling
3. Nutrional and sensory function

Physical function

A. Provide soft tissue "casing'' to protect the vessels and nerves from injury by mechanical forces.
B. Transmission of occlusal forces to the bone.
C. Attaches the teeth to the bone.

D. Maintains the gingival tissues in their proper relationship to the teeth.
E. (shock absorption) Resists the impact of occlusal forces

Formative and Remodeling function

Cells of the periodontal ligament have the capacity to control the synthesis and resorption of the cementum, ligament and alveolar bone. Periodontal ligament undergoes constant remodeling; old cells and fibers are broken down and replaced by new ones.

Nutritive functions

Since PDL has a rich vascular supply, it provides nutrition to the cementum, bone, and gingiva.

Sensory functions

The PDL is supplied with sensory nerve fibers which transmit sensation of touch, pressure and pain to higher centers.

Clinical consideration:

The width of PDL space varies with *age*, *location* of tooth, degree of *stress* to which the tooth was subjected. In compliance with the physiologic mesial migration of the teeth the PDL is *thinner* on the *mesial* root surface than on the distal surface.

A tooth in *hyperfunction* may have a *wider* PDL space and a tooth in hypofunction may have a narrow PDL space.

The width of PDL space is about *0.25mm* in normal functions. It is *widest* at the *cervical* and *apical* portions of the root and narrowest at the middle.

The *most interesting features* of the PDL are its adaptability to rapidly changing applied force and its capacity to maintain its width at constant dimensions throughout its lifetime.

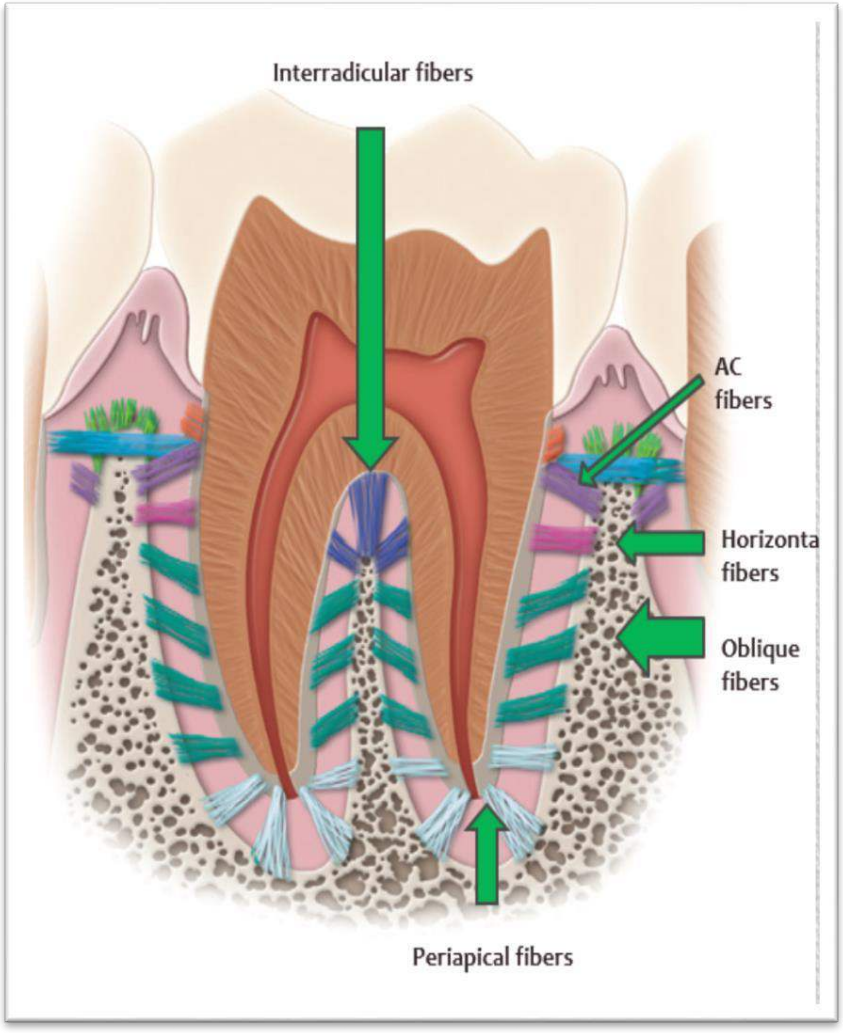

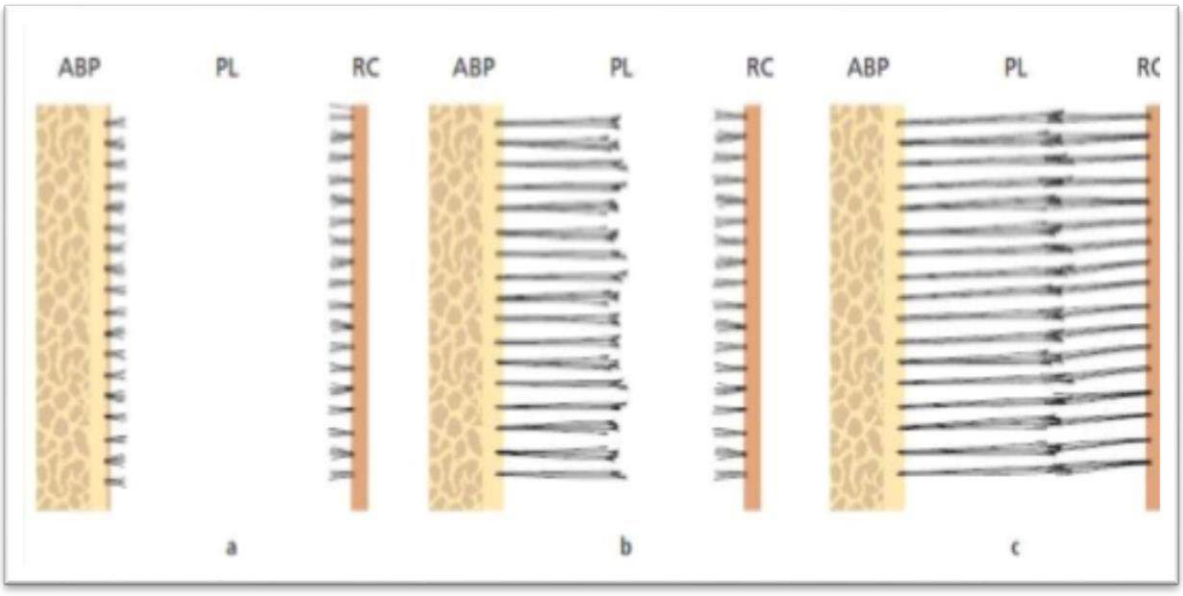
ABP
PL
RC
ABP
PL
RC
ABP
PL
RC
a
b
c

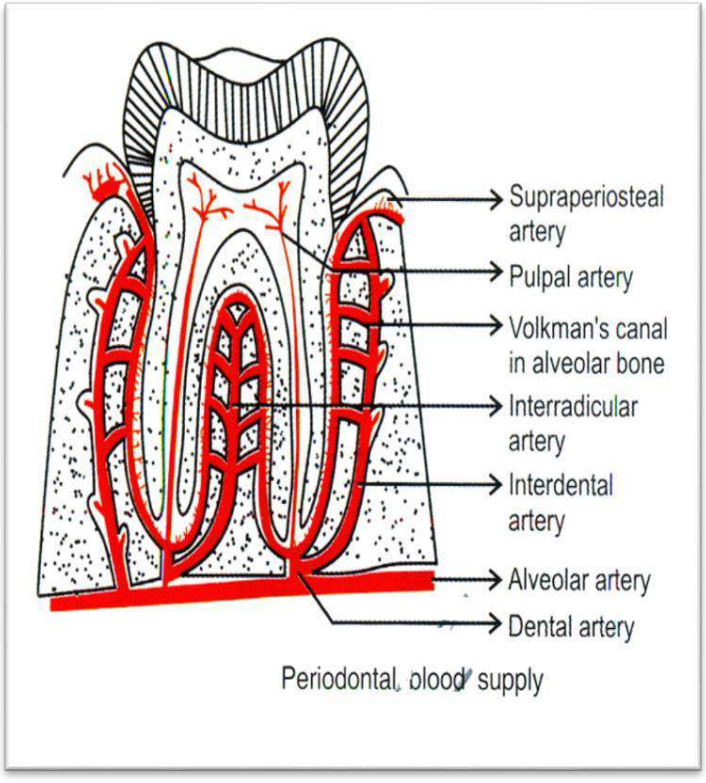
Supraperiosteal artery
Pulpal artery
Volkman's canal in alveolar bone
Interradicular artery
Interdental artery
Alveolar artery
Dental artery
Periodontal blood supply