Healing of periodontal wounds

Phases of Wound Healing

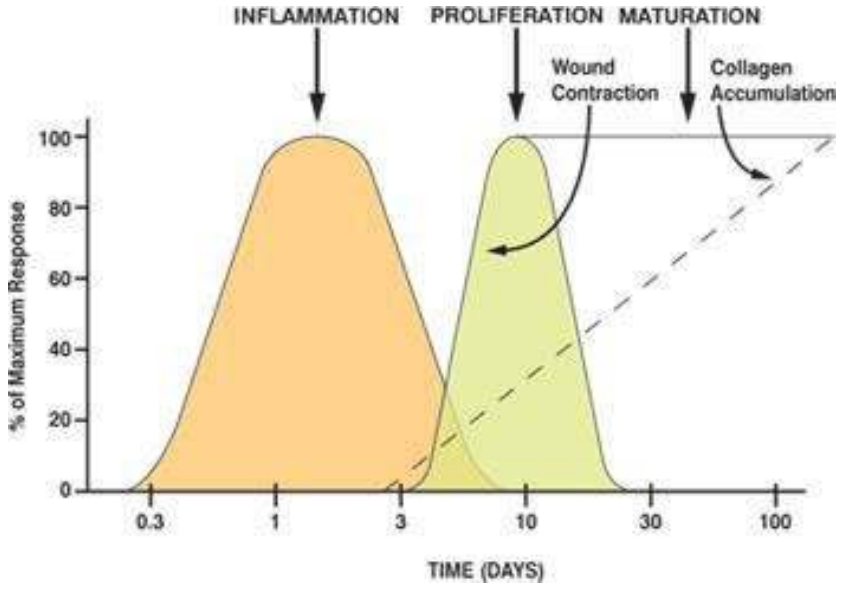

Whether wounds are closed by primary intention, or left to heal by secondary intention, the wound healing process is a dynamic one which can be divided into three phases. Wound healing process is not linear and often wounds can progress both forwards and back through the phases depending upon intrinsic and extrinsic factors The phases of wound healing are :

- Inflammatory phase
- Proliferation phase
- Maturation phase

The inflammatory phase is the body‟s natural response to injury. After initial wounding, the blood vessels in the wound bed contract and a clot is formed. Once haemostasis has been achieved, blood vessels then dilate to allow essential cells; antibodies, white blood cells, growth factors, enzymes and nutrients to reach the wounded area. This leads to a rise in exudate levels. It

is at this stage that the characteristic signs of inflammation can be seen; erythema, heat, oedema, pain and functional disturbance. The predominant cells at work here are the phagocytic cells; „neutrophils and macrophages"; mounting a host response and autolysing any devitalised „necrotic / sloughy" tissue.

During **proliferation**, the wound is „rebuilt" with new granulation tissue which is comprised of collagen and extracellular matrix and into which a new network of blood vessels develop, a process known as „angiogenesis". Healthy granulation tissue is dependent upon the fibroblast receiving sufficient levels of oxygen and nutrients supplied by the blood vessels. Healthy granulation tissue is granular and uneven in texture; it does not bleed easily and is pink / red in color. The color and condition of the granulation tissue is often an indicator of how the wound is healing. Dark granulation tissue can be indicative of poor perfusion, ischemia and / or infection. Epithelial cells finally resurface the wound, a process known as „epithelialisation".

Maturation is the final phase and occurs once the wound has closed. This phase involves remodeling of collagen from type III to type I. Cellular activity reduces and the number of blood vessels in the wounded area regress and decrease

Repair of wounds: include 2 responses

 Epithelial response which mean that mobilization and migration of epithelial cell at wound margin.

 Connective tissue response a-
Hemostasis b-Inflammation c-
Proliferation d-Remodeling
(collagen synthesis) Initial
response to wounding:

A.Hemostasis

The damaged vessels constrict to slow blood flow

Hemorrhaging results in deposition of fibrin, aggregation of platelets (to stop bleeding) and coagulation to form a clot within minutes of wounding. The clot aid in:
- Serves as a hemostatic barrier
- Unites the wound margin
- Provide a scaffold for subsequent migration of reparative cells

B. Inflammatory cell activation, migration and function (leukocytes migrate into tissue to initates inflammatory process). These inflammatory cells derived from 3 sources:
1. Cells normally present in the tissue.
2. Cells extravasated when blood vessels are damaged.
3. Cells carried in intact blood vessels.

The most important inflammatory cells:
 Neutrophil within few hours of injury to reach max. Concentration at 24 hours. Main functions: phagocytosis and mediate inflammatory changes.
 Macrophage which present after 24 hours and predominate at 5 days, these cells aid in phagocytosis of macrophages and release of growth factors as angiogenic substances to stimulate capillary growth and the granulation process. Also they release inflammatory mediators as IL1

C. Proliferation of fibroblast (2 days and on) from undifferentiated perivascular cells.and secrete glycoprotein and collagen

Epidermal cells migrate from the wound edge. then the granulation tissue will formed from macrophages ,fibroblast, and new capillaries

D. Remodeling; collagen synthesis from the new fibroblast to strengthen the wound these fibers will be reorganize and wounds will contract increasing tissue integrity .Eidermal cells grow over connective tissue to close the wound

Wound union:

A. ***Primary union:*** if wounds are produced surgically in sterile environments and their edges are brought closely, it is said that “primary union” or “healing by primary intent” has been achieved. Under these condition there is:

a. Minimal trauma

b. Little chance of secondary infection
c. Heal quickly without complication.

Steps of healing:
1. Clot formation
2. Inflammation
3. Granulation
4. Epithelization
5. Cicatrization (scar formation).

B. ***Secondary union:*** it takes place when the edge of wound can‟t be brought together e.g: Gun shot exit wounds, free gingival graft,(the wound produced at the donor site can‟t be sutured together and is left open), it termed “secondary union” or “healing by secondary intent” or “granulatingin”.

Steps of healing:
1. Clot formation
2. Inflammation
3. Granulation
4. Epithelization
5. Cicatrization (scar formation).

Wound healing after periodontal treatment:
Rationale for periodontal treatment:
1. Eliminate pain and gingival inflammation and bleeding.
2. Reduce periodontal pockets.
3. Eliminate infection and stop pus formation.
4. Arrest soft tissue and bone destruction and restore the tissue destroyed by the disease.
5. Reduce abnormal tooth mobility and establish optimal Occlusal function.
   6. Re-establish the physiologic gingival contour necessary for the preservation of periodontal health.
7. Prevent recurrence of the disease and so reduce tooth loss.

Healing after scaling and blind root planing:

If scaling is done with overlapping strokes, it is technically possible to detach all the subgingival deposits. Immediately after conclusion of a successful subgingival scaling all plaque organisms are detached from the tooth, many of the bacteria are swimming in the exudates. However, the bleeding which follows will carry most of detached particles, including bacteria out of the pocket during and immediately after the debridement. The bleeding will stop in a few minutes, but a fairly profuse exudation from damaged blood vessels will continue for many hours. The exudate which is a mixture of water, serum protein and white blood cells will accumulate between the tooth and the soft tissue. This is called gingival fluid. Gingival crevicular fluid secretion per day of normal healthy gingiva is 0.5-2.4 ml/ day. The gingival fluid contributes to the mechanical cleansing of pocket because it seeps out in a continuous flow.

Most of the detached plaque organisms are brought out of the pocket with the gingival fluid in a few minutes. Those organisms which may have been captured in the soft tissue are being eradicated by the PMNL. Finally, large numbers of bacteria enter the lymph and blood vessels to be brought to the regional lymph nodes or to spleen where they are destroyed.

Only a few hours after debridement, all the bacteria are removed (mostly with the gingival fluid). The secretion of gingival fluid will then subside and the epithelial reminant which may have been left in the pocket begin to proliferate.

The granulation tissue in the lateral wall of the pocket, in an environment free of plaque and calculus will be changed into connective tissue; there by minimizing shrinkage, this is regarded as an important advantage of blind root planning over radical surgery, i.e.: less trauma and hemorrhage will result in less gingival shrinkage during healing. This is very important for esthetic which is a major consideration of therapy, particularly in the anterior region.

Further more exposed cementum to a pathological pocket is cytotoxic to both epithelium and fibroblast by bacteria with their toxins penetrating this cementum.

Removal of exposed cementum through root planing eliminates undesirable surface contamination and provides a healthy surface to which fibroblasts adhere. Thus reduction of pocket probing depth following blind root planing is partly due to shrinkage of gingival wall of pockets (repair) forming long

junctional epithelium in most of cases and partly from regeneration of lost attachment.

Healing following surgical procedure:

Gingivectomy: healing will be by 2nd intention (secondary union) which occurs by the formation of granulation tissue which grows from the base of the wound to fill the defect.
The vascular and fibroblastic proliferation which together make up the granulation tissue are much more abundant and healing taken much larger than when it occur by first intention.
The main problem after Gingivectomy is for the epithelial cells to cover the open wound. There is little if any regeneration necessary in the connective tissue because an incision at the bottom of the pocket usually will remove all the granulation tissue, leaving a clean connective tissue surface. Thus, the epithelial cells are the main actors in the healing of Gingivectomy.

Steps of healing:

1. The incision exposes many blood vessels of all sizes, when the pack is applied, blood clot is formed and the blood vessels are sealed with fibrin to stop further bleeding. The underlying tissue becomes acutely inflamed with some necrosis.
2. The blood clot below the pack contains large numbers of microorganisms. However, these are in most cases quickly phagocytozed by PMNs which are migrating into the area in large numbers. Therefore, the blood clot is likely to be free of bacteria within hours.
3. The next step in healing is the proliferation of macrophages which engulf RBC and disintegrating PMN. Within 1-2 days, epithelial cells start to migrate from oral mucosa. These cells migrate on a network of fibrin.

Surface epitheliazation is completed after 5-14 days.

4. Under particularly favorable condition, epithelial cells can migrate as far as 2mm in 24 hours. After Gingivectomy, the speed must be considerably less and it may take 1-2 weeks before the oral epithelial cells reach the tooth surface.

5. If the regeneration occurred in a plaque free tooth surface, free gingival unit will form. This regeneration occurs in coronal direction and appear clinically as gain in marginal height “zero pocket”.
6. Complete epithelial repair taken about 4-5 weeks, while complete repair of connective tissue takes about 7 weeks.
7. The gingival fluid increases after Gingivectomy and diminished as healing progresses, because decrease in vasodilatation and vascularity. Also during the first 4 weeks after gingivectomy, keratinization is less than it was prior to surgery. Also pigmentation is diminished in the healed gingiva in patients with physiologic gingival melanosis.

Healing following a flap operation:

Healing will be by first intention and has many similarities with healing of an incision in the skin. It is more rapid than secondary intention and characterized by the formation of only minimal amounts of granulation tissue.

Steps of healing:

1. Immediately after suturing (0-24 hrs), a connection between flap and tooth or bone surface is established by the blood clot which consists of fibrin, PMNs, erythrocytes, debris from injured cells and capillaries at the edge of the wound, there are also bacteria and an exudates as result of tissue injury. 2. 1-3 days after surgery: the space between the flap and tooth or bone is thinner, epithelial cells migrate over the border of the flap to contact the tooth. When the flap is closely adapted to the alveolar process, there is minimal inflammatory response.

3. One week after surgery: epithelial cells are attached to the root by hemi desmosomes and a basal lamina. The blood clot is replaced by granulation tissue derived from gingival connective tissue, the bone marrow and the periodontal ligament.
4. Two weeks after surgery: appearance of collagen fibers parallel to the tooth surface. They are immature therefore union is still weak, although clinically may be normal.

One month after surgery: a fully epithelized gingival crevice with a welldefined epithelial attachment is present. There is a beginning of functional arrangement of supracrestal fibers.

Healing following grafting procedures

Thickness of any given graft range between 1-1.5 mm in optimum condition, Soft tissue grafts placed on bone shrink by about 25% while that placed on periosteum shrink by about50%. Healing of soft tissue grafts placed entirely on a connective tissue recipient
bed divided in to 3 phases (Oliver et al.1968)

1--.Initial phase : (from 0-3days)

Thin layer of exudates present between the graft and recipient bed during this period the graft survive with an avascular (plasmatic circulation) from recipient bed.

- The epi. Of free graft degenerate early and desquamated.
- In case of placing graft over a recession part of the bed will be a vascular root surface so the area of graft must receive nutrient from the connective tissue bed that surrounds the recession.

- **2-. Revascularization phase** :(from 2-11days)

anastomosis are established between the blood vessels of recipient bed and graft tissue (re-established of circulation)and capillary proliferation .also a fibrous union between graft and underlying C.T and re-epithelialization of the graft by proliferation of adjacent epi.

- **3-Tissue maturation phase** :(from 11-42days)

During this period the number of blood vessels in the transplant reduced and after 14 days vascular system appear normal with formation of keratin layer after epithelial maturation.

Factors affecting healing after perio treatment;

I. Local factors

a. Local factors improve healing

- Good debridement
- Immobilization of the healing area.
- Pressure on the wound
- An increase in O2 consumption that increase cellular activity

b. Local factors delay healing

- Excessive tissue manipulation.
- Trauma and presence of foreign bodies.
- Repetitive treatment procedures that disrupt the orderly cellular activity in the healing process.
- Inadequate blood supply lead to impaired cellular activity necrosis delay healing.

II. Systemic factors:

- Aging (diminishes capacity because of atherosclerotic vascular changes which reduce blood circulation).
- Patient with generalized infections.
- Diabetes.
- Patients with debilitating diseases.
- Malnutrition: Vit. C deficiency, Protein deficiency.
- Systemically administrated hormones as cortisone