Spaces

By:Dr. Ahmed Talib Al-Araji

The body's response to infection agents is inflammatory response which is essentially protective ,it consists of :

…1_Hyperemia caused by vasodilation of arterioles and capillary,and the release of permeability factors to allow for passage of nutrients and leukocytes.

…2_preciptation of a network of fibrin to wall off the infected region.

…3_phagocytosis of bacteria and other organisms as well as dead cells.…

…4_disposal by macrophages of necrotic debris.

Periapical infections
front infections arise when bareta from infected necrotic pine put a carous toots riben bacteria from indee exposure nee
Ponte invade the perlapscontamina ted ten the apical for roan.
ео осніт ез the аста piса новосо в оона й та ассовогу о сас ог
lateral surface of the tooth.
latenuel Aircation tea eat accose terror that presents on the These infection man tooth henselves as primary acute infectior
The man exacerbation ed premeding chronic pertapical indect is. bender to bite and to peresistin, ine pertapical region is tend acut infasure, the tooth is slights raised in the socket due to the acute inflammation and swelling by tat periodontal inflammation, the tooth may be mobile.
There is an intense throbbing pain, if treatment is delayed bone resorption will allow the pus to drain under the periosteum with diminution of pain intensity.
A periapical radiograph may show no significant changes except for widening of the periodontal space especially in acute infections or it may reveal the presence of periapical radiolucency.

Periodontal infections

Arise from preexisting periodontal pocket, in some cases food impaction or repeated occlusal trauma are the precipitating factors.

The teeth involved are not necessarily non vital, an acute infection produces redness and swelling near the gingival margin, the pain is continuous, dull or throbbing but usually less than that

Experienced in acute periapical infections, pus may discharge from the gingival margin or may prodinieca sinus. The tooth may be mobile.

Pericoronal infections

Also called pericoronitis is an infection of the soft tissue covering abs crown of a partially is an id tooth, it is almost always Busiciated with partial, erupted impacted lower third molars.

Etiology involves:

Food impaction between the crown and the overlying fur (operculum) which is favourable site for bacterial proliferation and inflammation.

Trauma to the Overlying gum from the opposing tooth, but it is hard to determine whether the trauma occurs before or after the inflaretentry edema of the gum.

- Virulent microorganism.
- Lowering of the host resistance.

Pericoronitis appears to be the result of a combination of the aforementioned etiological factors.

The clinical presentation depends on the severity of infection

Chronic pericoronitis is either asymptomatic or there is mild discomfort.

In Subacute pericoronitis there is a dull pain which is well localized, the gum pad may be tender and red and there may be expression of a white material from underneath the gum flap, this material is composed of desquamated epithelial cells, food stuff, dead and living bacteria, there may be slight trismus and lymphadenopathy (LAP).

In Acute pericoronitis there is severe pain and limitation of mouth opening, intraoral swelling and there may be extraoral swelling as well as fever, malaise and LAP.

Pus may be expressed from underneath the flap, sometimes the pus may track submucosally and is expressed from a sinus in the molar or premolar region, this is termed migratory abscess.

Pericoronal infection:

Etiology involves:

…food impaction between the crown and the overlying gum (operculum) which is a fovorable site for bacterial proliferation and inflammation

…trauma to the overlying gum from the opposing tooth ,but it is hard to determine whether the truma occurs before or after the inflammatory edema of the gum.

…virulent microorganisms.

…lowering of the host resistance.

In treating pericoronitis, it is essential to determine if the tooth 18 likely to achieve full eruption upenis done by full clinical and radiographic examination, consideration should be given to the age of the patient and history of previous attacks.

Treatment of pericoronitis consists of:

- Drainage of abscess if present.
- If there is no abscess, gentle irrigation of the pericoronal space with normal saline, sometimes an antiseptic solution can be instilled in this space.
- If the upper third molar irritates the swollen gum flap, the pressure should be relieved by extraction or grinding the offending cusps.
- Antibiotics are needed for cases of acute infections.

.

Surgical extraction of the impacted teeth should be carried out after the inflammation subsides.

Infection of spaces in relation to the lower jaw

1. Submental space infection

Anatomic boundaries this space lies between the Mylohyoid muscle cervical fascia below, skin, subcutaneous tissue,
tissue, Platysma muscle and deep laterally by lower border of the mandible and anterior bellies of Digastric muscle.
It contains submental lymph nodes embedded in adipose tissues.
Source of infection a direct source is from infected lower incisors and canines, lower lip, skin overiving the chin or from the tip of the he anterior part of the floor of the mouth.
An indirect source bf infection is from submandibular spaces.
The site of the swelling is mostly extraoral including the chin and submental areas which are firmly swollen.
The site of incision and drainage is extraoral horizontal incision through the skin posterior to the crease behind the chin, providing dependent drainage and most esthetically acceptable scar.
It may be drained intraorally through the Mentalis muscle via the labial vestibule,
but the dependent drainage
can not be
established.

2. Submandibular space infection

Anatomic boundaries it is bounded by

Mylohyoid muscle

anterior and posterior bellies

superiorly,

of Digastric muscle

inferiorly,

Mylohyoid, Hyoglossus and Styloglossus muscles medially, laterally the space is bounded by the skin, superices lascia, Platysma, deep fascia and the lower border of the mandible This space contains the submandibular salivary gland and lymph nodes in addition to facial artery and vein, lingual and Hypoglossa nerve as they course deep to the submandibular salivary gland.

Source of infection is from the lower molar teeth especially second and third molars, as the infection perforates the lingual cortex not he mandible below the Mylohyoid muscle attachment.

Infection can also spread from the tongue, posterior part of the floor of the mouth, , upper posterior teeth, maxillary sinus and the submandibular salivary gland.

cheek, palate, the

Indirectly the infection may spread from infected sublingual and submental spaces.

Submandibular space infections can spread posteriorly to the pharyngeal space.

Submandibular space infection presents as a firm or fluctuant erythematous swelling of the submandibular region, the swelling bulges over and obliterates the inferior border of the mandible, there may be trismus, other signs and symptoms of infection may or may not be present.

Site of incision and drainage it is extraoral incision made parallel and about 2 cm. below the inferior border of the mandible to avoid injury to the marginal mandibular branch of the facial nerve, the incision extends through the skin and subcutaneous tissue only. while the space is entered bluntly to avoid structures within the space.



3. Sublingual space infection

Anatomic boundaries this is a V-shaped space, it is bounded anteriorly and laterally by the mandible, superiorly by sublingual mucosa, inferiorly by the Mylohyoid muscle and medially by Genioglossus, Geniohyoid and Styloglossus muscles.

Source of infection it is usually from the premolar and less commonly from molar teeth when the infection perforates the lingual cortex of the mandible above the attachment of the Mylohyoid muscle.

Indirectly the infection may spread from submental and submandibular spaces.

Infection from sublingual space may invade the submandibular and pharyngeal spaces.

Clinically there is erythematous swelling of the floor of the mouth. that may extend through the midline since the barrier between the two sublingual spaces is weak, usually there is elevation of the tongue.

Site of incision and drainage intraorally by an incision through the mucosa only parallel to Wharton's duct and lingual cortex in anteroposterior direction and away from the sublingual told.

This space may be drained extraorally through submandibular and submental incisions through the Mylohyoid muscle if the infection of these latter spaces is also evident.

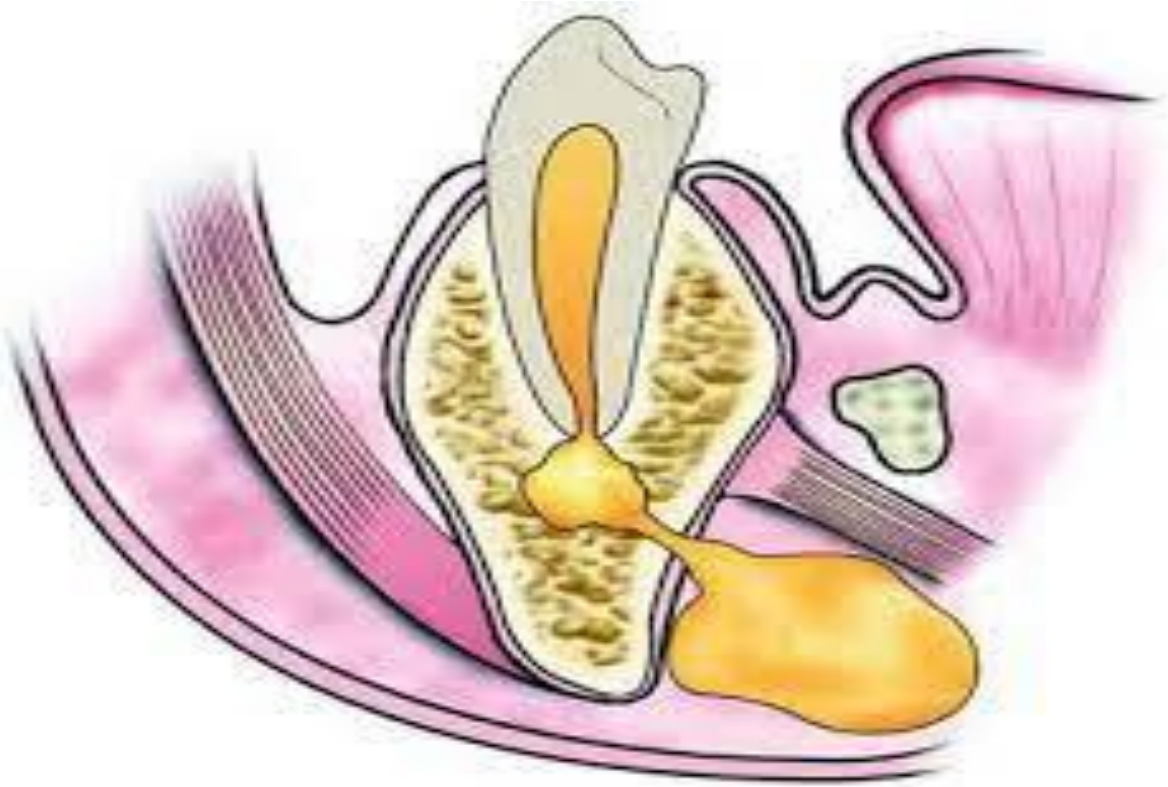

Ludwig's Angina

It is a massive firm cellulitis, affecting simultaneously the submandibular,, submental,sublingual , spaces bilaterally It is a very serious condition that requires prompt treatment, was described by Wilhelm Friedrich von Ludwig in 1836

Causes

- Dental infections in 90% of the cases.
- Submandibular salivary gland infections.
- Mandibular fractures.
- Soft tissue lacerations and wounds of the floor of the mouth.

The term angina is related to the sensation of suffocation.

If untreated this condition is almost fatal mainly due to posterior extension of the infection into thé epiglottis causing epiglottic edema and respiratory obstruction.

Signs and Symptoms:

There is a firm extensive bilateral submandibular swelling, intraorally there is swelling of the floor of the mouth that raises the tongue which may protrude from the mouth in extreme cases.

The patient is toxic, feverish and there is dyspnea and difficulty in swallowing.

Treatment :

- Securing the airway, endotracheal intubation is very difficult in this situation, tracheostomy may be needed, but it is also difficult to perform due to the massive neck edema.
- General anesthesia should be avoided.

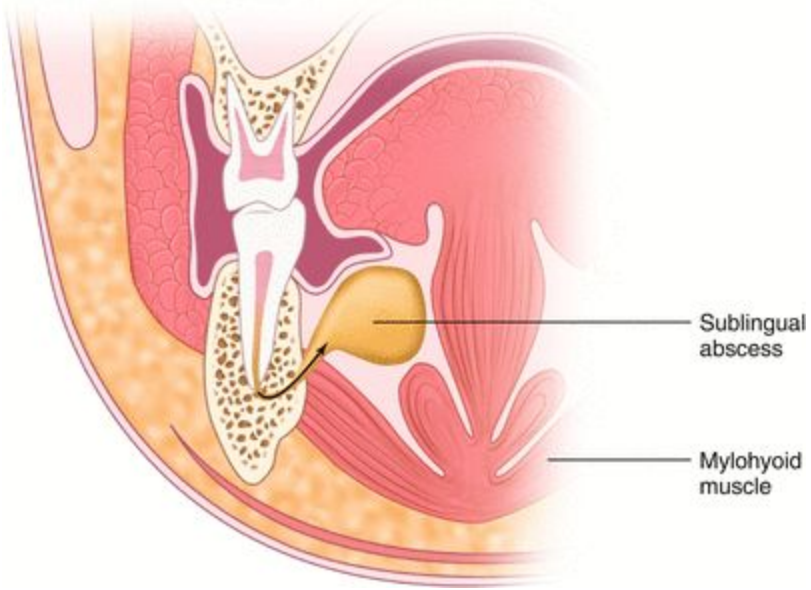
Sublingual abscess
Mylohyoid muscle

Ludwig’s angina

It is a massive firm cellulitis ,affecting simultaneously the submandibular ,submental and sublingual spaces bilaterally. It is a very serious condition that requires prompt treatment ,it was described by Wilhelmina fried rich von Ludwig in 1836.

Causes:

§Dental infections in 90% of the cases.

§Submandibular salivary gland infections.

§Mandibular fractures.

§soft tissue lacerations and wounds of the floor of the mouth.

12:31 AM Wed 11 Oct
ludwig's angina diagram
96%

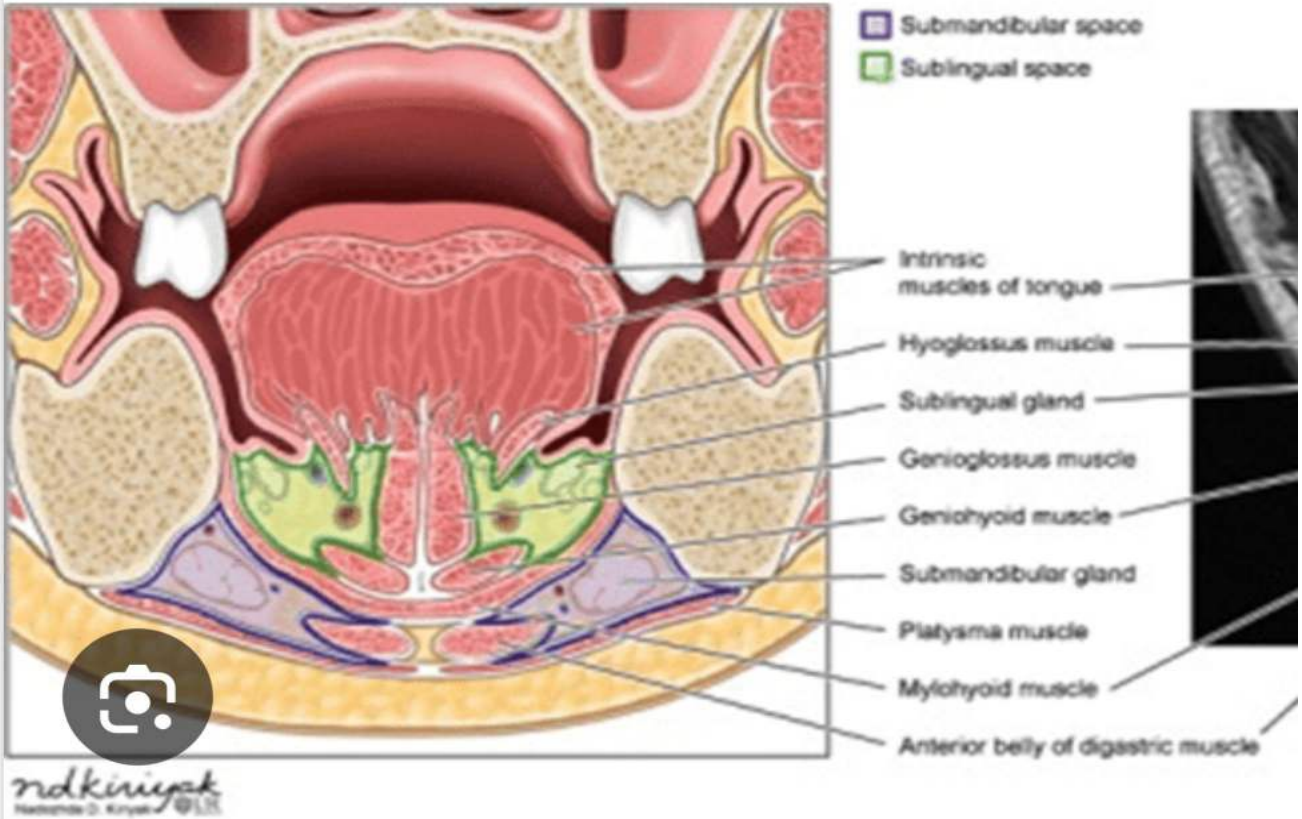

- Early surgical drainage of all the infected spaces bilaterally (under local anesthesia little pus is obtained since the infection is usually cellulitis.
- Intravenous antibiotic, using a combination of Penicillin and Metronidazole.

Some disciplines advocate high dose of antibiotics without surgery until fluctuation develops.

4-Buccal space infections

4. Buccal space infection

Anatomic boundaries bounded by the Buccinator muscle and Duccopharyngeal fascia medially, skin of the cheek laterally, labial musculature anteriorly, zygomatic arch superiorly, the inferior border of the mandible inferiorly, and the pterygomandibular raphe posteriory.

It contains the buccal pad of fat, facial artery and the parotid duct.

Source of infection of this space can be related to both jaws.

The relationship of the origin of the Buccinator muscle from the alveolar bone and the apecies of the upper and lower premolars and molars determines the direction of the spread of infection from these teeth. If the infection exits the alveolar bone above the attachment of the muscle in the upper alveolus or below the attachment in the lower alveolus, the infection spreads to the buccal space. Otherwise the infection spreads intraorally into the vestibule where it can be drained easily.

Usually the swelling appears in the cheek, the inferior border of the mandible can still be palpated.

Site of incision and drainage intraorally by a horizontal incision in the buccal mucosa below the parotid duct, the incision should be through the mucosa only, the space should be entered bluntlv using an artery or sinus forceps through the Buccinator muscle to avoid damage to the facial artery and nerve.

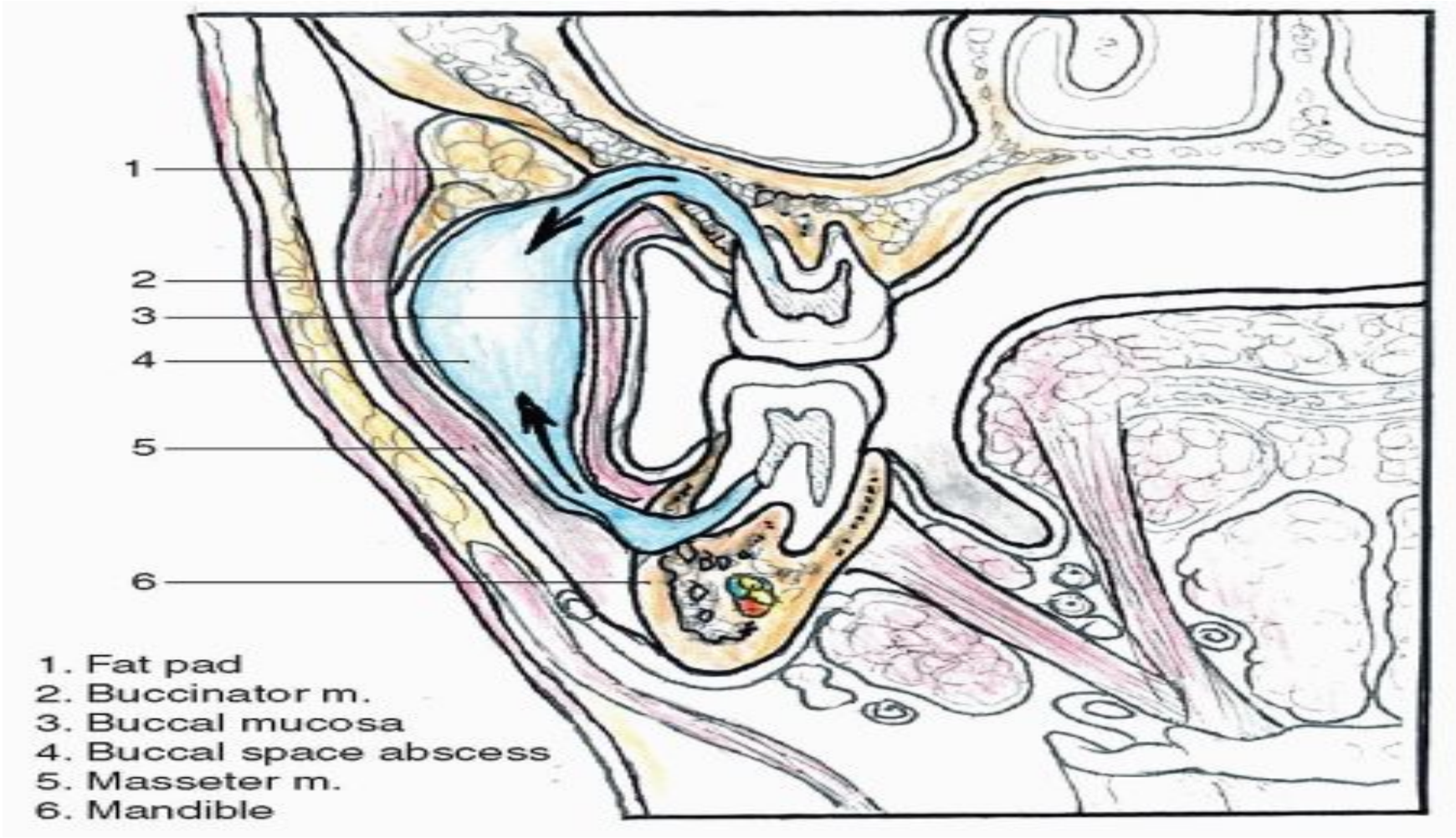
1
2
3
4
5
6
1. Fat pad
2. Buccinator m.
3. Buccal mucosa
4. Buccal space abscess
5. Masseter m.
6. Mandible

5-Masticator spaces infection

-massteric space.
-pterygomandibular space.
-temporal spaces.

These are well differentiated spaces but they communicate with each other as well as with the buccal, submandibular and pharyngeal spaces. They are:

Masseteric space,

Pterygomandibular space

Temporal space.

Masseteric space infection (also called submasseteric space)

Anatomic boundaries this space lies between the outer surface of the ascending ramus of the mandible medially, the Masseter muscle laterally and the parotid gland posteriorly.

Source of infection usually from molar teeth especially lower third molars, it can also occur after fracture of the angle of the mandible or it can also spread from buccal space.

The swelling is moderate in size over the ascending ramus and the angle of the mandible region. This infection is characterized by a (marked trismus. Chronic abscess can run a protracted course and can spread to the muscle itself or it can cause osteomyelitis of the ramus of the mandible.

Site of incision and drainage extraorally below and behind the angle of the mandible, the incision is carried through the skin and the subcutaneous tissue then by blunt dissection through the Platysma muscle and the deep fascia, after incising the attachment

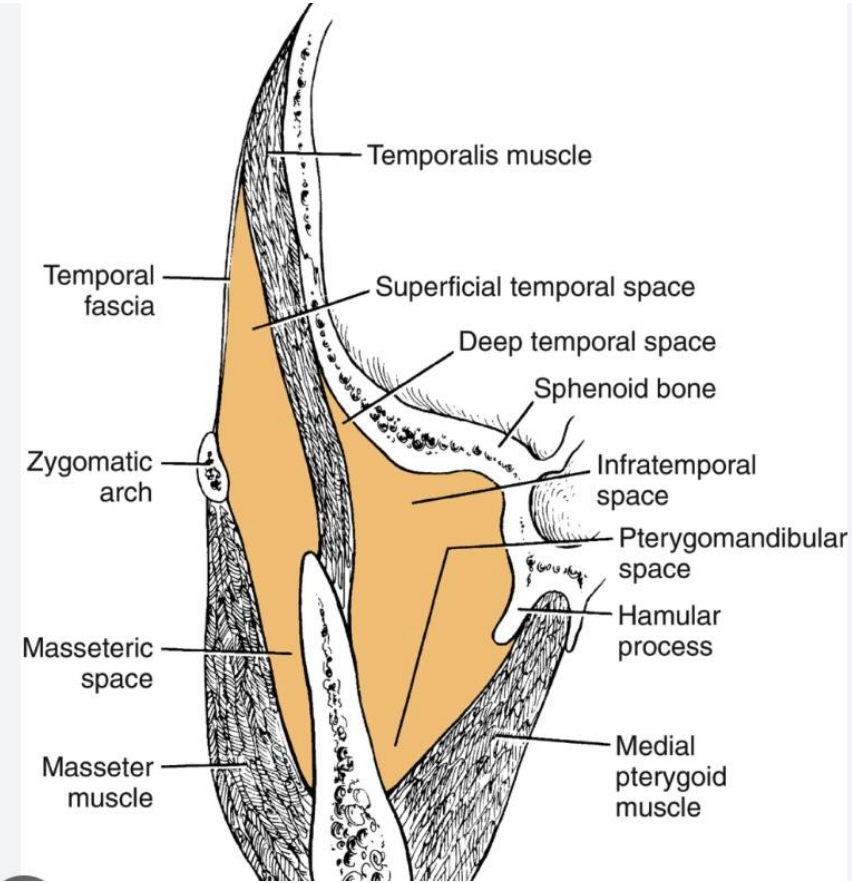
Temporalis muscle
Temporal fascia
Superficial temporal space
Deep temporal space
Sphenoid bone
Zygomatic arch
Infratemporal space
Pterygomandibular space
Hamular process
Masseteric space
Masseter muscle
Medial pterygoid muscle

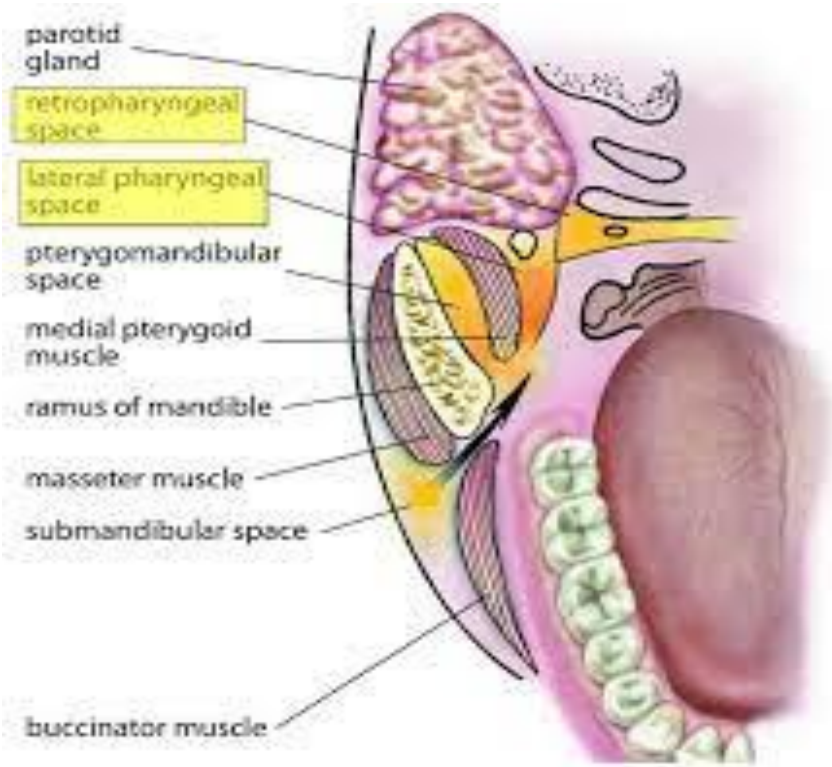
parotid gland
retropharyngeal space
lateral pharyngeal space
pterygomandibular space
medial pterygoid muscle
ramus of mandible
masseter muscle
submandibular space
buccinator muscle

6-lateral pharyngeal space

6. Lateral pharyngeal space infection (also termed parapharyngeal space)
Anatomic boundaries this space extends from the base of skull to the hyoid bone, it is conical in shape, the lateral boundaries include the medial surface of the Medial Pterygoid muscle. the medial wall is the Superior Constrictor muscle, Styloglossus muscle, Stylopharyngeus muscle and the Middle Constrictor muscle of the pharynx/Posteriorly by the parotid gland and anterirorly by ptergomandibular raphe. This space can be divided into two compartments; anterior and posterior, the latter contains the carotid sheath.
Source of infection, spread of infection from upper and lower molar teeth, most commonly from lower third molar infections by the way of submandibular, sublingual and pterygomandibular spaces.
A non-odontogenic infection can spread to this space like tonsillar infections.
Infections of this space are serious, the patient exhibits pain, fever, chills, medial bulge of the lateral pharyngeal wall, extraoral swelling below the angle of the mandible and trismus. It may lead To respiratory obstruction, septic thrombosis of the internal jugular vein and carotid artery hemorrhage.
Site of incision and drainage intraoral incision medial to the pterygomandibular raphe with the dissection medial to the Medial
Pterygoid muscle.
Extraoral incision at the level of the hyoid bone anterior to the Sternocleidomastoid muscle (SCM) and the dissection continued

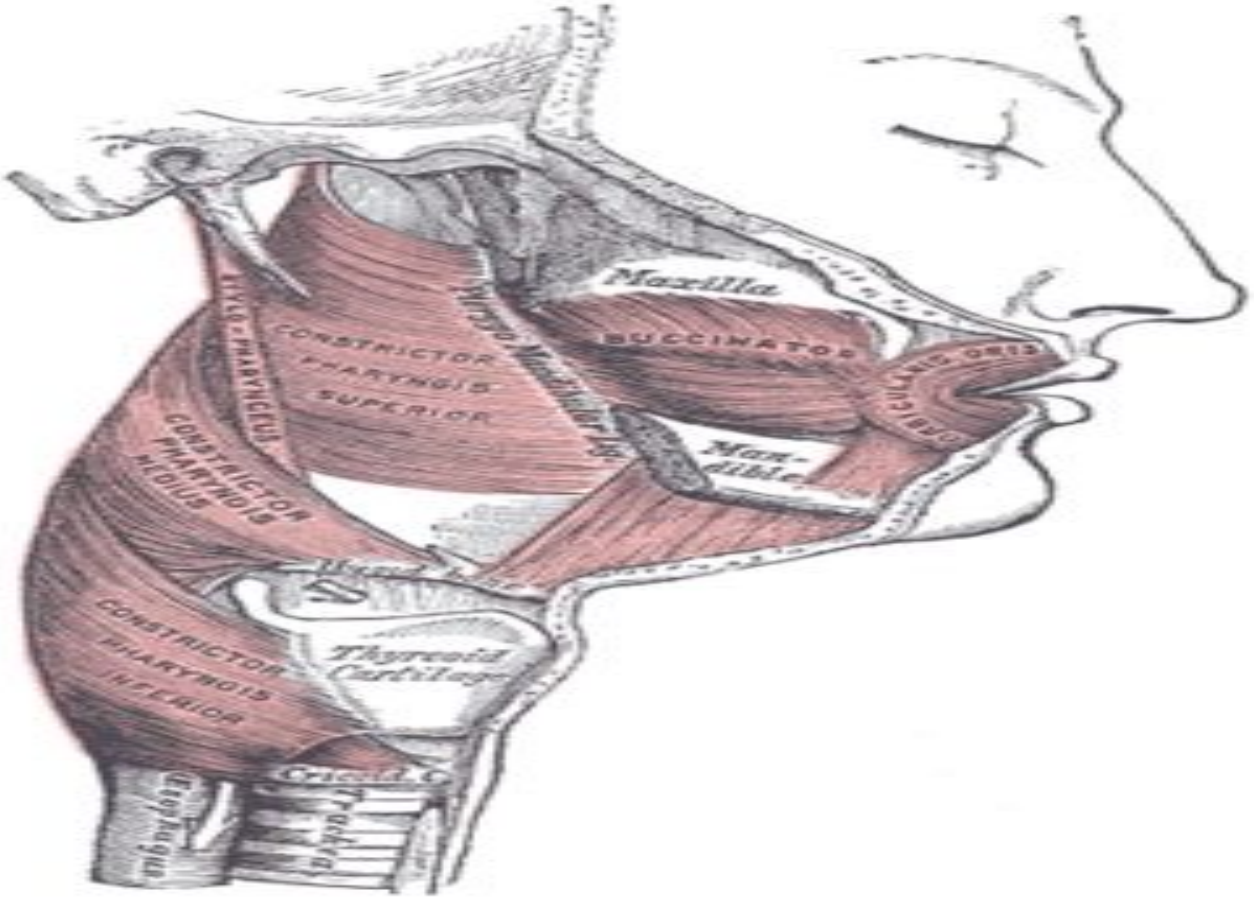
Maxilla
BUCCINATOR
CONSTRICTOR PHARYNGIS SUPERIOR
CONSTRICTOR PHARYNGIS MEDIUS
CONSTRICTOR PHARYNGIS INFERIOR
Thyroid Cartilage

7. Retropharyngeal space infection

Anatomic boundaries extend from the base of the skull to the upper mediastinum (C6-TI), it is bounded anteriorly by posterior wall of the pharynx and posteriorly by the Alar fascia.

Source of infection upper and lower molar teeth by lateral pharyngeal space by the way of pterygomandibular, submandibular, sublingual spaces.

It can also result from nasal and pharyngeal infections.

The swelling causes bulge of the posterior pharyngeal wall, there is dysphagia, dyspnea, and fever. Lateral neck radiograph may reveal widening of the retropharyngeal space.

Site of incision and drainage extraorally by an incision anterior to the SCM below the hyoid bone SCM and the carotid sheath are retracted laterally and blunt dissection is carried out deeply to enter the space.

Some authors advocated intraoral drainage by an incision along. the posterior pharyngeal wall in extreme Trendlenburg position and suction.

Most anesthesiologists prefer tracheostomy to secure the airway.

7-Reteropharyngeal space infection

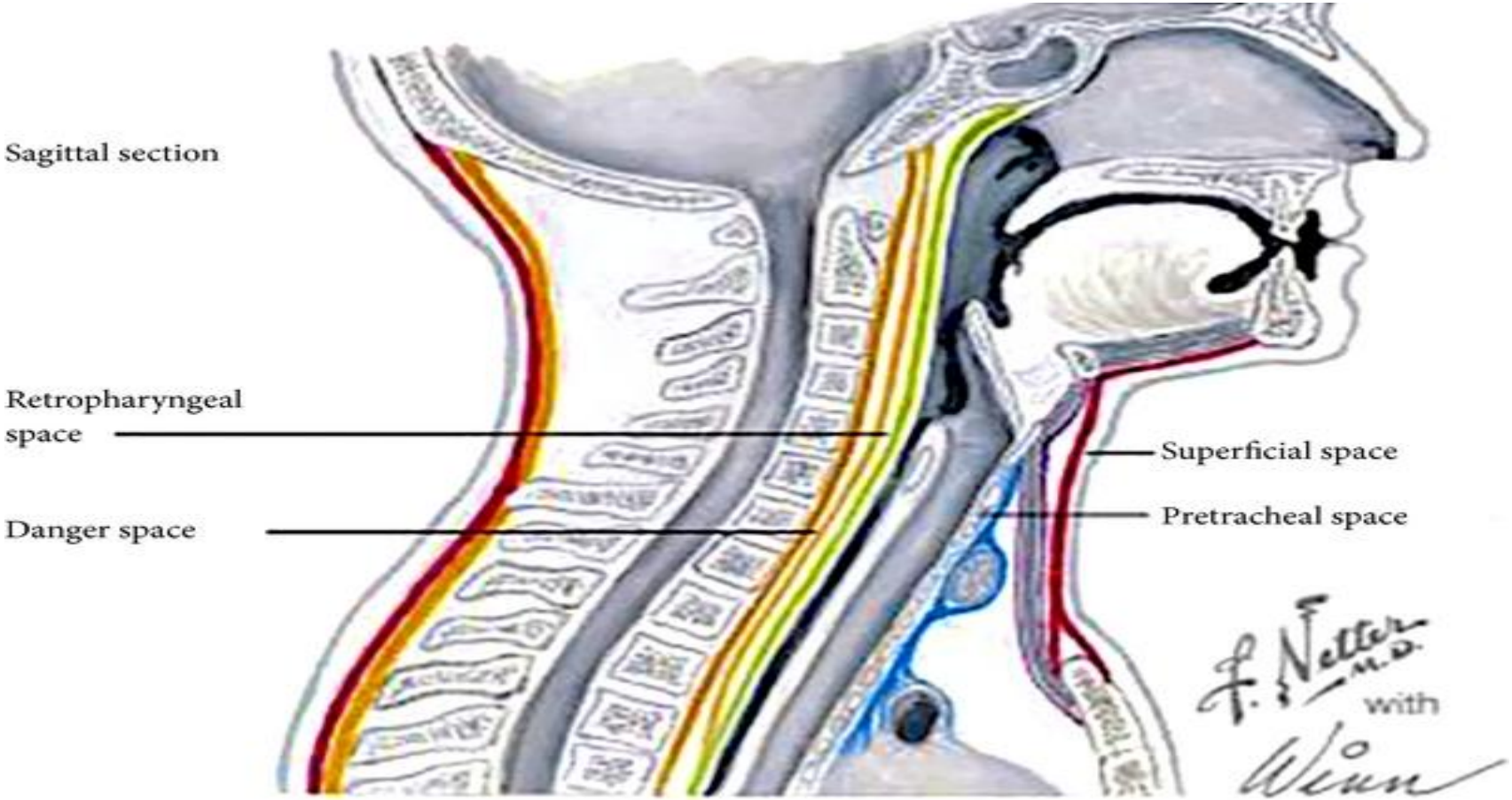
Sagittal section
Retropharyngeal space
Danger space
Superficial space
Pretracheal space
F. Netter M.D.
with

8-peritonsilar abscess

8. Peritonsillar abscess or Quinsy

Anatomical boundaries it is localized between the C.T. bed of the faucial tonsil and the Superior Constrictor muscle of the pharynx.

Source of infection it arises from tonsillitis, but it is occasionally a complication of pericoronitis of the lower third molar.

It causes swelling of the anterior pillar of the fauces and a bulge of the soft palate of the affected side which may reach the midline and push the uvula. Also there is acute pain, dysphagia, the voice becomes muffled, odynophagia, drooling and anorexia.

Site of incision and drainage the incision is placed in the point of maximum fluctuation, this can be done under local anesthesia, general anesthesia is used the anesthetist should be experienced and good suction be available to prevent aspiration and the patient should be in head down position.

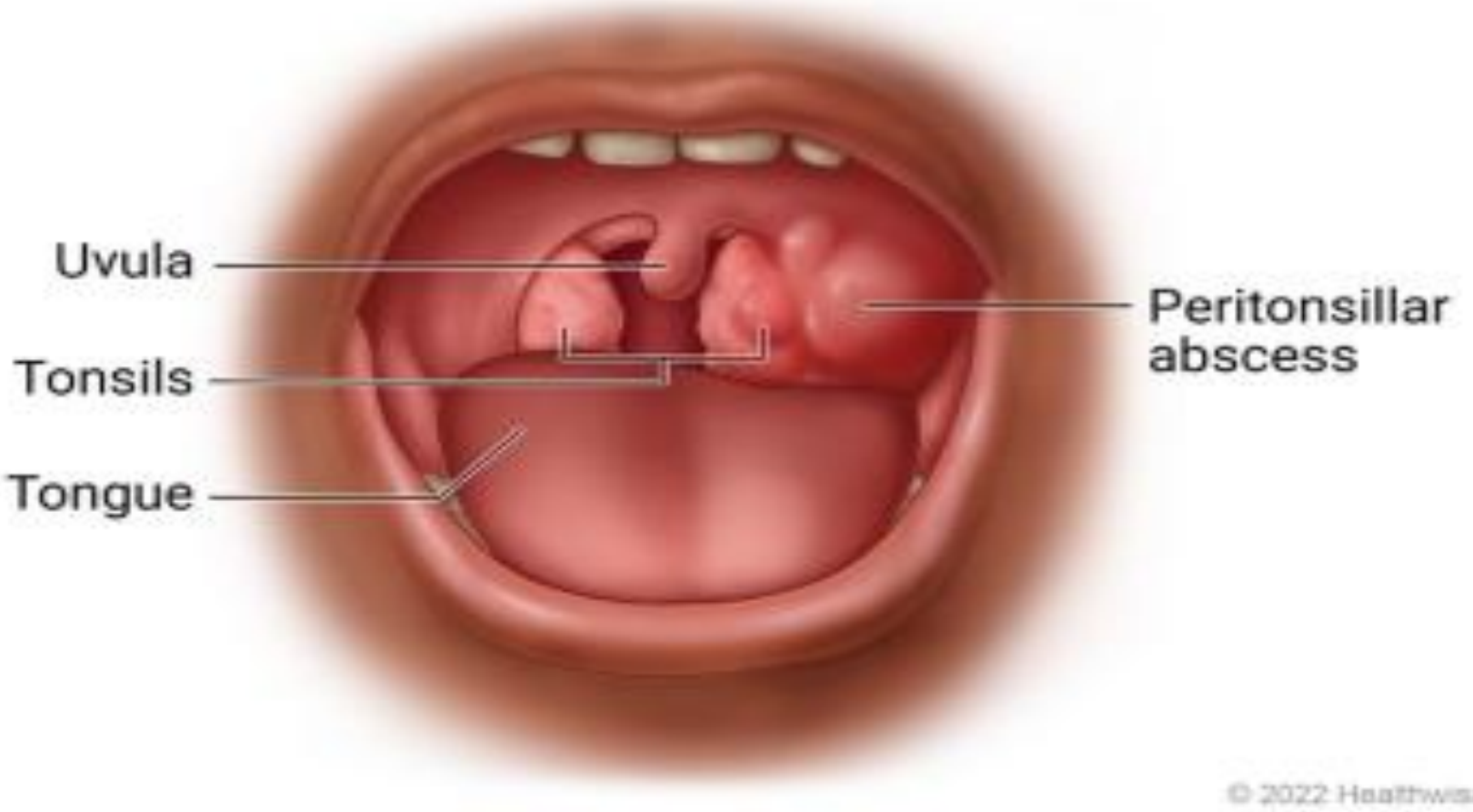
Uvula
Tonsils
Tongue
Peritonsillar abscess
© 2022 Healthwise

Infection of space in relation to the upper jaw

1-upper lip infection



Infections of spaces in relation to the upper jaw

1. Upper lip infection

Infections of the upper incisors and canines can spread to the upper lip usually on the oral side of Orbicularis Oris muscle and points in the vestibule.

Infection of the upper lip can lead to serious complications like orbital cellulitis or cavernous sinus thrombosis by extension of infection through the superior labial vein to anterior facial vein to ophthalmic vein to cavernous sinus.

Incision for drainage is made near the vestibule intraorally.

Cannie fossa infection

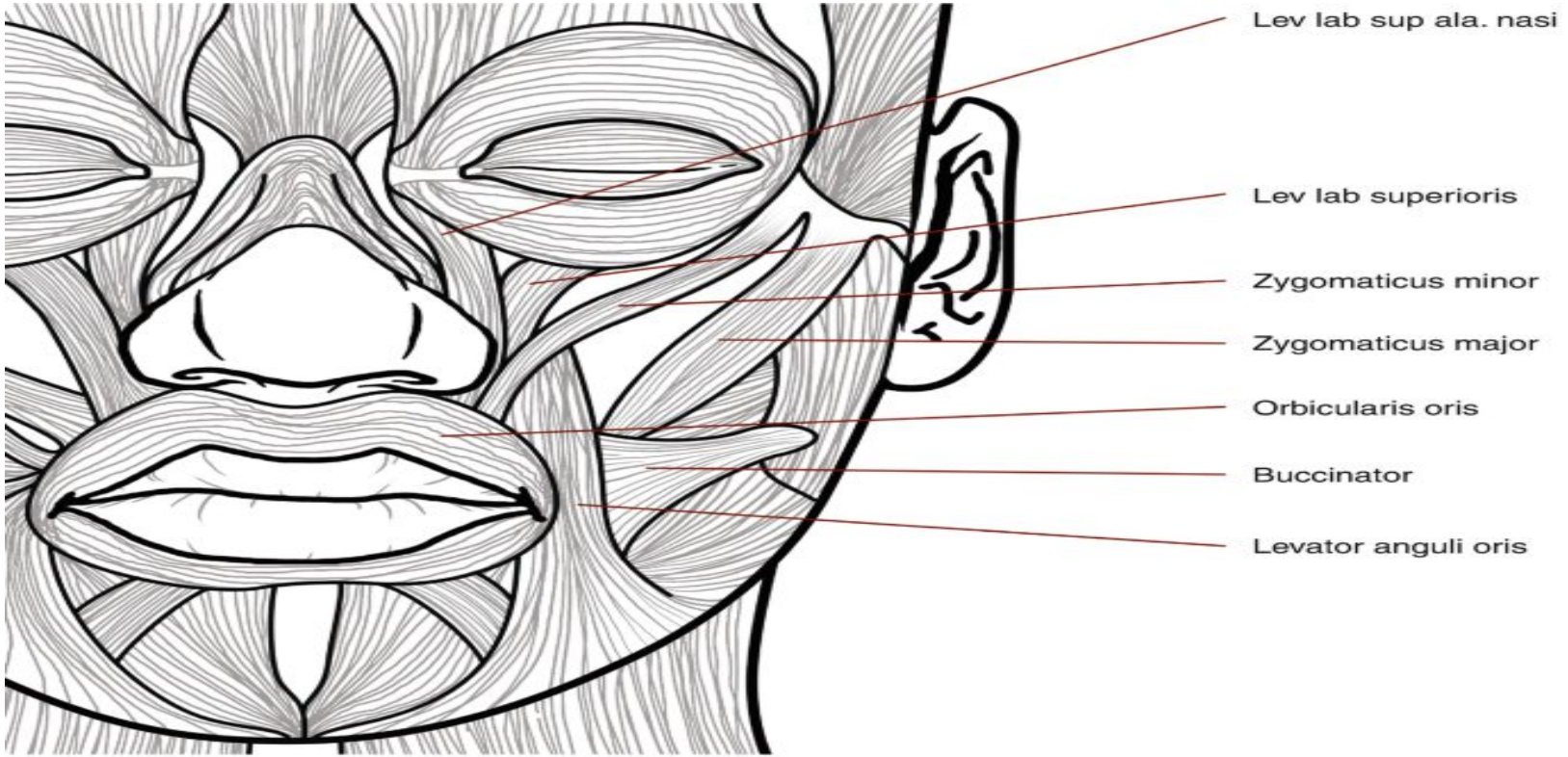

©Association of Oral and Maxillofacial Surgeons of India

2. Canine fossa infections

Anatomic boundaries it lies between the canine fossa and the muscles of the facial expression.

Source of infection mostly is the canine and first premolar but the infection can spread from upper incisor teeth.

Infection occurs when it spreads in the area above the origin of the Levator Anguli Oris and is directed toward the medial edge of the
Levator Labii Superioris.

The swelling is lateral to the nose leading to obliteration of the nasolabial fold and may lead to periorbital cellulitis, there is risk of cavernous sinus thrombosis.

Site of incision and drainage intraoral horizontal incision in the buccal vestibule.

3-buccal space infection

4-subperiosteal abscess in the palate

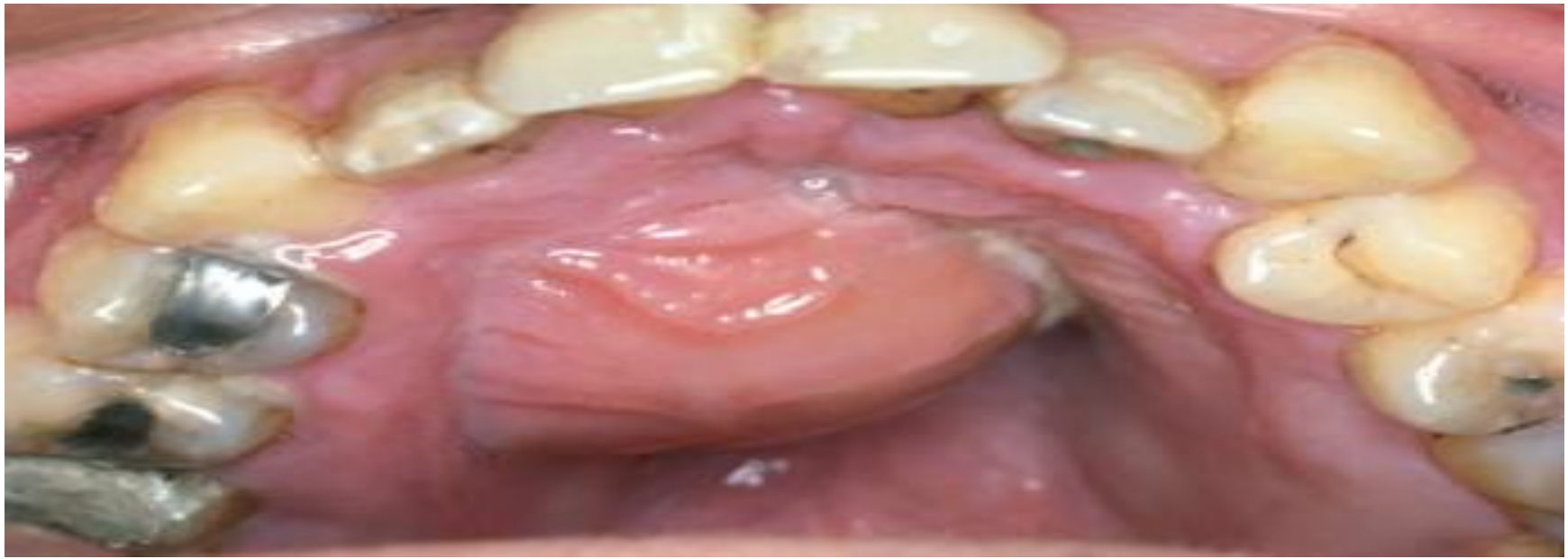

3. Buccal space infections

Infections spread from infected upper molar teeth where it spreads buccally above the attachment of Buccinator muscle. This space is already discussed.

4. Subperiosteal abscess in the palate

This potential space lies between the palatal mucoperiosteum and the underlying bone, the mucoperiosteum is strongly attached in the midline and at the gingival margin, pus may accumulate beneath the mucoperiosteum leading to its separation from the underlying bone.

Source of infection it may spread from the apex of the lateral incisor which is close to the palatal bone. Also infection can spread from the palatal root of multirooted upper molars. It can also originate from palatal periodontal pocket.

The swelling causes palatal bulge between the gingival margin and the midline, confined to one side.

5-maxillary antrum

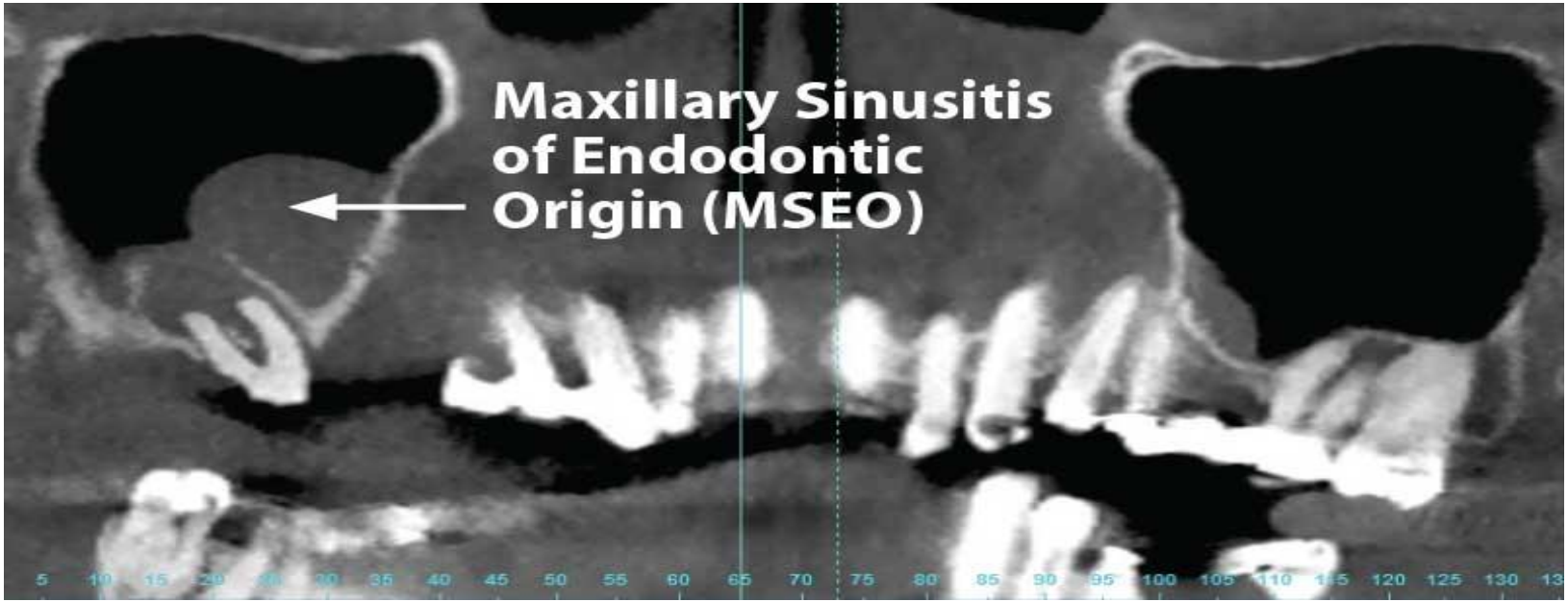

5. Maxillary antrum

infection from upper molars and less frequently premolars may spread to the maxillary antrum, this depends on the size of the maxillary antrum and the length of the root.

It causes acute sinusitis with facial pain that worsens on bending or leaning forward, the infection may lead a chronic course leading to mucosal thickening and polyps.

Occipitomental radiograph shows opaque maxillary sinus or fluid level.

Pus may drain partially through the sinus osteum, extraction of the causative tooth leads to drainage of pus but it may leave a defect in the floor of the sinus and cause oroantral fistula. If the defect is small and with antibiotic treatment the socket may heal uneventfully, but larger defects may require further management.

Infratemperal spaces infection

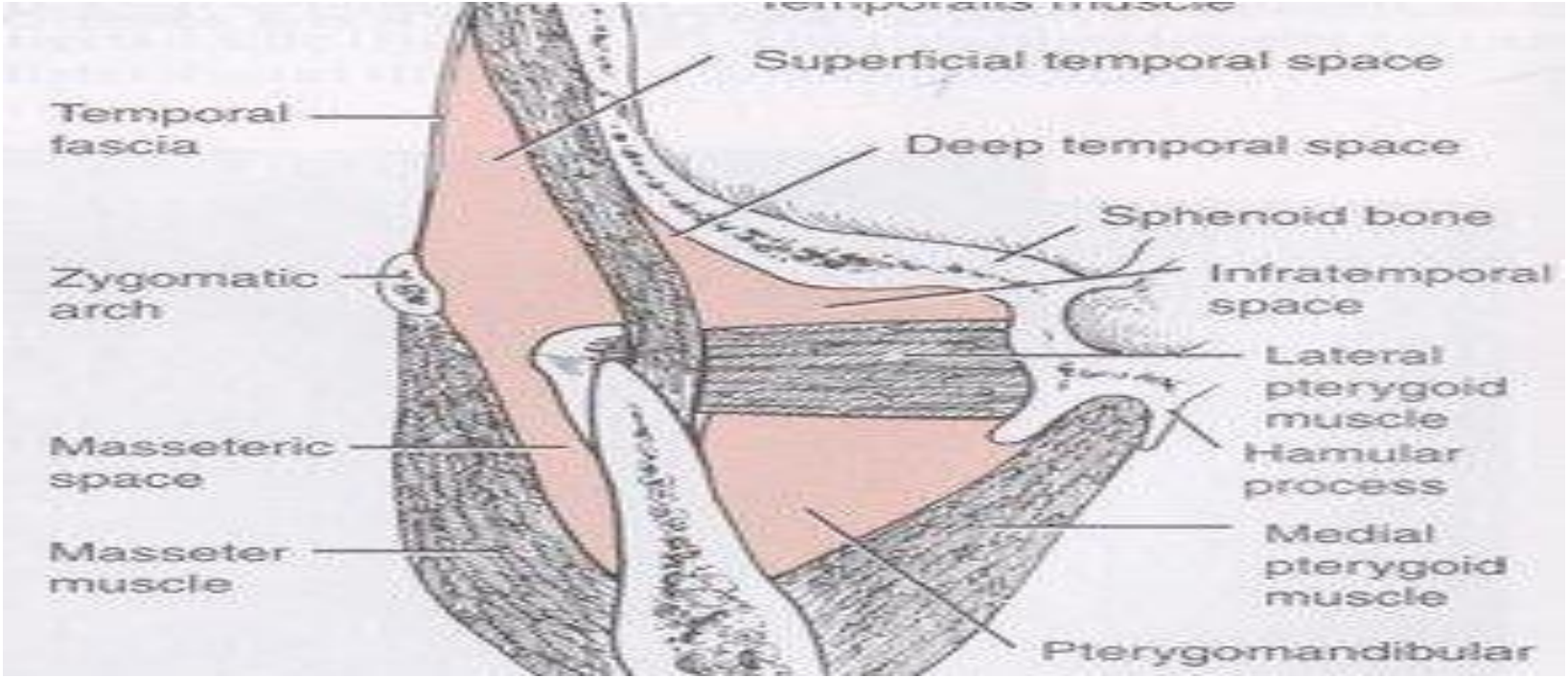

6. Infratemporal space infection

Anatomic boundaries this space is bounded laterally by the ramus of the mandible and the Temporalis muscle, medially by lateral

pterygoid plate, superiorly by infratemporal surface of the greater wing of the sphenoid.
It is traversed by the maxillary artery and contains pterygoid venous plexus. It represents the upper extremity of the pterygomandibular space.
Source of infection directly from upper molar teeth or through contaminated needle from the pterygomandibular space.
Infection may spread to the temporal space.
There could be moderate swelling in the temporal region with trismus, usually the patient is toxic with high temperature. These infections are serious since they can spread through the pterygoid venous plexus to the cavernous sinus through emissary vein or it can spread to the middle cranial fossa with headache, photophobia, irritability, vomiting and drowsiness.
Site of incision and drainage intraorally through an incision buccal to the upper third molar following the medial surface of the corronoid upward and backward, but with the presence of trismus this approach is difficult. Extraorally through an incision in the upper and posterior edges of the Temporalis muscle within the hair line passing downward, forward and medially.
Infection related to the maxillary teeth can spread to the masticator spaces and pharyngeal spaces and these were already discussed.

9-cavernous sinus thrombosis

Causes
Clinical features
Treatment

It is a very serious ascending infection, although not a fascial space infection but it can be caused by odontogenic infections especially of upper teeth. It can also result from upper lip, nasal and orbital infections.

Infection can spread to the cavernous sinus through two routes:

- Anterior route; through the valveless angular vein and inferior ophthalmic vein.

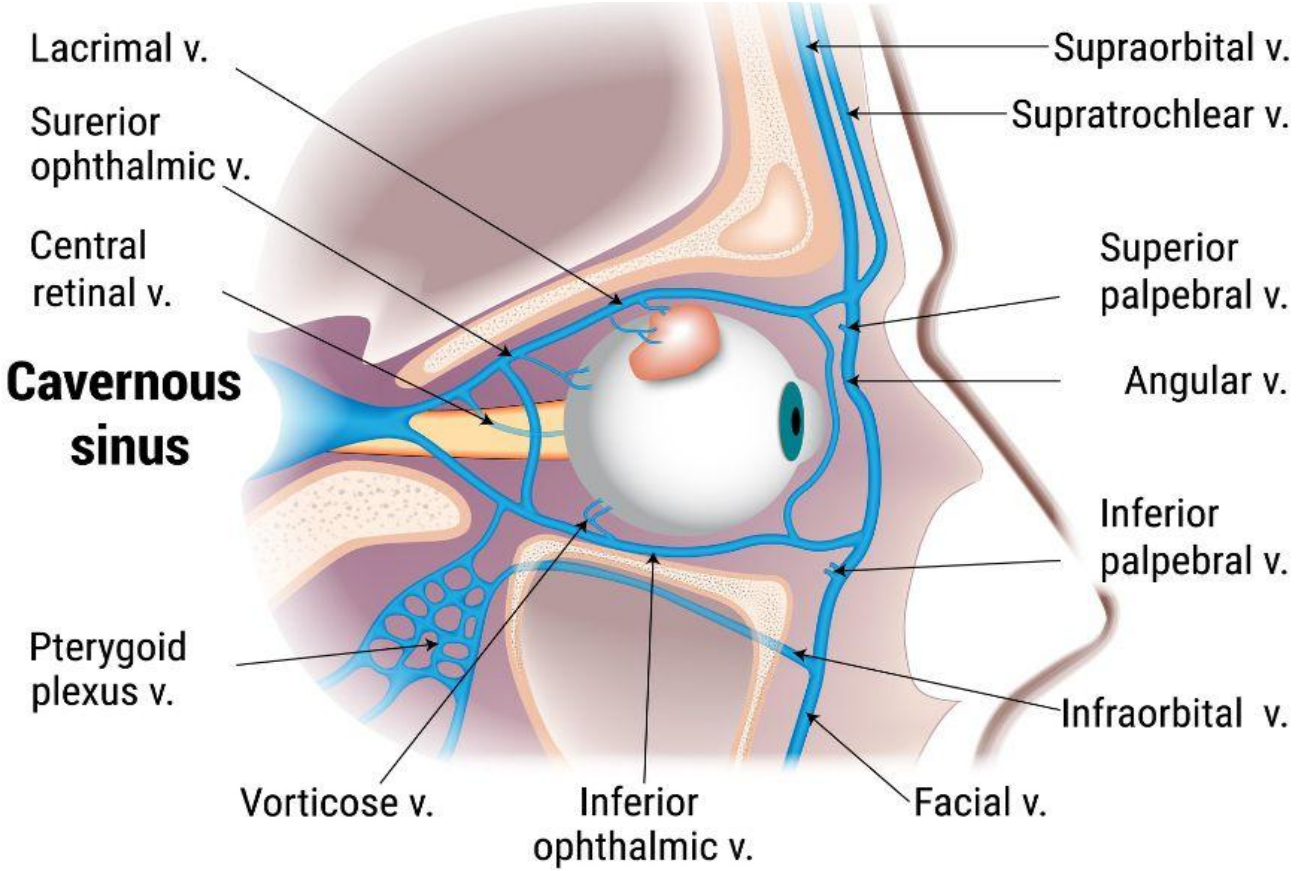
Lacrimal v.
Surerior ophthalmic v.
Central retinal v.
Cavernous sinus
Pterygoid plexus v.
Vorticose v.
Inferior ophthalmic v.
Facial v.
Infraorbital v.
Inferior palpebral v.
Angular v.
Superior palpebral v.
Supratrochlear v.
Supraorbital v.



Indication of incision and drainage

Pus accumulation

Deep space

Rapid evolving infection

Indication of incision and drainage:

- When there are signs of accumulation of pus, ideally abscess should be drained when fluctuant, prior to spontaneous rupture and drainage.

When the involved compartment is inaccessible; like pterygomandibular or pharyngeal spaces, where it is not possible to elicit the classic signs of suppuration, such as ;

when there is no improvement with adequate doses of antibiotic, recurrence of pyrexia or a sudden increase in temperature and severe trismus.

- Serious and rapidly evolving infections of the neck and floor of the mouth, like Ludwig's angina

.

Principles of incision and drainage

Principles of incision and drainage:

1. Incise in healthy skin and mucosa as possible, incisions should be placed in an area of maximum fluctuation in a dependent position to encourage drainage by gravity.
Incisions made in areas where the tissue is necrotic or beginning to perforate may leave unaesthetic scars.
2. It should be placed in an esthetically acceptable area, in a natural skin crease or fold.
3. Incision in the skin of face and neck should include only the skin and subcutaneous tissues and the dissection through deeper tissues is continued bluntly using closed sinus or artery forceps which are advanced by controlled pressure to the pus containing tissue space and opened inside the cavity, then the forceps are drawn open then closed again and reinserted. The process is repeated until all the pus is evacuated. This is termed Hilton's method (after john Hilton, an English surgeon 1804-1878).

The role of antibiotics resistantance

1-long term antibiotic used
2-intrinsic resistance
3-nontherapeutic used
4-careless disposals of wastes
5-animals ingestion

Failure of antibiotic therapy may be attributed to:

- Inadequate surgical treatment.
- Depressed host defense.
- Presence of foreign body.
- Problems associated with the patient and antibiotic, like lack of patient's compliance and inadequate dose...etc

.

The role of dentists in antibiotic resistance

The cause of bacterial resistance is multi-factorial including:

1. Long term and repetitive use of broad spectrum antibiotics.
2. Intrinsic resistance.
3. Non-therapeutic use of antibiotics in agriculture.
4. Careless disposal of wastes by the pharmaceutical industry.
5. Ingestion of animals treated with prophylactic or therapeutic antibiotics.

FDA estimates that 13 million Kg. of antibiotics are used in animals, while 1.5 million Kg. are used in humans annually.

Prophylactic use of antibiotics in animal agriculture to compensate for unsanitary conditions leads
to contamination of the
environment with antibiotics.

As dentists and oral surgeons we can do little to the use of agriculture or dumping of antibiotic by-products into environment, but we can strive to practice responsible evidence based dentistry by adhering to the up to date principles and guidelines.

Sinus formation

When the abscess is not drained properly and neglected for a sufficient period of time, it will burst and drain spontaneously leading to sinus formation in an unfavorable site, the sinus is puckered, thickened and depressed, if the source of infection is not treated the sinus will become chronic and it will be subject to exacerbations and remissions.

During the active phase the sinus will exhibit signs of inflammation and may be tender while in the quiescence phase it heal over.

Sinus excision, after treatment of the source of infection, is carried out through an elliptical incision around the external orifice of the sinus, the tract of the sinus is followed bluntly to its source on the surface of the bone of the mandible. The resulting defect is closed in layers to eliminate dead space, the skin is closed with careful eversion to ensure an acceptable scar.

Thank you.