Principles of Surgical Management of Impacted Third Molar
Part II

By:Dr.Ahmed Talib Al-Araji

Surgical procedure

Patient positioning

Generally, for operative procedures in mandible the occlusal plane of lower teeth should be parallel to the floor and for the maxillary teeth the occlusal plane of the upper teeth at 45° angles to the floor. The instruments are arranged in a rational order of their intended use over the instrument tray of the dental chair or more preferably on a separate instrument trolley.

Incision and Designing the Flap

• As a general rule, the deeper the third molar more extensive the bone removal required and the necessity for tooth sectioning.

• The most commonly used flap is the envelope flap, which extends from just posterior to the position of the impacted tooth anteriorly to the level of the first molar. The posterior end of the incision is directed buccally along the external oblique ridge.

• If greater access is required, a release incision is given on the anterior aspect of the incision, creating a triangular flap (started from a point approximately 6 mm down in the buccal sulcus and then extended obliquely upwards to the gingival margin to a point at the junction of the posterior and middle thirds of the second molar).

• The blunt end of the periosteal elevator is passed beneath the mucoperiosteum to reflect the soft tissue.

• Reflection of lingual mucoperiosteum is kept to the minimum to avoid injury to lingual Nerves .

Bone Removal

The amount of bone removal varies with the depth of impaction remove sufficient amount of bone to free the tooth from obstruction and to provide a point of application for the elevator.

A. A common technique 'lingual split bone technique' introduced by Ward (1956)a section of bone lingual to the wisdom tooth is fractured off to facilitate the removal of the impacted tooth.

B. Buccal approach; should be kept to minimum to avoid weakening of the mandible.

1. The bone on the buccal and the distal aspect of the impacted tooth is removed down to the level of the cervical line (Further bone removal if required is done in a manner not detrimental to the strength of mandible)achieved by drilling a deep vertical gutter alongside the buccal aspect and if required on the distal aspect of the tooth.

2. Guttering method will ensure that the height of the buccal plate is maintained without weakening the mandible and adequate space is created for tooth delivery.

3. As the bur reaches the apex of the tooth, the inferior alveolar canal may be opened brisk haemorrhage from inferior alveolar vessels controlled with pressure pack or bone wax.

4. Drilling in the region of the mesial surface of impacted tooth should be kept to the minimum avoid damage to the distal aspect of second molar.

.

5. Removing bone on the distolingual aspect care protect the lingual.

6. Moderate force alone is sufficient to displace the tooth.

7. If the tooth is still resistant plan for further bone removal or tooth sectioning.

8. At the time of elevating the tooth, the index finger of the operator's left hand should

rest on the occlusal surface of the wisdom tooth to judge its movement and the

other fingers support the mandible.

9. In order to apply the elevator, a point of application (purchase point) is required

either in the bone or a bur cut is made on the tooth deep enough and placed in substantial portion of tooth structure elevation of rather than fracture

Sectioning and Tooth Delivery

Tooth sectioning is performed either with a bur or a chisel and it helps to;

- reduce operating time
- Avoid the need to remove additional amount of bone.

A- First section is generally done at the neck of the tooth using bur facilitate the removal

of the crown followed by the roots in one piece.

B- Divergent roots roots have to be divided and removed separately.

C- The following key points should be observed while performing tooth sectioning:

If sectioning tooth in a buccal to the lingual direction only three quarters the way is cut using bur. The reminder is then split with a straight elevator prevents injury to the lingual cortical plates and lingual nerve

• The line of sectioning of crown/tooth should be perpendicular. If NOT sectioned segment will be wider at the bottom elevation will be difficult

• If sectioning in the superior to inferior directoryEntry of bur is limited to

three fourth of the width of the tooth and the rest is separated with elevator if NOT possibility of damaging the contents of the canal

Modifications for Removal of Impacted Tooth

• Mesioangular impaction; Buccal gutter is extended mesially to reach the mesial surface of impacted tooth beneath the cementoenamel junction tip of the elevator can engage beneath the cervical cementum on the mesial aspectthe tooth turns distal mesial angulation of the tooth into a vertical position deliver the tooth. If removal is difficult remove necessary distal bone and/ or sectioning the distal half of the crown to just below the cervical line

Mesioangular tooth is 'locked' beneath the distal convexity of the crown of the second molar section impacted tooth crown at the cervical region remove coronal portion by applying force below its inferior surface The roots are removed by engaging the bifurcation

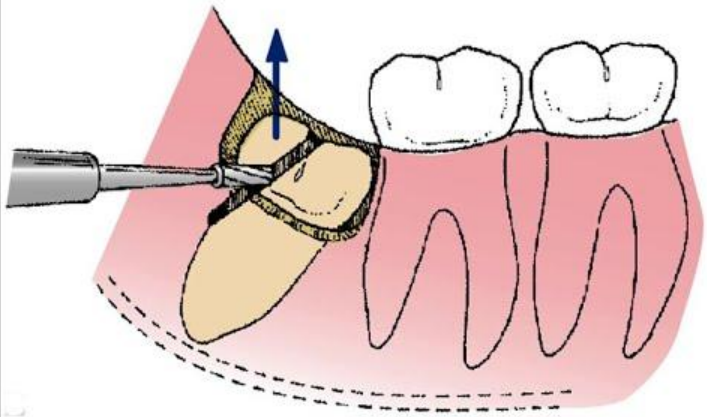

Sectioning the tooth (Mesioangular Mandibular Impaction)

Impacted Teeth (Lecture 9)

Prof Dr Syed Amjad Shah

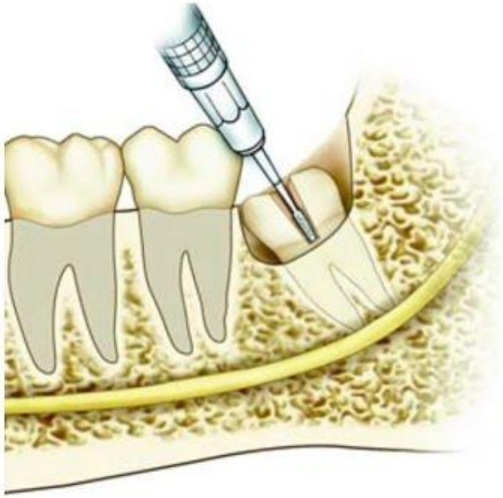

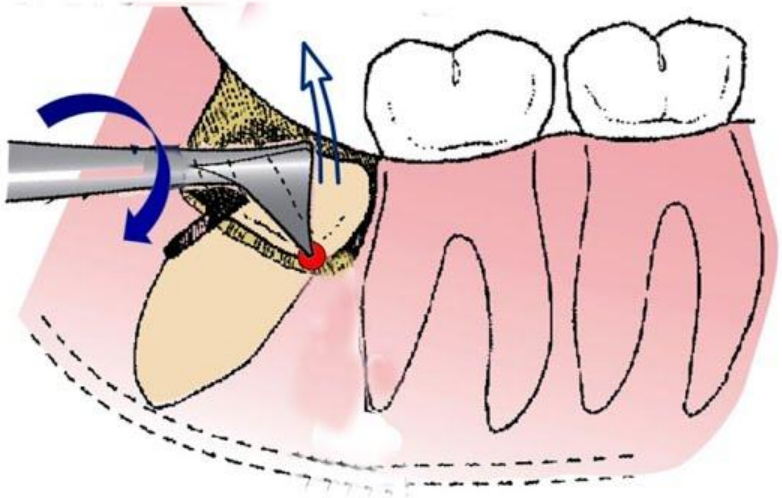



The horizontal impaction; Bone is removed superiorly to expose the whole width of the crown and the upper third of the root tooth sectioned at the cervical region crown is removed The root is then brought forwards into the space previously occupied by the crown removed either in a single piece or after sectioning. If impacted tooth is not locked beneath the crown of the second molar turn the tooth into a vertical position by application of force in the mesial aspect.

• Deep vertical impaction; one of the more difficult ones to remove. Bone is removed first from the occlusal, buccal, and distal aspect. The distal half of the crown is then sectioned and removed, and the tooth is elevated by applying a small straight elevator at the mesial aspect of the cervical line.

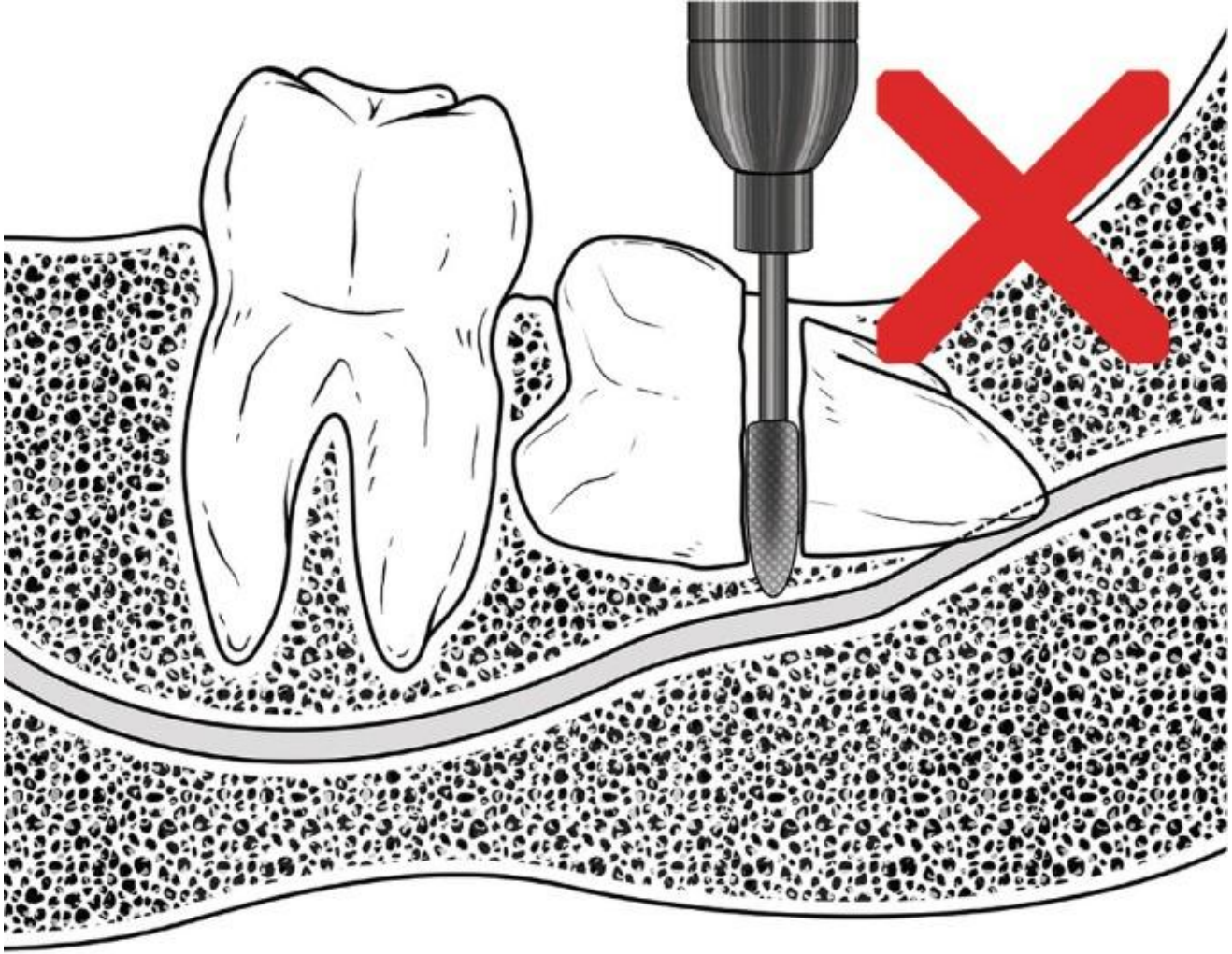

©Association of Oral and Maxillofacial Surgeons of India

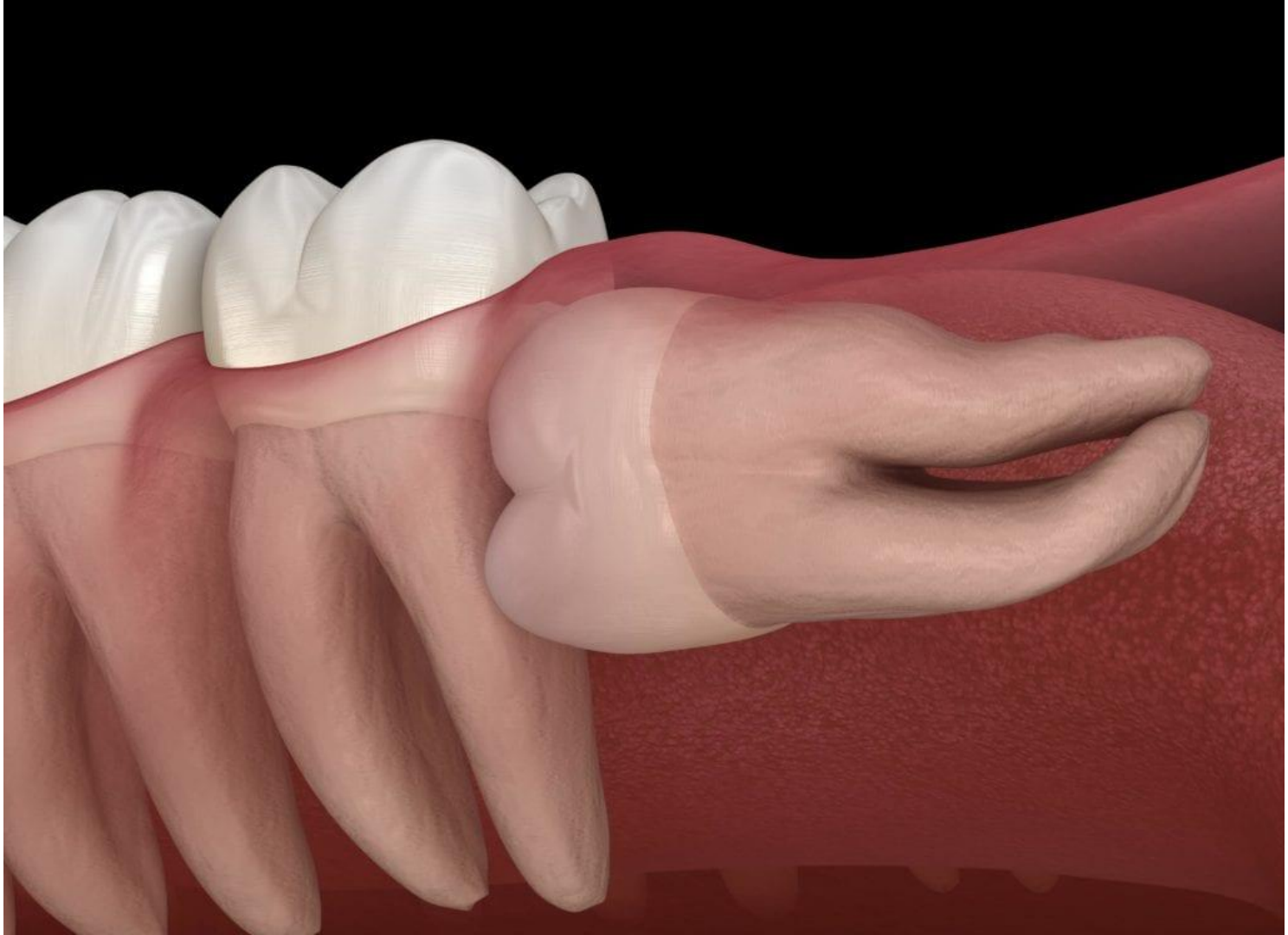

Less deep vertical impactions, mesial application of force with an elevator can dislodge the tooth

• Vertical impaction with widely divergent roots; crown is divided first followed sectioning of the roots and its subsequent removal.

• A deep, vertically impacted third molar below the cervical line of the second molar and fully covered with bonetooth should be exposed and a buccal and distal trough

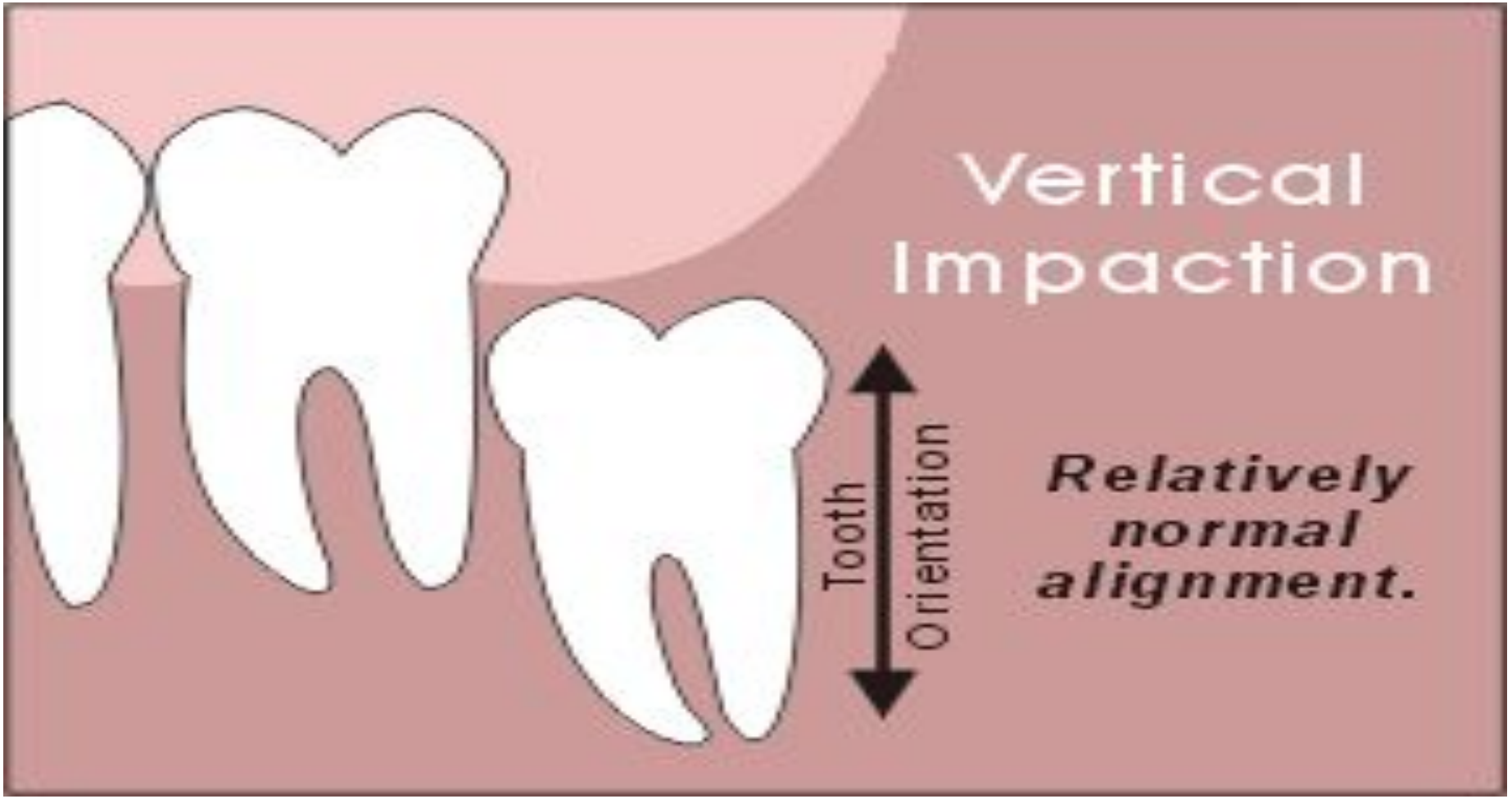
Vertical
Impaction
Tooth
Orientation
Relatively
normal
alignment.



(guttering) created sectioning of crown in a horizontal fashion roots can be

elevated in one piece or sectioned and removed (distal preceding that of the mesial).

• The distoangular impaction; Most difficult tooth to remove because the pathway of delivery is into the vertical ramus (more distal bone must be removed)create an adequate buccal and distal trough (guttering) around the full crown of the tooth to a depth below the cervical line create a point of application of elevator on the buccal aspect of the tooth using the buccal cortical plate as the fulcrum elevate the tooth out of the socket upwards and distally some movement distal portion of the crown sectioned in a horizontal fashion and removed (section the tooth segments further as needed rather than to remove more bone)The roots delivered together or sectioned

and delivered independently with a Cryer's elevator

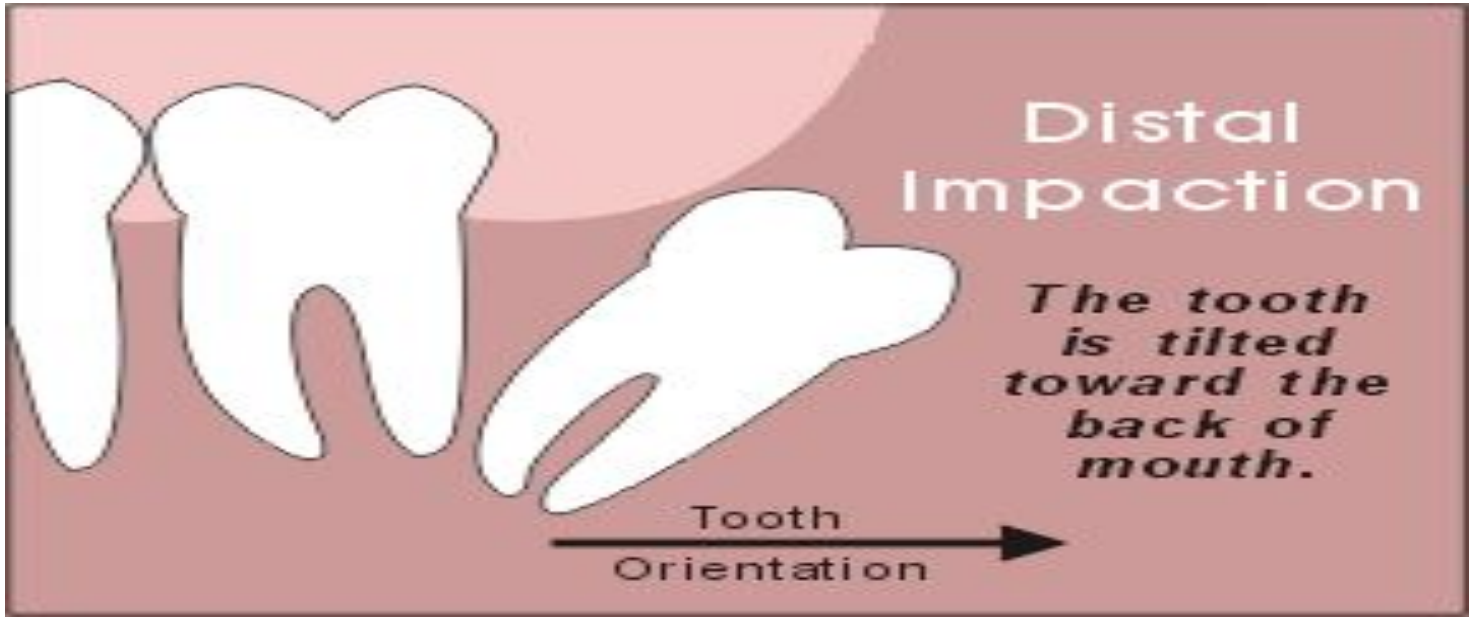
Distal
Impaction
The tooth is tilted toward the back of mouth.
Tooth
Orientation

Other Methods for Removal of Impacted Lower Third Molar

• Sagittal split ramus osteotomy: In this technique two cortical cuts are done: horizontal cut through the medial aspect of the ramus to area posterior and above the lingula, and a vertical cut through the anterior border of ramus and extends down to the inferior border of mandible. An osteotome is used to complete the split along the horizontal and then the vertical cuts. the result is longitudinal split of the mandible in the cut area. The technique is used in patients with;

history of recurrent infection with/ or without trismus associated with a deeply impacted lower right third molar tooth, and/or

impacted lower third molar intimately involved with the inferior alveolar nerve

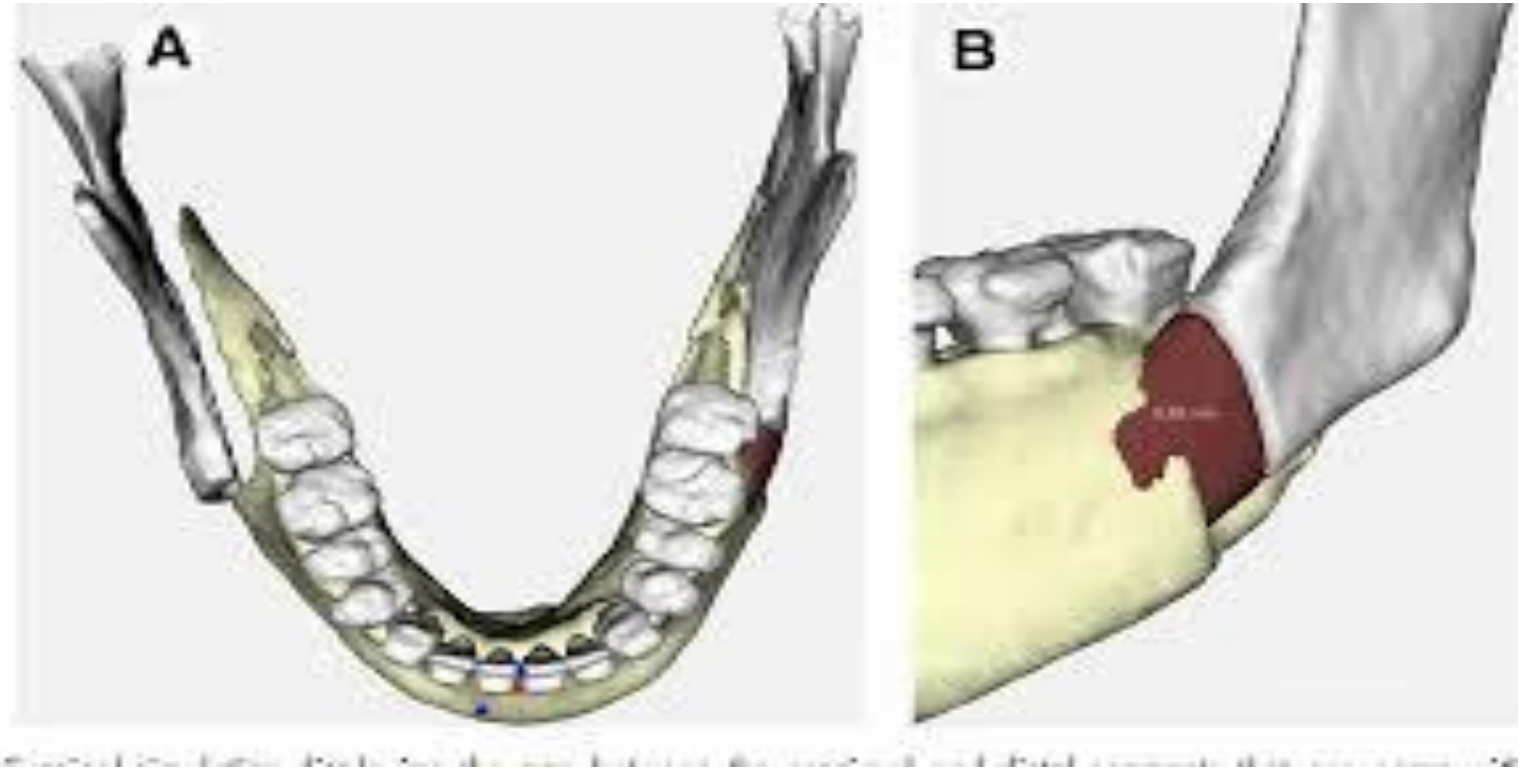
A
B

Buccal corticotomy: For deeply impacted mandibular teeth rectangular window is made over the deeply impacted tooth using a narrow fissure bur mesial and distal cuts almost reaching the inferior border of the mandible window removed with osteotome impacted molar divided and removed The bony (window) replaced.

• Lingual Split technique: Involves the use of a chisel and mallet to remove or displace the lingual plate of bone adjacent to lower third molar. A small amount of buccal bone is often removed to facilitate exposure of the crown and provide a point of application for an elevator. Sometimes tooth division is required for its removal (operated under general anaesthesia, young patients elastic bone

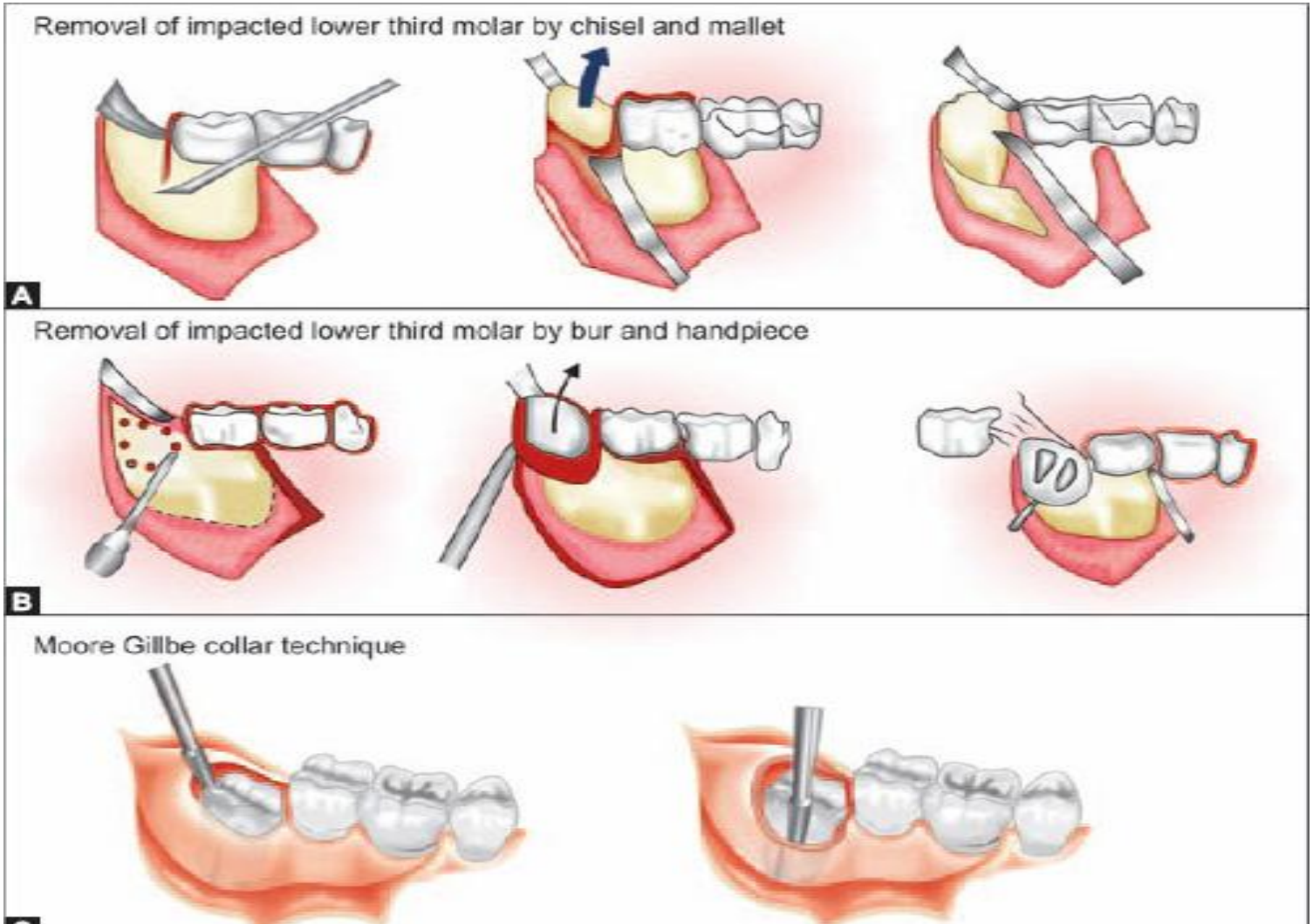
Removal of impacted lower third molar by chisel and mallet
A
Removal of impacted lower third molar by bur and handpiece
B
Moore Gillbe collar technique

Partial Odontectomy: (coronectomy, deliberate root retention) procedure devised to protect the IAN. Radiographic features suggesting an intimate relationship:

• Darkening of the root and interruption of the white line of the canal

• Narrowing of the canal • Deflection of the roots

Adequate amount of root must be removed below the crest of the lingual and buccal plates of bone bone forms over the retained roots. Contraindications to Partial Odontectomy

• Active infection around the tooth

• Mobile teeth - any retained mobile root nidus for infection.

• Horizontally impacted tooth along the course of the nerve sectioning the tooth will damage the IAN.

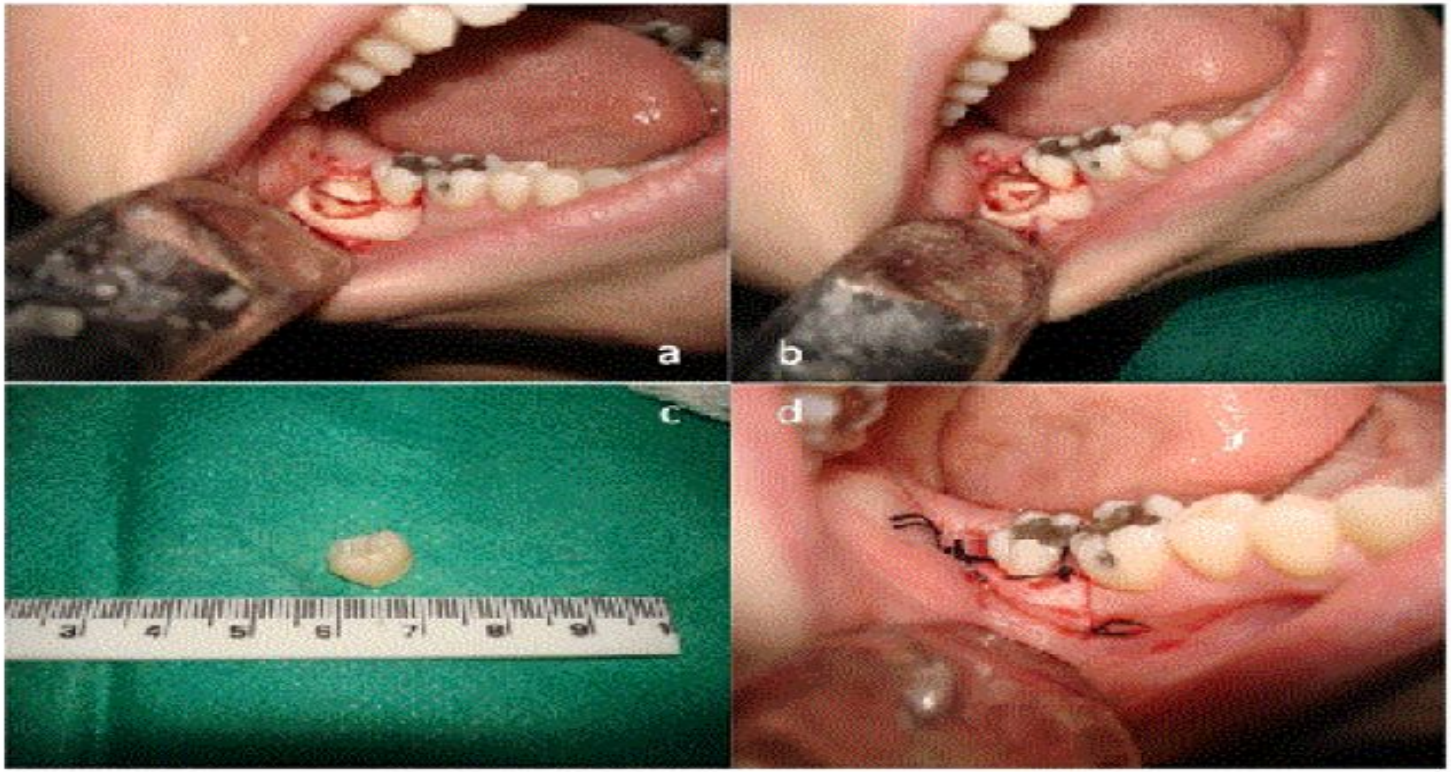

Figure 3: a. Odontosection (intentional partial odontectomy). b. After removal of the coronary portion. c. Coronal portion removed. d. Simple suture points (postoperative).

Orthodontic extraction: for the safe extraction of impacted third molars with a high risk

of neurological complication due to the close proximity to mandibular canal;

- Phase 0 Assessment of surgical risks
- Phase 1 Creation of orthodontic anchorage: stainless steel lingual arch and buccal stainless-steel sectional wire tied from second molar to the first bicuspid.
- Phase 2 Surgical exposure of the third molar crown
- Phase 3 Orthodontic extrusion (3rd molar); setting 3rd molar apart from IAN
- Phase 4 Clinical and radiographic assessment of the extrusion level
- Phase 5 Third molar extraction if adequate bone separating the root from INA

Upper third molars

Classification of impacted maxillary third molars:

- State of Eruption; 1. Fully erupted 2. Partially erupted 3. Unerupted
- Angulation of the Tooth; 1. Vertical, 2. Mesioangular, 3. Distoangular, 4. Laterally displaced with the crown facing the cheek, horizontal, inverted and transverse positions,

5. Aberrant position

- Pell and Gregory Classification;

Position A; 3rd molar occlusal surface is at the same level of that of 2nd molar.

Position B; 3rd molar occlusal surface is between occlusal plane and cervical line 2nd molar.

Position C; 3rd molar occlusal surface is at or above cervical line of 2nd molar

Relationship of Impacted Maxillary Third Molar to the Maxillary Sinus

Sinus approximation (SA): No bone or a thin partition of bone between third molar and maxillary sinus.

No sinus approximation (NSA): 2 mm or more bone between third molar and

maxillary sinus

Nature of Roots; 1. Fused (conical) 2. Multiple—Favourable/Unfavourable

Indications for the Removal of Maxillary Third Molar

1-Extensive dental caries which is beyond restoration

2-Recurrent pericoronitis

3-Buccally or distally erupting teeth cheek biting

4-Tooth involved in pathological process

5-Over erupted and non-functional upper third molar

6-Buccally erupting upper 3rd molar impinging on the coronoid process pain during movement

7-Interference with placement of prosthesis

Local Contraindications for Removal

1-Symptom-less upper third molar completely embedded in bone.

2-Third molar high in alveolus displacing into antrum or infratemporal fossa

3-Deeply impacted tooth removal can damage the adjacent second molar

Radiographic Examination

1-Periapical X-ray

2-OPG

3-Occlusal X-ray

4-True lateral view

5-PNS (paranasal sinus) view of maxilla if associated pathology

6-CT scan—especially if associated pathology

Determining the Degree of Difficulty of Removal

1-Angulation: same angulations in mandibular third molar cause opposite degree of difficulty for maxillary third molar extraction.

2-Position in bucco angular direction: directed towards the buccal aspect easy.
-Positioned towards the palatal aspect difficult to remove.

3-Type of overlying tissues; only soft tissue covering is easier to remove

4-Proximity to maxillary sinus

5-Proximity to maxillary tuberosity; tuberosity can be fractured. Factors contributing to this hazard are:

Dense and non-elastic bone as in old age

- Multirooted tooth with large bulbous roots
- Large maxillary sinus (that include roots of third molar)
- Use of excessive force to elevate the tooth
- Mesioangular impactions

Other factors influencing the degree of surgical difficulty:

- Tooth with roots which are the difficulty increased
- Hypercementosis Difficulty increased
- Wide periodontal space difficulty decreased.
- Tooth with a wide follicular space difficulty decreased
- Bone is more elastic as in young patients difficulty decreased
- Close relationship to second molar difficulty increased
- Fusion of third molar with roots of second molar difficulty increased
- Presence of large restoration on second molar difficulty increased
- Difficult access due to small oral aperture or trismus difficulty increased

Steps in the operative procedure for removal of unerupted third molar

One of the difficulties that will be encountered during its surgical removal is the limited access due to the presence of the coronoid process. This can be overcome by opening the mouth only partially.

1. Incision: It starts from the mesial aspect of first molar and extends posteriorly beyond the distobuccal aspect of second molar and then continued into the tuberosity. If greater access is required (deep impaction)release incision in the mesial aspect of second molar to raise a triangular flap

2-Using a Howarth's periosteal elevator, the mucoperiosteum is reflected.

3-Bone removal is restricted to the occlusal and the buccal aspect of the tooth down to the cervical line (using chisel or bur). Additional bone is removed on the mesial aspect of the tooth above the height of contour of the crown for the insertion of an elevator and to act as a purchase point.

4-Maxillary third molars rarely need sectioning (overlying bone is usually thin and elastic). If bone is thick, sclerotic and less elastic bone removal rather than tooth sectioning.

5-Delivery of the tooth: using small straight elevators. The following points should be borne in mind while elevating the tooth

Due to the proximity of the maxillary sinus and infratemporal fossa no upward pressure exerted during bone removal and delivery

• This can be avoided by creating sufficient room between crown and surrounding bone

• Moderate pressure is exerted downward and outward with the forefinger placed posterior to maxillary tuberosity to detect tuberosity fracture if it occurs.

• Minnesota retractor or periosteal elevator can be placed distal to impacted maxillary third molar during final elevation avoid displacement under the flap and into the infratemporal fossa

6-Debridement and Closure: A single suture is all that is needed to secure the wound. The suture is passed from the palatal side of the interdental papilla between the first and second molars into the anterior end of the buccal flap

Complications During Surgery of Impacted Maxillary Third Molar

1-Displacement of tooth into maxillary sinus:

partially erupted and has conical roots

excessive force is exerted for elevating a buried wisdom tooth

Retrieval can be accomplished via a Caldwell-Luc approach

2-Dislodgement into soft tissues and into the infratemporal fossa may occur: Buccal flap is not adequate

Decreased visibility during surgical extraction

Incorrect extraction technique

Distolingual angulation of tooth

Third molar crown above the level of the adjacent molar root apices

Such displaced tooth should be removed as early as possible to avoid development of infection. Tooth retrieval can be done with hemostat or Allis' forceps. Surgical access is gained through an incision along the crest of the alveolus. If the tooth could not be removed after a single effort patient informed antibiotic is administered to prevent infection tooth removed four to six weeks later by an oral and maxillofacial surgeon

Summary of Instructions to Patient Following Surgical Removal of Impacted Tooth

1. Remove the gauze pack after 30 minutes to one hour

2. Apply ice (ice cubes taken in a polythene bag) on the face for the first 24 hours.

3. For the first day take cold liquids or semisolids.

4. Avoid warm saline gargle in the first 24 hours.

5. There may be mild to moderate swelling on the side of the face for three to four days.

6. Mild bleeding/oozing of blood can be there from the surgical site for one to two days. In

the event of excessive bleeding bite on a fresh piece of sterile gauze and inform the

doctor.

7. In the first few days, difficulty may be experienced in opening the mouth. To avoid this,

from the next day of surgery onwards try to open the mouth forcefully.

8. From the next day onwards after surgery or once the oozing of blood has completely stopped, warm saline mouth-baths can be used at fourth hourly intervals. Avoid

application of dry heat on the face.

9. Tooth brushing have to be done from the next day on wards.

10. Take the drugs prescribed by the doctor at regular intervals.

11. Avoid alcohol, smoking, physical exercise and long journey for the next few days.

12. Report for review to the doctor as suggested for suture removal

Drug therapy

Use of antibiotic

Postoperative oral prophylactic antibiotic treatment after the removal of lower third molars have not shown to contribute to a better wound healing, less pain, or increased mouth opening and could not prevent inflammatory problems after surgery. And therefore, is not recommended for routine use. The following principles should be considered before prescribing antibiotics:

The surgical procedure should harbour a significant risk for infection, for example:

• Long procedure (> 30 minutes) or difficult surgery involving significant tissue trauma.

• Where there is existing infection in and around the surgical site.

2. Administration of the antibiotic must be immediately prior to or within 3 hours after the start of surgery:

• The ability of systemic antibiotics to prevent the development of a primary bacterial lesion is confined to the first 3 hours after inoculation of the wound.

• Commencing prophylactic antibiotic cover the day before surgery only leads to the development of resistant organisms.

• Continuing antibiotics for days after surgery has not been shown to decrease the incidence of wound infection

3. Prophylactic antibiotics should be given at twice the usual dose over the shortest effective time so as to minimize the potential side-effects of long-term use (e.g. diarrhoea) and to prevent the growth of resistant strains of bacteria.

4. Examples of antibiotic prophylactic regimens:

• Amoxicillin 3 gm orally, 45 minutes before surgery under local anaesthesia.

• Clindamycin 600 mg orally, 30 minutes before surgery under local anaesthesia for patients allergic to penicillin.

• Benzyl Penicillin 600 mg IV/IM on induction for procedures under general anaesthesia.

• Erythromycin lactobionate 500 mg IV on induction for surgery under general anaesthesia for patients allergic to penicillin.

The above dose may be followed with an additional oral dose 6 hours after the initial dose

Use of Anti-inflammatory Drugs and Steroids

Perioperative corticosteroids have been used to minimize swelling, trismus and pain in oral and maxillofacial surgery patients. However, the method of usage is extremely variable. The most widely used steroids are dexamethasone and methylprednisolone. Common doses of dexamethasone are 4 to 12 mg given IV at the time of surgery. Additional oral dosages of 4 to 8 mg. twice a day for the day of surgery and 2 days afterwards leads to the maximum relief of swelling, trismus and pain. Methylprednisolone is most commonly given IV 125 mg at the time

of surgery followed by significantly lower doses, usually 40 mg 3 or 4 times daily taken orally for the day of surgery and for 2 days after surgery

Use of Non-steroidal Anti-inflammatory Drugs (NSAIDs)

they are frequently used after surgical procedures in order to reduce the soft tissue oedema and pain by suppressing inflammation

Use of Analgesics

- It has been reported that soluble aspirin 900 mg provides significant and more rapid analgesia than paracetamol 1,000 mg in the early postoperative period
- Patients should be encouraged to take analgesics either before the onset or at the time of onset of pain or discomfort rather than waiting till the pain becomes unbearable.
- Long-acting local anaesthetic solutions may be of value in some situations where extreme pain is likely to be a feature in the immediate post-operative period.
- It has been shown that administering a dose of analgesic preoperatively markedly reduces postoperative pain

Complications of Impaction Surgery

Complications during the Surgical procedure

1-Complications during incision; Excessive bleeding may occur in the following situations:

A- Pre-existing local inflammation.

B-Bleeding from retromolar vessels

C-Bleeding from facial vessels

D-Damage to lingual nerve

2-Complications during bone removal

a. Use of bur

• Accidental burns

• Laceration of soft tissues

• Injury to inferior alveolar

bundle

• Injury to adjacent tooth

• Injury to lingual nerve •

Necrosis of one

• Emphysema

b. Use of chisel:

- Splintering of bone
- Fracture of mandible
- Displacement of tooth into lingual pouch
- Injury to lingual nerve
- Injury to second molar tooth and soft tissues

3-Complications during sectioning of tooth

- Incorrect line of sectioning of crown
- Injury to mandibular canal: During

4-Complications during elevation of tooth

- Fracture of impacted tooth/ root
- Breakage of bur
- Injury to second molar
- Fracture of mandible
- Dislodgement of tooth/crown into the lingual pouch or lateral pharyngeal space
- Injury to mandibular canal

Post-Surgical Sequelae and Complications:.

1-Haemorrhage

2-Oedema

3-Trismus

4-Pain

5-Infection

6-Alveolar osteitis (Dry socket)

7-Nerve Injury

8-Surgical Emphysema

9- Hematoma

10-Pain during swallowing

11-Pyrexia

12-Osteomyelitis

13-Temporomandibular joint (TMJ) complications

14-Fracture of instruments: Especially that of sharp Ones

15-Periodontal pocket formation distal to second molar

16-Aspiration /Swallowing of tooth


Thank
you !