periodontology

Cementum:-

It is a thin specialized calcified tissue covering the roots surfaces of the teeth.

It has many features similar to the bone tissue but differs from bone in the following aspects

It is microscopic organization.

Has no innervation

Has no blood or lymph vessels.

Does not undergo physiological remodeling

(resorption and deposition),but it is characterized by continuous deposition throughout life.

Functions of cementum:-

Anchorage of the tooth in the alveolus

To attach the PDL fibers to the teeth

To contribute to the process of repair after damage to the root surface and following regenerative periodontal surgical procedures.

Cemento-enamel junction (C.E.J)

Three types of relationships involving the cementum may exist at the C.E.J:-

Cementum overlaps the enamel (60%-65%)

Edge-to edge (butt joint (30%)

Cementum and enamel fail to meet (5%-10%)

In the last condition,there is a possibility of gingival recession which may result in sensitivity because the dentin is exposed.

<u>There are two types of cementum:</u>

1. Primary (acellular cementum):-

Is the first to be formed in conjunction with root formation and tooth eruption , it does not contain cells and sharpey's fibers make up most of its structure . Generally it covers the cervical third of the root

2. Secondary (cellular cementum):-

Which is formed after tooth eruption and in response to functional demands, therefore it grows faster and over a thin layer of acellular cementum at the apical third of the root and furcations of multirooted teeth . This type of cementum contains cells (cementocytes), but sharpey's fibers occupy a smaller portion of this type of cementum. Cellular cementum is less calcified than the acellular type.

Both acellular cementum and cellular cementum are arranged in lamellae separated by incremental lines parallel to the long axis of the root.These lines represent “rest periods” in cementum formation and they are more mineralized than the adjacent cementum.

Structures of cementum:- cementum consist of

Fibrous elements (collagen fibers) which is composed of type I (90%) and type III (about 5%) collagens.

Cellular elements

Calcified interfibrillar matrix

Fibrous elements:-there are two types

a. Extrinsic fibers (sharpey's fibers): which are the embedded portion of the principal fibers of the PDL and are formed by the fibroblast cells . Sharpey's fibers make up most of the structure of acellular cementum and they are inserted at right angles to the root surface and penetrate deep into the cementum.

b. Intrinsic fibers: These fibers are produced by cementoblast cells and are oriented more or less parallel to the long axis of the root and form a cross banding arrangement with sharpey's fibers

2. Cellular elements: The cells associated with

cementum are few and generally resides within the PDL.

a. cementoblast cells: responsible for the formation of both cellular and acellular cementum

b. cementocyte cells: are found only in cellular cementum , they are located within spaces (lacunae) that communicate with each other through canaliculi for transportation of nutrients through the cementum and contribute to the maintenance of the vitality of this tissue.

C.fibroblast cells:these cells belong to the PDL where they are responsible for synthesis of principal fibers but since these fibers become embedded in cementum, fibroblasts indirectly participate in the formation of cementum

d.cementoclast cells:these cells are responsible for extensive root resorption that lead to primary teeth exfoliation. Permenant teeth do not undergo physiologic resorption but localized cemental resorption may occur which appears as concavities in the root surface and may be caused by local or systemic causes.local conditions include,trauma from occlusion, orthodontic movement, cyst and occur on mesial surfaces in association with mesial drift. Among systemic conditions are calcium deficiency and hypothyroidism.

<u>Reversal line:</u>The newly formed cementum is demarcated from the root by a deeply staining irregular line which delineates the border of the previous resorption.

Both acellular cementum and cellular cementum are arranged in lamellae separated by <u>incremental lines</u> parallel to the long axis of the root.These lines represent "rest periods" in cementum formation and they are more mineralized than the adjacent cementum.

<u>Trauma from occlusion:</u>Forces that exceed the adaptive capacity of the periodontium and produce injury.

<u>Interfibrillar matrix:</u>These are proteoglycans, glycoproteins and phosphoproteins formed by cementoblast cells.Proteoglycans are most likely to play a role in regulating

cell-cell and cell-matrix interactions both during normal development and during the regeneration of cementum.

<u>Mineralization of cementum:</u>occurs by the deposition of hydroxyapatite crystals,first within the collagen fibers,later upon the fiber surface and finally in the interfibrillar matrix.Cellular cementum is less calcified than acellular cementum and cementum mineralizalion is less than that of the bone, enamel and dentin

Permeability of cementum:-

In very young animals,acellular cementum and cellular cementum are very permeable and permit the diffusion of dyes from the pulp and external root surface.The canaliculi in cellular cementum is some areas are contagious with the dentinal tubule.The permeability of cementum diminishes with age.

Exposure of cementum to the oral environment:-

Cementum becomes exposed to the oral environment in cases of gingival recession and as a result of the loss of attachment in pocket formation.The cementum is sufficiently permeable to be penetrated in these cases by organic substances,organic ions and bacteria.Bacterial invasion of the cementum occurs frequently in individuals with periodontal disease,and cementum caries can develop.

<u>Development of cementum:</u>Both cellular and acellular cementum are produced by cementoblast cells.Cementoid is first formed which is a non-calcified tissue containing collagen fibrils distributed in matrix.Cementum is characterized by continuous deposition and increase in thickness throughout

life.A thin layer of cementum noted on recently erupted tooth will tend to increase thickness with age.Cementum formation is most rapid in the apical regions to compensates for tooth eruption and attrition. The thickness of cementum is more pronounced in the apical third and in the furcation areas than the cervical portion.Cementum is thicker in distal than in mesial surfaces because of functional stimulation from mesial drift over time.

Hypercementosis:refers to a prominant thickening of the cementum.It is largely an age-related phenomenon and it may be localized to one tooth e.g.tooth without antagonists or with periapical lesion , and sometimes affect the entire dentition that may occur in patients with paget's disease.It could pose a problem if an affected tooth requires extraction.

Cemental aplasia or hypoplasia:refers to an absence or paucity of cellular cementum.

Ankylosis:Fusion of the cementum and alveolar bone with obliteration of the PDL.It results in resorption of the cementum and its gradual replacement by bone tissue and it may develop after chronic periapical inflammation and occlusal trauma.Clinically,ankylosed teeth lack the physiologic mobility of normal teeth as well as proprioception is lost because pressure receptors in the PDL.are deleted or do not function correctly.Furthermore,the physiologic drifting and eruption of teeth can no longer occur .When implants are placed in the jaw,healing results in bone that is formed in direct apposition to the implant without intervening CT,this maybe interpreted as a form of ankyloses.

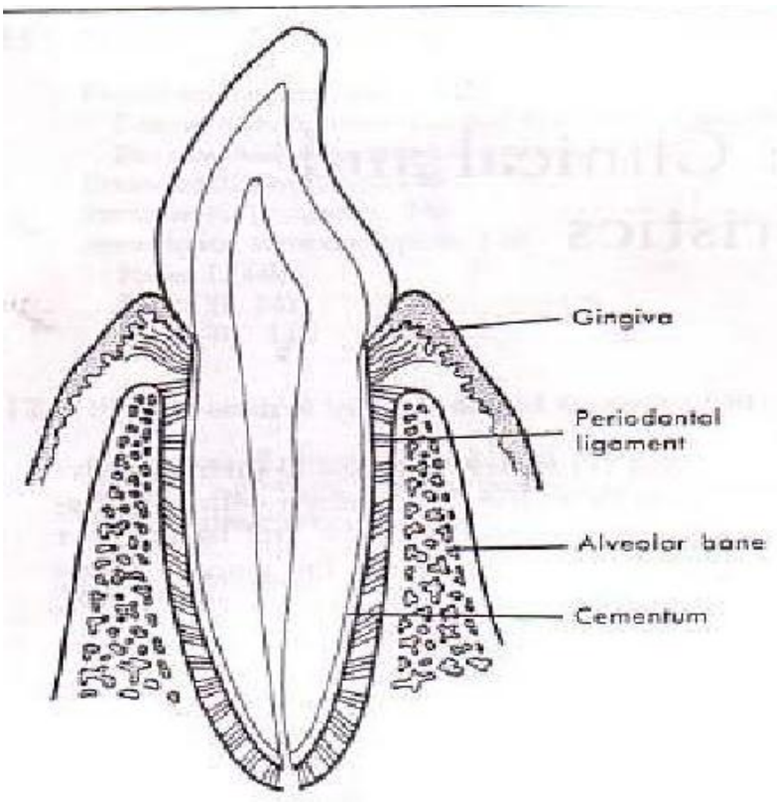

FIGURE 1-1. Faciolin
trating the tissues com

Cemento-enamel junction

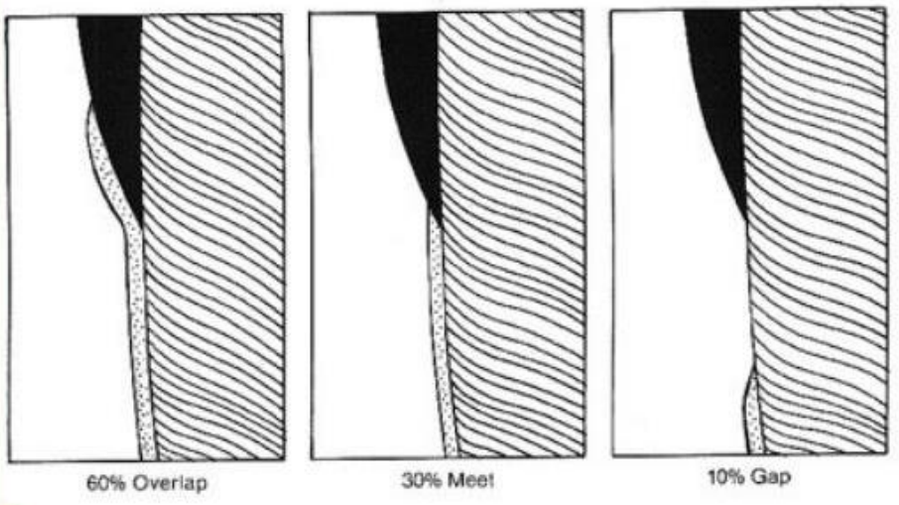

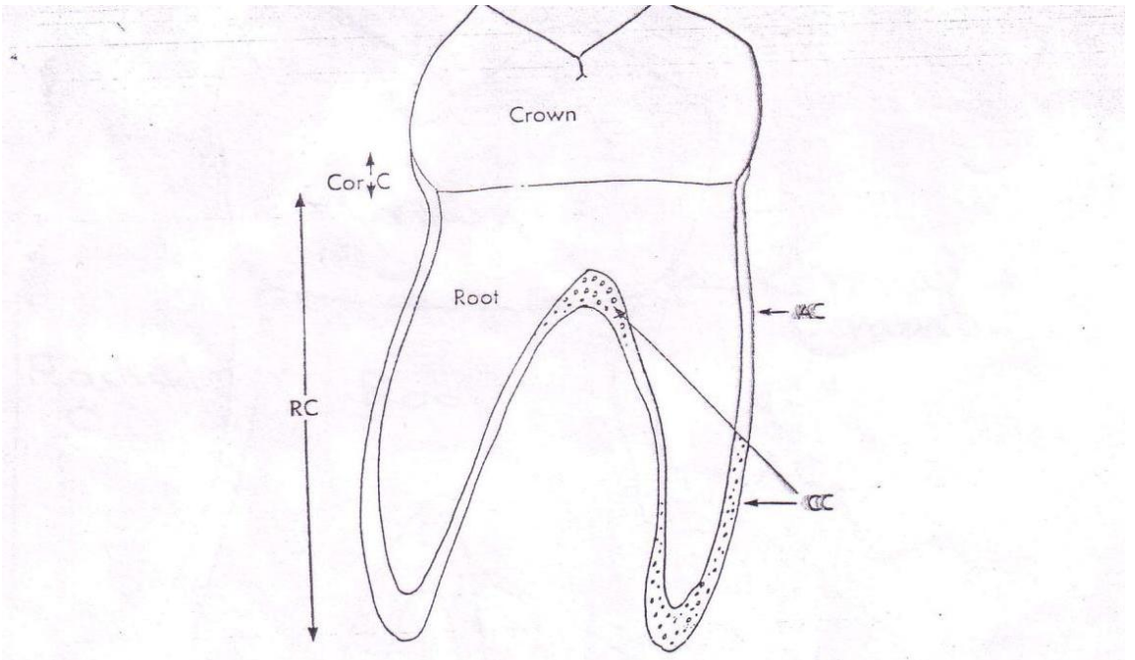

Fig. 4-1. Diagram illustrating the distribution of cementum on the tooth surface. The cementum covering the anatomic crown of the tooth is coronal cementum *(Cor C)*. The roots are covered with radicular cementum *(RC)*. Cellular cementum *(CC)* can be found on the apical third of the roots and within furcations. Acellular cementum *(AC)* covers the coronal two thirds of the root and extends over the cervical portion of the crown.

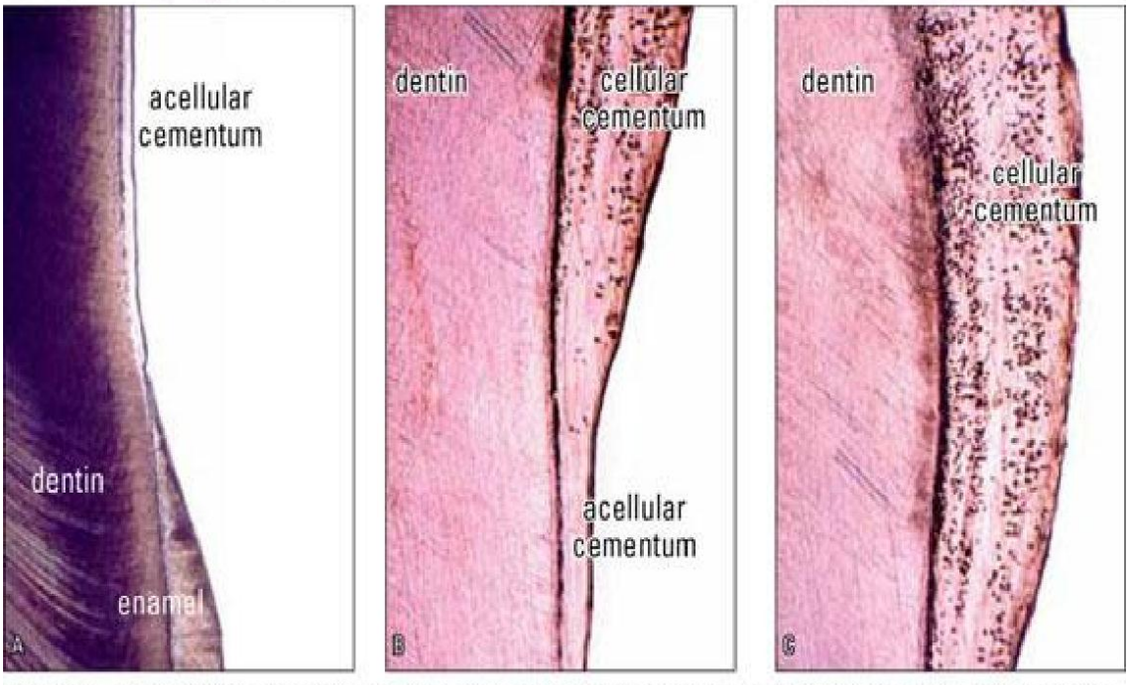

FIGURE 5 - Hypercementosis in tissue sections obtained by grinding, with no demineralization or staining. The cementum presents a uniform thickness in the cervical and middle thirds. The lacunae are in great quantity in the cellular cement in the apical third. Note the growing thickness of the tooth cementum from bottom (cervical) to top (apical) (**A**=4x, **B**=10x and **C**=25X).

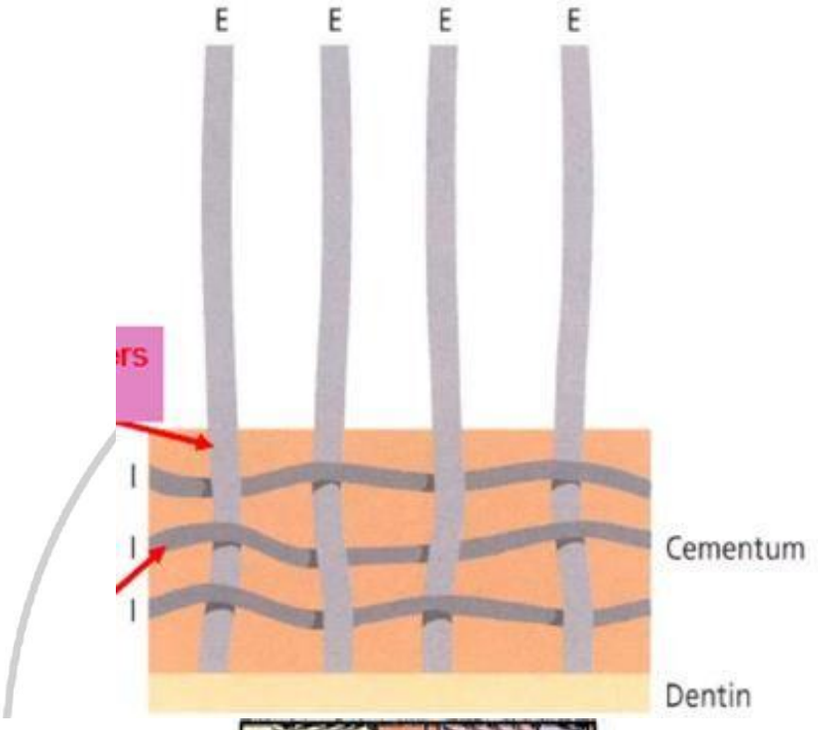
E
E
E
E
Cementum
Dentin

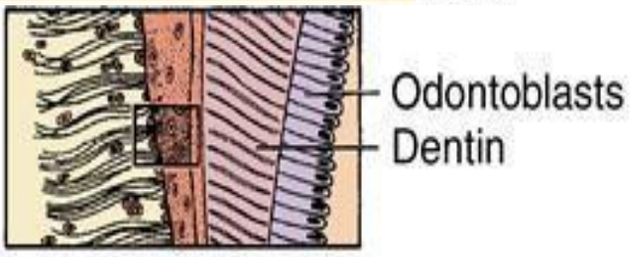
Odontoblasts
Dentin

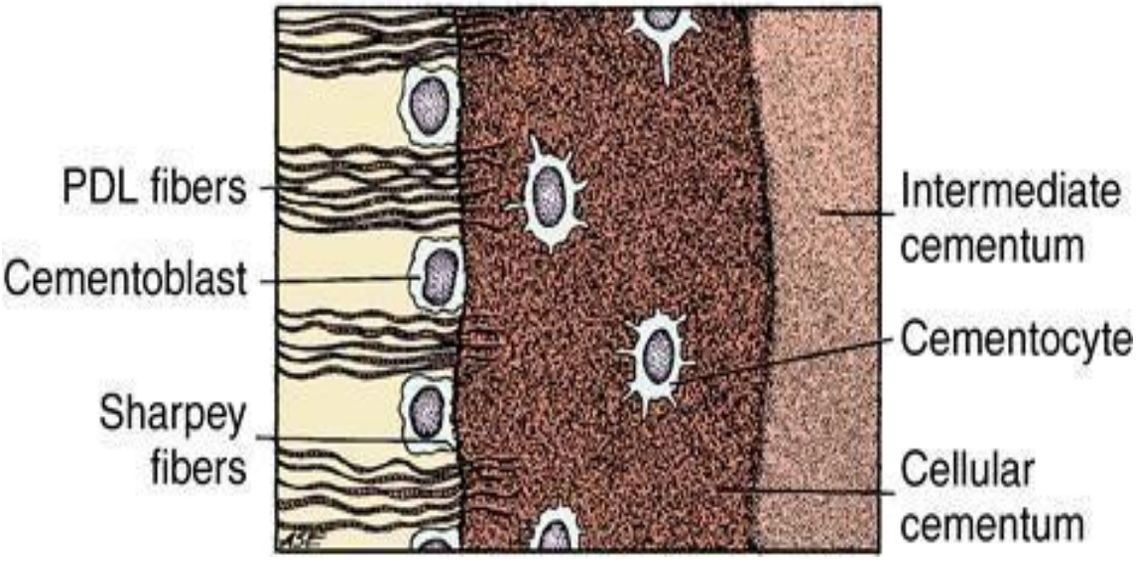
PDL fibers
Cementoblast
Sharpey fibers
Intermediate cementum
Cementocyte
Cellular cementum

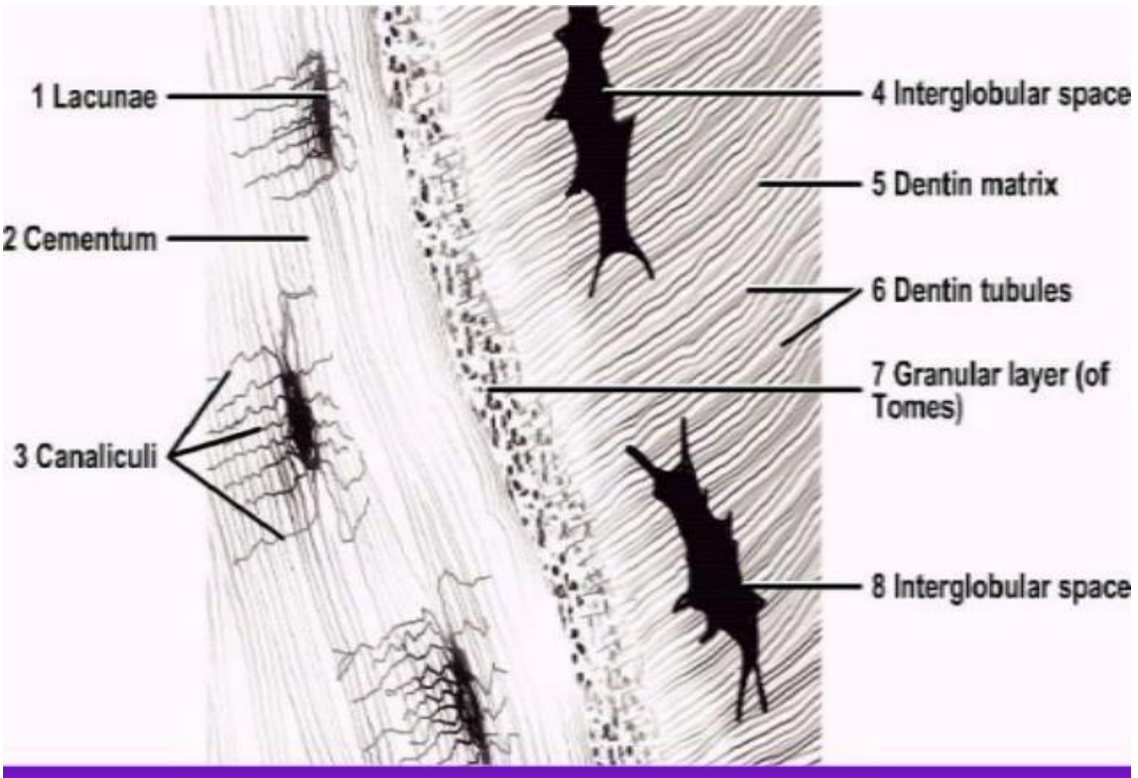

Cementocytes

Incremental Lines

- Incremental lines of Salter

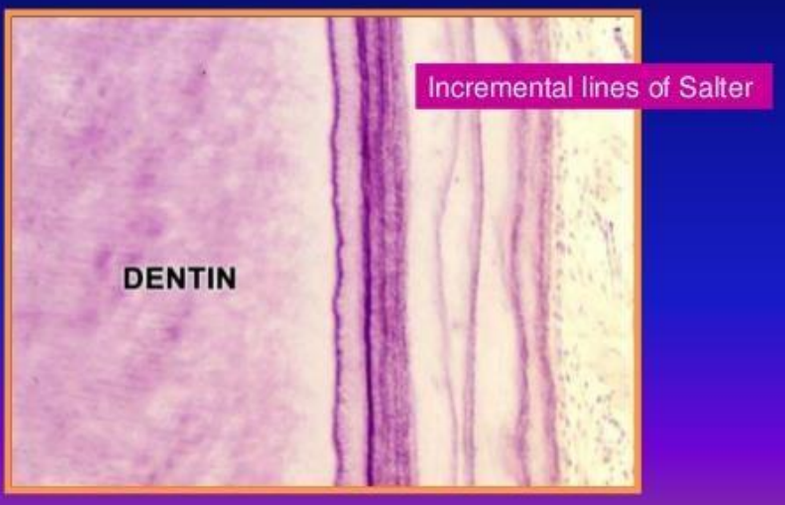

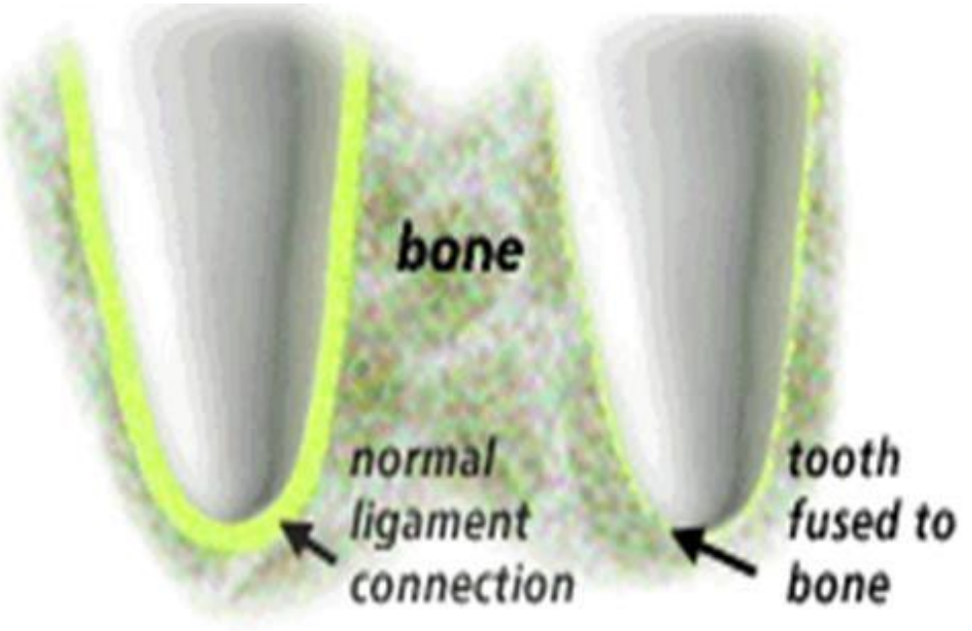





Arrow indicates region of hypercementosis around apex of lingual root of lower premolar. Hypercementosis may often result from chronic periapical inflammation.

