Periodontology

Alveolar process(AP)

Is the portion of the maxilla and mandible that forms and supports the tooth sockets (alveoli).

It develops in conjunction with the formation of and during the eruption of the teeth and is gradually resorbed if the teeth are lost , thus it is tooth dependent structure

Functions of alveolar process:

1. **comprises the attachment apparatus and the supporting tissue of the teeth together with root cementum and PDL fibers.**
2. **provide the osseous attachment to the PDL fibers**
3. **distribute and resorb forces generated by mastication and other tooth contacts**

Alveolus:is the space in the alveolar bone that accommodates the roots of the teeth.

Parts of the alveolar process:

1. **Alveolar bone proper: it is a thin layer of compact bone forming the inner socket wall (lines the alveolus), which is seen as the lamina dura in radiographs. A great number of sharpey's fiber bundles are embedded into this layer of bone which is adjacent to the PDL therefore it is called((bundle bone))**

Histologically this bone contains many small holes or openings called ((volkmann's canals)) through which blood vessels , lymphatics and nerves link the PDL with the cancellous bone thus it is called ((cribriform plate))

2. **An external plate of cortical bone**

3. **Cancellous trabeculae or spongy bone: which is located in the space between the external cortical plate and alveolar bone proper, they meet and fuse to form the alveolar crest.cancellous bone, which act as supporting alveolar bone, with cortical bone surround the alveolar bone proper (ABP)**

<u>Basal bone:-</u> is the portion of the jaw located apically but unrelated to the teeth.

<u>Lamina dura:-</u>the layer of ABP appears as white line surrounding the root of the tooth on radiographs.

<u>The alveolar processes are subdivided according to their anatomical relationships to the teeth</u>

1. **Interproximal bone (interdental septum):- The bone located between the roots of adjacent teeth**

2. **inter radicular bone:- the bone located between the roots of multirooted teeth.**

3. **radicular bone:- the alveolar process located on the facial, lingual or palatal surfaces of the roots of teeth.**

The distance between the crest of the alveolar bone and the cementoenamel junction increases with age to an (average of 2.81mm).The thickness of alveolar process varies from one region to another depends on the position of the teeth in the arch and their relationship to one another, e.g. teeth that are labially positioned in the arch will have thin labial radicular bone and thicker lingual radicular bone.

<u>Bone marrow:-</u> The cavities of all bones of new-born are occupied by red marrow while in the adult jaw occupied by fatty or yellow type of marrow , however foci of red bone marrow are seen in the jaw which may be visible radiographically as zones of radiolucency.

Common locations are the maxillary and mandibular molar and premolar areas.

<u>Periosteum and Endosteum:</u>

Periosteum:-it is a layer of tissue covering the outer surface of bone,it contains collagen fibers and cells (osteoblasts) with blood vessels, nerves and fibroblasts

Endosteum:- the marrow spaces inside the bone are lined by endosteum, this tissue contains cells (osteoblasts)

Anatomical defects of bone:-

1. **Fenestration(window):-This bony defect include isolated areas in which the root is not covered with bone but covered only by periosteum and overlying gingiva and it does not extend to the marginal bone.**
2. **Dehiscence:-This bony defect include the denuded areas which extend to the bone margin,exposing the root surface.The defects may extend to the middle of the root or farther.**

Such defects occur on approximately 20% of the teeth,they occur more often on the facial bone than on the lingual bone are more common on anterior than on posterior teeth.

The cause of these defects is not clear, but may be related to some factors such as, prominent root, malposition or labial protrusion of the root with thin bony plate.

Haversian system or Osteon:-

It is an internal mechanism that bring a vascular supply to bones, consists of central canal called (Haversian canal)which in their center contains the blood vessel. These blood vessels surrounded by bone lamellae which arranged in concentric layers constitute the center of an osteon.The blood vessels in haversian canal are connected with each other by anastomoses running in the Volkmann's canals,so the nutrition of bone is secured by the incorporation of blood vessels in the bone tissue.

Bone cells:-

1. Osteoblast cells(bone forming cells):is responsible for the production of an organic matrix of bone which is consisting primarily of collagen fibers called (osteoid), this bone matrix undergoes mineralization by the deposition of minerals such as calcium and phosphate,which are subsequently transformed to hydroxyl apatite

2. Osteoclast cells:-These are large multinucleated cells found in concavities on the bone surface called (howship's lacunae) these cells responsible for bone resorption.

3. Osteocyte cells:- osteoblast cells that become trapped in the bone matrix and later on in the mineralized bone tissue , we call them osteocyte cells, they are located in the lacunae and are connected with the one another by extending processes into canaliculi through which they get nutrients and removes metabolic waste products.

Resorption of bone:-

The sequence of events in the resorptive process as follows:

1. attachment of osteoclasts to the mineralized surface of bone

2. creation of a sealed acidic environment,which demineralizes bone and exposes the organic matrix

3. degradation of the exposed organic matrix to its constituent amino acids via the action of released enzymes(e.g.,acid phosphates, cathepsin).

4. Sequestering of mineral ions and amino acids within the osteoclast

Composition of the bone:-

Bone consists of 2/3 inorganic matter and 1/3 organic matrix.

The inorganic matter is composed principally of the minerals calcium and phosphate,along with hydroxyl,carbonate,citrate,and lactate trace amounts of other ions such as sodium,magnesium and fluorine. The mineral salts are in the form of hydroxy apatite crystals.

The organic matrix consists mainly of collagen type I fibers (90%),with small amounts of non collagenous proteins such as osteocalcin and osteonectin.

Bone contains 99% of the body's calcium ions and therefore is the major source for calcium release when the calcium blood levels decrease,this is monitored by the parathyroid gland.

Remodeling of alveolar bone:-

Alveolar bone undergoes constant physiologic remodeling (resorption and formation)in response to external forces specially occlusal forces.

Teeth erupts and tend to move mesially throughout life to compensate for wearing in the proximal contact areas with age which become flat , this referred to as physiologic mesial migration , thus osteoclast cells and bone resorption occur in areas of pressure on the mesial surface and osteoblast cells with new bone formed in areas of tension on the distal surface.This process of resorption and formation of bone is called bone remodeling and it is important in the orthodontic treatment.

Remodeling of alveolar bone is regulated by local influences include functional requirements on the tooth and age related changes in bone cells while,systemic influences are probably hormonal(e.g.,parathyroid hormone,or vitamin D_3).



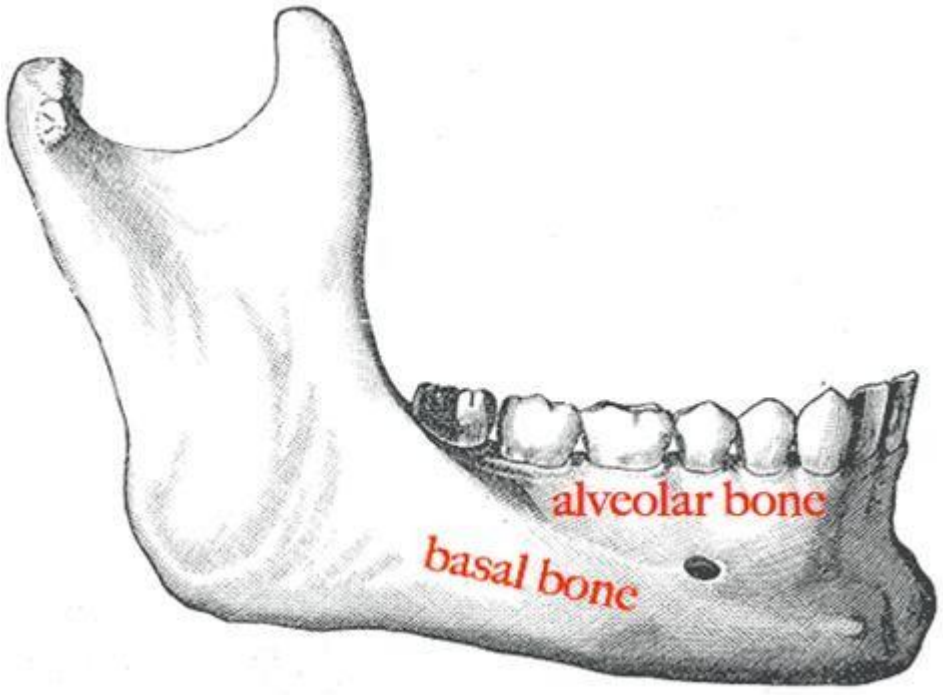

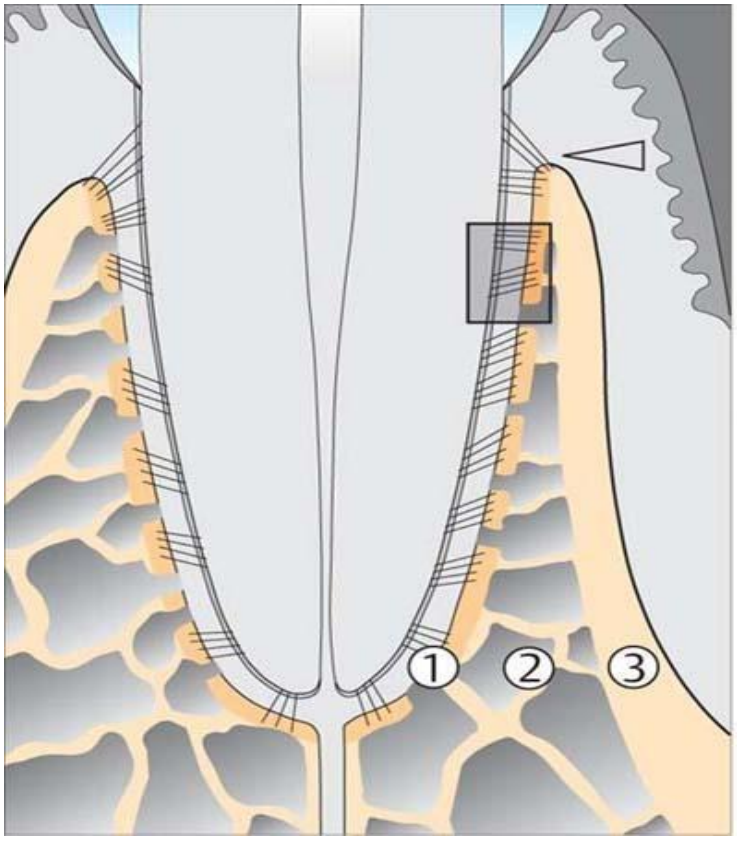



1 **Alveolar Bone**
Synonyms:

Anatomically
– Alveolar Wall
– Cribriform Plate

Radiographically
– Lamina dura

2 **Trabecular Bone**

3 **Compact Bone**

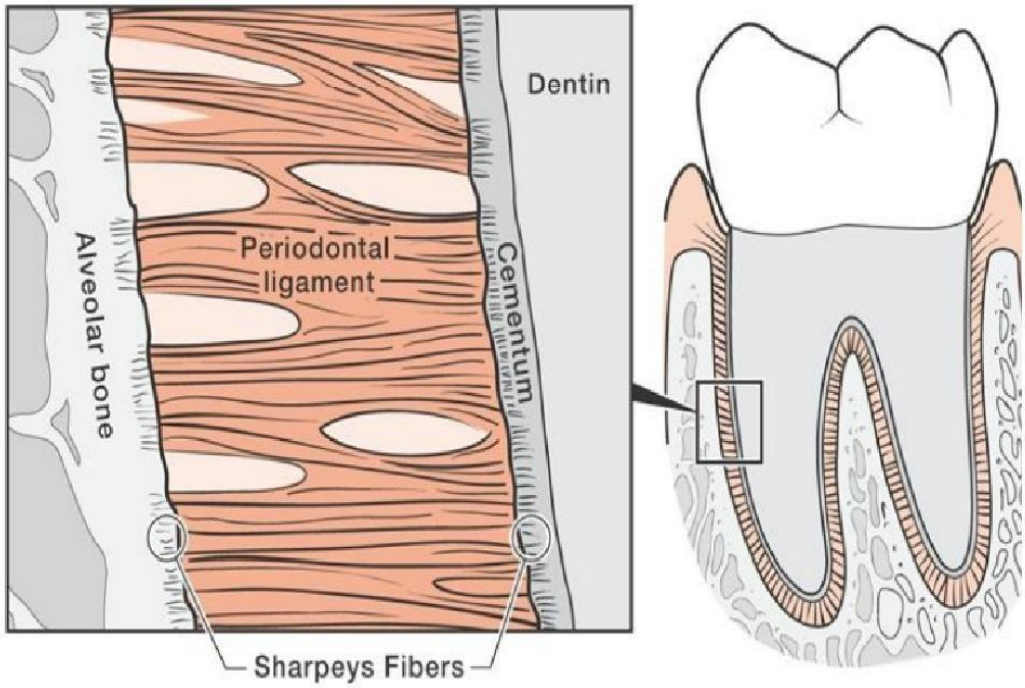
Dentin
Periodontal ligament
Cementum
Alveolar bone
Sharpeys Fibers

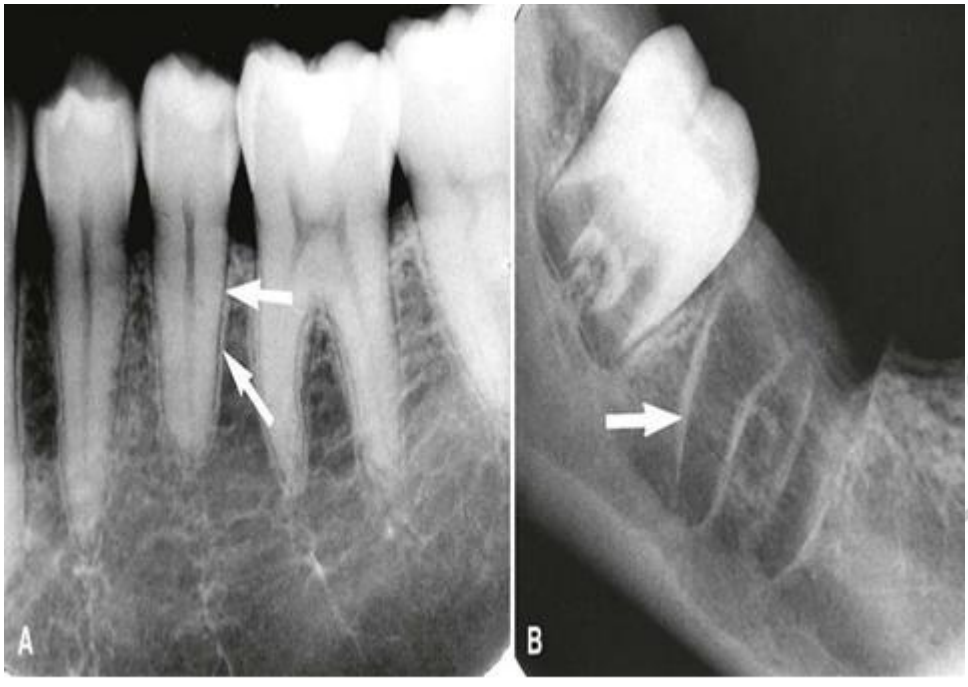
A
B

College of I

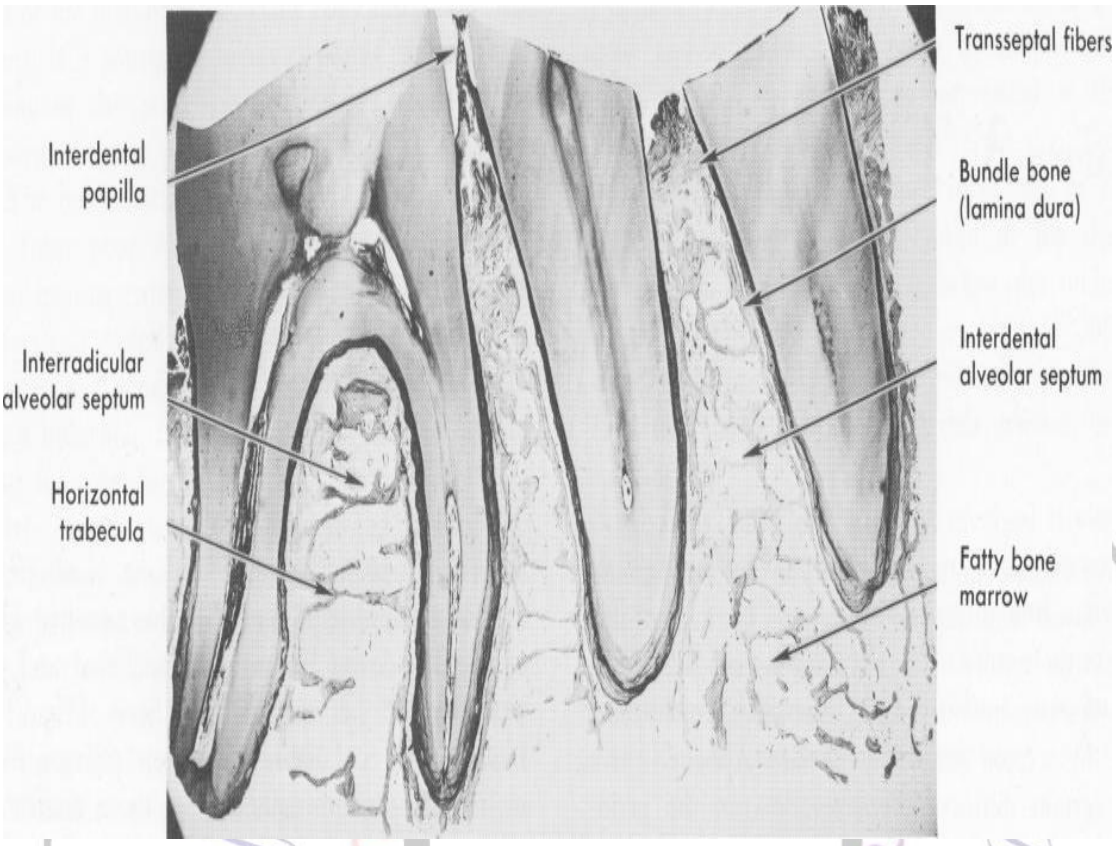
Interdental papilla
Interradicular alveolar septum
Horizontal trabecula
Transseptal fibers
Bundle bone (lamina dura)
Interdental alveolar septum
Fatty bone marrow

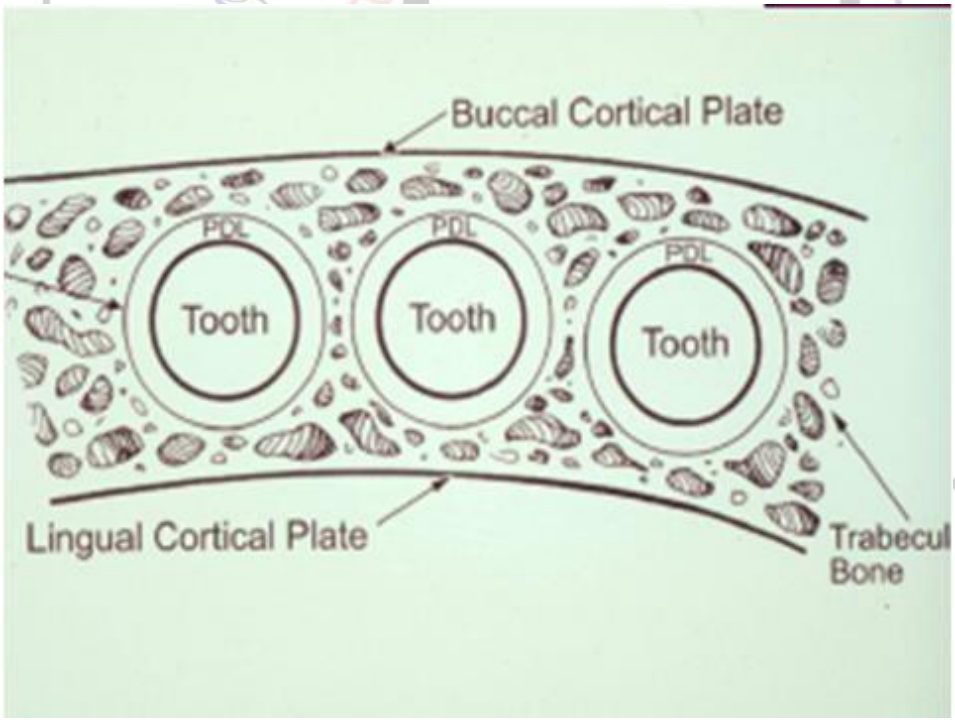
Buccal Cortical Plate
PDL
PDL
PDL
Tooth
Tooth
Tooth
Lingual Cortical Plate
Trabecul
Bone

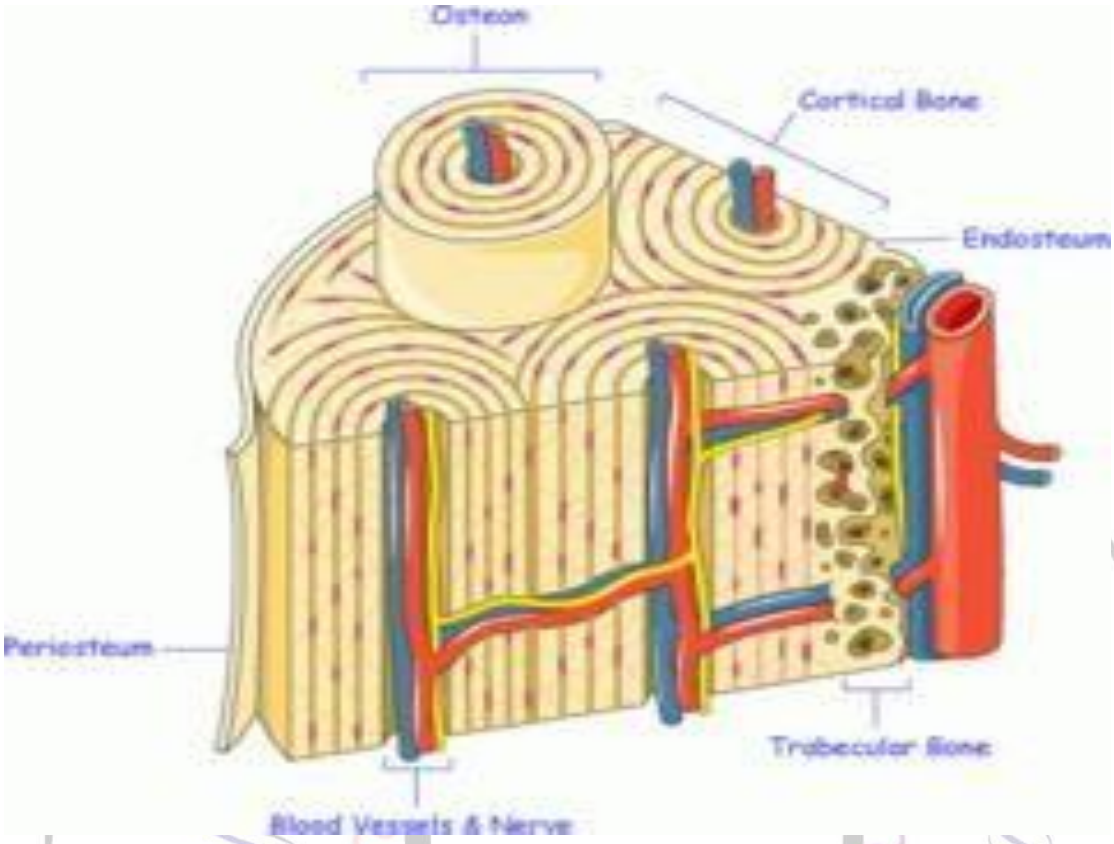
Osteon
Cortical Bone
Endosteum
Periosteum
Trabecular Bone
Blood Vessels & Nerve

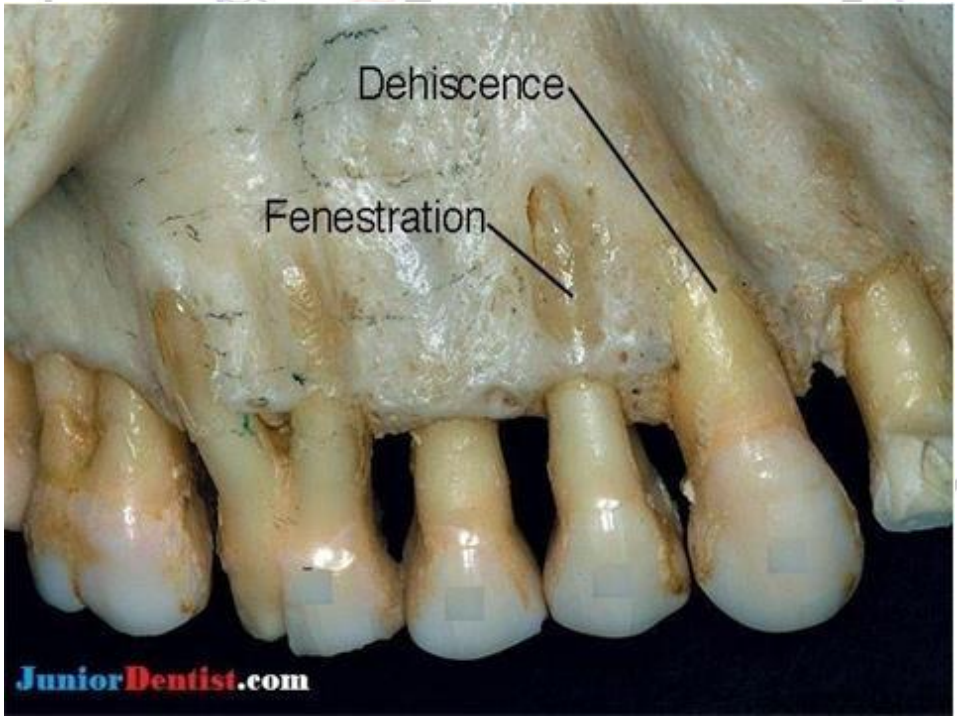
Dehiscence
Fenestration
JuniorDentist.com

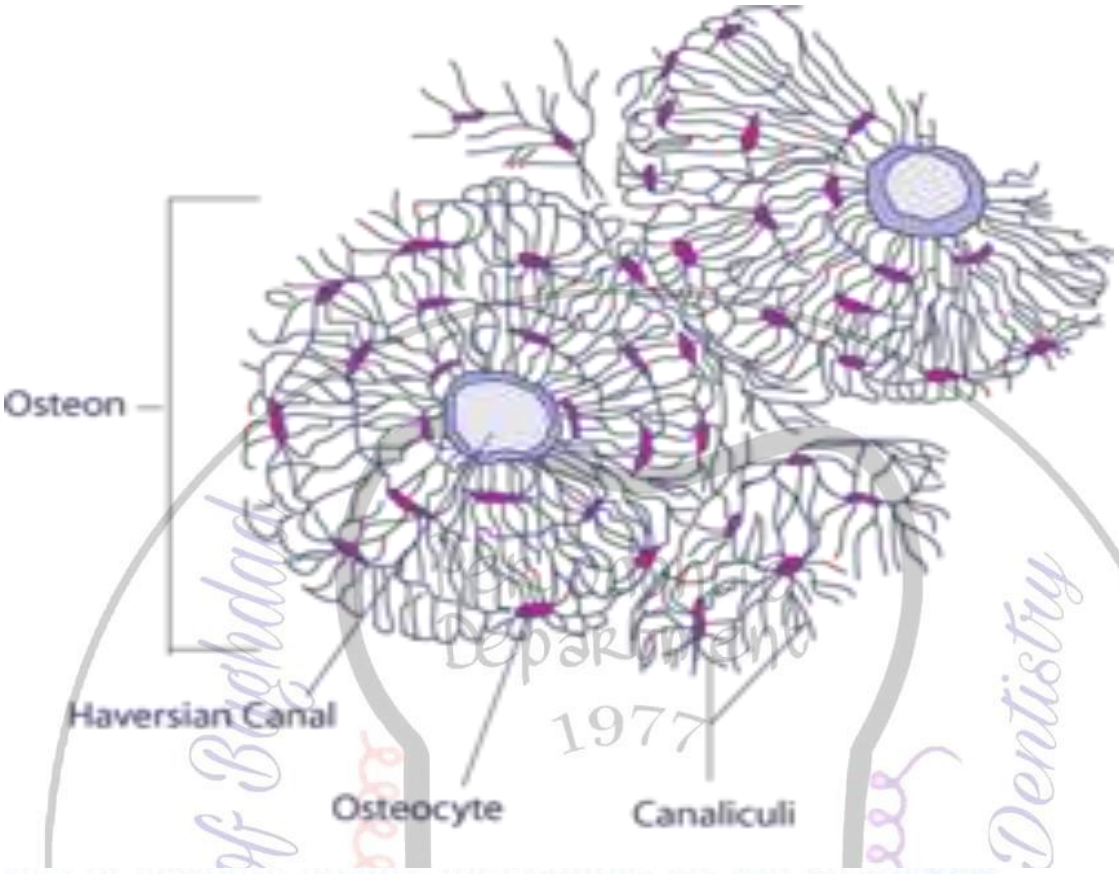
Osteon
Haversian Canal
Osteocyte
Canaliculi

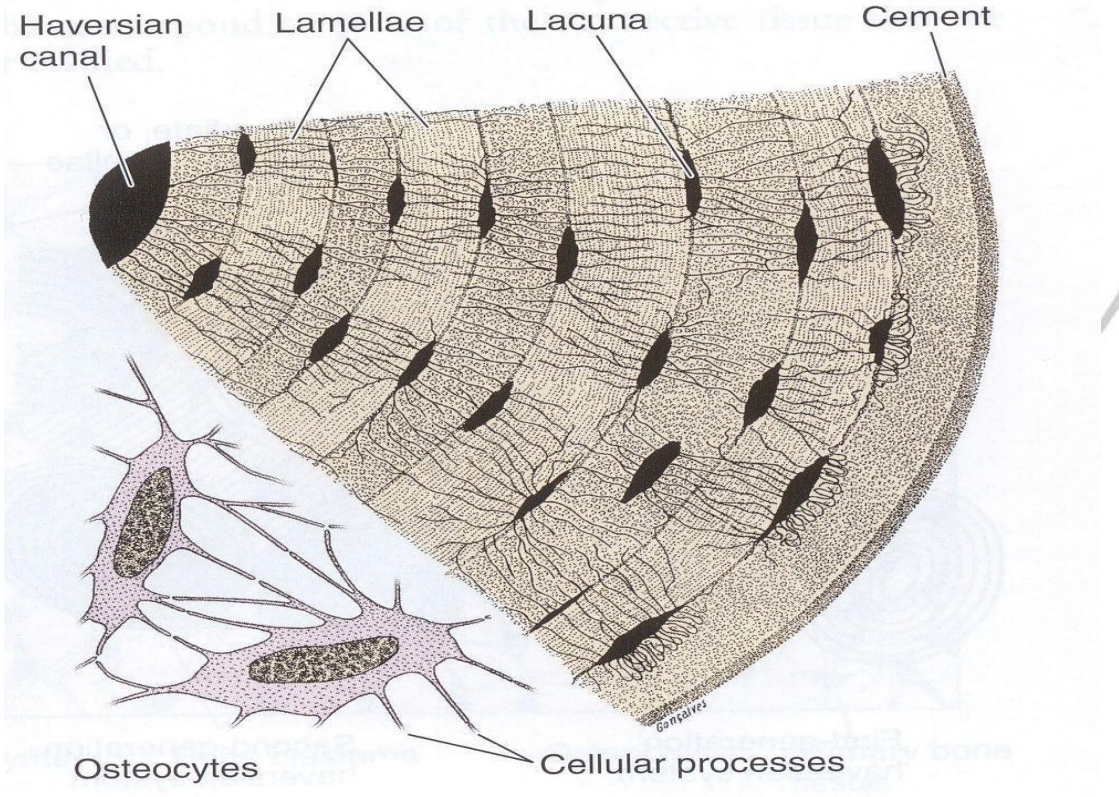
Haversian canal
Lamellae
Lacuna
Cement
Osteocytes
Cellular processes

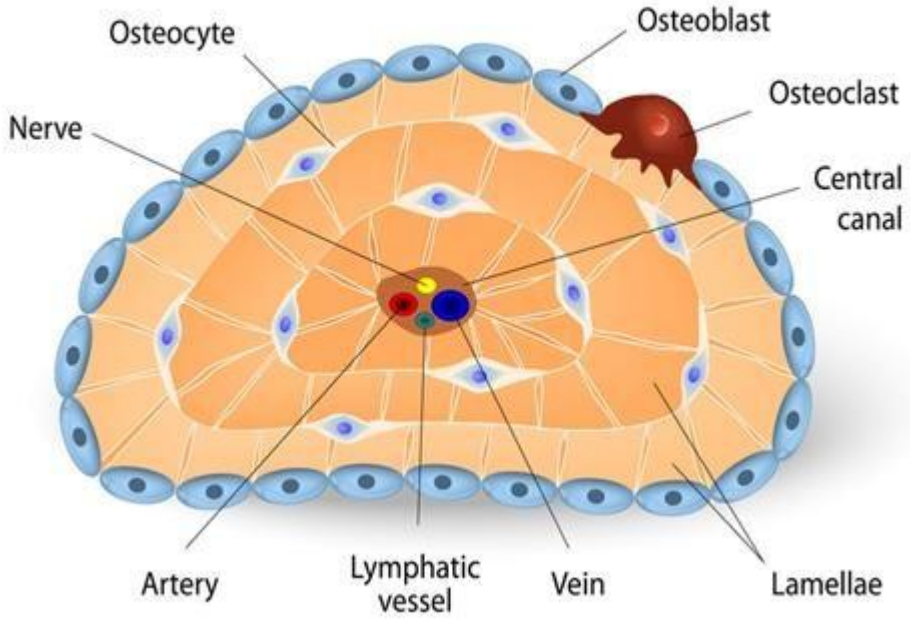

Bone Remodeling- Howships Lacunae

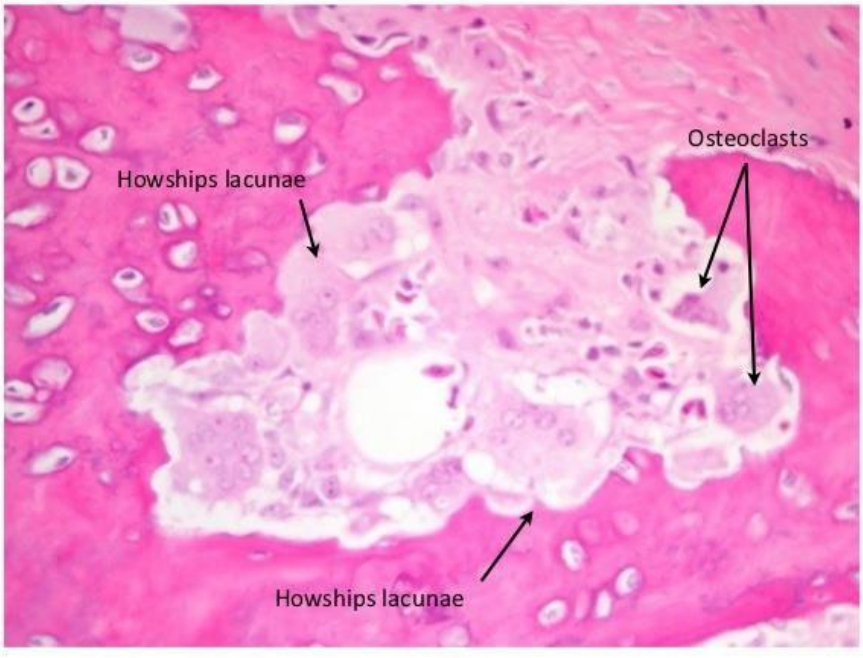


LC

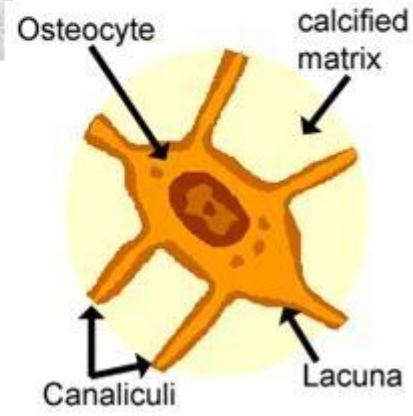
Osteocyte
calcified matrix
Canaliculi
Lacuna

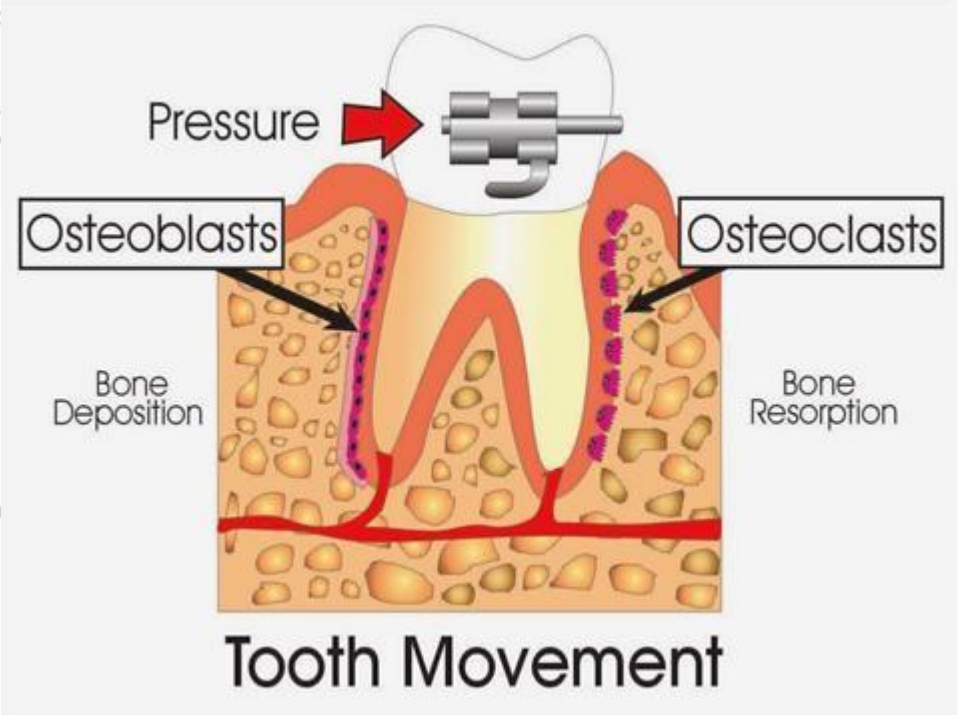
Pressure
Osteoblasts
Osteoclasts
Bone Deposition
Bone Resorption
Tooth Movement