Normal periodontium

Contents

- ❑ **Terms & definitions frequently used in periodontology**
- ❑ Oral mucosa
- ❑ Gingiva

o Classification

◦ Marginal gingiva

◦ Attached gingiva

◦ Interdental gingiva

o microscopic features

◦ Epithelium

◦ Epithelial connective tissue interface

◦ Connective tissue

◦ Gingival fibers

◦ Connective tissue ground substance

◦ Blood supply and nerves

o Clinical descriptive criteria of clinically healthy gingiva and inflamed one

Terms & definitions frequently used in periodontology

The term periodontium arises from the Greek word “Peri” meaning around and “odont” meaning tooth, thus it can be simply defined as “the tissues investing and supporting the teeth”. The periodontium comprises the following tissue:

✓ Gingiva (Investing tissue)

✓ Periodontal Ligament (Supporting tissues)

✓ Cementum

✓ Alveolar Bone

The main function of the periodontium is to attach the tooth to the jawbone and to maintain the integrity of the surface of the masticatory mucosa of the oral cavity

o the various diseases of the periodontium are collectively termed as periodontal diseases.

o Periodontal therapy: is the treatment of periodontal diseases.

o Periodontology: the clinical science that deals with the periodontium in health and disease.

o Periodontics is the branch of dentistry concerned with prevention and treatment of periodontal disease.

Oral Mucosa

The oral mucosa is continuous with the skin of the lips and the mucosa of the soft palate and pharynx. The oral mucosa consists of three zones:

(1) The masticatory mucosa, which includes the gingiva and the covering of the hard palate.

The boundaries are from the free gingival margin to the **mucogingival junction** on the facial and lingual surfaces. The mucogingival junction is a distinct line between the attached gingiva apically and the alveolar mucosa.

No mucogingival junction on the palatal side because both gingiva and alveolar mucosa are of the same type which is masticatory mucosa.

The tissue is firmly attached to the underlying bone and covered with keratinized epithelium to withstand the frictional forces of food during mastication.

(2) The specialized mucosa, which covers the dorsum of the tongue

(3) The lining mucosa: It is the oral mucous membrane that lines remainder of the oral cavity.

Examples for this type are the tissue covering the lips, cheeks, floor of the mouth, inferior surface of the tongue, soft palate and the alveolar mucosa.

Alveolar mucosa: is located apical to the attached gingiva and extends into the vestibule of the mouth, it is darker red and movable because it has no elastic fibers.

Biology of periodontal tissues

Introduction

Periodontium is the functional unit of tissues supporting the tooth including gingiva, the periodontal ligament (PDL), the cementum and the alveolar process.

The tooth and the periodontium are together called the **dentoperiodontal unit**.

The main support of the tooth is provided by the periodontal ligament, which connects the cementum of the root to the alveolar bone or tooth socket into which the root fits

Gingiva

Macroscopic features

The gingiva is that part of the masticatory mucosa which covers the alveolar process and surrounds the cervical portion of the teeth. The main function of the gingiva is to protect the surrounding tissues from the oral environment.

Classification

In an adult, normal gingiva covers the alveolar bone and tooth root to a level just coronal to the cementoenamel junction.

ANATOMICALLY, the gingiva is divided into, Figure 1:

1. Marginal gingiva (free or un-attached gingiva)

2. Attached gingiva

3. Interdental gingiva

1. Marginal Gingiva (free or un-attached gingiva)

The marginal, or unattached, gingiva is the terminal edge or border of the gingiva surrounding the teeth in collar like fashion. It is well adapted to the tooth surface, but it is not attached to it. It is separated from the tooth by a fine space called the gingival sulcus.

The marginal gingiva is separated from the attached gingiva by **free gingival groove** which is (a shallow linear depression on the faciolingual surface that roughly corresponds to the base off the gingival sulcus). The free gingival groove is about 1mm wide and it is only present in about 30-40% of adults.

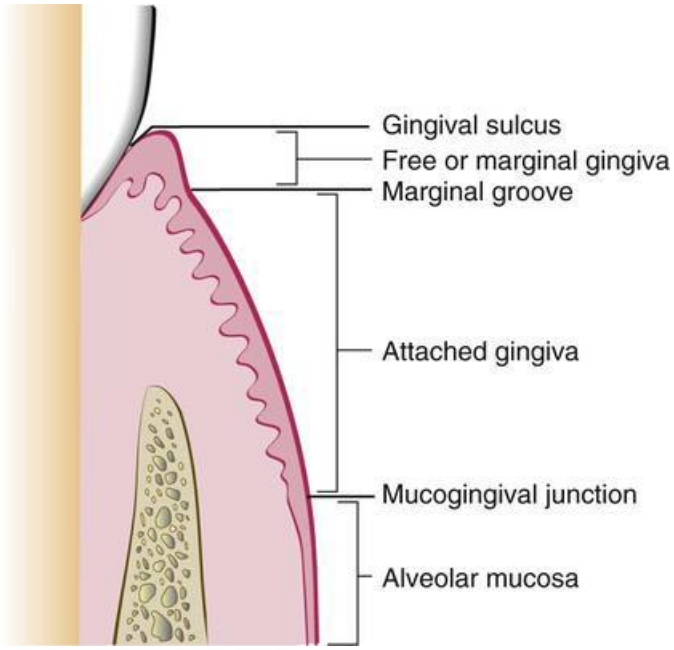

Figure 1. Anatomical landmarkes of the gingival tissue

Gingival sulcus

Is a space or shallow crevice around the tooth bounded by the surface of the tooth on the one side and the epithelium lining the surface of the gingiva on the other side. It is V-shaped and barely permits the entrance of periodontal probe.

Under **ideal** condition it is about **0 mm** which is seen only in germ free animal. In **histologic sections** the depth of the sulcus has been reported as **1.8 mm**. The probing depth of a **clinically normal gingival sulcus** is **2 to 3 mm**.

Boundaries of Gingival sulcus

The sulcus is coronal to the attachment of the junctional epithelium and bounded by the tooth on one side and the sulcular epithelium on the other. The coronal extent of the gingival sulcus is the gingival margin.

2. Attached gingiva

It is firm, resilient and tightly bound to the cervical portion of the tooth and underlying periosteum of the alveolar bone by the gingival fibers and the junctional epithelium, (Figure 2).

It is demarcated coronally from the free gingiva by the free gingival groove and extends apically to the mucogingival junction where it becomes continuous with the alveolar mucosa. (the junction between the attached gingiva and the alveolar mucosa is called the mucogingival line or junction).

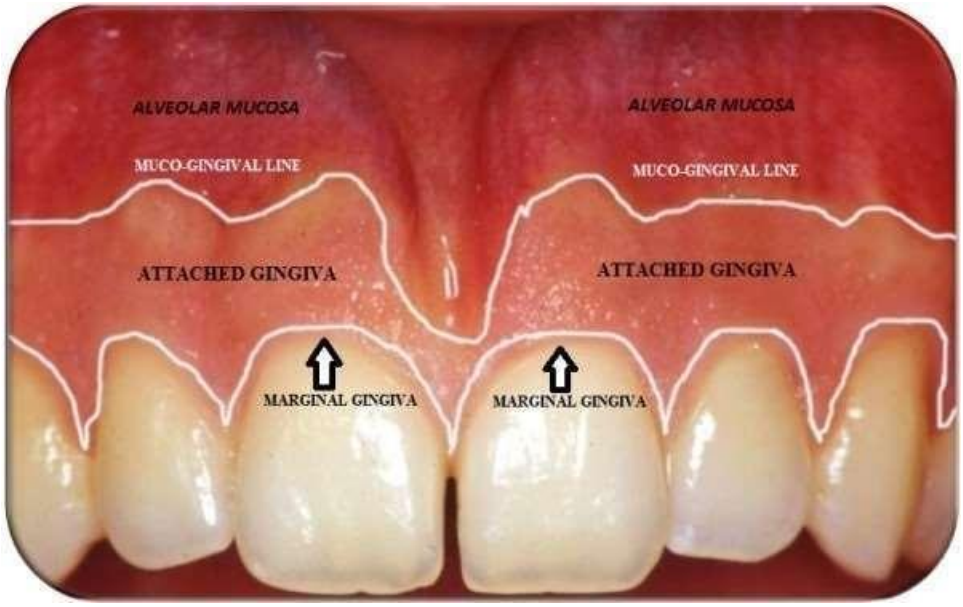

Figure 2. attached gingiva and its boundaries

Width of the attached gingiva

Defined as the distance between the mucogingival junction and the projection on the external surface of the bottom of the gingival sulcus or the periodontal pocket. While the width of the keratinized gingiva also includes the marginal gingiva

The width of attached gingiva is greater in maxilla than mandible. Least width in the mandibular 1st premolar and the greatest width are in the maxillary incisors. The width of attached gingiva **increases** with age and in supra-erupted teeth.

On the lingual aspect of the mandible terminates at the junction of the lingual alveolar mucosa, which is continuous with the mucous membrane that lines the floor of the mouth. The palatal surface of the attached gingiva in the maxilla blends with the firm palatal mucosa.

◦ Maxillary incisor region: 3.5- 4.5 mm (GREATEST)

• Mandible incisor region: 3.3 – 3.9 mm

◦ Maxillary premolar: 1.9 mm

• Mandibular first premolars: 1.8 mm

3. Interdental gingiva

The interdental gingiva occupies the gingival embrasure, Figure 3, which is the interproximal space beneath the area of tooth contact. The interdental gingiva can be pyramidal or can have a “col” shaped.

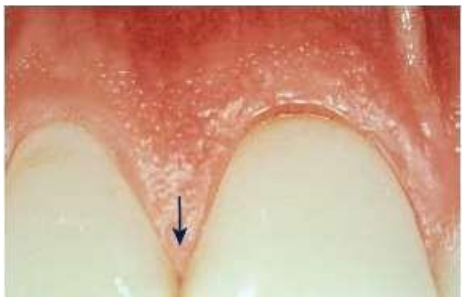

Figure 3. Interdental papilla

In the pyramidal, the tip of one papilla is located immediately beneath the contact point. The **Col** presents a valley-like depression that connects a facial and lingual papilla and follows the shape of the interproximal contact, Figure 4.

It is covered by thin non-keratinized epithelium representing the most frequent site for initiation of disease process.

The **lateral** border and **tip** of the Interdental papilla are formed by continuation of **marginal** gingiva and the **intervening** portion by the **attached** gingiva. In the presence of diastema, the Interdental papilla will be absent.



Figure 4. Interdental papilla, the Col

The shape of the interdental gingiva (the interdental papilla) is determined by:

• The contact relationships between the teeth.

• The width of the approximal tooth surfaces.

• The course of the cemento-enamel junction.

Microscopical features

Gingival tissue is composed of stratified squamous epithelium and central core of connective tissue:

1. Epithelium: predominantly cellular.

2. Connective tissue: less cellular and composed primarily of collagen fibers and ground substances.

1. Gingival Epithelium

It consists of a continuous lining of stratified squamous epithelium. Three different areas can be defined from the morphogenic and functional point of view:

1. The oral or outer epithelium (Keratinized epithelium)

2. Sulcular epithelium

3. junctional epithelium (non-keratinized epithelium)

1. The oral or outer epithelium

It covers the crest and outer surface of the marginal gingiva and the surface of the attached gingiva. On average, the oral epithelium is **0.2 to 0.3 mm** in thickness.

It is keratinized or Para keratinized or presents various combination of these conditions. Keratinization varies in different areas in the following order:

• Palate (Most keratinized)

• Gingiva

• Ventral aspect of the tongue

• Cheek (least keratinized)

The boundary between the oral epithelium and the underlying connective tissue has a wavy course. The projections of epithelial cells into the connective tissue are known as “Rete Pegs” while the intervening connective tissue portions which project into the epithelium are called connective tissue papillae. This alternating pattern of depression and protuberances of the connective tissue papillae and epithelial rete pegs is thought to give the attached gingiva the **stippled appearance**.

The oral epithelium has the following cell layers:

1. **Basal layer (stratum basale or stratum germintivum):** the basal cells are either cuboidal or cylindrical and possess the ability to divide. It is called stratum germintivum because it is where the epithelium renewed. The basal cells are separated from the connective tissue by a basement membrane.

2. **Spinous layer (Stratum spinosum):** consists of large cells with short cytoplasmic processes resembling spines.

3. **Granular layer (stratum granulosum):** electron dense keratohyalin bodies begin to occur. These granules are believed to be related to synthesis of keratin.

4. **Keratinized cell layer (stratum Corneum):** This is the most superficial layer and where both para and ortho-keratinization occur.

Types of cells in the oral epithelium

1. **Keratinocytes cell**: it is the principal cell type of oral epithelium comprises about 90% of the total cell population, responsible to produce keratin which contributes to the protective function of the epithelium. These cells undergo continuous proliferation and differentiation from basal cell to the surface of epithelium. It takes about 3-4 weeks for the keratinocyte to reach the outer surface where it becomes desquamated from stratum corneum.

2. **Melanocyte cells**: responsible to produce melanin pigment and can be found in the basal cell layer.

3. **Langerhans cell:** they play a role in defense mechanism of the oral epithelium. They have an immunological function by recognizing and processing antigens.

4. **Merkel cells**: they are located in the deeper layers of epithelium; they have nerve ending and have been identified as tactile receptors.

The epithelial cells are joined together by structure known as **desmosome**, which is composed of **two hemidesmosomes** separated from each other by granulated material (GM)

Each **hemidesmosome** is composed from:

- **The outer leaflets (OL):** of cell membrane of two adjoining cells.
- **The inner leaflet (IL):** is the thicker leaflet of cell membrane.
- **The attachment plaque (AP):** which represent granular.

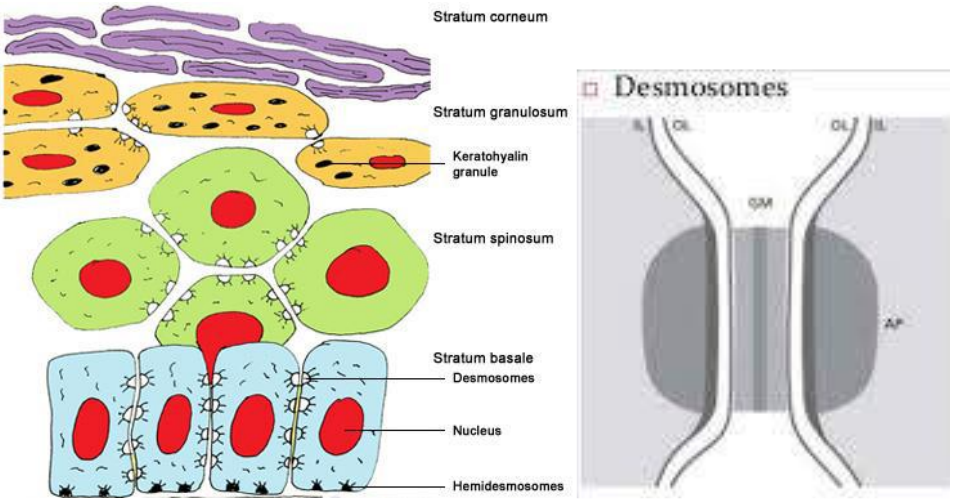

2. The sulcular epithelium

It lines the gingival sulcus and is thin, **non-keratinized** stratified squamous epithelium **without** rete pegs. It extends from the coronal limit of the junctional epithelium to the crest of the gingival margin. Although it contains Keratinocytes, they do not undergo Keratinization. Partial Keratinization may occur in response to physical stimulation.

The sulcular epithelium is extremely important because it may act as a semi permeable membrane through which injurious bacterial products pass into the gingival and tissue fluid from the gingiva seeps into the sulcus.

3. The junctional epithelium (JE):

The epithelium that attaches the gingiva to the surface of the tooth. It forms the base of the sulcus. The junctional epithelium is attached to the tooth surface by internal basal lamina and hemidesmosome and to the gingival connective tissue by external basal lamina and hemidesmosome.

The attachment of the JE to the tooth is reinforced by the gingival fibers; hence, the JE and the gingival fibers are considered a functional unit, referred to as the **dentogingival unit.**

The JE consists of a collar like band of stratified squamous non keratinized epithelium. Thickness varies from 2-3 Layers in early life and increases with age up to 15-20 layers at the base of the gingival sulcus. The length of junctional epithelium ranges from 0.25 to 1.35mm. The cells are arranged in basal and suprabasal layer. The JE assumes a key role in maintenance of periodontal health, it creates the firm epithelial attachment that connects the soft tissue to the tooth surface.

It is quite permeable and thus serves as a pathway for diffusion of the bacterial plaque products to the connective tissue. There is also a diffusion of host defense substances in the opposite direction moving towards the sulcus.

Differences between the three types of gingival epithelium

o The **size** of the cells in the junctional epithelium is relatively **larger** than the oral epithelium.

o The **intercellular spaces** are **wider** in the junctional epithelium than the oral epithelium.

o The **number of desmosome** is **fewer** in the junctional epithelium than the oral epithelium, this could explain the JE susceptibility to tear during probing and its greater permeability to migrate cells and fluids.

o **No Keratinization,a no rete pegs** in the sulcular and junctional epithelium, so they are **thinner** than oral epithelium

o **Turnover rate** is **very high** in junctional epithelium (4-6 days) compared to oral epithelium (6-12 days or up to 40 days).

o Junctional epithelium forms the **attachment** of the gingiva to the tooth surface while oral and sulcular epithelium have no attachment to tooth surface.

2. The gingival connective tissue (CT)

Epithelial-Connective tissue interface

Basement membrane forms a continuous sheet that connects the epithelium and connective tissue. Electron microscope reveals a faintly fibrillar structure, called as the basal lamina which is a part of the basement membrane. This structure has:

• Lamina lucida adjacent to the basal epithelial cell.

• Lamina densa which is located beneath the lamina lucida from this structure and there are anchoring fibrils that project into the connective tissue.

The connective tissue supporting the oral epithelium is termed as lamina properia and can be divided into two layers:

• The superfacial papillary layer: This has papillary projections between the epithelial rete pegs.

• The deep reticular layer: that lies between the papillary layer and the underlying structures.

The lamina properia consists of cells, fibers, blood vessels embedded in amorphous ground substances.

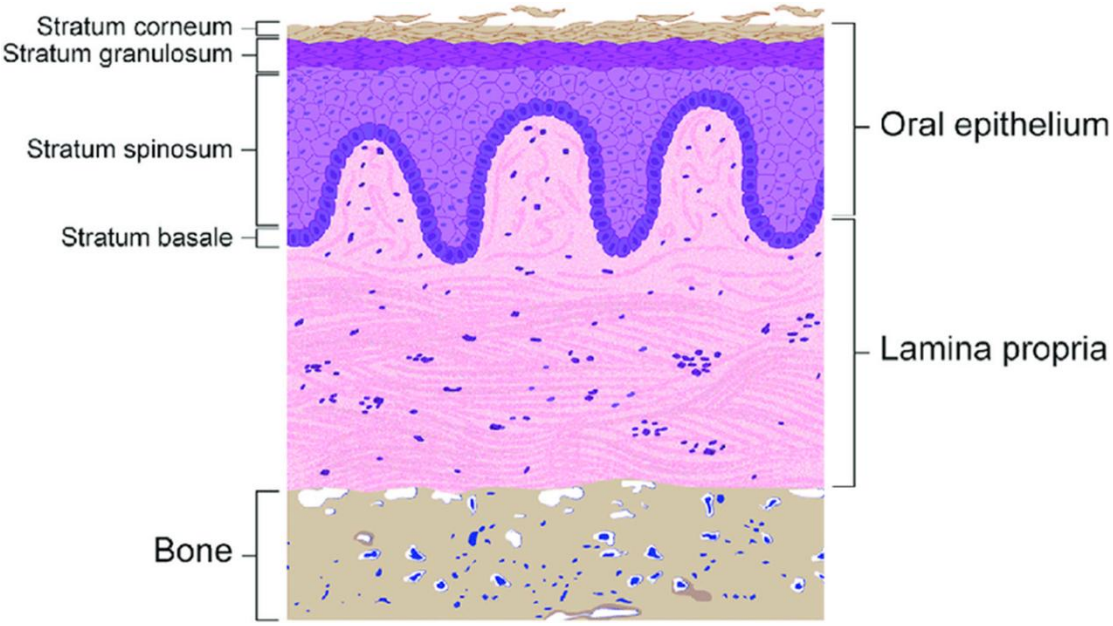

Cells of the connective tissue

o Fibroblast: the most predominant cells of the CT (65%). They synthesize collagen, elastic fibers and the connective tissue matrix, and they regulate collegen degredation.

o Mast cells: it is responsible for the production of certain components of the matrix, and they produces vasoactive substances which may control the flow of blood through the tissue.

o Macrophages: They have a phagocytic action and involved in the defense mechanism.

o Inflammatory cells: they have different immunological functions such as polymorphonuclear leukocytes, lymphocytes and plasma cells.

The connective tissue fibers

which are formed by the fibroblast's cells

• Collagen fibers: which is the most predominant type of fibers

• Reticulin fibers

• Oxytalan fibers

• Elastin fibers

The arrangement of the gingival fibers is described as **principle** group fibers which are:

1. **Dentogingival fibers**: they project from the cementum in a fan-like conformation towards the crest and outer surface of the marginal gingiva. They provide support to the gingiva by attaching it to the tooth.

2. **Alveolar gingival fibers**: they extend from the periosteum of the alveolar crest coronally into the lamina properia. Their function is to attach the gingiva to the alveolar bone.

3. **Dentoperiosteal fibers**: they arise from the cementum near the cementoenamel junction and insert into the periosteum of the alveolar bone and protect the periodontal ligament.

4. **Circular fibers**: they surround the tooth in a cuff or ring like fashion and course through the connective tissue of the marginal and attached gingiva.

5. **Trans-septal fibers**: they are located interproximally, they extend from cementum of one tooth to the cementum of neighbouring tooth. They protect the interproximal bone and maintain tooth to tooth contact.

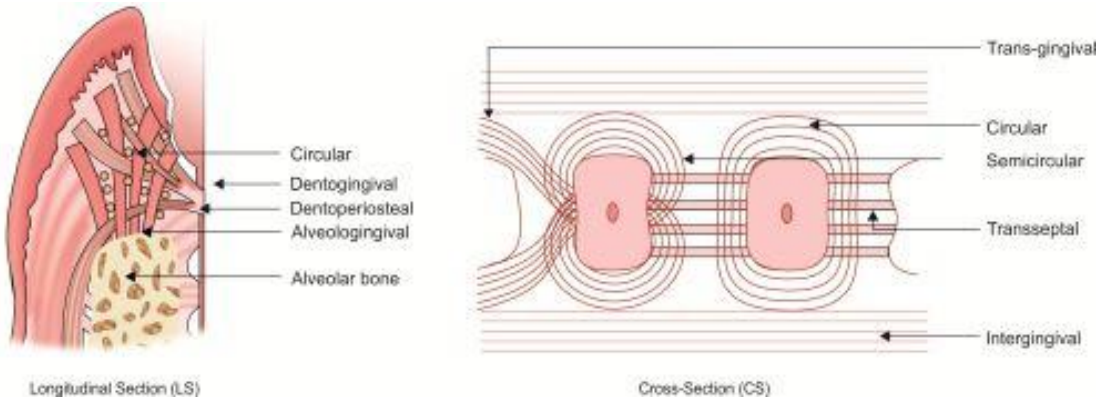

Longitudinal Section (LS)

Cross-Section (CS)

The functions of gingival fibers

1. It braces the marginal gingiva firmly against the tooth.

2. It helps to withstand the forces exerted by mastication

3. It unites the free gingiva to the root cementum and the adjacent attached gingiva.

Connective tissue ground substances

It is produced by fibroblast, followed by mast cells and other components derived from the blood. The matrix is the medium in which the connective tissue cells are embedded and is essential for the maintenance of the normal function of the connective tissue. Thus, the transportation of water, electrolytes, nutrients, metabolites etc.. to and from the individual connective tissue cells occurs within the matrix.

The main constituents are proteoglycans and glycoproteins.

Blood supply and nerves

Gingival tissue has rich vascular supply from internal maxillary artery.

Blood supply is from:

• Supraperiosteal arteriols.

• Vessels of periodontal ligaments.

• Arterioles emerging from the crest of the Interdental septa.

Nerve supply is derived from the terminal branches of the maxillary and mandibular branches of the trigeminal nerve.

Clinical descriptive criteria of clinically healthy gingiva and inflamed one

1. Gingival color

The normal color of gingiva is **coral pink** with some variations depending on:

• The amount of **melanin** in the tissues.

• The **thickness** of the epithelium.

• The degree of the **Keratinization**.

• The **vascularity** of the connective tissue.

Dark skinned people often exhibit dark blue or brown color. Melanin, a non-hemoglobin-derived brown pigment, is responsible for the normal pigmentation of the skin, gingiva and remainder of the oral mucous membrane. It is present in all normal individuals, often not in sufficient quantities to be detected clinically but in black individuals it is prominent in the oral cavity.

The color of inflamed gingiva may vary from **red** to **bluish red** due to vasodilatation which leads to bleeding tendency.

2. Gingival contour

The gingiva usually ends coronally in **knife** edged margins and **scalloped** in contour. In inflamed gingiva, the contours are often rounded and enlarged because of vascular stagnation and increases formation of collagen fibers.

3. Gingival consistency

The gingiva is usually resilient, firm and bound down to the underlying bone because of the dense collagenous nature of the gingival connective tissue.

In inflamed gingiva, the consistency may be **soft and spongy** because of the vascular stagnation and decrease in the amount of gingival collagen

fibers or **extremely firm** because of excessive formation of collagen (fibrosis), this is in case of chronic inflammation.

4. Gingival surface texture

Gingiva may have either **stippled or smooth and shiny surface**, the attached gingiva is stippled, while the free gingiva is smooth. In inflamed gingiva, reduction or lack of stippling is not an indicator of health nor is the absence of stippling an indicator of disease. Hence, stippling frequently begins to disappear in old age.

5. Size

The size of the gingiva corresponds with the sum of the bulk of cellular and intercellular elements and their vascular supply. Alteration in size is a common feature of gingival disease.