Phase II Surgical phase

Contents

Phase II Surgical Therapy

- • Periodontal surgery
- • Objectives of periodontal surgery
- • Gingivectomy
- • Excisional and Incisional Instruments
- • Gingivoplasty
- • Gingival Curettage
- • Postoperative instruction
- • Management of Postoperative Pain
- • Periodontal dressing
- • Maintenance phase (supportive periodontal therapy SPT)

Phase II Surgical Therapy

In this phase the surgical techniques are used for the following purposes:

1-Controlling or eliminating periodontal disease (surgical pocket therapy)

2-Correcting anatomic conditions that favour periodontal disease, impair aesthetics or delay the placement of prosthetic appliances (plastic surgery, aesthetic surgery, preprosthetic techniques)

3-Placing implants to replace lost teeth and improve the environment for their placement and function.

Periodontal surgery

Successful cause-related therapy (by the removal of plaque and calculus) will reduce gingival inflammation thereby assessing the true gingival contour and pocket depth possible. In addition, the soft tissue will be more fibrous and thus firmer, which facilitates surgical handling of the soft tissues.

The propensity for bleeding is reduced, making the inspection of the surgical field easier. The effectiveness of the patient's home care which is of decisive importance for the long-term prognosis must be properly evaluated; a lack of effective self-performed plaque control will often mean that the patient should be excluded from surgical treatment. Transient root hypersensitivity and recession of the gingival margins frequently accompany the healing process following close and open S+ RP, thus the patient should be warned that these results may happen.

Objectives of periodontal surgery

1-Accessibility and direct vision for proper S+ RP

2-Reduction or elimination of plaque retentive area especially periodontal pockets that have not responded to initial therapy.

3-Eliminate inflamed periodontal tissue

4-Enhancing the regeneration of periodontal tissue

5-Create a physiologic morphology of the dentogingival area that will facilitate efficient self performed plaque control

6-Correct mucogingival defect and improve periodontal aesthetic

7-Provide access to correct bony defects

Surgical treatment includes

1-Gingivectomy for the removal of the over growth gingival tissues

2-Flap surgery

3-Distal wedge procedure

4-Mucogingival surgery for correction of mucogingival and aesthetic defect

5-Crown lengthening to increase clinical crown length

6-Guided tissue regeneration (GTR) to regenerate periodontal supporting structures

Gingivectomy

This surgical procedure aimed at the excision of the soft tissue wall of a pathologic periodontal pocket and this pocket elimination was usually combined with recontouring of the diseased gingiva to restore physiologic form (e.g. Drugs induced gingival enlargement, and the resulting false pocket can be removed by this method).

Indication

1-Gingival enlargement or overgrowth

2-Idiopathic gingival fibromatosis.

3-Shallow supra bony pocket

4-Minor corrective procedure

Contraindication

1-Infrabony pocket

2-Thickening of marginal alveolar bone and the need for bone surgery

3-Attached gingiva is narrow or absent

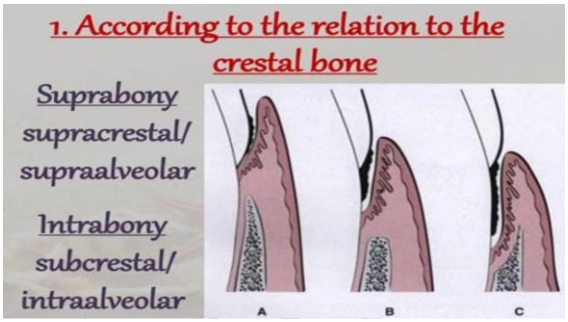

Advantage

1-Technically simple, good visual access

2-Complete pocket elimination

3-Restoration of a physiologic gingival contour

Disadvantage

1-Gross wound, post operative pain

2-Healing by secondary intention

3-Danger of exposing bone

4-Loss of attached gingiva

5-phonetics and aesthetic problem in the anterior area with sensitivity due to exposure of the cervical area of tooth

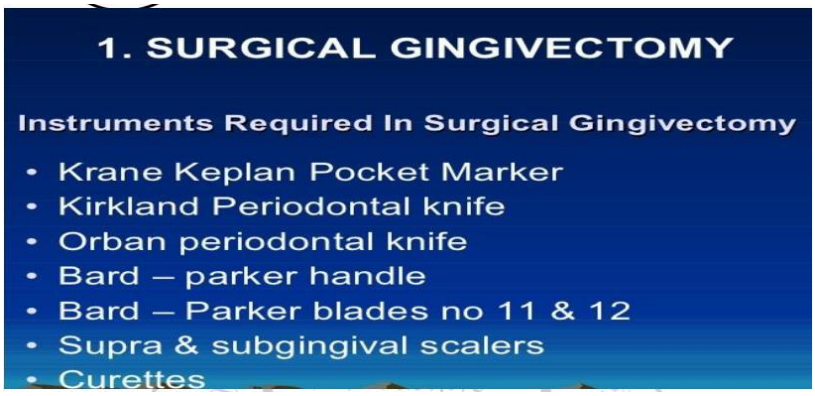





Fig. 59.7 Surgical blades. *Top to bottom,* #15, #12D, and #15C. These

Gingivectomy knives





Sharpness!
Arkansas stone + oil

- GV knife (Kirkland, L & R)
- Papilla knife (Orban, L & R)
- Universal knife

Pocket marking forceps





- Paired (L & R)
- **Use:** indicate the location of the base of the pocket

Pocket marking forceps



Excisional and Incisional Instruments

Periodontal Knives (Gingivectomy Knives)

1. The Kirkland knife is representative of the knives that are typically used for gingivectomy. These knives can be obtained as either double-ended or singleended instruments. The entire periphery of these kidney-shaped knives is the cutting edge.

2. Interdental Knives: The Orban knife and the Merrifield knife are examples of knives that can be used for interdental areas. These spear-shaped knives havecutting edges on both sides of the blade, and they are designed with either double-ended or single-ended blades.

3. Surgical Blades Scalpel blades of different shapes and sizes are used in

periodontal surgery. The most common blades are #12D, #15, and #15C .

The #12D blade is a beak-shaped blade with cutting edges on both sides that allow the operator to engage narrow, restricted areas with both pushing and pulling cutting motions. The #15 blade is used for thinning the flaps and is also used for general purposes. The #15C blade, which is a narrower version of the #15 blade, is useful for making the initial, scalloping-type incision. The slim design of this blade allows for incising into the narrow interdental portion of the flap. All of these blades are discarded after one use.

Goldman gingivectomy procedure

1. Giving local anaesthesia

2. Marking the pocket depth: the straight arm of a pocket depth marker forceps is guided into a buccal pocket, when the base of the pocket is encountered, the forceps is pinched together causing the horizontal forceps tip to mark the depth of the pocket, by repeating this procedure at each tooth surface, a series of bleeding points is created, which are used subsequently as a guide for incision.



Fig. 60.12 The pocket marker makes pinpoint perforations that indicate pocket depth.

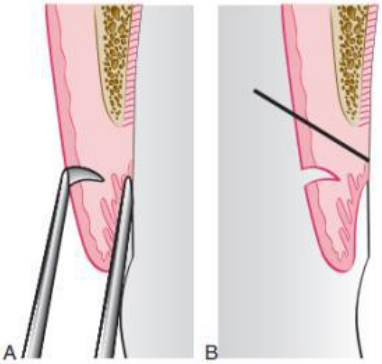

Fig. 60.13 Marking the depth of a suprabony pocket. (A) A pocket marker in position. (B) The beveled incision extends apical to the perforation made by the pocket marker.

414 Marking the base of pockets

The pocket marking forceps is used on papillae and on the midfacial marginal gingivae to indicate the course of the sulcus base between teeth 43 and 33.

An incision at this level would yield a blunt ledge of tissue; therefore, the incision must be made slightly apical to the bleeding points.





417 Proper position of the Kirkland gingivectomy knife

The GV knife is placed at a 45° angle to the tooth long axis, at the first marking point near tooth 33. From here a...

3. ***Primary bevelled incision*** which was carried out 1 mm apical to bleeding points by Kirkland knife.



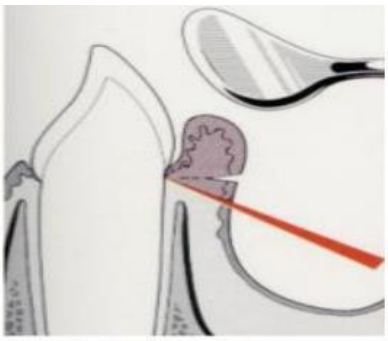

4. Continuous incision or interrupted , straight or scalloped is made.

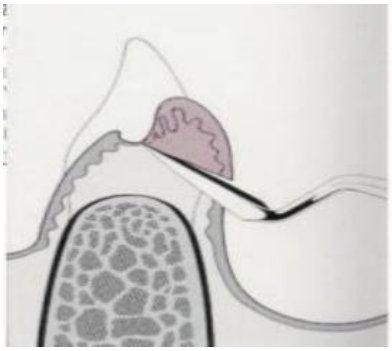



5. Secondary incision to separate the interproximal soft tissues from the interdental periodontium by Orban knife.

421 Removal of the tissue
The gingival segment is lifted gently with a forceps, and the papilla knife is used to severe any remaining tissue.



6. Careful removal of the incised tissues by a currete or a cumine.

422 Excised tissue
In this case it was possible to remove the redundant tissue as a single piece. If the etiology of the lesion is known, there is no need for a histopathological assessment of the specimen.



423 Scaling and root planing with direct vision
Any plaque and calculus remaining in the pseudopocket after initial therapy becomes visible once the redundant tissue is removed, and can be eliminated completely during root planing.

Thus, the most important component of the gingivectomy procedure is the thorough cleansing and smoothing of the tooth. This will insure a bioacceptable surface as the new epithelial attachment and junctional epithelium form during the healing process.



7. By curette remove plaque, calculus and granulation tissues then smoothing teeth surfaces.



424 Gingivectomy wound after scaling
Despite the 45° angulation employed during surgery, the wound margin is still at a relatively sharp angle. This edge must be rounded in order to provide ideal gingival contour after healing.

8. Use Kirklaned knife for gingivoplasty(minor alterations in gingival morphology without tissue excision)by shaving wound margin to create thin margin.



427 Clinical view immediately following GV/GP
The surgical procedure has resulted in a relatively expansive open wound surface which must be covered and protected with a periodontal dressing.

429 Dressing in place
In this case, Peripac was used. This is a rigid dressing which must not encroach upon the mobile mucosa, to prevent formation of pressure areas and ulceration. The dressing should be left in situ for 7–10 days without changing it.



9. Control bleeding by placing gauze packs Put dressing to cover the wound with pressure to prevent the bleeding with consequence formation of granulation tissue under dressing and without interference with occlusion or mobile Mucosa

430 Dressing removal and dental prophylaxis after 7 days

The dressing is carefully removed and the teeth gently cleaned using a rubber cup and a minimally abrasive prophy paste (or dentifrice). The wound surface is cleansed using hydrogen peroxide solution (3%) on cotton pellets, then sprayed with the water syringe. The patient can be dismissed with the recommendation that oral hygiene be practiced regularly, but carefully at first.

A second dressing application is indicated only if epithelialization appears to be retarded.





Fig. 60.11 Results obtained by treating a suprabony pocket with gingivectomy. (A) and (B) Preoperative facial and palatal views. (C) Marking of the depth of the suprabony pocket. (D) The bottoms of the pockets are indicated by pinpoint markings. (E) A beveled palatal incision with an Orban knife. (F) A facial beveled incision with a Bard–Parker #15 blade extends apical to the perforations made by the pocket marker. Note that the beveled incision can also be made with a Kirkland knife. (G) The interdental incision and excision of the pocket wall with a Bard–Parker #12 blade. (H) A completed gingivectomy. (I) The surgical site covered with periodontal dressing. (J) One week after healing. (K) and (L) Results 22 months after the operation. *(Courtesy Dr. Kitetsu*

Gingivoplasty

Is recontouring the gingiva in the absence of pockets. It may be accomplished with a periodontal knife, a scalpel, or rotary coarse diamond stones.

Gingival Curettage:

The word curettage is used in periodontics to describe the scraping of the gingival wall of a periodontal pocket to remove the chronically inflamed tissue.

It is a definitive subgingival curettage procedure that is performed with a knife. Historically, it was thought this tissue hinders healing and new attachment, which necessitate gingival curettage. However, when the root is thoroughly scaled and planed, and the biofilm and calculus are removed, the inflammation in the tissue automatically resolves without tissue curettage. Therefore,the use of curettage to eliminate the inflamed granulation tissue is unnecessary.

It has been shown that scaling and root planing with additional curettage do not improve the condition of the periodontal tissues beyond the improvement that results from scaling and root planing alone.

Postoperative Instructions:

The typical postoperative instructions should be given to the responsible adult, and the patient should be scheduled for a postoperative visit in 1 week. with a clear view of the surgical site.Typically, the control of intraoperative bleeding can be managed with

1. aspiration. Continuous suctioning of the surgical site with an aspirator.

2. The application of pressure to the surgical wound with moist gauze can be a helpful adjunct to control site-specific bleeding.

3. A suture can then be passed through the tissue and tied to restrict blood flow.

4. Minor areas of persistent bleeding from capillaries can be stopped by applying cold pressure to the site with moist gauze for several minutes.

5. The use of a local anesthetic with a vasoconstrictor (epinephrine) may also be useful for controlling minor bleeding. Both of these methods act through vasoconstriction, thereby reducing the flow of blood. This action is relatively short lived, and it should not be relied on for long-term hemostasis.

It is important to avoid the use of vasoconstrictors to control bleeding before sending a patient home. When the patient is dismissed from the appointment and the effect of the vasoconstriction is no longer present, bleeding can occur during the patient's trip home. For a slow, constant blood flow and oozing, **hemostasis** may be achieved with hemostatic agent, Absorbable gelatin sponge. Finally, it is imperative to recognize that excessive bleeding may be caused by systemic disorders, including (but not limited to) platelet deficiencies, coagulation defects, medications, and hypertension.

As a precaution, all surgical patients should be asked about any current medications that maycontribute to bleeding, any family history of bleeding disorders, and hypertension. All patients, regardless of health history, should have their blood pressure evaluated before surgery, and anyone who is diagnosed with hypertension must be advised to see a physician before surgery. Patients with known or suspected bleeding deficiencies or disorders must be carefully evaluated before any surgical procedure. A consultation with the patient's physician is recommended, and laboratory tests should be performed to assess the risk of bleeding. It may be necessary to refer the patient to a hematologist for a comprehensive workup

First Postoperative Week

Patients should be instructed to rinse with 0.12% chlorhexidine gluconate immediately after the surgical procedure and twice daily thereafter until normal biofilm control can be resumed.

The following complications may arise during the first postoperative week:

1. Persistent bleeding after surgery. The dressing is removed, and local anaesthesia may be needed before the bleeding areas are located.

The bleeding is stopped with pressure, or if necessary the area may have to be anesthetized and resutured. After the bleeding has been stopped, the area is again redressed.

2. Sensitivity to percussion. Extension of inflammation into the periodontal ligament may cause sensitivity to percussion. The dressing should be removed and the surgical area checked for localized areas of infection or irritation. The area should be irrigated or enabled to provide drainage if areas of localized exudate are present. Particles of calculus that may have been overlooked should be removed. Relieving the occlusion can be helpful. Sensitivity to percussion may also be

caused by excess dressing, which interferes with the occlusion. Removal of the excess usually corrects the condition.

3. Swelling. During the first 2 postoperative days, some patients may report a soft, painless swelling of the cheek in the surgical area. Lymph node enlargement may occur,and the temperature may be slightly elevated. The area of operation itself is usually symptom-free. This type of involvement results from a localized inflammatory reaction to the surgical procedure. It generally subsides by the fourth postoperative day without necessitating the removal of the dressing. If swelling persists, enlarges, or is associated with increased pain, amoxicillin (500 mg) should be taken every 8 hours for 1 week. The patient should also be instructed to apply moist heat intermittently over the area.

4. Feeling of weakness. Occasionally, patients report having weakened feelings for about 24 hours after surgery. This represents a systemic reaction to transient bacteremia induced by the procedure. This reaction can be prevented by premedication with amoxicillin (500 mg) every 8 hours. This protocol should be started 24 hours before the next procedure and continue for 5 days postoperatively.

Removal of the Dressing and Return Visit

When the patient returns in 1 week, the periodontal dressing is removed by inserting a curette along the margin and exerting gentle lateral pressure. Pieces of the dressing retained interproximally and particles adhering to the tooth surfaces are also removed with curettes. Particles of dressing and debris may be enmeshed in the surgical surfaces and should be carefully removed with cotton pliers. The entire area is irrigated with peroxide to remove the superficial debris.

Findings at the Time of Dressing Removal

The following are the usual findings when the dressing is removed:

• If gingivectomy has been performed, the incised surface is covered with a friable meshwork of new epithelium. This tissue should not be disturbed. If calculus has not been completely removed, red, beadlike protuberances of granulation tissue will persist. The granulation tissue must be removed with a curette to expose the calculus so the root can be planned.

• The facial and lingual mucosa may be covered with a greyish-yellow or white granular layer of debris that has entered under the dressing. This is easily removed with a moist cotton pellet. The root surfaces may be sensitive to touch or thermal

change. The patient should be assured that these changes will disappear with time (4 to 6 weeks). The dentition that was beneath the dressing may be stained in a brownish-yellow color that can be removed by polishing later.

• Fragments of calculus delay healing. Each root surface should be carefully rechecked visually to be certain that no calculus was missed during surgery. The grooves on the proximal root surfaces and the furcations are areas where calculus is likely to be overlooked.

Redressing

After the dressing is removed, it is usually not necessary to replace it. However, redressing for an additional week is advised for the following types of patients:

(1) those with a low pain threshold who are particularly uncomfortable when the dressing is removed.

(2) those with unusually sensitive root surfaces post-surgically.

(3) those with an open wound. Periodontal dressings assist healing by protecting the tissue through prevention of surface trauma during mastication and protect the patient from pain induced by contact of the wound with food or with the tongue during mastication

Tooth Mobility

Tooth mobility usually increases immediately after surgery. This results from edema in the periodontal ligament space from the inflammation that occurs posturgically. The mobility diminishes to the pretreatment level by the fourth week. The patient should be reassured before surgery that the mobility is temporary.

Mouth Care Between Procedures

1. Because the area is still healing and uncomfortable. Vigorous brushing is not feasible during the first week after the dressing is removed. However, the patient is advised to try to keep the area as clean as possible with the gentle use of a soft toothbrush and light water irrigation.

2. Rinsing with chlorhexidine mouthwash or applying such a rinse topically with cotton-tipped applicators is indicated for the first few postoperative weeks.

3. Brushing is introduced when the healing of the tissues permits, and the overall hygiene regimen is increased as healing progresses.

Patients should be told that (1) some gingival bleeding will occur when the wounded areas are gently cleaned; (2) this bleeding is normal and will subside as healing progresses; and (3) the bleeding should not deter them from following their oral hygiene regimen.

Management of Postoperative Pain

Periodontal surgery produces only minimal pain and discomfort. a common source of postoperative pain is an overextension of the periodontal dressing onto the soft tissue apical to the mucogingival junction or onto the frena. Overextended dressings cause localized areas of edema that are usually noticed 1 to 2 days after surgery.

The removal of excess dressing is followed by a resolution in about 24 hours. Extensive and excessively prolonged exposure of bone with poor irrigation during surgery induces greater pain.

For most healthy patients, a preoperative dose of ibuprofen (600 to 800 mg) followed by one tablet every 8 hours for 24 to 48 hours is very effective for reducing discomfort after periodontal surgery. Caution should be used when prescribing or dispensing ibuprofen to patients with hypertension that is controlled by medications because it can interfere with the effectiveness of the medication.

Patients experiencing severe postoperative pain should be seen on an emergency basis. The area should be anaesthetized by infiltration, and the dressing should be removed to allow for theexamination of the area in pain. Postoperative pain related to infection is accompanied by localized lymphadenopathy and a slight elevation in temperature. This type of pain should be treated with systemic antibiotics and analgesics.

Dentin (Root) Hypersensitivity

Dentin or root hypersensitivity is a relatively common problem in periodontal practice. It may occur spontaneously when the root becomes exposed as a result of gingival recession or pocket formation, or it may appear after scaling and root planing and other periodontal surgical procedures. The root sensitivity management must be performed.

Periodontal dressing

Is mainly used:

I· To protect the wound post-surgically

2-To obtain and maintain a close adaptation of the mucosal flaps to the underlying bone (especially when a flap has been repositioned apically)

3-For the comfort of the patient

4-Prevent post-operative bleeding during the initial phase of healing

5-Prevent the formation of excessive granulation tissue.

Periodontal dressing should have the following properties:

1-Should be soft but still have enough plasticity and flexibility to facilitate its placement in the operated area and to allow proper adaptation.

2-Should harden within a reasonable time

3-After setting should be sufficiently rigid to prevent fracture and dislocation.

4-Should have a smooth surface after setting to prevent irritation to the check and lips

5-Should preferably have bactericidal properties to prevent excessive plaque formation

6-Not detrimentally interfere with healing

Types of dressing

I-Zinc-oxide eugenol pack: eugenol in this type may induce an allergic reaction

2-Non eugenol pack: e.g. Coe pack; one tube contain zinc oxide and lorothidol (Fungicidal) and the second tube contain non ionizing carboxilic acids and chlorothymol (bacteriostatic agent)

3-Light cured dressing



Retention of Dressing

Periodontal dressings are usually kept in place mechanically by interlocking the dressing in interdental spaces and joining the lingual and facial portions of the dressing. In isolated teeth or when several teeth in an arch are missing, retention of the dressing may be difficult. Numerous reinforcement splints and stents for this purpose have been described. The placement of dental floss tied loosely around the teeth enhances the retention of the dressing.

Allergy

Contact allergies to eugenol and rosin have been reported.

Antibacterial Properties of Dressing

Improved healing and patient comfort with less odor and taste have been obtained by incorporating antibiotics into the dressing. Bacitracin, oxytetracycline (Terramycin), tetracycline, neomycin, and nitrofurazone have been used. Care must be taken when any antibiotic products are used because they may produce hypersensitivity reactions. The emergence of resistant organisms and opportunistic infections has been reported. The incorporation of tetracycline powder into the Coe-Pak is generally recommended, particularly when long and traumatic surgical procedures are performed.

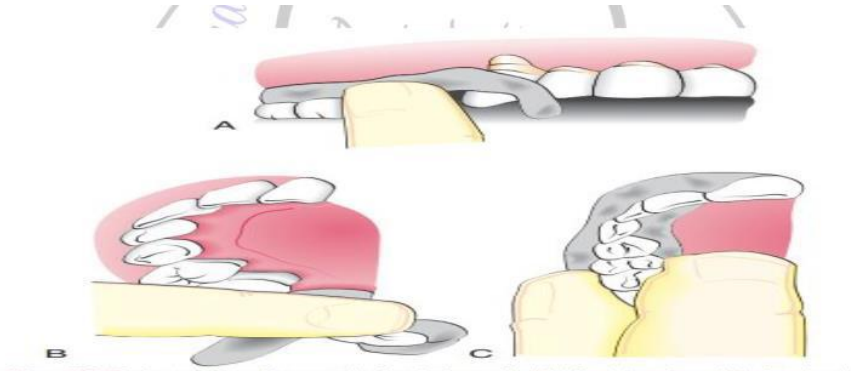

Fig. 59.2 Inserting the periodontal pack. (A) A strip of pack is hooked around the last molar and pressed into place anteriorly. (B) The lingual pack is joined to the facial strip at the distal surface of the last molar and fitted into place anteriorly. (C) Gentle pressure on the facial and lingual surfaces joins the pack interproximally.



Fig. 59.3 Continuous pack covers the edentulous space.

Maintenance phase (supportive periodontal therapy SPT)

Preservation of the periodontal health of the treated patient requires a supportive program that is just as important as the therapy used to treat the periodontal disease. The maintenance phase of periodontal treatment starts immediately after the completion of phase I therapy. While the patient is in the maintenance phase, the necessary surgical and restorative procedures are performed. This ensures that all areas of the mouth retain the degree of health attained after phase I therapy.

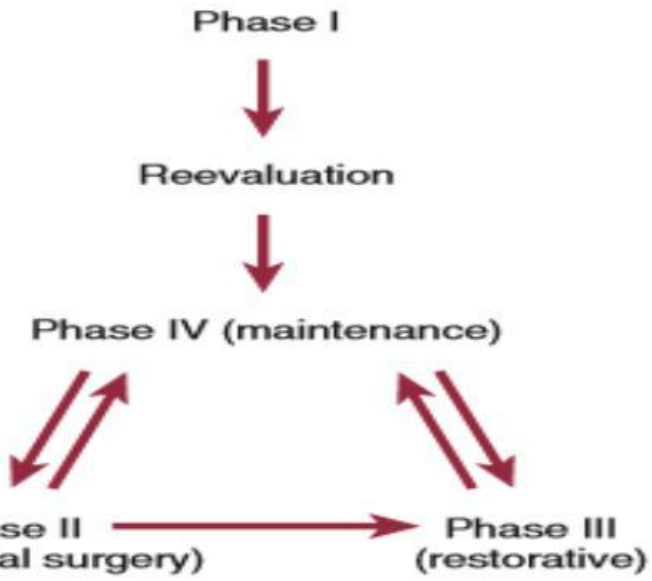

Fig. 72.2 Correct sequence of periodontal treatment phases.

The primary goal of maintenance therapy include

I-Maintenance of oral health (cancer screening)

2-Prevention of new infection

3-Prevention of re-infection and disease recurrence.

The time interval between the recall appointments should be based on a periodontal risk assessment (type and severity of periodontitis, systemic and local risk factors, degree of motivation, compliance, manual dexterity and the patient's success to maintain a proper personal oral hygiene standard.It is important to emphasize that the recall program must be designed to meet the individual needs of the patient, some patients should be recalled every month while others may have to be checked only once a year. Findings From long-term clinical trials have suggested that recall appointments, once every three months are effective in preventing disease recurrence.

There are three parts to an SPT appointment:

1. examination

2. treatment

3. report, clean up and scheduling

The time required for a recall visit for patients with multiple teeth in both arches is approximately 1 hour.

Recurrence of Periodontal Disease

Occasionally, lesions may reoccur, which is often due to inadequate plaque/biofilm control on the part of the patient or failure to comply with recommended SPT schedules.

It should be understood, however, that it is the responsibility of the dentist to educate and motivate patients to improve their oral hygiene techniques. Surgery should not be undertaken unless the patient participates in disease prevention and demonstrates proficiency in plaque/biofilm control.

Other causes for recurrence include the following:

1. Inadequate or insufficient treatment that has failed to remove all of the potential factors favoring biofilm accumulation. Incomplete calculus removal in areas of difficult access is a common source of problems.

2. Inadequate restorations were placed after the periodontal treatment was completed.

3. Failure of the patient to return for periodic maintenance care.

4. Presence of some systemic diseases that may affect host resistance to previously acceptable levels of biofilm.

A failing case can be recognized by the following:

1. Recurring inflammation revealed by gingival changes and bleeding of the sulcus on probing.

2. Increasing depth of sulci, leads to the recurrence of pocket formation.

3. Gradual increases in bone loss, as determined by radiographs.

4. Gradual increases in tooth mobility, as ascertained by clinical examination.

The decision to retreat a periodontal patient should not be made at the preventive maintenance appointment but should be postponed for 1 to 2 weeks. Often, the mouth appears improved at that time because of the resolution of edema and the resulting improved tone of the gingiva.

References

Lang, N.P., Berglundh, T., Giannobile, W.V. and Sanz, M. eds., (2021). *Lindhe's clinical periodontology and implant dentistry*. John Wiley & Sons.

Newman, M.G. *et al.* (2011). *Carranza's clinical periodontology*. Elsevier health sciences.