Advances in Pediatric Dentistry

Advances in diagnostic aids

I-Digital radiography

is a filmless technique for intraoral radiography, utilizes very little of the radiation to which the patient has been exposed and avoid the need for developing films.

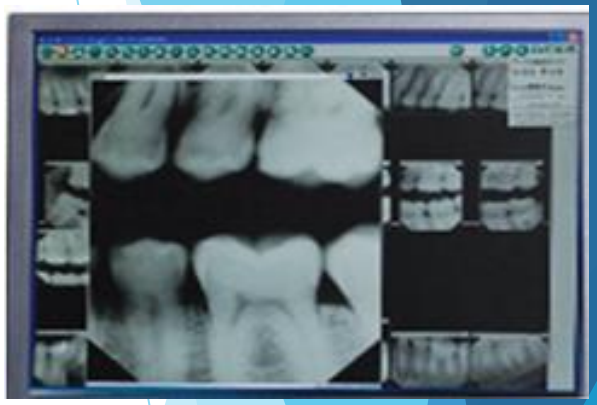

Advantages

1- The image is displayed immediately and no need of processing

2- Reduction in radiation dose

3- Digital manipulation of the image is possible to enhance the viewing

4 - It can be used as a visual aid to be shown to the patient on the computer screen

5 - It increases the confidence and credibility in the treatment-decision making process.

Disadvantages

1 - The rigidity and thickness of sensor can cause discomfort to the patient

2-The lifespan of sensor is unknown

3- High initial system cost

II- Digital Subtraction Radiography (DSR) is a more advanced image analysis tools which allows professionals to distinguish small differences between subsequent radiographs that otherwise would have remained unobserved because of over projection of anatomical structures or differences in density that are too small to be recognized by the human eye.

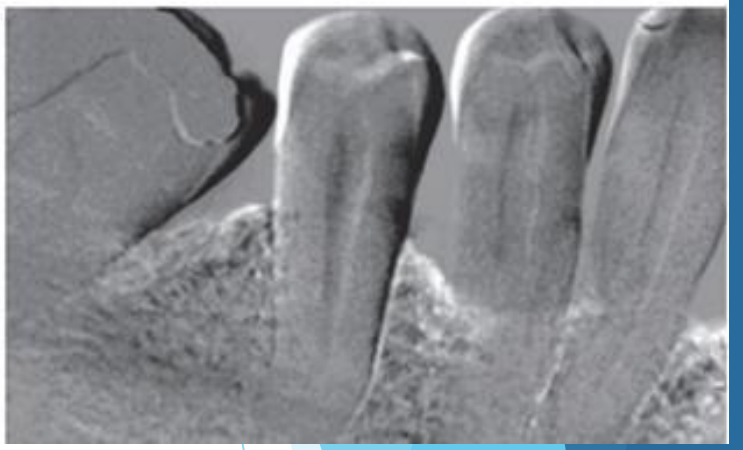

- The procedure is based on the principle that two digital radiographic images obtained under different time intervals,
- If the two digital images are identical, this method will produce an image without details (the result is zero).
- When there is caries progression, the outcome will be a value above zero (increase in pixel values).
- In case of caries regression, the result is opposite, and the outcome will be a value below zero (decrease in pixel values)
- The major disadvantage of this technique is very sensitive to any physical noise occurring between the radiographs and even minor changes leads to large errors in the results

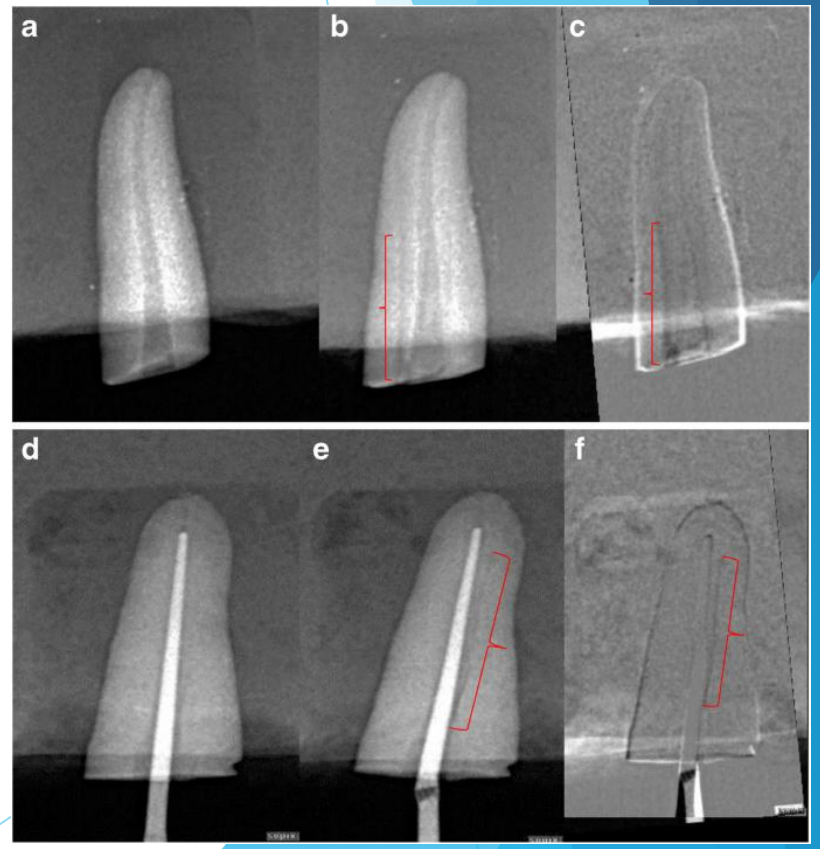

III- Fiberoptic Transillumination

It is a practical method of imaging teeth in the presence of multiple scattering.

The illumination is delivered via light source to tooth surface. The light propagates from the fiber illumination across tooth tissue to nonilluminated surfaces.

The resulting images of light distribution are then used for diagnosis. Carious area appears as darkened shadow that follows the decay. It is used for diagnosis of caries and identification of necrotic canals.



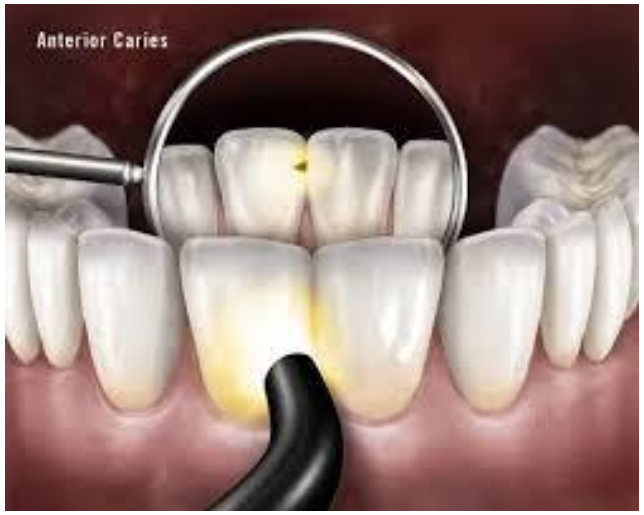

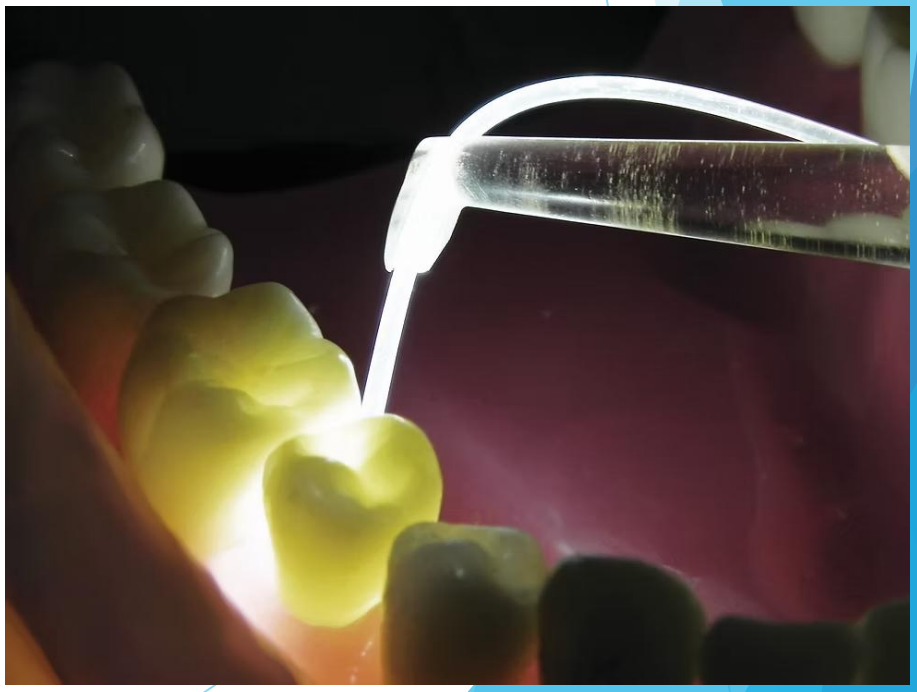

IV-Quantitative Light-induced Fluorescence

The **QLF equipment** is comprised of a light box containing a xenon bulb and a handpiece, similar in appearance to an intraoral camera. Light is passed to the handpiece via a liquid light guide and the handpiece contains the bandpass filter.

Live images are displayed via a computer and accompanying software enables patient's details to be entered and individual images of the teeth of interest to be captured and stored. Once an image of a tooth has been captured, the next stage is to analyze any lesions and produce a quantitative assessment of the demineralization status of the tooth.

Advantages are high reproducibility, detection of small incipient lesions in enamel and dentin, image storage and transmission and can act as motivational tool for patient.

- Disadvantage is that it is an isolation sensitive procedure.









V-DigitalImaging Fiberoptic Transillumination

This is a new method for detection of dental caries in which the images of teeth are obtained through visible light fiberoptic transillumination and digital CCD camera. These images are then sent to a computer for analysis with specific algorithms. These algorithms are developed to facilitate the location and diagnosis of the carious lesion and provide quantitative characterization for monitoring the lesions.

Advantage is that it can indicate the presence of incipient and recurrent caries even when radiological images fail to show their presence.





VI-Fluorescence Camera (Vista Proof)

This device is an intraoral camera which consists of six blue LEDs emitting a 405- nm light, charge couple device (CCD) sensor and software for analysis. With this camera it is possible to digitize the video signal from the dental surface during fluorescence emission using a CCD sensor. On these images, it is possible to see different areas of the dental surface that fluoresce in green (sound dental tissue) and in red (carious dental tissue).

Advantages include motivation for patient and storage of data

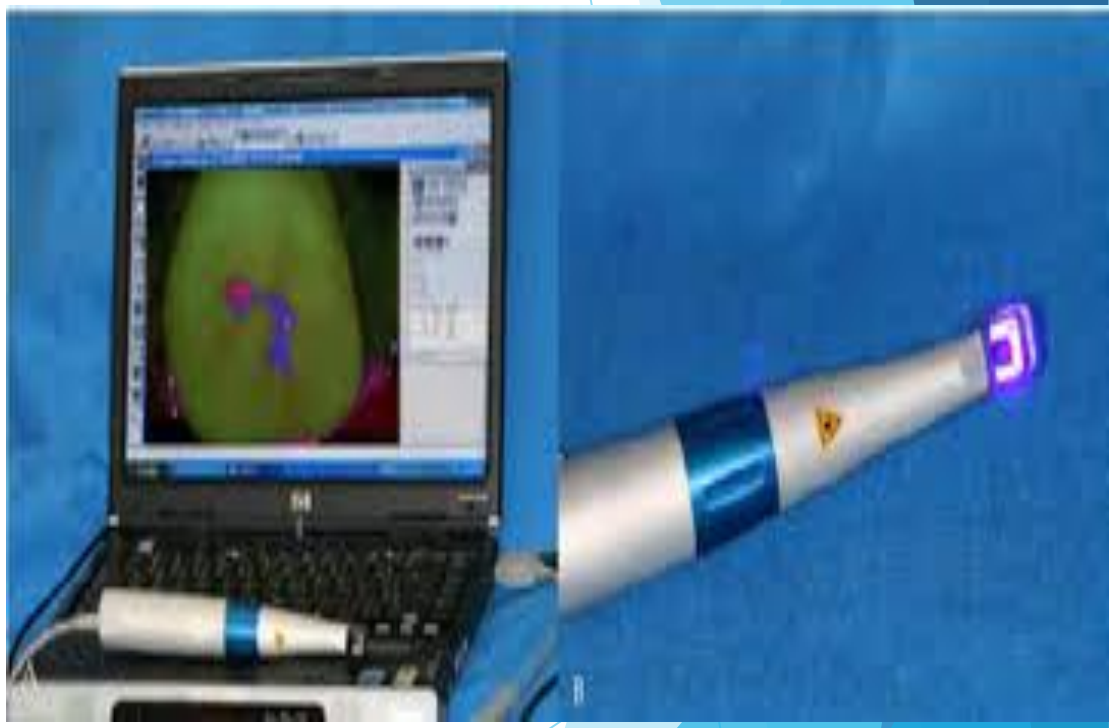

VII -Ultrasound Caries Detector

This is a new ultrasonic proximal caries detector that works by transmitting surface ultrasonic waves. The ultrasound caries detector (UCD) device is based on pulse echo method and has software, hardware and transducer as components. A medical grade silicon wedge is positioned in front of probe to yield surface waves on the tooth surface when the transducer comes in contact with the tooth. This detector records specific profiles of ultrasonic echoes obtained from the enamel surface, dentino-enamel junction and pulpo dentinal junction. Changes in this profile have been described in demineralized lesions, this a substantial difference in the sonic conductivity between sound and demineralized enamel.



- **VIII-Midwest Caries ID** (LED technology) This technology utilizes a handheld device which emits a soft light emitting diode (LED) between 635 nm and 880 nm and analyzes the reflectance and refraction of the emitted light from the tooth surface, which is captured by fiberoptics and is converted to electrical signals for analysis.
- The demineralization leads to a change in the LED from green to red with a simultaneous audible signal, which is directly related to the severity of caries lesions. Advantage is that sensitivity and specificity is higher than that of DIAGNOdent. Disadvantage is that Midwest Caries ID is not able to differentiate enamel lesions from sound surfaces



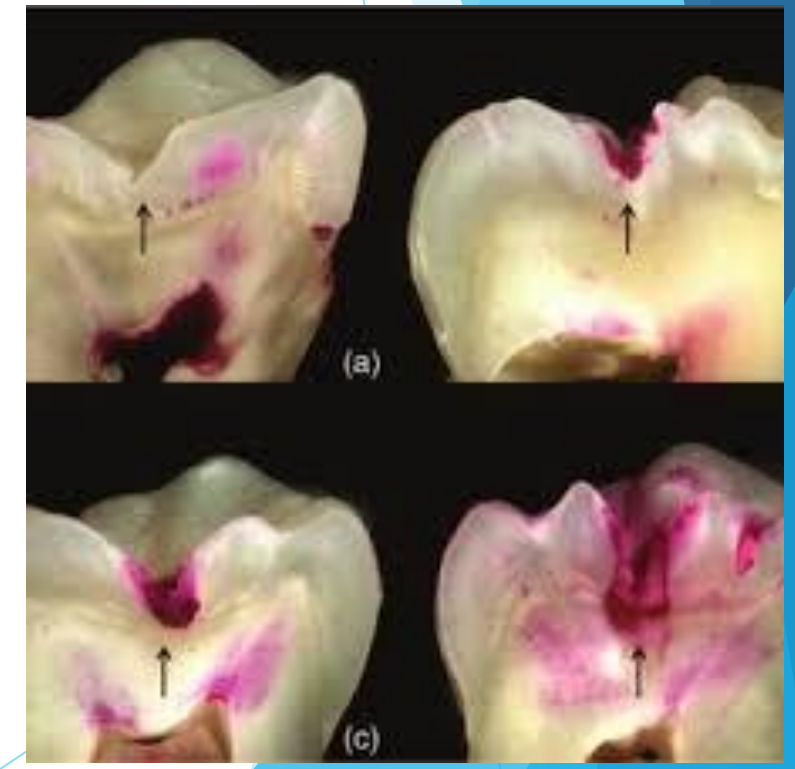

- X-Intraoral Television Camera
  Through intraoral television camera (IOTV) the dentist can educate the patient and at the same time can improve their own diagnostic expertise as they see magnified oral conditions, which are significantly better than direct vision
- Advantages are increased vision and magnification.
- Disadvantage is loss of specificity



Advances in cavity preparation method

I-Chemomechanical Caries Removal

The chemomechanical method is an effective alternative for caries removal because it brings together atraumatic characteristics and bactericide/bacteriostatic action. The method was created so as that an active ingredient would soften the predegraded collagen of the lesion without pain or undesirable effects to adjacent healthy tissues. The chemomechanical method for caries removal was developed to overcome these limitations.

It is not only more comfortable for the patient but also able to better preserve the healthy tissue. GK-101 was the first chemomechanical agent for caries removal.

Advantages of chemomechanical caries removal are safety, elimination of local anesthesia and bur, lower anxiety, conservation of the sound tissue. it is include CARIDEX, Carisolv and Papain Gel

1- Caridex

was developed by CM Habib from a formula made of N-monochloroglycine and amino butyric acid and was called as GK-101E.

Disadvantages of this were expense, additional time consumption and bulky armamentarium



2-carisolv

was a more efficient and effective chemomechanical caries removal system than Caridex. Despite its effectiveness, Carisolv was not a blockbuster mainly because it required extensive training and customized instruments which increased the cost of the solution.



3-PAPAIN GEL

A new type of chemomechanical agent was developed in Brazil in 2003 comprised of papain, chloramines, toluidine blue, salts, thickening vehicle and called as Papain gel





Indications

- Where the preservation of tooth structure is important
- The removal of root/cervical caries
- The management of coronal caries with cavitation
- The removal of caries at the margins of crowns and bridge abutments
- The completion of tunnel preparations
- Where local anesthesia is contraindicated
- The care of caries in dentally anxious patients, notably needle phobic
- Management of primary carious lesions in deciduous teeth
- Atraumatic restorative technique procedures
- Caries management in patients with special needs

2-air Abrasion (Microabrasion And Kinetic Cavity Preparation

Air abrasion for restoration preparation removes tooth structure using a stream of aluminium oxide particles generated from compressed air or bottled carbon dioxide or nitrogen gas.

Like any air stream air abrasion can cause **subcutaneous emphysema.**

Advantages of the air abrasion:

- It is painless
- Local anesthesia is rarely needed
- It works quickly and work quietly without the whine of the all too familiar dental headpiece
- There is no vibration or pressure to cause micro fractures that weaken tooth
- There is no production of heat to damage the dental pulp
- Lesser sound tooth structure is removed.

Clinical Uses

1. Class I, II, III, IV and V cavity preparations
2. Sealants and preventive restorations
3. Repair of composite and porcelain
4. Removal of composite and amalgam





3-Laser

One of the main uses of laser in dentistry is the removal of dental caries and preparation of restorative cavities. Similarly, using laser in preparation of restorative cavities is accompanied with low risk of damage to adjacent teeth. It also makes the tooth structure more resistant to acid and decay. As laser acts with a different mechanism to prepare dental cavities, the morphology of laser prepared surfaces is different from that of those prepared by conventional method. laser prepared permanent and primary tooth dentin reveals non-uniform scaly rough surfaces and opened tubules without formation of smear layer and any evidence of thermal damages.

4-Smart prep bur

Carbide dental burs are designed to efficiently remove non-decalcified enamel and dentin but do not facilitate the differentiation between carious and normal dentin during cavity preparation.

Polymer burs consist of cutting elements that cut softer dentin efficiently but are unable to cut normal dentin. The cutting blades of Polymer burs will deflect and deform upon encountering normal or partially decalcified dentin, thereby enabling the reduction of cutting efficiency and alteration of the operator's tactile sensation.

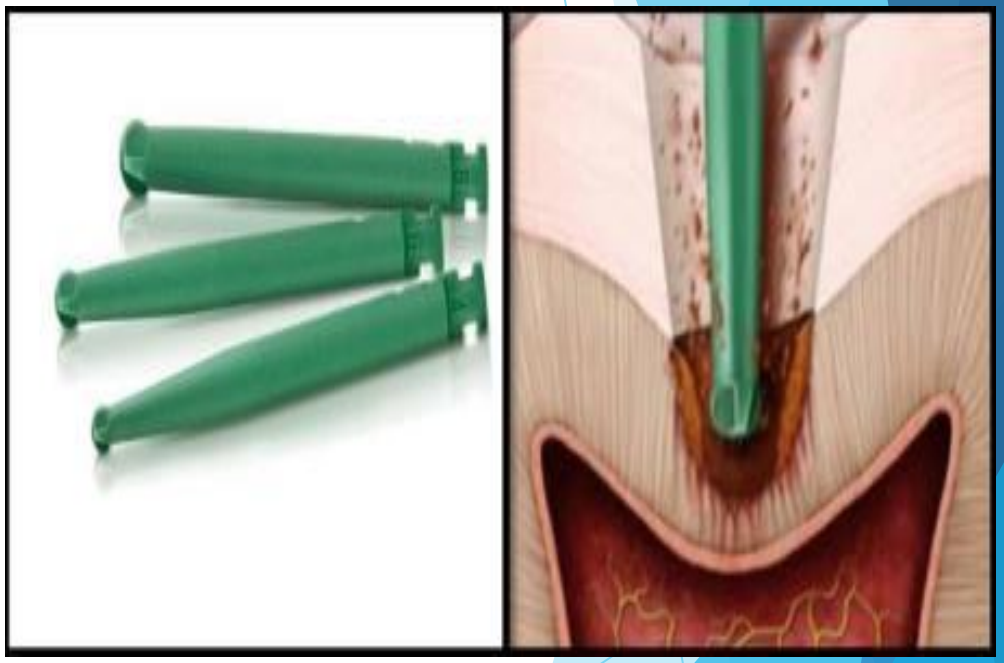

Advances in restorative materials in Pediatric Dentistry

Bioactive Composite Resins

bioactive" is a broad term that typically describes a type of dental material that interacts with living tissue.

- These were a **compound of** resin and glass ionomer that contain surface pre-reacted glass as a filler within the resin. This gives it properties like cariostatic qualities and an anti-plaque effect to better prevent further damage.
- When applied to teeth, this composite resin forms a film when it comes into contact with saliva that repels plaque and neutralizes acids which greatly increases its resilience.

indications

- for class I and class II caries in primary molars.
- According to the manufacturer, this material is also indicated in cases where the isolation is compromised or impossible and in patients with high caries index due to its fluoride-releasing properties.

Resin-Modified Glass Ionomer

- Another new restorative material in pediatric dentistry, this form of composite resin is unique in that it contains no Bisphenol.
- This type of resin contains a **rubberized** component that against fractures and contains properties that release fluoride calcium and phosphate when it comes into contact with saliva.
- By creating this hybrid between the rubberized component and a light-curing resin.
- RMGIs are self-adhesive, not requiring removal of the smear layer, and their low modulus and ionomeric reaction can buffer the effects of polymerization shrinkage of composites.
- RMGIs bond to tooth structures via a combination of micromechanical and chemical bonding mechanisms.

Bulk Fill Composites

- are light-cure resin that is applied in layers or increments of, typically, 4-5mm of depth. This option has existed for a few years now, but the adoption of bulk-fill composites is finally catching up with the typical 2mm application of restorative resins.
- The primary benefit of bulk-fill composites is that the application and polymerization of the resin are much quicker and uses a much simpler technique that is beneficial for children with sensitive teeth.
- It used when the resin needs to fill out all the empty space within a tooth because its greater depth.

Advances in surgical procedures

A variety of new instruments and techniques are revolutionizing the fields of oral and maxillofacial surgery and dentistry. This including the **powered periotome**, **piezo surgery,** the **Physics Forceps** and laser **therapy**,

1-Physics forceps are newer instruments. The introduction of physics forceps can be time saving, less invasive and reduce post-extraction complications.



2-powered periotome

are designed to easily engage and cut periodontal ligaments. Sharp and precise, periotomes are used cut away periodontal ligament from the tooth for atraumatic extraction.



3-Dental piezo surgery

is used in many different situations. It can be used for dental extractions, sinus augmentation surgery, periodontal surgery and endodontic surgery. It is an ultrasonic surgical system that prevents thermal damage and preserves soft tissue structures. The Piezo surgery device is used when we need **a high level of precision when performing surgery, when there is an increased risk of soft tissue and nerve damage, or to preserve bone during tooth extractions,** for example when the plan is to replace the failing and unrestorable **tooth** with a dental implant



4-Laser therapy

represents a novel and exciting complementary treatment modality for oral health professionals. With applications ranging from soft tissue surgery to caries preparation,

the potential advantages include faster healing after trauma and surgery, and reduced pain following procedures., a reduced need for anesthetic during tooth preparation, and the potential for improved healing in frenotomies, frenectomies and minor soft tissue surgeries represent valid reasons to consider lasers as a viable approach to pediatric treatment.

When a clinician uses the laser for surgical or pulpal procedure, **children become more cooperative** and thus enhances treatment outcome.

It is used for caries prevention, early diagnosis, cavity restoration, management of traumatized teeth, and minor oral surgical procedure in child patients

miscellaneous Advancements in Pediatric Dentistry.

Fluoride varnish

Sodium fluoride varnishes are being used for caries arrest in children, and using varnish is more effective than older technologies. Varnishes are safe for at-risk infants and children and provide an easy-to-use fluoride vehicle for young children**.**

Xylitol

Xylitol is a naturally occurring alcohol sugar that is not metabolized by *Streptococcus mutans* (mutans streptococci [MS]). Xylitol inhibits the attachment of the biofilm and interferes with intracellular metabolism. Xylitol is available in many forms: gum, lozenges, mints, sprays, rinses, pastes, and a baking substitute for sugar or other sweeteners.

Silver diamine fluoride

The antimicrobial action of silver compounds is proportional to the bioactive silver ion released and the availability of the ion to interact with bacterial or fungal cell membranes.

The specific interest in SDF centers around its presumed attributes : control of pain and infection, ease and simplicity of use (paint on), affordability of material, minimal requirement for personnel time and training, and noninvasiveness.

The side effects of SDF include teeth staining and unpleasant poor taste.

ASDF solution is commonly used to arrest caries in primary teeth, especially of those children who are young and less cooperative. In these cases,

Calcium Phosphate Fluoride

There are developing, interesting, and novel remineralizing agents, such as casein phosphopeptide–amorphous calcium phosphate, formulated as professionally applied pastes and toothpastes. These remineralizing agents may complement and increase the established clinical effectiveness of topical fluorides.

Advanced Radiographic Techniques

• ***Magnetic resonance microimaging (MRMI)*** Carious regions give an intense image that is readily distinguishable from other soft tissues

– Advantage is that this technique is noninvasive and allows a specimen to be re-imaged after further exposure to clinically relevant environment.

– Major drawbacks include cost and clinical testing.

• ***Photo stimulable phosphor radiography*** –A latent image is produced by exposing the storage phosphor screen with X-rays.

– Advantages are that it can be used with existing X-ray sources, wider exposure range and transfer of images is possible.

– Disadvantages are the high cost and chances of cross infection.

• ***Tuned aperture computed tomography (TACT)*** is a new imaging device which uses digital radiographic images, and its software correlates these images into layers so that sliced sections can be viewed. – A series of 8 radiographs can be assimilated into one TACT image. It is effective in evaluating primary stimulated recurrent caries and simulated osseous defects and can localize a lesion accurately with minimal radiation.

Advances in endodintics

1-Niti Files

- Before the introduction of Nickel Titanium (NiTi) in endodonics, simple endo files were made of carbon steel or a stain less steel. Stainless steel instrument has inherent stiffness which increases as the size of the instrument increases. This led to a lot of transportation of the canal, zip perforations to occur.
- NiTi instruments on the other hand have shape memory and super elasticity which made them more flexible thereby respecting the curved and complexing root canal anatomy.
- NiTi instruments have undergone revolutionary changes in terms of their construction to their physical characteristics. The objective was to preserves as much dentin as possible after shaping the canal and negotiated thin curved canals without the separation and latest being the use of single file system for shaping the canal. They can either be rotary or reciprocating based on their motion.

advances in local anesthesia
1-pharmacological Local Pain Management

Chemically induced local anesthesia is achieved by creating a depot of an anesthetic agent in the tissues by a diffuse or vascular-diffuse mechanism.

The diffuse methods in it include topical, infiltration and conduction anesthesia, while **vascular-diffuse mechanism** is observed in intraosseous, intrafilamentary anesthesia.

1. Diffuse local anesthesia

1- 1 Topical anesthesia.

a- Lidocaine patches

The lidocaine patch is a transoral delivery system of lidocaine via a mucoadhesive base attached to the oral mucosa. The anesthetic agent is absorbed by the mucosa and the reported onset of anesthetic effect is within 2 minutes of application and may last up to 30 minutes after removal.

Indications for use include super facial mucosal and gingival procedures, and topical analgesia before injectable local anesthesia,

disadvantages include its high cost and poor adhesion to the oral mucosa

b. EMLA – cream.

Mixtures of anesthetic agents aimed for topical anesthesia are called eutectic mixtures for local an-esthesia (EMLA). Such formulations are considered to have lower melting points, which promotes easier absorption in the oral mucosa.

Indications for use include procedures on the oral soft tissues causing minor pain. Following the introduction of EMLA cream, a 1:1 mixture of 2.5% prilocaine and 2.5%lidocaine, as topical anesthetic in dermatology. Further studies are needed to determine the appropriate dose and duration of exposure in children to prevent the risk of overdosing and adverse effect.

c. Intranasal spray

This is a novel technique for achieving local anesthesia of maxillary teeth by infiltration of an anesthetic solution through the nostrils by a metered device.

It is hypothesized that the anesthetic solution diffuses through the nasal mucous walls and affects the structures, involved in innervation of maxillary teeth. Besides its anesthetic properties, it also reduces the risk of bleeding due to the shrinkage of regional blood vessels without causing significant cardiovascular disturbance in healthy patients.

The method allows to perform conservative dental manipulations requiring pulpal anesthesia of maxillary anterior teeth, canines and premolars in adults and children weighing more than40 kg.

Infiltration anesthesia

a. Vibrotactile devices reduce the pain of needle injection by applying pressure, vibration, micro oscillations, or a combination of them such as Dental Vibe. The applied physical stimuli modify or interfere with pain signals by closing the neural gate of cerebral cortex, aimed to decrease the pain perception due to distraction.



b. Modification in techniques –

anterior middle superior alveolar (AMSA) and palatal approach to anterior superior alveolar (P-ASA) nerve blocks gingiva, These are two recently defined techniques for maxillary teeth analgesia without occurrence extraoral soft tissue anesthesia.

The AMSA nerve block achieves pulpal anesthesia of the maxillary incisors, canines and premolars on the side of the injection,

while the P-ASA technique anesthetizes six frontal teeth, from canine to canine, as well as the palatal and labial mucoperiosteum and bone covering these teeth.





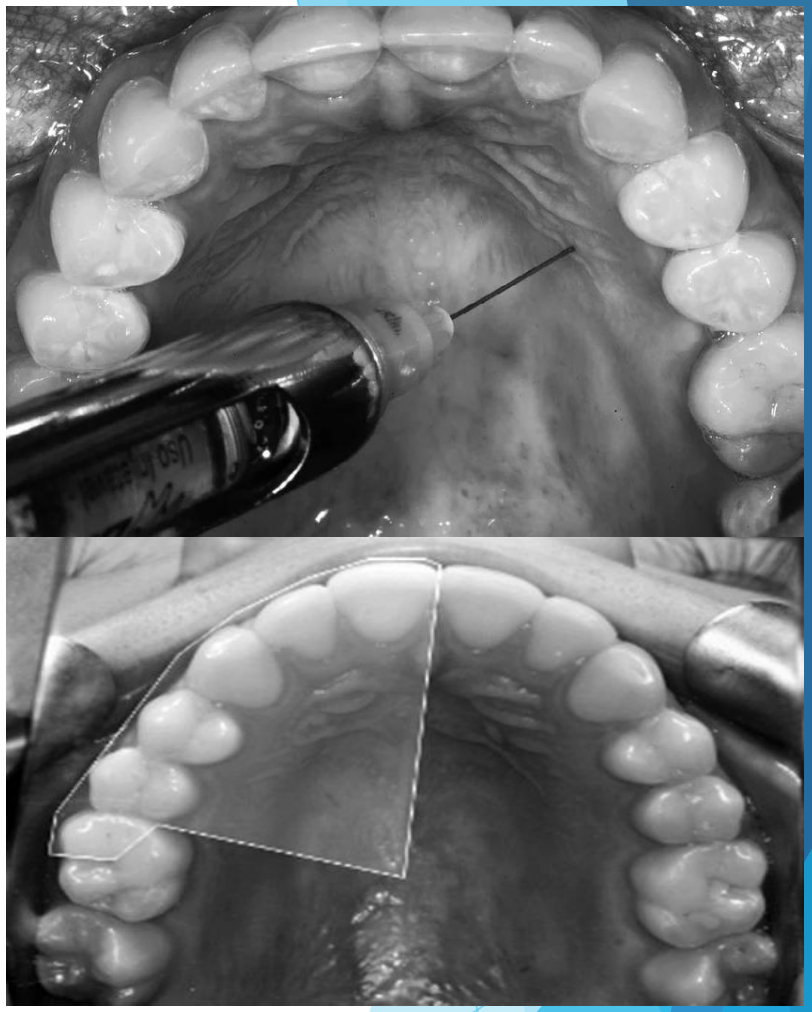

2. Vascular-diffuse local anesthesia

a-Computer-controlled intraligamentary anesthesia

- The computer-controlled local anesthetic delivery (CCLAD) systems present a technology for controlling the volume and flow rate of anesthetic solution through the needle.
- **The STA (single tooth anesthesia) system** is an intraligamentary CCLAD system with an additional function for dynamic pressure sensing, providing real time feedback to the practitioner.
- **The advantage** is the rapid onset of profound pulpal anesthetic effect, with mild to moderate injection pain. The prolonged duration of the anesthetic administration could be considered drawback for pediatric patients.
- Safety precautions should be considered when intraligamentary anesthesia is applied on primary teeth close to developing permanent teeth, as some researchers report risk of enamel hypoplasia occurrence.



b-Computer-assisted intraosseous anesthesia (CAIO)

Intraosseous anesthesia is considered to be a successful alternative to conventional anesthetic infiltration, as the anesthetic agent injected directly into the cancellous bone adjacent to the tooth required to be anesthetized.

Computer-controlled intraosseous anesthesia delivered with **constant velocity and pressure of the anesthetic solution**, is found to reduce the injection pain and the time of onset of the anesthetic effect.

Two main techniques of CAIO application are **transseptal and osteocentral** infiltration.

Consideration should be given to the location permanent when applying the method in primary dentition.



2. Non-pharmacological Local Pain Management

Laser analgesia

is a non-invasive, non-thermogenic biomodulation of the dental pulp reactivity. Laser pulses alter the behavior of a neuronal cell membrane causing a temporary disruption of the NaK pump. This leads to loss of impulse conduction, and thus an analgesic effect is achieved.

The analgesic effect, together with the lack of contact and vibration in the manipulations, are prerequisites for accepting laser treatment as effective in reducing the anxiety associated with dental treatment in children and adolescents.

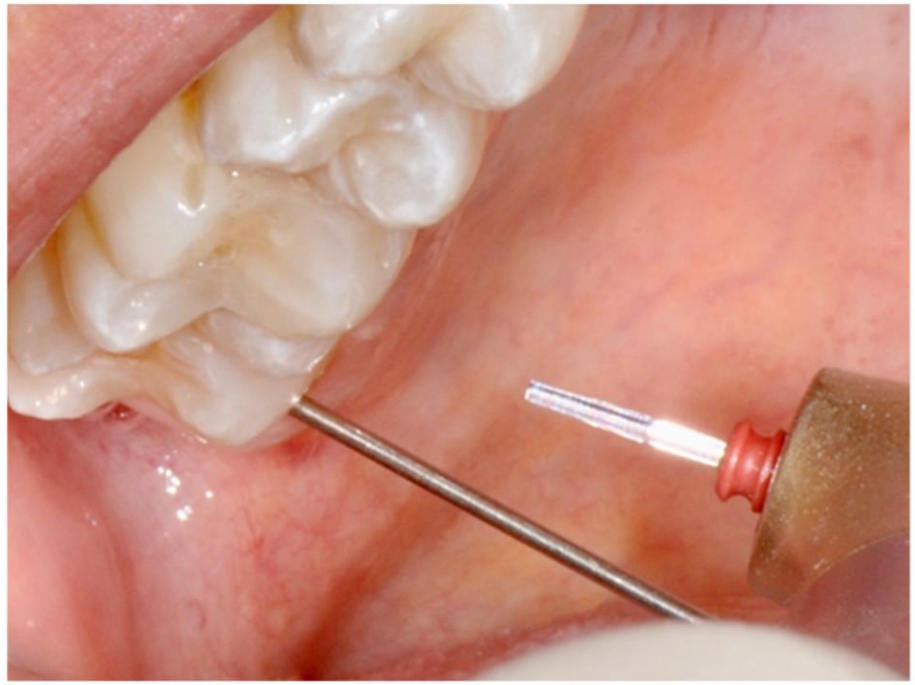

2-“Virtual anesthesia”

The most widely used behavioral techniques for relieving dental anxiety are verbal. The current progress in the field of virtual reality devices presents more engaging forms of distraction. Virtual reality may also have analgesic potential, leading to new term creation - “virtual anesthesia”.





3. Reversal Of Local Anesthesia

The prolonged duration of soft-tissue anesthesia is often an undesirable effect of infiltrative local anesthesia in dental patients. Self-induced soft tissue trauma, a sensation of altered face appearance, impaired speech and eating are some of the post-operative side effects of local analgesia.



Phentolamine mesylate (OraVerse) is a short-acting alpha-adrenergic antagonist, leading to an increased clearance of local anesthetic solution from the injection site, reducing the duration of action.

Since it is an antagonist to the vasoconstrictor and not to the anesthetic agent compound, it is mainly recommended for use in non-surgical treatment. and its associated functional deficits in adults and children after 6 years of age.