ALVEOLAR PROCESS (BONE)

The alveolar process is that part of the maxilla and mandible (the basal bone) in which the roots of the functioning teeth are located.

The alveolar processes are tooth dependant structures. ***They develop along with the formation and eruption of the teeth and are resorbed after the teeth are lost***. Alveolar processes **do not develop** at all in children with total anodontia. There is no clear cut between the alveolar process and the bone of the jaw. The alveolar bone is adapted to mechanical stress. It changes continuously during ①growth ②eruption ③movements ④wear and ⑤loss of teeth.

The morphology of the alveolar processes is depending on the :

1. Size of the tooth 2. Shape of the tooth 3. Position of the tooth.

The alveolar bone between the roots of adjacent teeth is known as the interdental septum, while the alveolar bone between the roots of multi rooted teeth is known as the interradicular septum (Fig.1).

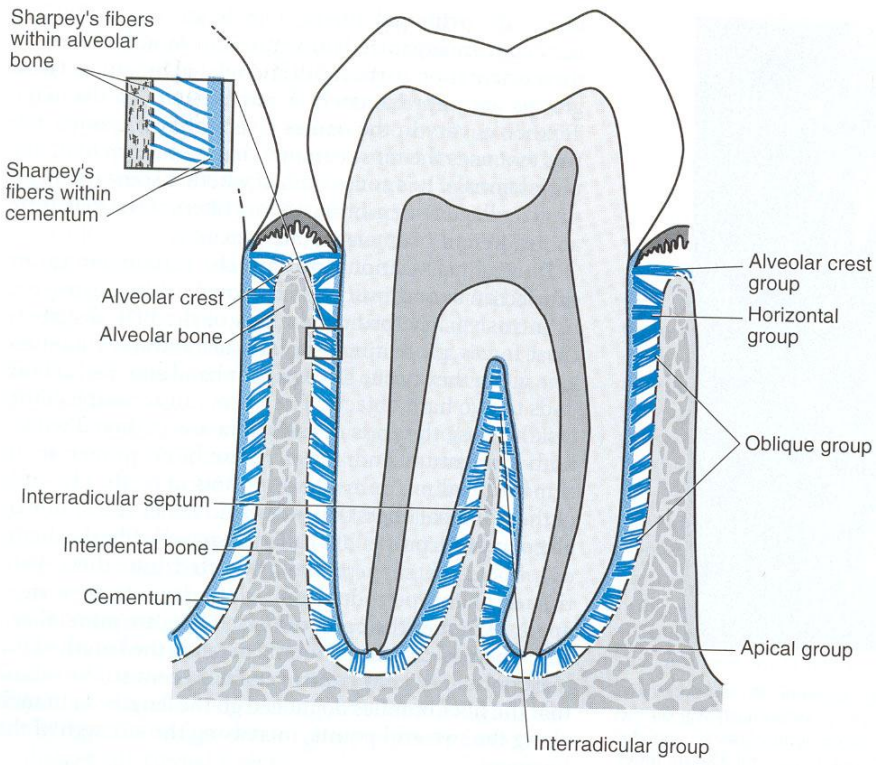

Fig.(1): Showing different parts of alveolar bone and their relation to the other parts of periodontium.

DEVELOPMENT:

The development of alveolar bone is occurring alongside with the development of the root of the tooth. After eruption of teeth the alveolar bone gradually takes the shape of adult form

STRUCTURE:

It is composed of two parts (Figs. 1 ,2 and 3):-

1) Alveolar bone proper.
2) Supporting bone which consists of cortical plates (inner and outer) and inner spongy or cancellous bone ,which has bone marrow filled spaces .

ALVEOLAR BONE PROPER(***CRIBRI FORM PLATE OR LAMINA DURA***):-

It is a thin lamella of bone that surrounds the root of the tooth and gives attachment to the principal fibers of the periodontal ligament.
It is perforated by numerous foramina (Volkmann's canals) that carry branch of the alveolar nerve and blood vessels into the periodontal ligament and that are why it is called **cribriform plates.** The **term lamina dura** is given to this layer of bone because it appears radiopaque in x-ray.

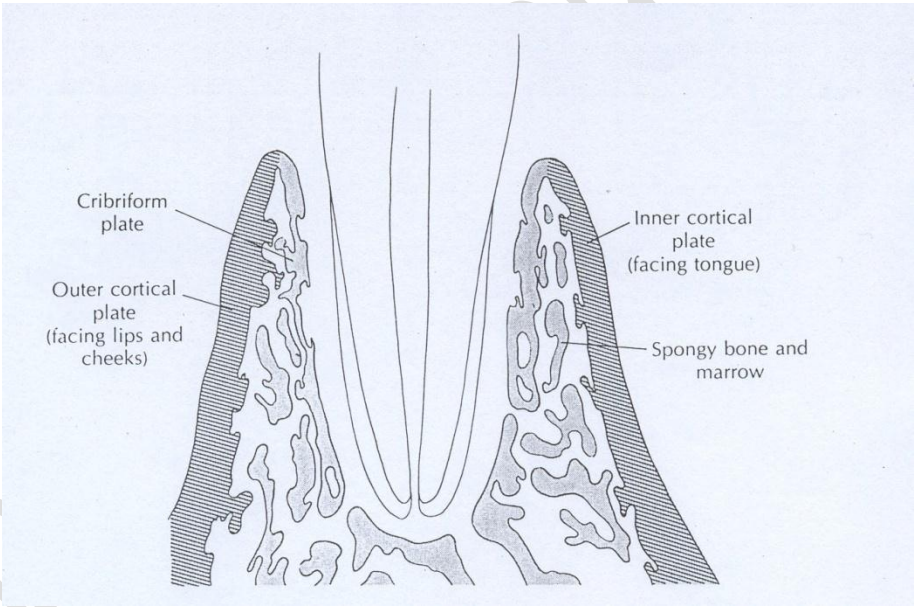

Fig. (2): Diagram of a tooth root in its alveolar bone socket.

HISTOLOGICAL STRUCTURE:-

The alveolar bone proper is consisting partly of compact bone with Haversian system and partly by **bundled** bones which covers the superficial part of the bone.The bundle bone is the site where the principal fibers of PDL are attached.
The Bundle bone contains more calcium salts than other types of bone tissue so it appears dense in the x-ray. Bundle bone is found in the sockets where recent bone formation has occurred as a result of tooth movement.
Main features of bundles bone:

1) contain the Sharpey`s fibers of PDL.
2) Contains fewer fibers than does compact bone.
3) Contains more calcium salts per unit area than other types of bone tissue so appears radio-opaque in the X-ray film.

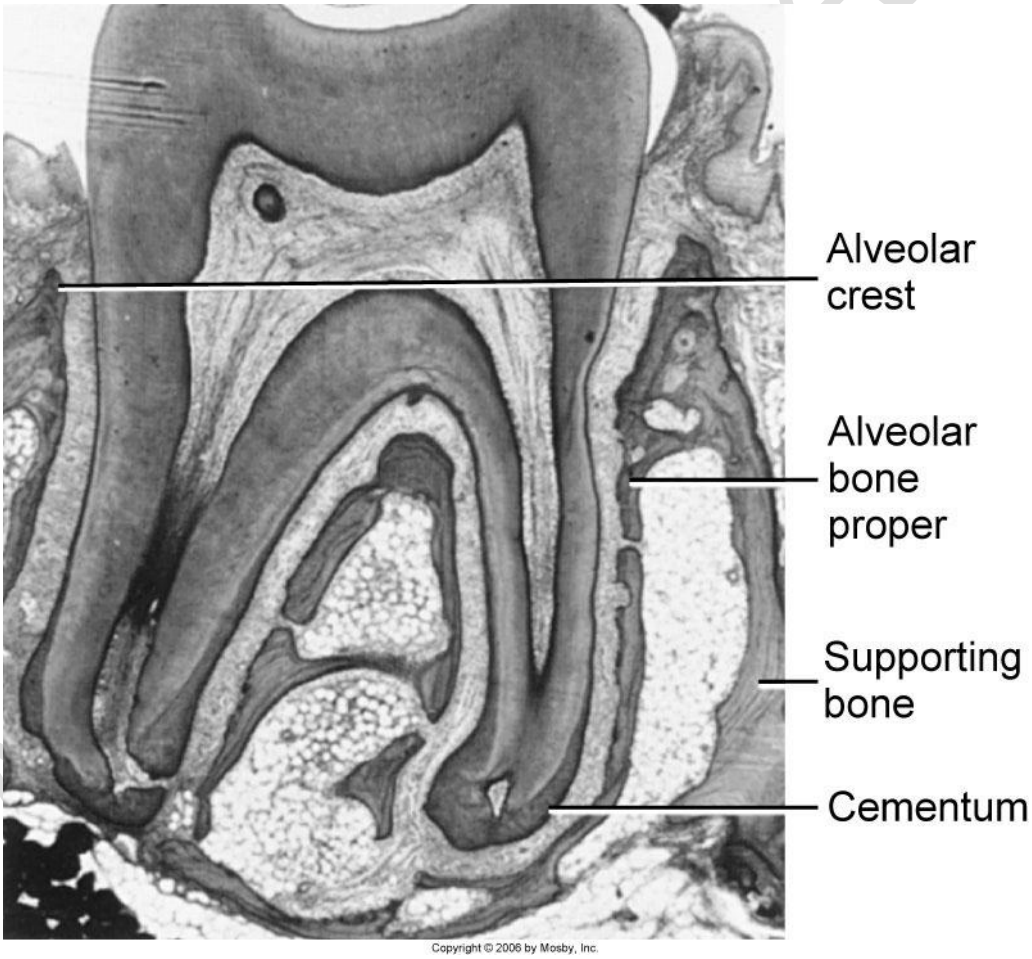

Fig. (4): Showing the different parts of the alveolar bone and its relationship to cementum and PDL

THE cribriform plate of alveolar bone proper has 0.1 to 0.4mm thickness with a character of fine-hold sieve and is attached to trabecullae of the spongy (cancellous bone). The foraminae in this plate are numerous in the coronal and apical regions of the alveoli and connect the PDL to bone marrow spaces. These opening correspond to

Volkmann's canals and their concentration increases from alveolus to alveolus in a posterior direction. Blood vessels, lymph vessels, and nerves fibers pass through them. The increase in the number of concentration number of these foraminae in a posterior direction is due to the following reason:

In the sudden but short acting pressures which arise during mastication the blood is displaced into the surrounding alveolar bone through the anastomoses between the periodontal vessels and those of the Haversian system and cancellous bone of the alveolar bone via the foraminae in the cribriform plate of alveolar bone proper. These anatomizing vessels probably provide escape routes for blood when the vessels of PDL are compressed as a result of the pressure exerted during mastication.

THE SUPPORTING BONE:-

It consists of 2 portions:

a. Cortical plates: made up of compact bone and form the outer(labial and buccal and inner (or lingual)plates of the alveolar process. The cortical plates: they are continuous with the compact layer of the maxillary and mandibular body. They are thickest in the premolar and molars. In the region of anterior teeth of both jaws the supporting bone usually is very thin with no spongy bone and the cortical plate is fused with the alveolar bone proper. The thickness of cortical plate is between 1.3-5 mm.

b. Spongy (cancellous): This bone is filling the area between the cortical plates and alveolar bone proper. The degree of its development is related to the force of mastication, thus it is nearly absent in the anterior teeth. The cancellous bone is built of many trabecullae, between which a spaces filled with bone marrow.

The trabecullae of the cancellous bone undergo continual remodeling(resorption and deposition).

In addition to that the cancellous bone is very sensitive to variation in functional force. Increase functional force lead to formation of new bone, while decrease in function leads to decrease in volume of bone (**osteoporosis**). This can be observed in the cancellous bone which has lost its antagonist (fig. 5). When the force of mastication is excessive the cancellous bone is very dense and the trabecullae being numerous and thick.

Dr.Akram Yousif Yasear

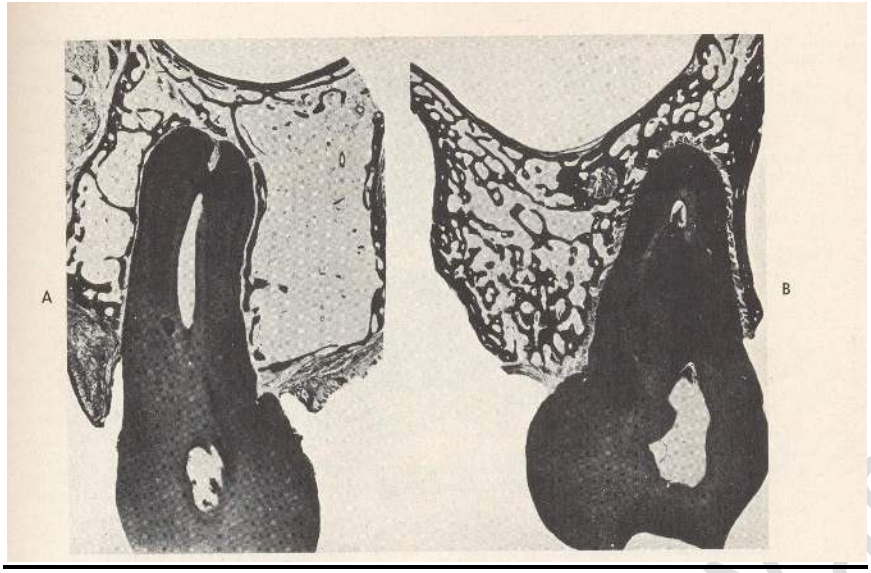

Fig. (5): Osteoporosis of the for the cancellous bone of the tooth(on the left)which has lost its antagonist .

The bone:

General structure of the bone:
Periosteum and endosteum:
The outside surface the bone is covered by connective tissue (C.T) membrane called periosteum. A thin C.T membrane called endosteum covers the inner surface of compact bone and trabecullae in the bone marrow.
Bone cells:

1. **Osteoprogenitor (osteogenic) Cells:**
These cells are considered as undifferentiated cells derived from the mesenchymal cells. These cells are present on the deepest layer of periosteum and in the endosteum .They give rise to osteoblasts.

2. Osteoblasts: They are derived from Osteoprogenitor cells and appear on the surface of the bone. Bone is produced by the activity of osteoblasts. They are responsible for the synthesis of organic components of bone matrix, and calcification of the matrix they produced.
3. Osteocytes: As osteoblasts become surrounded by their own secretory products they are converted into osteocytes. Osteocytes present inside the bone. These cells are responsible for maintenance of bone matrix.

4. OSTEOCLAST: (clast=break)
It is a multinucleated cell originated from circulating monocytes specialized for resorption of bone.

Dr.Akram Yousif Yasear

The surface facing the bone is irregular showing the presence of microvilli called ruffled border. Osteoclast is found in bony depression in bone called Howship's Lacuna.
The life span of the osteoclast is 6 weeks. Time of its differentiation is 1-2 weeks (Fig.6).

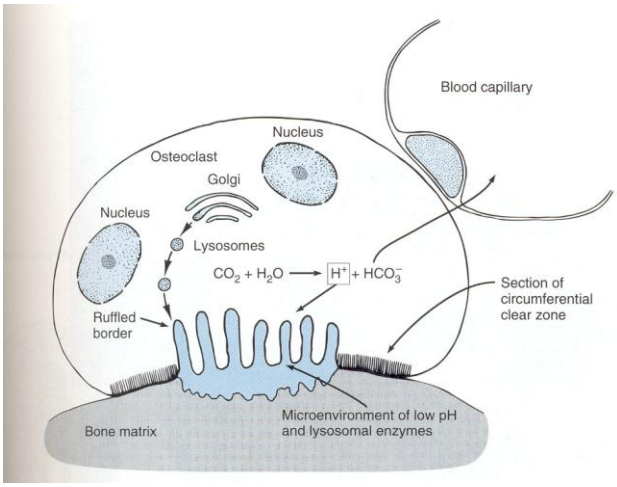

Fig. (6) : Osteoclast and bone resorption.

Bone resorption: is the removal of the both mineral material and the organic matrix of bone. A key event in bone resorption is binding of osteoclasts to the mineralized matrix of bone surface. The process of resorption is occurring in three successive stages:

a) **DECALCIFICATION:**

This is achieved at the ruffled border of osteoclast by secretion of organic acid (citric and lactic acids) which increase the solubility of hydroxyapatite.

b) **DEGRADATION OF ORGANIC MATTER:**

In this process there is fragmentation of the collagen fibers by collagenase and proteolytic enzymes outside the osteoclast.

(C) Transport of the soluble products to the extracellular space or the blood vascular system.

Bone resorption always followed by bone remodeling.

The bone remodeling is important because:-

1) Allow the tooth to be moved orthodontically. The remodeling enables the alveolar bone to accommodate to the new conditions. Most orthodontic movements are tipping movements.
2) The remodeling as a response to normal tooth minor movement as normal loading on the jaw.
3) Throughout the body bone remodeling takes place to adjust constantly to the circulating levels of calcium and phosphate ions.
4) During active eruption, (the full eruption), teeth may undergo some movements in a horizontal direction (mesial drift). Where a slight movement of all teeth toward the front of oral cavity. This movement occurs at slow rate. The first bone to be broken down is

Dr. Akram Yousif Yasear

the bundle bone of the lamina dura. The break down may result in the detachment of the PDL fibers which insert in the bone.

5) Jaw growth.
6) Replacement of deciduous teeth.

INTERNAL RECONSTTRUCTION OF BONE:-

Bone formation and bone resorption are processes that occur in bones throughout the life of the individual. They occur in response to certain stimuli: examples:-

1) Tension (pull) on P.D.L fibers attached to the bone causing bone formation.
2) Pressure on the P.D.L and on the bone inducing resorption.

The stimuli for bone formation and resorption are coming from:

1) Tension on PDL fibers attached to the bone.
2) Pressure on PDL and on the bone.
3) Presence of osteoclastic activating factor (OAF) and cyclic AMP enzyme which increase the osteoclast activity. Cyclic AMP level usually increases on the pressure side.

Note:

a) Bone is resorbed on the pressure said and builds up on the side of tension.
b) Tension generally acts as a stimulus to the production of new bone. Thus the entire alveolus is allowed to shift with the bone.

Why there is a success of orthodontic treatment?

The success of orthodontic treatment is depending on three factors:-

1) The bone is resorbed more easily than the cement.
2) The area of lamina dura which has moved toward the tooth is resorbed because it is under pressure.
3) The area of the lamina dura away from which the tooth is moved is built up because it is under tension.

Dr.Akram Yousif Yasear

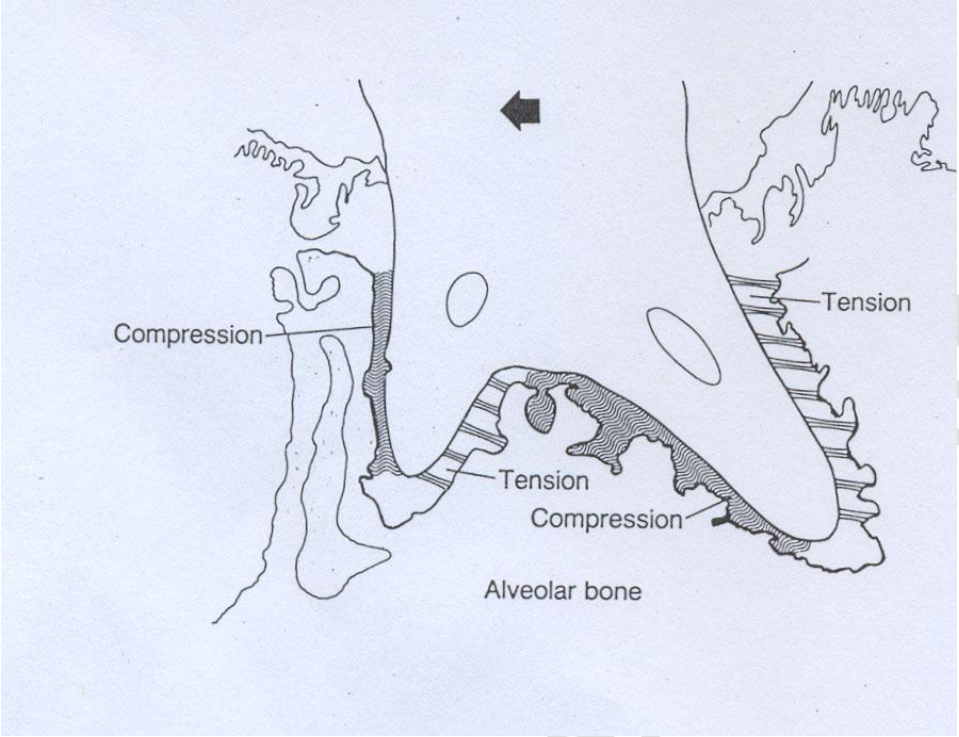

Fig. (9): Tooth movement to the left, with zones of compression along the advancing root surface.

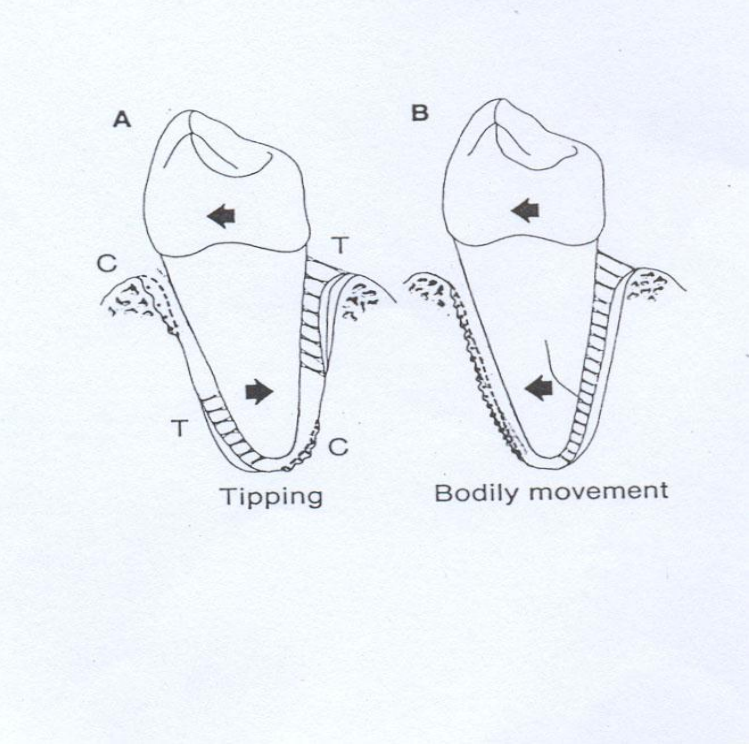

Fig. (10) : A: Tipping of the a tooth crown to the left causes the root to compress(c) the ligament at upper left and lower right. Tension (T) occurs at upper right and lower left. (B) Bodily movement.

1) **Age change in bone**:-

1- Decrease in water content lead to brittleness.

2- Thinning of trabecullae of spongy bone and widening of marrow space.

3- Red bone marrow transformed into yellow bone marrow except in 3 places, (maxillary, tuberosity, and, angle of mandible, condylar process).

4- Inclination mesially of tooth due proximal attrition of tooth result in distal slopping of alveolar crest. This is pronounced in premolar and molars.

Dr.Akram Yousif Yasear