Human Anatomy

Dr_Mustafa Fadhil

Lec.

14

Maxillary artery

The maxillary artery is the larger of the two terminal branches of the external carotid artery; arises posterior to the neck of the mandible. Then it runs forward medial to the neck of the mandible and enters the pterygopalatine fossa of the skull. It is divided into three parts based on its relation to the lateral pterygoid muscle:

- **(Retro)mandibular**: arteries enter foramina and supply dura, mandibular teeth and gums, ear, and chin.
- **Pterygoid**: branches supply muscles of mastication and buccinator.
- **Pterygopalatine**: branches enter foramina and supply maxillary teeth and gums, orbital floor, nose, paranasal sinuses, palate, auditory tube, and superior pharynx.

The three parts of the maxillary artery and their branches are illustrated in **Figure 1**; their courses and distributions are listed in **Table 1**.

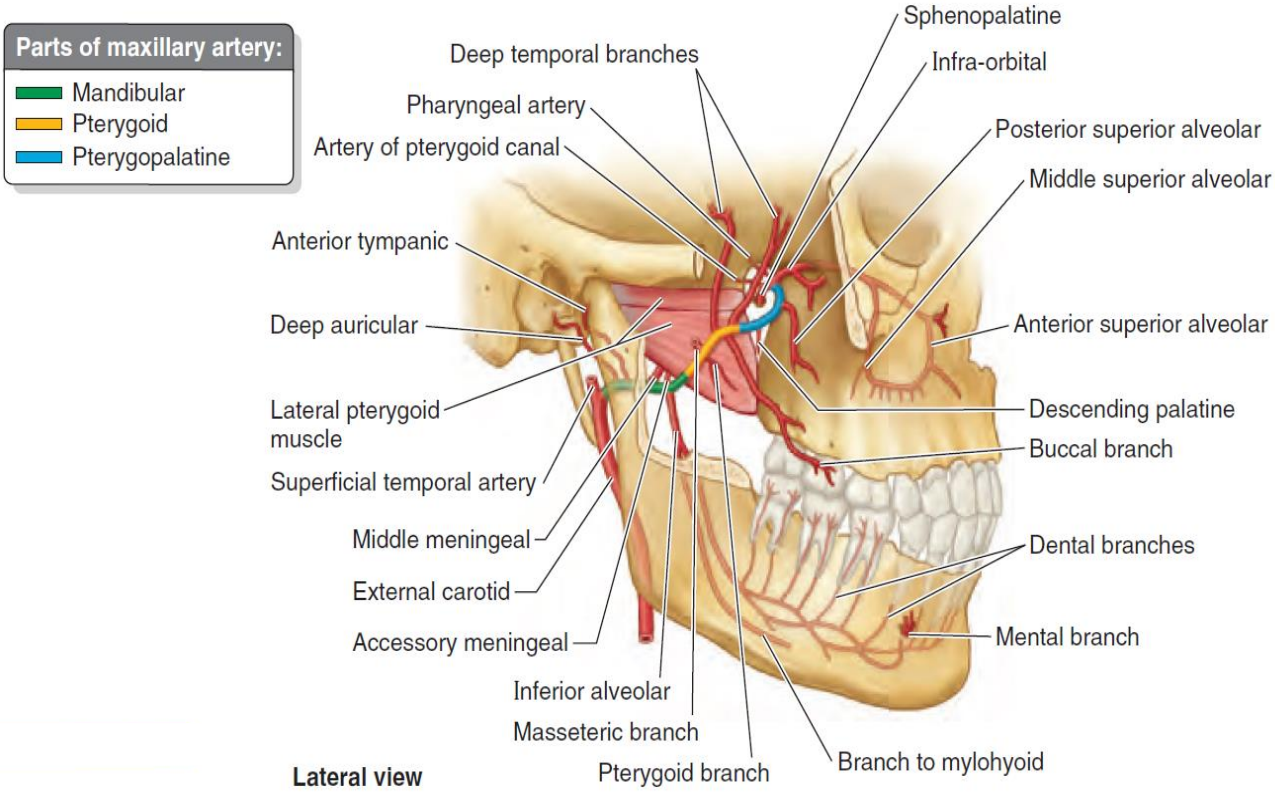

FIGURE 1: Parts and branches of maxillary artery.

TABLE 1: Parts and branches of maxillary artery.

Part	Course	Branches	Distribution
First (mandibular)	Proximal (posterior) to lateral pterygoid muscle; runs horizontally, deep (medial) to neck of condylar process of mandible and lateral to stylomandibular ligament	Deep auricular artery	Supplies external acoustic meatus, external tympanic membrane, and temporomandibular joint
		Anterior tympanic artery	Supplies internal aspect of tympanic membrane
		Middle meningeal artery	Enters cranial cavity via foramen spinosum to supply periosteum, bone, red bone marrow, dura mater of lateral wall and calvaria of neurocranium, trigeminal ganglion, facial nerve and geniculate ganglion, tympanic cavity, and tensor tympani muscle
		Accessory meningeal artery	Enters cranial cavity via foramen ovale; its distribution is mainly extracranial to muscles of infra-temporal fossa, sphenoid bone, mandibular nerve, and otic ganglion
		Inferior alveolar artery	Descends to enter mandibular canal of mandible via mandibular foramen; supplies mandible, mandibular teeth, chin, mylohyoid muscle
Second (pterygoid)	Adjacent (superficial or deep) to lateral pterygoid muscle; ascends obliquely anterosuperiorly, medial to temporalis muscle	Masseteric artery	Traverses mandibular notch, supplying temporomandibular joint and masseter muscle
		Deep temporal arteries	Anterior and posterior arteries ascend between temporalis muscle and bone of temporal fossa, supplying mainly muscle
		Pterygoid branches	Irregular in number and origin; supply pterygoid muscle
		Buccal artery	Runs antero-inferiorly with buccal nerve to supply buccal fat-pad, buccinator, and buccal oral mucosa
Third (pterygoid-palatine)	Distal (anteromedial) to lateral pterygoid muscle; passes between heads of lateral pterygoid and through pterygomaxillary fissure into pterygopalatine fossa	Posterior superior alveolar artery	Descends on maxilla's infratemporal surface with branches traversing alveolar canals to supply maxillary molar and premolar teeth, adjacent gingiva, and mucous membrane of maxillary sinus
		Infra-orbital artery	Traverses inferior orbital fissure, infra-orbital groove, canal, and foramen; supplies inferior oblique and rectus muscles, lacrimal sac, maxillary canines and incisors teeth, mucous membrane of maxillary sinus, and skin of infra-orbital region of face
		Artery of pterygoid canal	Passes posteriorly through pterygoid canal; supplies mucosa of upper pharynx, pharyngotympanic tube, and tympanic cavity
		Pharyngeal branch	Passes through palatovaginal canal to supply mucosa of nasal roof, nasopharynx, sphenoidal air sinus, and pharyngotympanic tube
		Descending palatine artery	Descends through palatine canal, dividing into greater and lesser palatine arteries to mucosa and glands of hard and soft palate
		Sphenopalatine artery	Terminal branch of maxillary artery, traverses sphenopalatine foramen to supply walls and septum of nasal cavity; frontal, ethmoidal, sphenoid, and maxillary sinuses; and anteriormost palate

Pterygoid Venous Plexus

The pterygoid venous plexus is located partly between the temporalis and pterygoid muscles. It is the venous equivalent of most of the maxillary artery, that is, tributaries from each of the areas supplied by the branches of the maxillary artery ultimately drain into the pterygoid venous plexus and/or its principal anastomotic veins. These veins are valve-less, so flow can go in either direction based on gravity and pressure (**Fig. 2**).

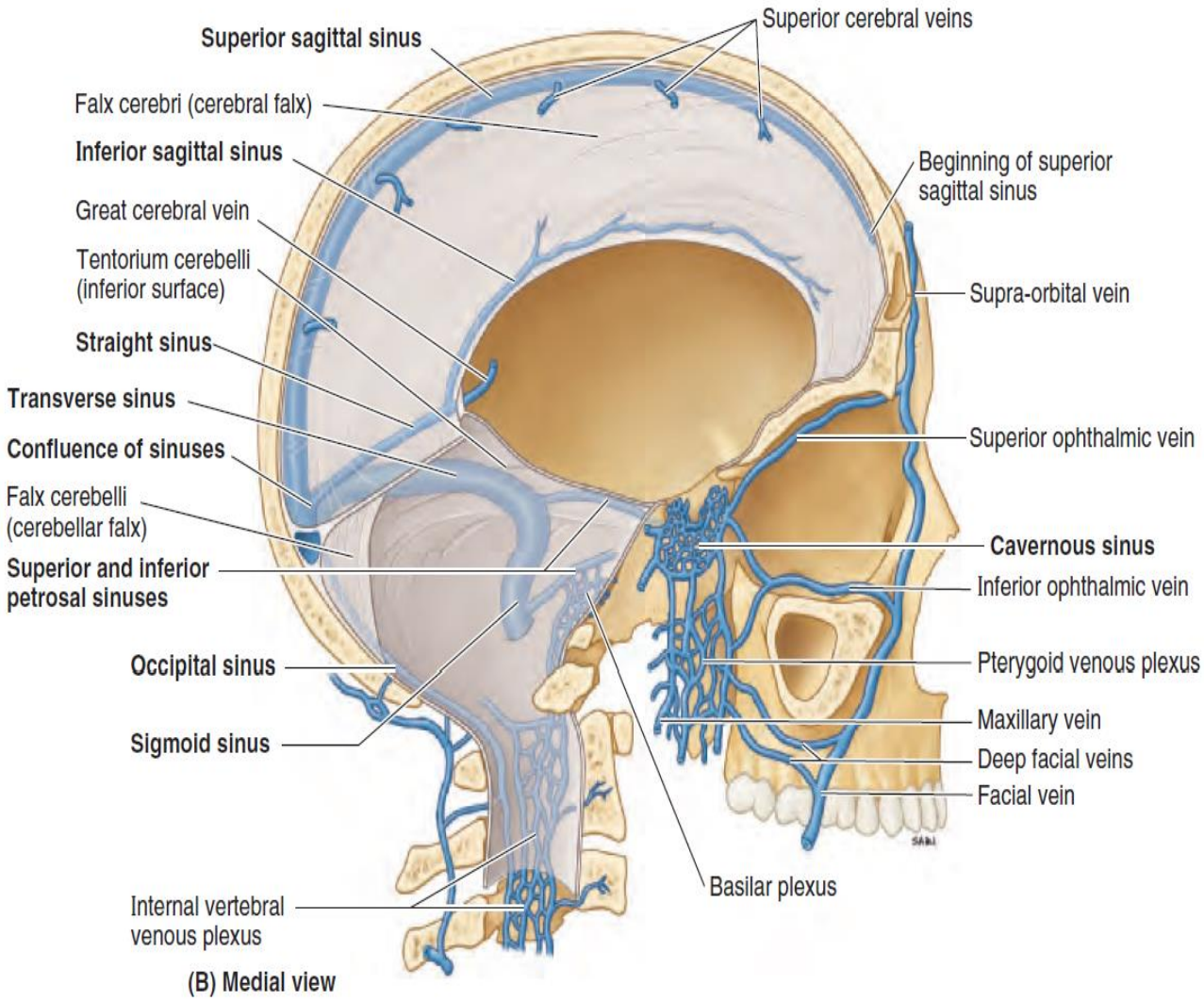

FIGURE 2: Dural infoldings and dural venous sinuses.

The plexus communicates with the **cavernous sinus**, the **facial vein**, the **inferior ophthalmic vein** and the **pharyngeal plexus** (**Fig. 3**). The connections with the cavernous sinus are via emissary veins. The communication with the facial vein is via the deep facial vein. The inferior ophthalmic vein communicates with the pterygoid plexus through a branch passing through the inferior orbital fissure.

The pterygoid venous plexus chiefly drains posteriorly into the maxillary vein. The maxillary vein runs with the first part of the maxillary artery, passing deep to the neck of the condyle of the mandible to enter the parotid gland. Here, it joins the superficial temporal vein to form the retromandibular vein (**Fig. 3**).

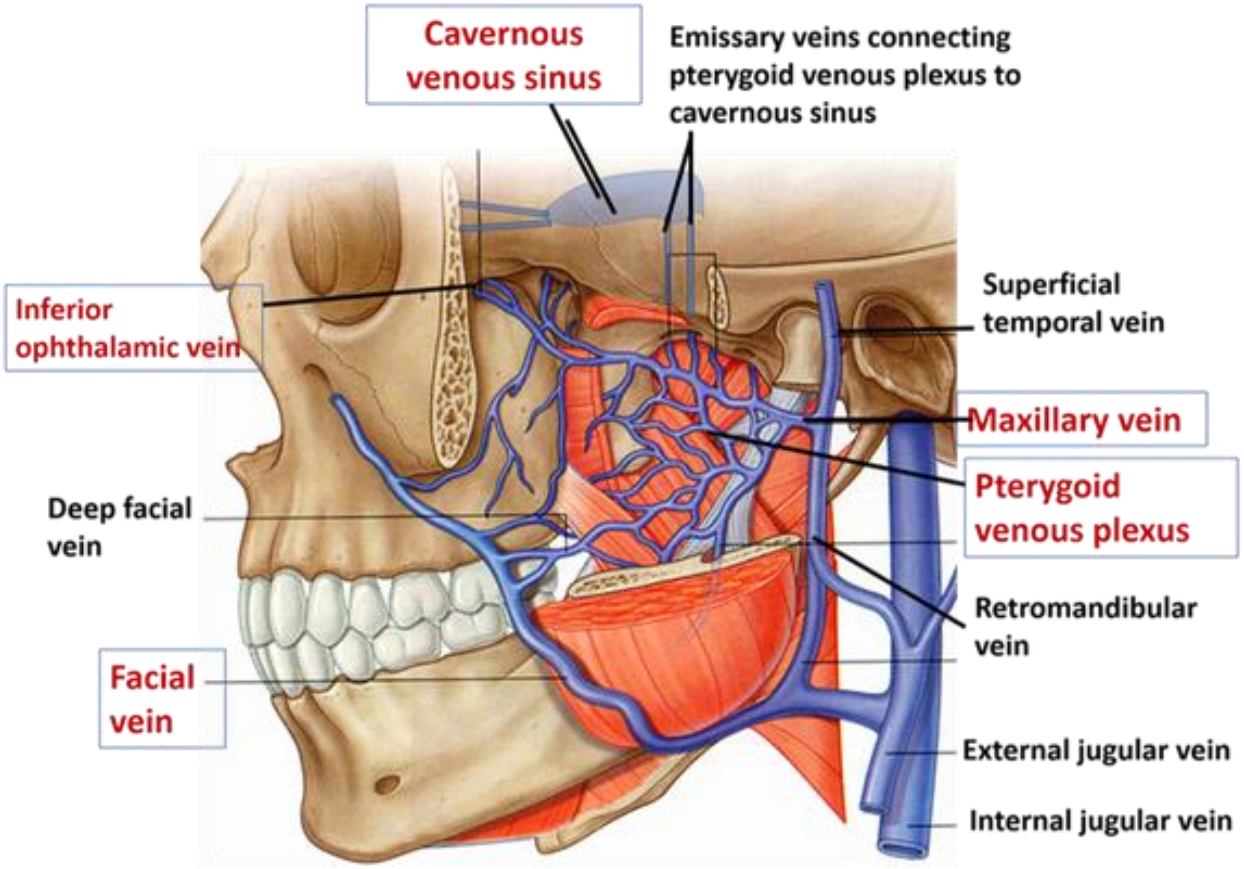

FIGURE 3: Communications of pterygoid venous plexus.

References

1. **Snell RS: Clinical anatomy by regions. Lippincott Williams & Wilkins, 2011.**
2. **Keith LM: Clinically Oriented Anatomy, 7th edition. Wolters Kluwer, 2014.**
3. **Hansen JT: Netter's Clinical Anatomy, 3rd edition. E-Book with Online Access. Elsevier Health Sciences, 2014.**