The Submandibular Region

The submandibular region lies under cover of the body of the mandible, between the mandible and the hyoid bone. It contains the following structures:

• Muscles: Digastric, mylohyoid. hyoglossus. geniohyoid, genioglossus, and styloglossus.
• Salivary glands: Submandibular and sublingual.
• Nerves: Lingual, glossopharyngeal and hypoglossal.
• Parasympathetic ganglion: Submandibular.
• Blood vessels: Facial artery and vein and lingual artery and vein.
• Lymph nodes: Submandibular group.

MUSCLES OF THE SUBMANDIBULAR REGION

Digastric Muscle

The digastric muscle has a posterior belly, an intermediate tendon, and an anterior belly.

• Origin and Insertion: The posterior belly arises from the medial surface of the mastoid process of the temporal bone, passes downward and forward across the carotid sheath, and ends in the intermediate tendon. The intermediate tendon pierces the stylohyoid insertion and is held in position by a loop of deep fascia , which binds the tendon down to the junction of the body and greater cornu of the hyoid bone. The anterior belly runs forward and medially and is attached to the lower border of the body of the mandible, near the median plane.
• Nerve supply: The posterior belly is supplied by the facial nerve and the anterior belly is supplied by the nerve to the mylohyoid, which is a branch of the mandibular division of the trigeminal nerve.
• Action: Depresses the mandible or elevates the hyoid bone.

Stylohyoid Muscle

The stylohyoid muscle is a small slip that passes along the upper border of the posterior belly of the digastric muscle.

• Origin: From the styloid process of the temporal bone.
• Insertion: The muscle passes downward and forward and is inserted into the junction of the body with the greater cornu of the hyoid bone. It is pierced near its insertion by the intermediate tendon of the digastric rnuscle,
• Nerve supply: Facial nerve.
• Action: Elevates the hyoid bone.

Mylohyoid

• Origin: This flat , triangular sheet of muscle arises from the whole length of the mylohyoid line of the mandible.

• Insertion: The fibers run downward and forward. The posterior fibers are inserted into the body of the hyoid bone: the anterior fibers are inserted into a fibrous raphe, which extends from the symphysis menti to the body of the hyoid bone.

• Nerve supply: Mylohyoid branch of the inferior alveolar nerve.

• Action: The two mylohyoid muscles form a muscular sheet that supports the tongue and the floor of the mouth. When the mandible is fixed. They elevate the floor of the mouth and the hyoid hone during the first stage of swallowing. When the hyoid bone is fixed, it assists in the depression of the mandible and the opening of the mouth.

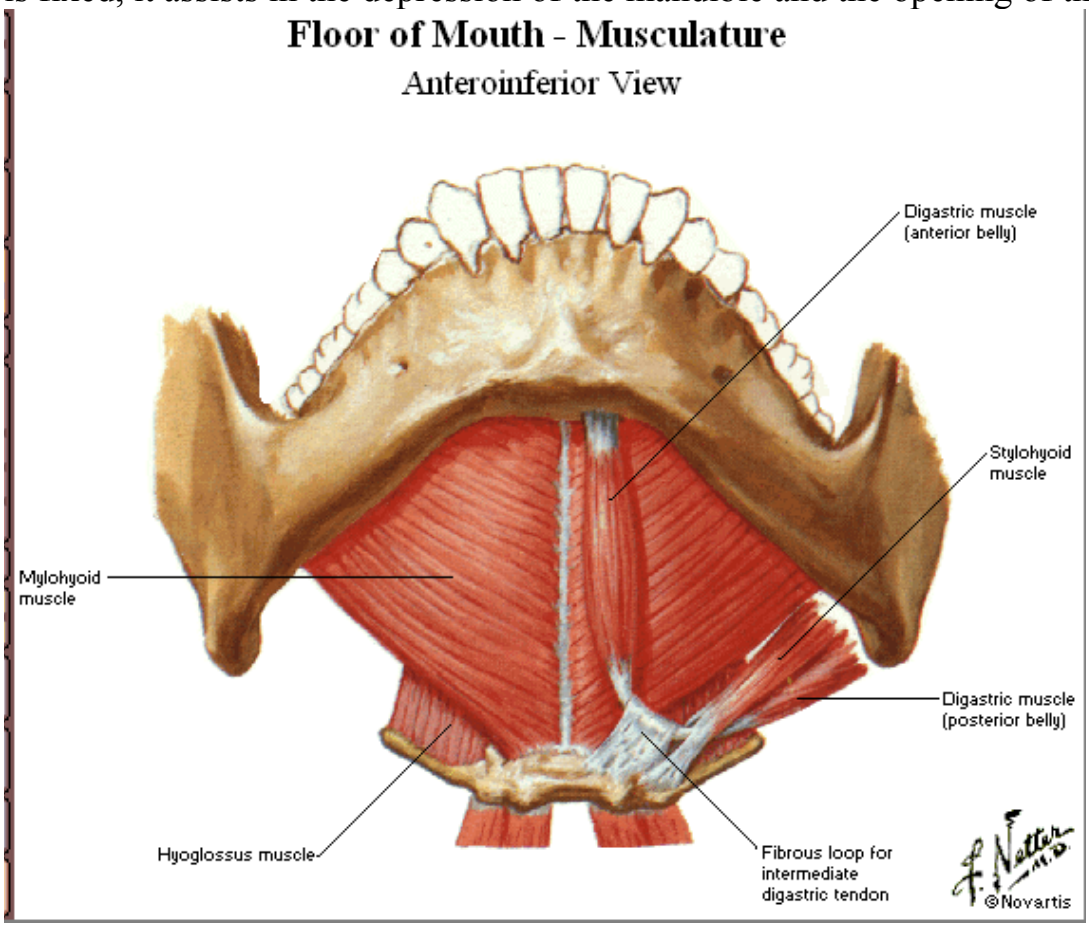

Hvoglossus

• Origin: From the upper border of the body and greater cornu of the hyoid bone.

• Insertion: The muscle is quadrilateral and runs upward deep to the mylohyoid muscle to enter the side of the tongue. It ends when its fibers mix with those of other muscles of the tongue.

• Nerve supply: Hypoglossal nerve.

• Action: Depresses the tongue.

Geniohyoid

• Origin: From the inferior mental spine, behind the symphysis menti of the mandible.

• Insertion: It is a narrow muscle that lies above the mylohyoid and is inserted onto the anterior surface of the body of the hyoid bone. Its medial surface lies in contact with the corresponding muscle of the opposite side.

• Nerve supply: First cervical nerve through the hypoglossal nerve.

• Action: Elevates the hyoid bone and draws it forward; or depresses the mandible.

Genioglossus

• Origin: From the superior mental spine. behind the symphysis rnenti of the mandible .

• Insertion: This fan-shaped muscle widens as it extends backward into the tongue . The superior fibers pass to the tip of the tongue , and middle fibers pass to the dorsum of the tongue, and a few of the inferior fibers are attached to the body of the hyoid bone .

• Nerve supply: Hypoglossal nerve.

• Action: Draws the tongue forward and protrudes the tip so that it points to the opposite side, the two muscles acting in unison protrude the tongue in the midline

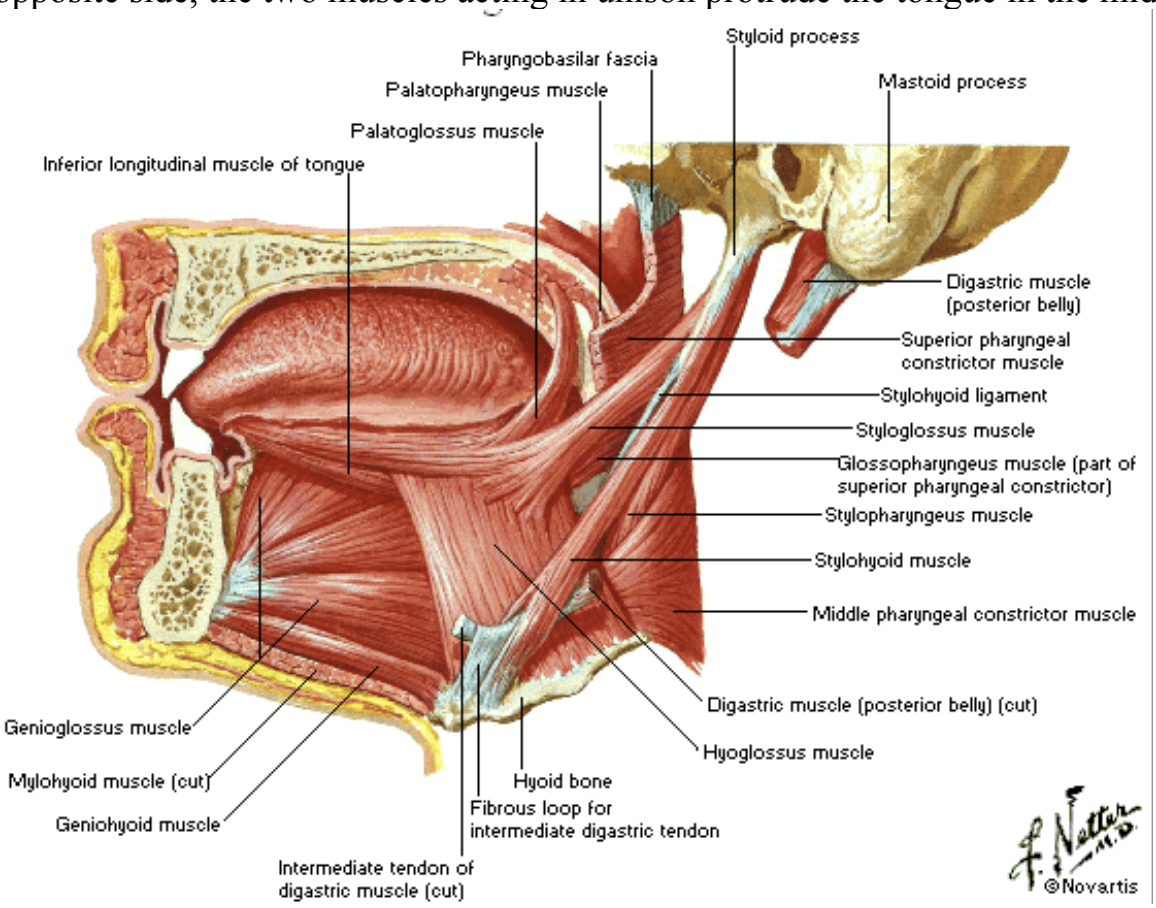

Styloglossus

• Origin: From the styloid process.

• Insertion: The fibers run downward and forward on the lateral surface of the superior constrictor muscle. On reaching the interval between the superior and middle constrictor muscles, the styloglossus passes forward to enter the side of the tongue.

• Nerve supply: Hypoglossal nerve.

• Action: Draws the tongue upward and backward.

The submandibular gland

The submandibular gland is a large salivary gland and is composed of a mixture of serous and mucous acini, the former predominating. It lies partly under cover of the body of the mandible and is made up of a large superficial part and a small deep part. Which are continuous with each other around the posterior border of the mylohyoid muscle.

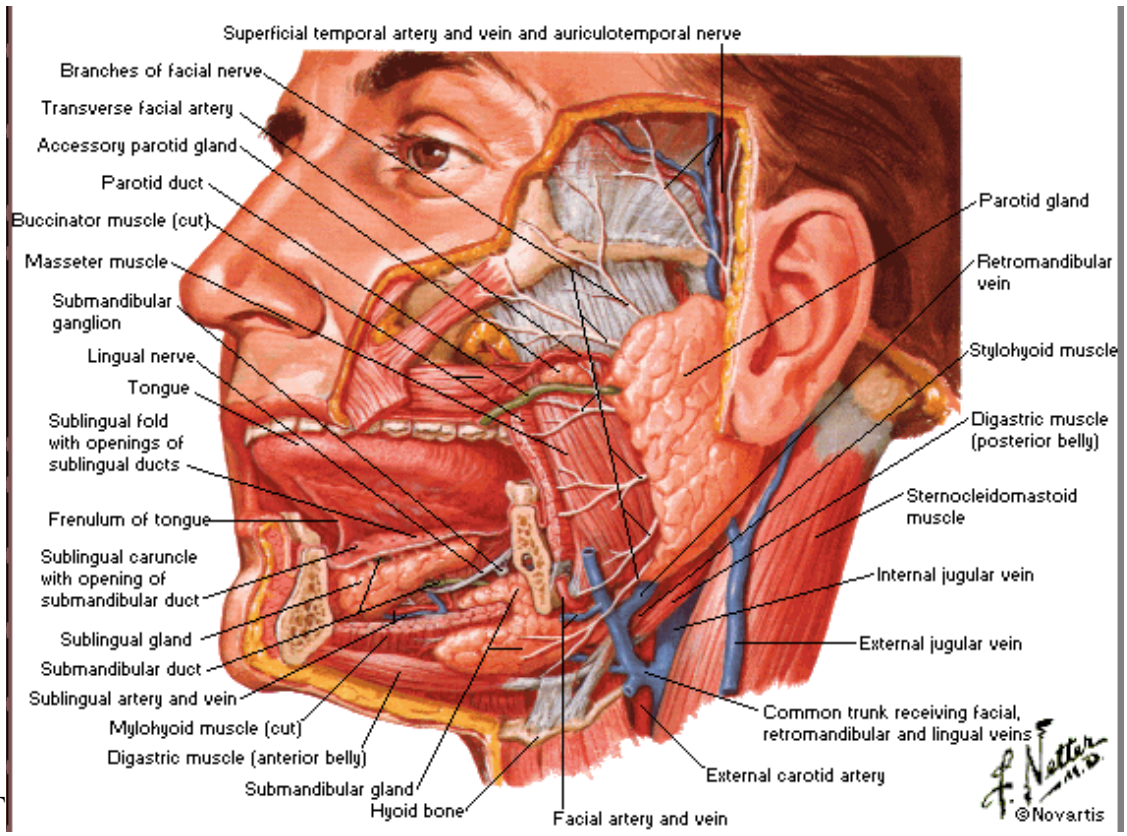

T

Retations of the Superficial Part of the Gland

- Anteriorly: The anterior belly of the digastrics
- Posteriorly: The stylohyoid, the posterior belly of the digastric, and the parotid gland.
- Medially: The mylohyoid, the hyoglossus, and the lingual and hypoglossal nerves.
- Laterally: The gland lies in contact with the submandibular fossa in the medial surface of the mandible.

- Inferolaterally, it is covered by the investing layer of deep cervical fascia , the platysma muscle, and skin. It is crossed by the cervical branch of the facial nerve and facial vein. The submandibular lymph nodes also lie lateral to it.

The facial artery is related to the posterior and superior aspects of the superficial part of the gland.

The deep part of the gland extends forward in the interval between the mylohyoid below and laterally and the hyoglossus and styloglossus medially. Its posterior end is continuous with the superficial part of the gland around the posterior border of the mylohyoid muscle; its anterior end reaches as far as the sublingual gland.

Relations of the Deep Part of the Gland
• Anteriorly: The sublingual gland.
• Posteriorly: The stylohyoid, the posterior belly of the digastric, and the parotid gland.
• Medially: The hyoglossus and styloglossus.
• Laterally: The mylohyoid muscle and the superficial part of the gland.
• Superiorly: It is related superiorly to the lingual nerve and the submandibular ganglion; it is covered by the mucous membrane of the floor of the mouth.
• Inferiorly: The hypoglossal nerve.

Capsules of the Gland
The submandibular gland is a lobulated mass surrounded by a connective-tissue capsule. In addition, the gland is partly enclosed in a dense fibrous capsule derived from the investing layer of deep cervical fascia.

Submandibular Duct
The submandibular duct emerges from the anterior end of the deep part of the gland. It passes forward along the side of the tongue, beneath the mucous membrane of the floor of the mouth. It is crossed laterally by the lingual nerve and then lies between the sublingual gland and the genioglossus muscle. It opens into the mouth on the summit of a small papilla, which is situated at the side of the frenulom of the tongue.
Clinically, it is important to remember that the submandibular duct and the deep part of the gland can be readily palpated through the mucous membrane of the floor of the mouth alongside the tongue. Saliva can usually be seen emerging from the orifice of the duct

Sublingual Gland
Type and Location
The sublingual gland is the smallest of the three main salivary glands. It contains both serous and mucous acini, the latter predominating. It lies beneath the mucous membrane of the floor of the mouth, close to the midline.

Relations

• Anteriorly: The gland of the opposite side.
• Posteriorly : the deep part of the submandibular gland.
• Medially : The genioglossus muscle, the lingual nerve, and the submandibular duct.
• Laterally: The gland is related laterally to the sublingual fossa of the medial surface of the mandible.
• Superiorly: The mucous membrane of the floor of the mouth, which is elevated by the gland to form the sublingual fold.
• Inferiorly : The gland is supported by the mylohyoid muscle.

