Human Anatomy

Dr. Mustafa Fadhil
Ph.D. Anatomy

Lec.19

Cranial nerves

Like spinal nerves, cranial nerves are bundles of sensory or motor fibers that innervate muscles or glands, carry impulses from sensory receptors, or have a combination of motor and sensory fibers. They are called cranial nerves because they emerge through foramina or fissures in the cranium and are covered by tubular sheaths derived from the cranial meninges. Twelve pairs of cranial nerves arise from the brain, and they are identified both by their names and by Roman numerals I to XII (**Figs. 1 & 2**). Their names reflect their general distribution or function. Some cranial nerves are purely sensory, others are considered purely motor, and several are mixed (**Table 1**).

The cranial nerves are somewhat unique and can contain multiple functional components:

- **General:** same general functions as spinal nerves.
- **Special:** functions found only in cranial nerves.
- **Afferent** and **efferent:** sensory and motor functions, respectively.
- **Somatic** and **visceral:** related to skin and skeletal muscle (somatic) or to smooth muscle, cardiac muscle, and glands (visceral).

Therefore, each cranial nerve (CN) may possess one or more of the following **five main** functional components: (**Table 1**)

1. **Motor efferent fibers** to voluntary (striated) muscle (**e.g.,** muscles of mastication).
2. **Motor efferent fibers** to involuntary (smooth) muscles or glands (**e.g.,** the sphincter pupillae and lacrimal gland).
3. **Sensory afferent fibers** transmitting general sensation (**e.g.,** touch, pressure, heat, cold, etc.)
4. **Sensory afferent fibers** conveying sensation from the viscera (**e.g.,** pharynx, larynx, trachea, bronchi, lungs, heart, and gastrointestinal tract).
5. **Sensory afferent fibers** transmitting unique sensations:
   - ✓ Special visceral (**e.g.,** taste and smell).
   - ✓ Special somatic (**e.g.,** vision, hearing, and balance).

TABLE 1: Summary of cranial nerves.

Nerve	Components	Function	Opening in Skull
I. Olfactory	Sensory	Smell	Openings in cribriform plate of ethmoid
II. Optic	Sensory	Vision	Optic canal
III. Oculomotor	Motor	Lifts upper eyelid, turns eyeball upward, downward, and medially; constricts pupil; accommodates eye	Superior orbital fissure
IV. Trochlear	Motor	Assists in turning eyeball downward and laterally	Superior orbital fissure
V. Trigeminal			
Ophthalmic division	Sensory	Cornea, skin of forehead, scalp, eyelids, and nose; also mucous membrane of paranasal sinuses and nasal cavity	Superior orbital fissure
Maxillary division	Sensory	Skin of face over maxilla and the upper lip; teeth of upper jaw; mucous membrane of nose, the maxillary air sinus, and palate	Foramen rotundum
Mandibular division	Motor	Muscles of mastication, mylohyoid, anterior belly of digastric, tensor veli palatini, and tensor tympani	Foramen ovale
	Sensory	Skin of cheek, skin over mandible, lower lip, and side of head; teeth of lower jaw and temporomandibular joint; mucous membrane of mouth and anterior two thirds of tongue	
VI. Abducent	Motor	Lateral rectus muscle: turns eyeball laterally	Superior orbital fissure
VII. Facial	Motor	Muscles of face, cheek, and scalp; stapedius muscle of middle ear; stylohyoid; and posterior belly of digastric	Internal acoustic meatus, facial canal, stylomastoid foramen
	Sensory	Taste from anterior two thirds of tongue, floor of mouth, and palate	
	Secretomotor parasympathetic	Submandibular and sublingual salivary glands, lacrimal gland, and glands of nose and palate	
VIII. Vestibulocochlear			
Vestibular	Sensory	Position and movement of head	Internal acoustic meatus
Cochlear	Sensory	Hearing	
IX. Glossopharyngeal	Motor	Stylopharyngeus muscle: assists swallowing	
	Secretomotor parasympathetic	Parotid salivary gland	Jugular foramen
	Sensory	General sensation and taste from posterior third of tongue and pharynx; carotid sinus and carotid body	

TABLE 1: Summary of cranial nerves (*Continued*).

X. Vagus	Motor	Constrictor muscles of pharynx and intrinsic muscles of larynx; involuntary muscle of trachea and bronchi, heart, alimentary tract from pharynx to splenic flexure of colon; liver and pancreas	Jugular foramen
	Sensory	Taste from epiglottis and vallecula and afferent fibers from structures named above	
XI. Accessory			
Cranial root	Motor	Muscles of soft palate, pharynx, and larynx	Jugular foramen
Spinal root	Motor	Sternocleidomastoid and trapezius muscles	
XII. Hypoglossal	Motor	Muscles of tongue controlling its shape and movement (except palatoglossus)	Hypoglossal canal

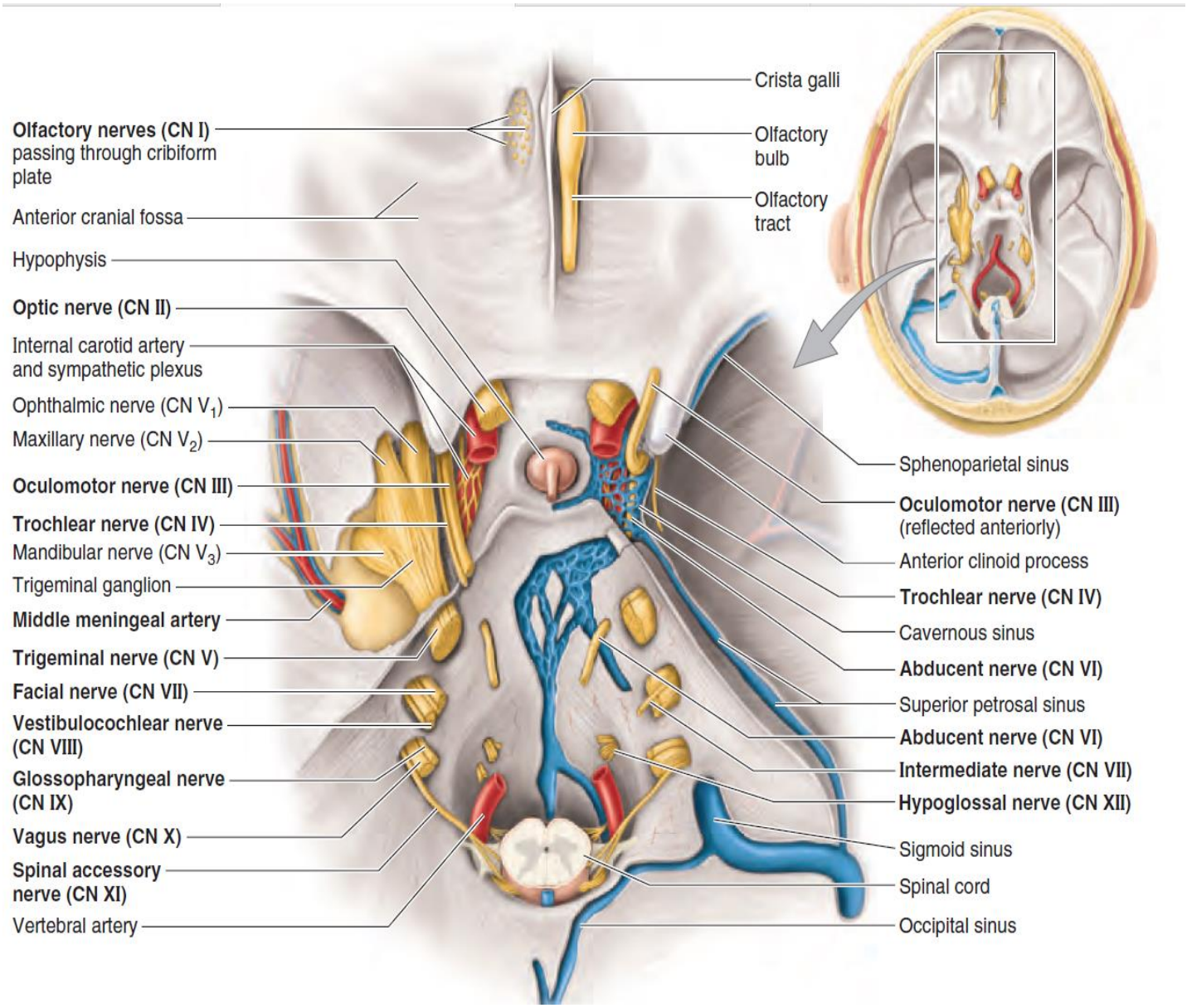

FIGURE 1: Cranial nerves in relation to internal aspect of cranial base (superior view).

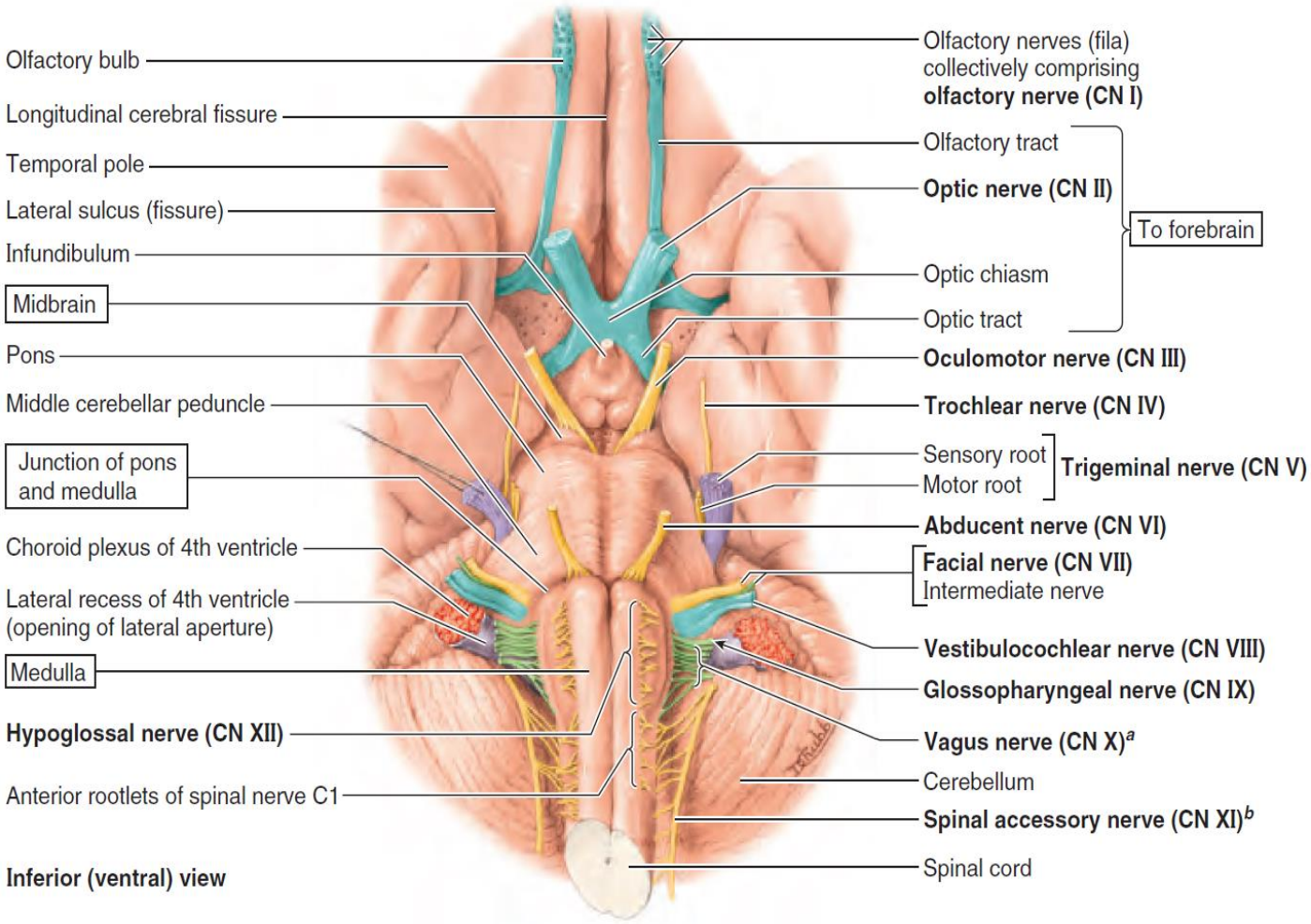

FIGURE 2: Superficial origins of cranial nerves from brain and spinal cord (except for CN IV, which arises from the posterior aspect of the midbrain). [a]The traditional "cranial root of the accessory nerve" is considered here as part of the vagus nerve. [b]The spinal accessory nerve as listed here refers to only the traditional "spinal root of the accessory nerve."

References

1. **Snell RS: Clinical anatomy by regions. Lippincott Williams & Wilkins, 2011.**
2. **Keith LM: Clinically Oriented Anatomy, 7th edition. Wolters Kluwer, 2014.**
3. **Hansen JT: Netter's Clinical Anatomy, 3rd edition. E-Book with Online Access. Elsevier Health Sciences, 2014.**