Dr.Mustafa Fadhil
PhD.Anatomy & Histology

Human Anatomy

Lec.5

Parotid region

Regions of Head

To allow clear communications regarding the location of structures, injuries, or pathologies, the head is divided into regions (**Fig. 1**).

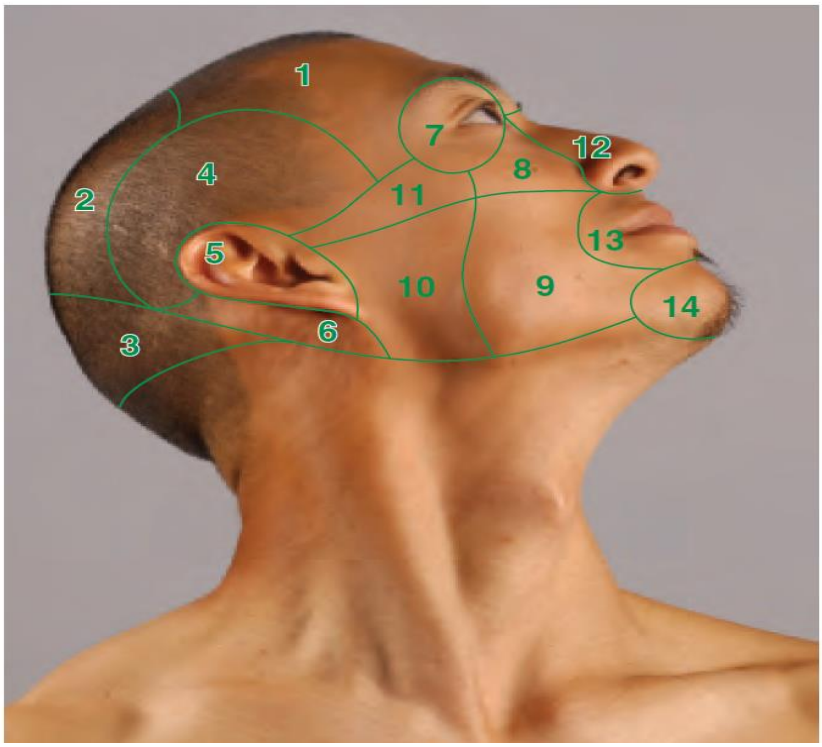

Regions of the head:

1 Frontal region
2 Parietal region
3 Occipital region
4 Temporal region
5 Auricular region
6 Mastoid region

Facial region:
7 Orbital region
8 Infra-orbital region
9 Buccal region
10 Parotid region
11 Zygomatic region
12 Nasal region
13 Oral region
14 Mental region

FIGURE 1: Regions of head.

Parotid Region

The parotid region is the posterolateral part of the facial region (**Fig. 2**), bounded by the:

- Zygomatic arch **superiorly**.
- Angle and inferior border of the mandible **inferiorly**.
- Ramus of the mandible **medially**.
- Anterior border of the masseter muscle **anteriorly**.
- External ear and anterior border of the sternocleidomastoid muscle **posteriorly**.

The parotid region includes the parotid gland and duct, the parotid plexus of the facial nerve (CN VII), the retromandibular vein, the external carotid artery, and the masseter muscle. On the parotid sheath and within the gland are parotid lymph nodes. The five terminal branches of the facial nerve leave through the anterior border of the gland in a radiating manner that resembles the foot of a goose. Hence, this pattern is known as **"pes anserinus".**

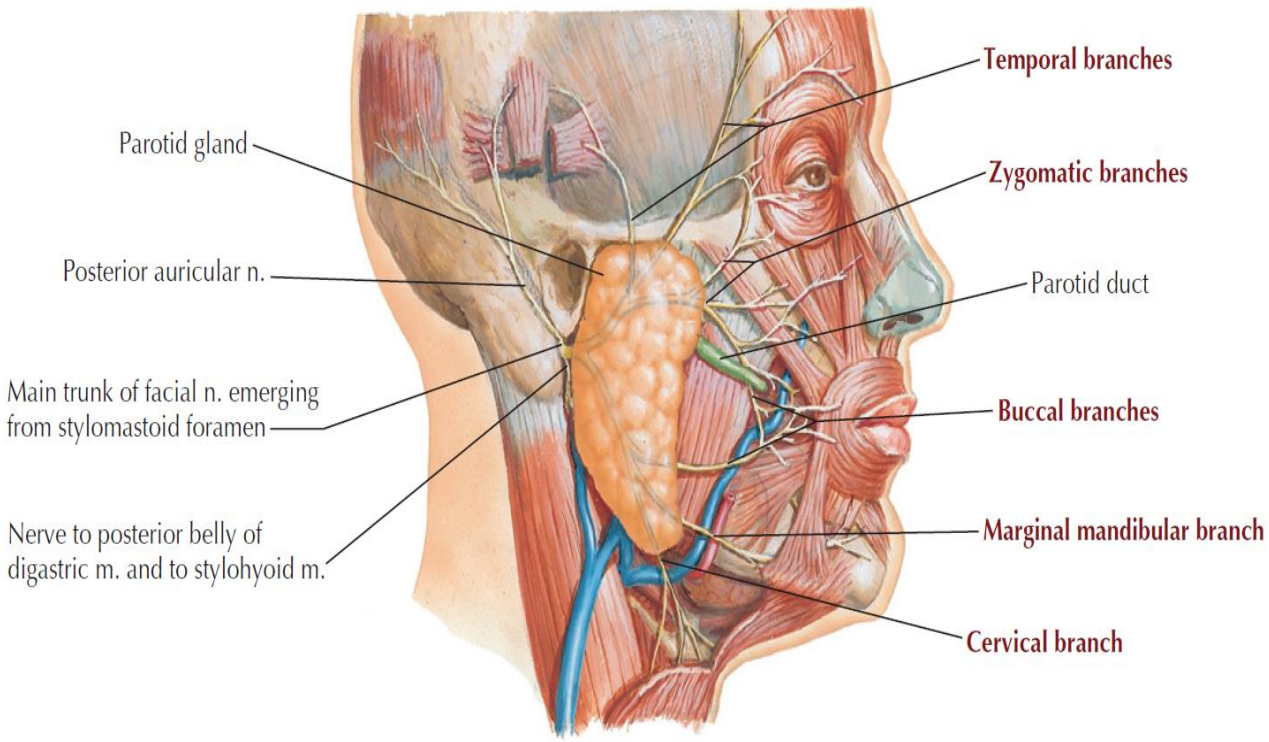

FIGURE 2: Terminal branches of facial nerve and parotid gland.

Parotid Gland

The parotid gland is the largest of three paired salivary glands and is composed mostly of serous acini. It is enclosed within the **parotid sheath**, a tough unyielding capsule derived from the deep cervical fascia. (**Fig. 3**). It lies in a deep hollow below the external auditory meatus, behind the ramus of the mandible (**Fig. 4**), and in front of the sternocleidomastoid muscle.

The parotid gland has an irregular shape; the apex is posterior to the angle of the mandible, and its base is related to the zygomatic arch. The subcutaneous lateral surface of the parotid gland is almost flat (**Fig. 4**).The facial nerve divides the gland into **superficial** and **deep lobes.** Fatty tissue between the lobes confers the flexibility the gland must have to accommodate the motion of the mandible.

Parotid Duct

The parotid (Stensen's) duct passes horizontally from the anterior edge of the gland (**Figs. 2 & 4**) and passes forward over the lateral surface of the masseter muscle about one fingerbreadth below the zygomatic arch. It then turns medially, dives deeply into the buccal fat-pad, piercing the buccinator muscle and enters the vestibule of oral cavity through a small orifice (papilla) opposite the second maxillary molar tooth (**Fig. 4**). The oblique passage of the duct in the buccinator muscle acts as a valve-like mechanism & prevents inflation of the duct during blowing. The duct is about 2 in. (5 cm) long. It is represented by the **middle 1/3rd** of a line extending from the tragus of the auricle to a point midway between the ala of nose & upper lip.

Innervation of Parotid Gland and Related Structures

Although the parotid plexus of the facial nerve (CN VII) is embedded within the parotid gland, CN VII does not provide innervation to the gland. The **auriculotemporal** and **great auricular nerves** provide sensory fibers to the gland and innervate the parotid sheath (**Fig. 3**) as well as the overlying skin. The parasympathetic component of the **glossopharyngeal nerve** (CN IX) supplies presynpatic secretory fibers to the **otic ganglion** (**Fig. 5**). The postsynaptic parasympathetic fibers are conveyed from the ganglion to the gland by the auriculotemporal nerve. Stimulation of the parasympathetic fibers produces a thin, watery saliva. Sympathetic fibers are derived from the cervical ganglia through the **external carotid nerve plexus** on the external carotid artery (**Fig. 3**).

Arterial Supply

External carotid artery & its terminal branches.

Venous Drainage

Into the retro-mandibular vein.

Lymph Drainage

Into the **parotid** & then into the **deep cervical** lymph nodes.

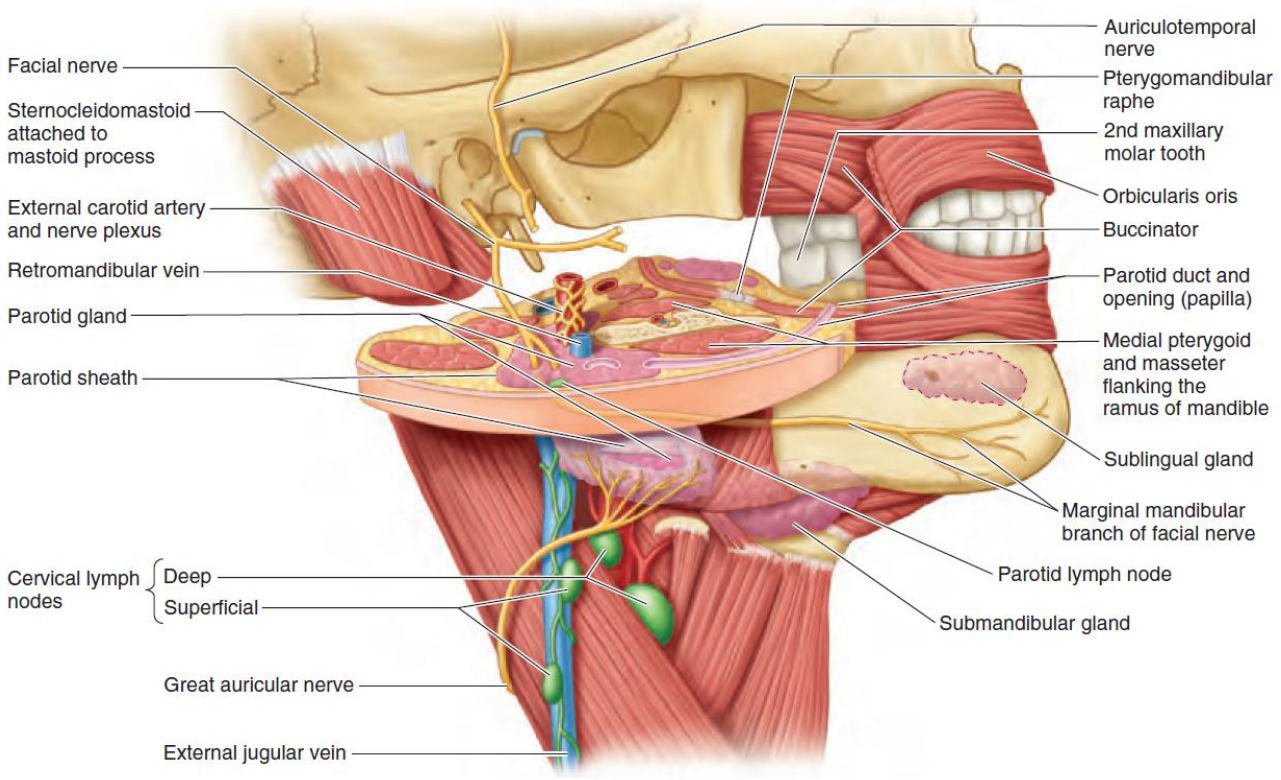

FIGURE 3: Relationships of parotid gland.

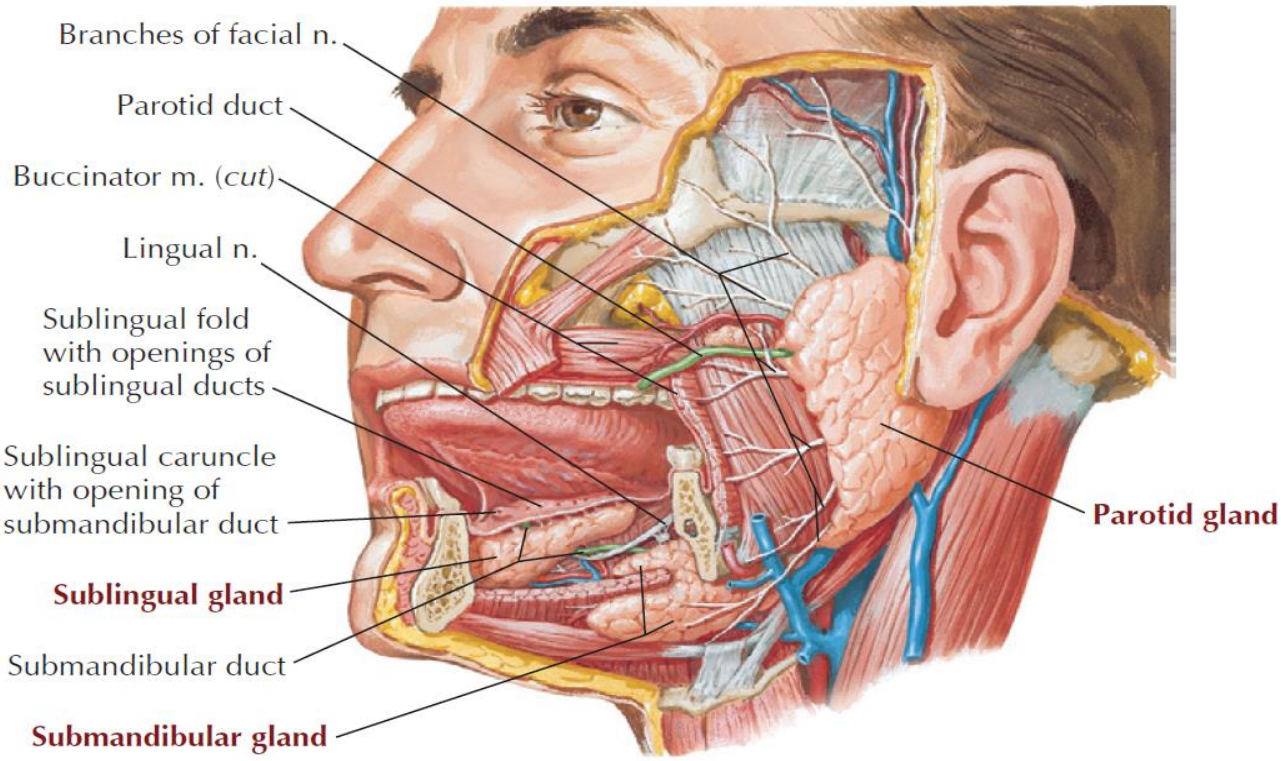

FIGURE 4: Major salivary glands.

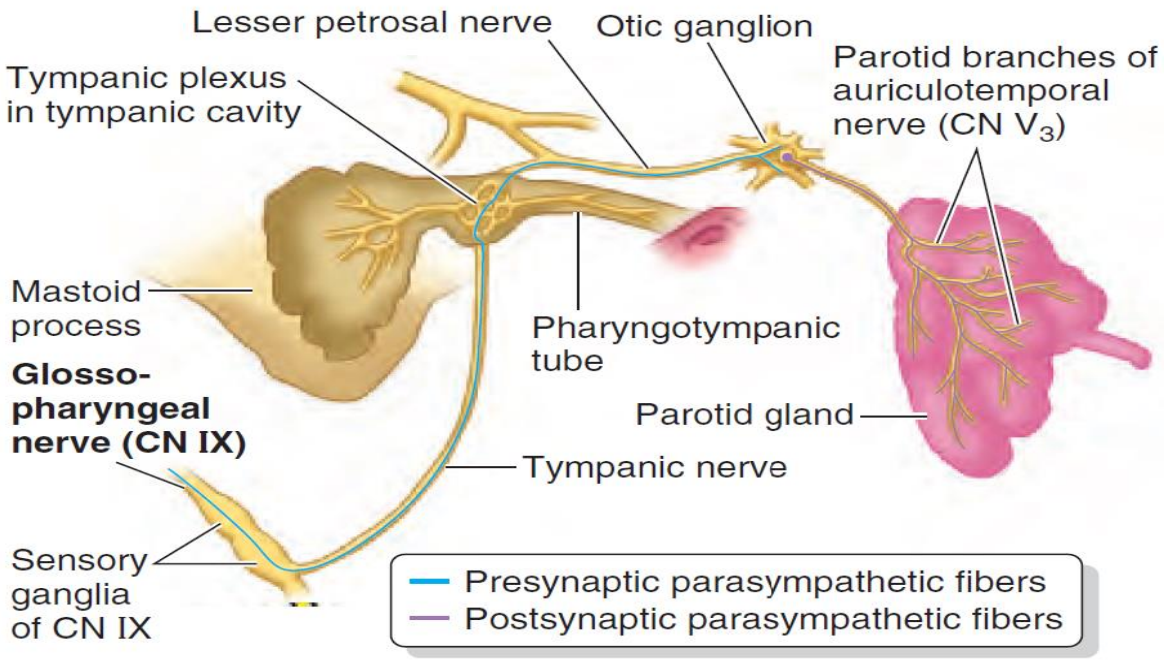

FIGURE 5: Innervation of parotid gland.

The Buccal Pad of Fat

Superficial to the buccinators (on either side of the face) are encapsulated collections of fat; these **buccal fat-pads** are much larger in infants, to reinforce the cheeks and keep them from collapsing during sucking. The blood supply to the buccal fat-pad originates from the buccal and deep temporal branches of the **maxillary artery**, the transverse facial branch of the **superficial temporal artery**, and branches of the **facial artery**. This rich vascularity allows a reliable long axial flap and explains the rapid surface re-epithelialization. The cheeks are innervated by buccal branches of the mandibular nerve.

The buccal fat-pad's primary function is thought to be related to chewing and suckling, especially in infants. Another proposed function is as gliding pads that facilitate the action of the muscles of mastication. The buccal fat pad may also function as a cushion to protect sensitive facial muscles from injury due to muscle action or exterior force.

Clinical Notes

- **Parotid Duct Injury**
  The parotid duct may be damaged in injuries to the face or may be inadvertently cut during surgical operations on the face.

- **Parotid Salivary Gland and Lesions of the Facial Nerve**
  The parotid salivary gland consists essentially of superficial and deep parts, and the important facial nerve lies in the interval between these parts. A **benign** parotid neoplasm rarely, if ever, causes facial palsy. A **malignant** tumor of the parotid is usually highly invasive and quickly involves the facial nerve, causing unilateral facial paralysis.

- **Parotid Gland Infections**
  The parotid gland may become acutely inflamed as a result of **retrograde bacterial infection** from the mouth via the parotid duct. The gland may also become infected via the bloodstream, as in **mumps**. In both cases, the gland is swollen; it is painful because the fascial capsule derived from the investing layer of deep cervical fascia is strong and limits the swelling of the gland.

- **Frey's Syndrome**
  Frey's syndrome is an interesting complication that sometimes develops after penetrating wounds of the parotid gland. When the patient eats, beads of perspiration appear on the skin covering the parotid. This condition is caused by damage to the **auriculotemporal** and **great auricular** nerves. During the process of healing, the parasympathetic secretomotor fibers in the auriculotemporal nerve grow out and join the distal end of the great auricular nerve. Eventually, these fibers reach the cutaneous sympathetic nerves that supply the sweat glands in the facial skin. By this means, a stimulus intended for saliva production produces sweat secretion instead.

References

1. Snell RS: Clinical anatomy by regions. Lippincott Williams & Wilkins, 2011.