THE PTERYGOPALATINE FOSSA

The pterygopalatine fossa lies beneath the posterior surface of the maxilla and the pterygoid process of the sphenoid bone. The pterygopalatine fossa contains the maxillary nerve, the maxillary artery (third part) and the pterygopalatine parasympathetic ganglion.

Boundaries

Anteriorly: posterior surface of maxilla.
Posteriorly: anterior margin of pterygoid process below and greater wing of sphenoid above.
Medially: perpendicular plate of palatine bone.
Superiorly: greater wing of sphenoid.
Laterally: communicates with infratemporal fossa through pterygomaxillary fissure

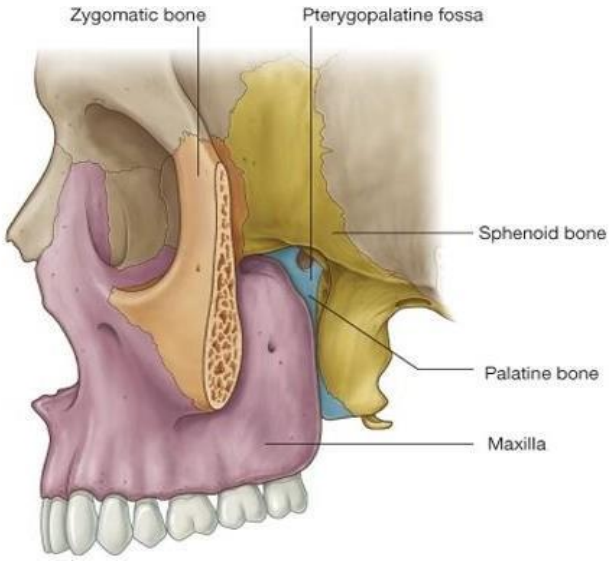

Communications and openings:

1. The pterygomaxillary fissure: transmits the maxillary artery from the infratemporal fossa, the posterior superior alveolar branches of the maxillary division of the trigeminal nerve and the sphenopalatine veins.
2. The inferior orbital fissure: transmits the infraorbital and zygomatic branches of the maxillary nerve, the orbital branches of the pterygopalatine ganglion and the infraorbital vessels.
3. The foramen rotundum: transmit the maxillary division of the trigeminal nerve.

4. The pterygoid canal: It transmits the greater petrosal and deep petrosal nerves (which combine to form the nerve of the pterygoid canal) and an accompanying artery derived from the maxillary artery.
5. The sphenopalatine foramen: This foramen communicates with the lateral wall of the nasal cavity. It transmits the nasopalatine and posterior superior nasal nerves (from the pterygopalatine ganglion) and the sphenopalatine vessels.
6. The opening of a palatine canal found at the base of the fossa. Lower down, the canal divides into *greater* and *lesser* palatine canals. The palatine canal transmits the greater and lesser palatine nerves, together with accompanying vessels, and these pass to the hard palate to emerge at the greater and lesser palatine foramina.
7. **Pharyngeal canal:** courses posteriorly and medially into pharynx, for pharyngeal artery

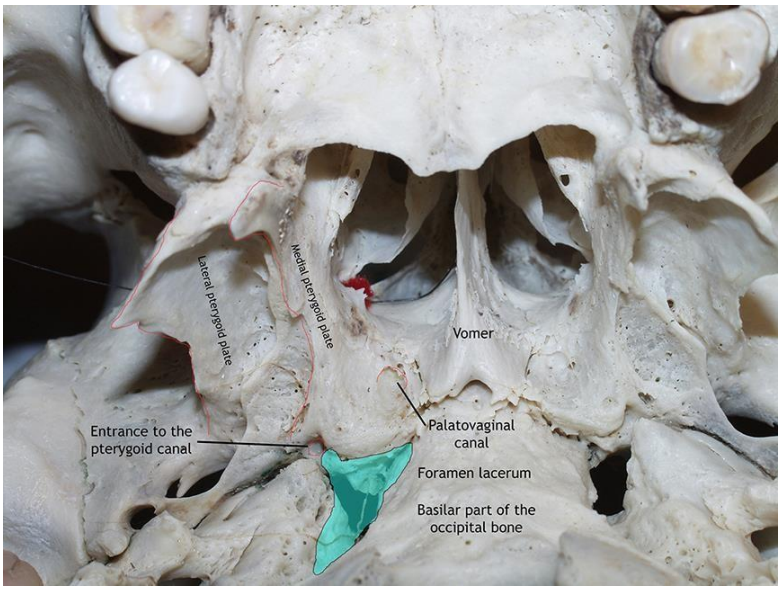

Maxillary nerve

This division of the trigeminal nerve (the fifth cranial nerve) contains only sensory fibers. Functionally, it supplies the maxillary teeth and their supporting structures, the hard and soft palate, the maxillary air sinus, much of the nasal cavity, and skin overlying the middle part of the face.

The maxillary nerve arises from the trigeminal ganglion on the floor of the middle cranial fossa. It passes along the lateral dural wall of the cavernous sinus to exit the cranial cavity at the foramen rotundum. It emerges from the foramen rotundum in the upper part of the pterygopalatine fossa, where most of the branches are derived. These branches can be classified into those which come directly from the maxillary nerve, and those which are associated with the pterygopalatine parasympathetic ganglion.

- Branches from the main maxillary nerve trunk:

1. Meningeal nerve
2. Ganglionic branches
3. Zygomatic nerve
   zygomaticotemporal nerve
   zygomaticofacial nerve
4. Infraorbital nerve
   middle superior alveolar nerve
   anterior superior alveolar nerve
5. Posterior superior alveolar nerve

- Branches from the pterygopalatine ganglion:

Orbital nerve
Nasopalatine nerve
Posterior superior nasal nerve
Posterior inferior nasal nerve
Greater (anterior) palatine nerve
Lesser (posterior) palatine nerve
Pharyngeal branch

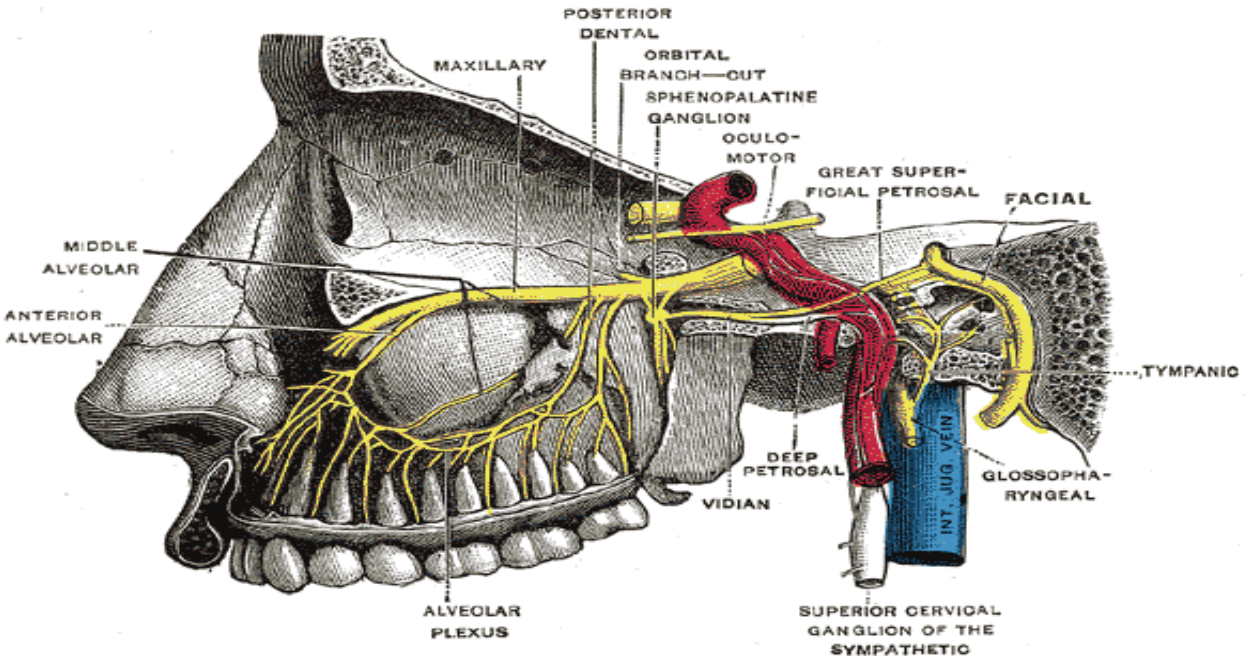

The meningeal nerve:
This is the only branch from the main trunk of the maxillary nerve that does not originate in the pterygopalatine fossa; it arises within the middle cranial fossa, before the foramen rotundum. It runs with the middle meningeal artery and innervates the dura mater lining the middle cranial fossa.

The ganglionic branches:
These are usually two in number and connect the maxillary nerve to the pterygopalatine ganglion.

The zygomatic nerve:
This leaves the pterygopalatine fossa through the inferior orbital fissure. It passes along the lateral wall of the orbit before dividing into zygomaticotemporal and zygomaticofacial branches. These pass through the zygomatic bone to supply overlying skin. The zygomaticotemporal nerve also gives a branch to the lacrimal nerve, which carries autonomic fibres to the lacrimal gland.

The posterior superior alveolar nerve(s)
This is one of three superior alveolar nerves that supply the maxillary teeth. The middle and anterior superior alveolar nerves are branches of the infraorbital nerve . The posterior superior alveolar nerve leaves the pterygopalatine fossa through the pterygomaxillary fissure. Then, it runs onto the tuberosity of the maxilla and eventually pierces the bone to supply the maxillary molar teeth and the maxillary sinus. Before entering the maxilla, the nerve provides a gingival branch which innervates the buccal gingivae around the maxillary molars.

The infraorbital nerve
This can be regarded as the terminal branch of the maxillary nerve proper. It leaves the pterygopalatine fossa to enter the orbit at the inferior orbital fissure. Initially lying in a groove in the floor of the orbit (the infraorbital groove), the infraorbital nerve runs into a canal (the infraorbital canal) and passes onto the face at the infraorbital foramen. The middle and anterior superior alveolar nerves arise from the infraorbital nerve in the orbit.

The branches of the maxillary nerve that arise with the pterygopalatine ganglion contain not only sensory fibres from the maxillary nerve, but also autonomic fibres from the ganglion, which are mainly distributed to glands and blood vessels.

The orbital nerve
This passes from the pterygopalatine ganglion into the orbit through the inferior orbital fissure. It supplies periosteum and, via sympathetic fibres, the orbitalis muscle. The orbital nerve can also supply part of the maxillary sinus and may pass through the posterior ethmoidal foramen to innervate posterior ethmoidal air cells and the sphenoid air sinus.

The Nasopalatine nerve
This nerve runs medially from the pterygopalatine ganglion into the nasal cavity through the sphenopalatine foramen. It passes across the roof of the nasal cavity to reach the back of the nasal septum. The nasopalatine nerve then passes downwards

and forwards within a groove on the vomer to supply the posteroinferior part of the nasal septum. It passes through the incisive canal, where it usually forms a single nerve with its fellow of the opposite side, and emerges on the hard palate at the incisive fossa to supply the oral mucosa around the incisive papilla and palatal gingiva of the anterior teeth.

The posterior superior nasal nerve

This nerve enters the back of the nasal cavity through the sphenopalatine foramen. It divides into lateral and medial branches.

The lateral branches supply the posterosuperior part of the lateral wall of the nasal fossa. The medial branches supply the nasal septum overlying the posterior part of the perpendicular plate of the ethmoid.

The posterior inferior nasal nerve

This supplies the inferior part of the lateral wall of the nose in the region of the inferior nasal concha.

The greater (anterior) palatine nerve

This nerves passes downwards from the pterygopalatine ganglion, through the palatine canal, and onto the hard palate at the palatine foramen. On the palate, it runs forwards at the interface between the palatine process and the alveolar process of the maxilla to supply much of the mucosa of the hard palate and palatal gingivae (except around the incisive papilla).

The lesser (posterior) palatine nerve(s)

This passes downwards from the pterygopalatine ganglion initially through the palatine canal. It then passes through lesser palatine foramen (or foramina). It runs backwards to supply the soft palate.

The pharyngeal branch

This originates from the pterygopalatine ganglion and passes through the palatovaginal canal to supply the mucosa of the nasopharynx.

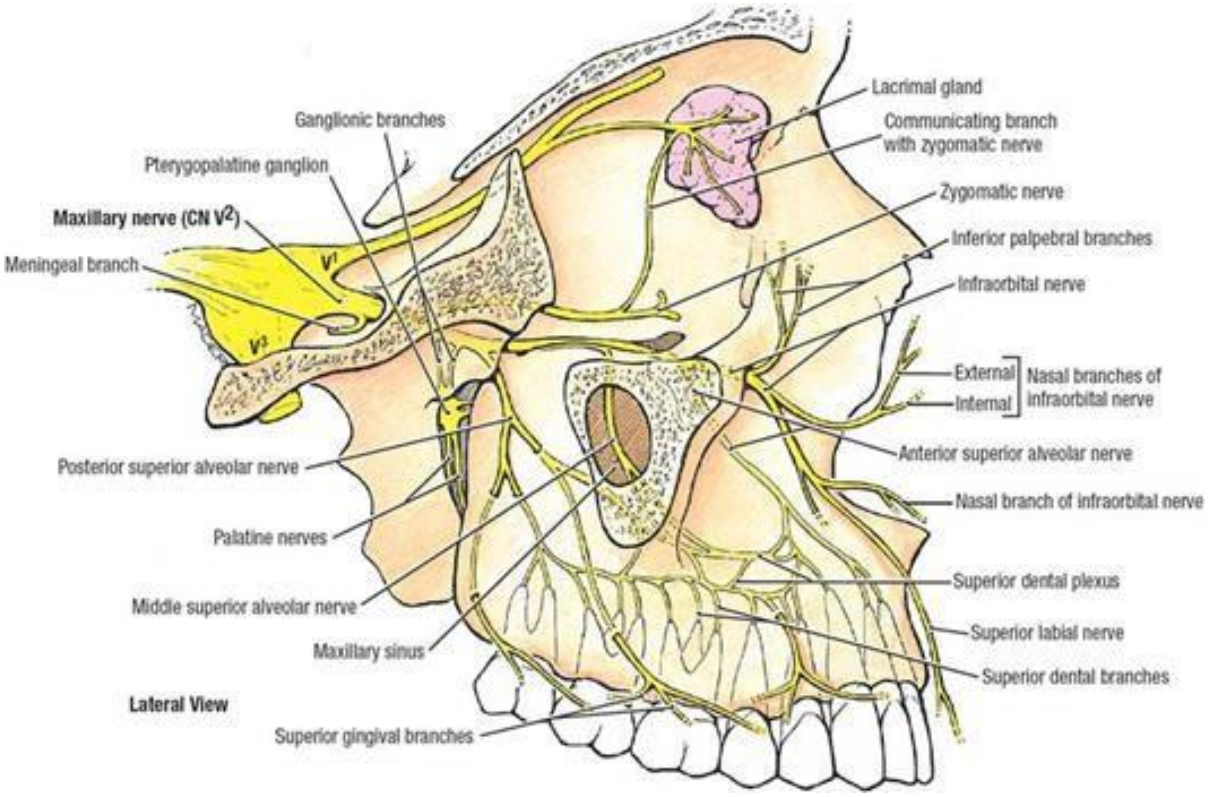

THE PTERYGOPALATINE GANGLION

This parasympathetic ganglion is situated below the maxillary nerve in the pterygopalatine fossa, connected by two ganglionic branches. It is concerned primarily with supplying the nose, palate, and lacrimal gland.

As with other parasympathetic ganglia in the head, three types of fibres enter the pterygopalatine ganglion: parasympathetic, sympathetic, and sensory fibres. However, only the parasympathetic fibres synapse in the ganglion. The preganglionic parasympathetic fibers originate from the superior salivatory nucleus in the brainstem. The fibers pass with the nerves intermedius of the facial nerve. They subsequently emerge as the greater (superficial) petrosal nerve. This occurs within the facial canal of the temporal bone, close to the geniculate ganglion of the facial nerve. The greater petrosal nerve enters the pterygoid canal . Postganglionic sympathetic fibers run to the pterygopalatine ganglion by a complex course. From the superior cervical ganglion, sympathetic fibers run to the internal carotid plexus surrounding the internal carotid artery. From this plexus, a branch called the deep petrosal nerve is given off that enters the pterygoid canal to reach the pterygopalatine ganglion. The greater petrosal nerve and the deep petrosal nerve join within the pterygoid canal to become the nerve of the pterygoid canal. The sensory fibers to the ganglion run in the ganglionic branches of the maxillary nerve.

The nerves leaving the pterygopalatine ganglion are the orbital nerve, the nasopalatine nerve, the greater and lesser palatine nerves, the posterior superior and inferior nasal nerves, and the pharyngeal nerve. The parasympathetic component will be distributed within these nerves to supply the minor salivary glands.

The parasympathetic component of the pterygopalatine ganglion is also responsible for supplying the lacrimal gland. The fibres first pass from the ganglion in one of the ganglionic branches to the maxillary nerve. They then travel with the zygomatic and zygomaticotemporal branches. Within the orbit, they pass from the zygomaticotemporal nerve to the lacrimal nerve (of the ophthalmic nerve) to reach the lacrimal gland.

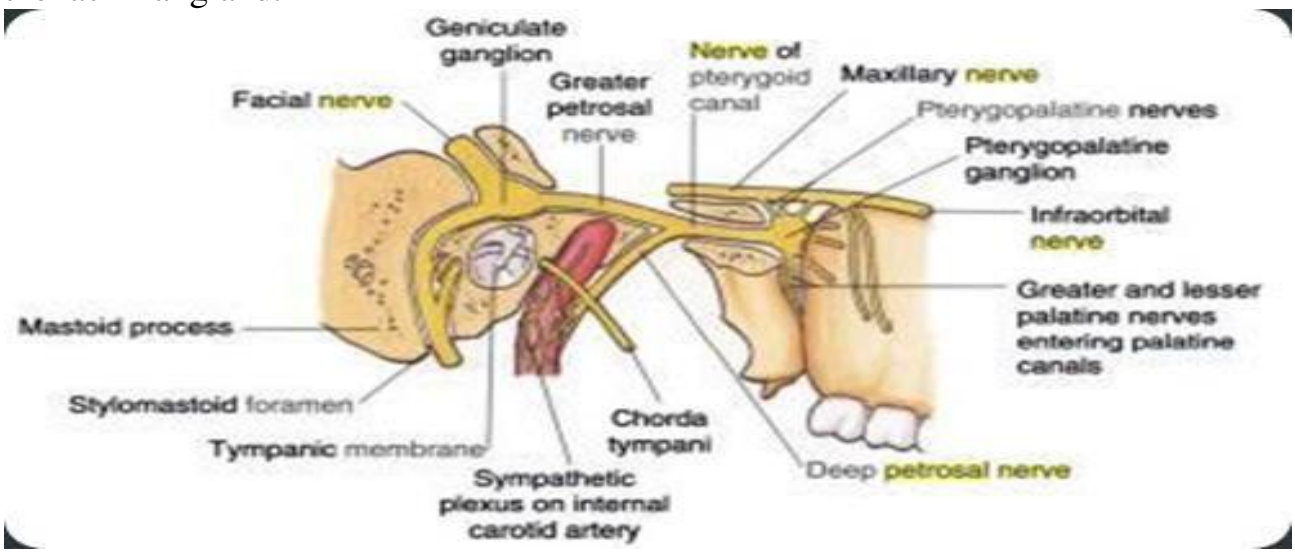

THE VEINS OF THE PTERYGOPALATINE FOSSA

The veins of the pterygopalatine fossa are small and variable. The most consistent is the sphenopalatine vein. This vein drains the posterior aspect of the nose and passes into the pterygopalatine fossa through the sphenopalatine foramen. It drains into the pterygoid venous plexus via the pterygomaxillary fissure.

The inferior ophthalmic vein in the floor of the orbit provides a connecting branch to the pterygoid venous plexus. This vein passes through the inferior orbital fissure in the region of the pterygopalatine fossa.

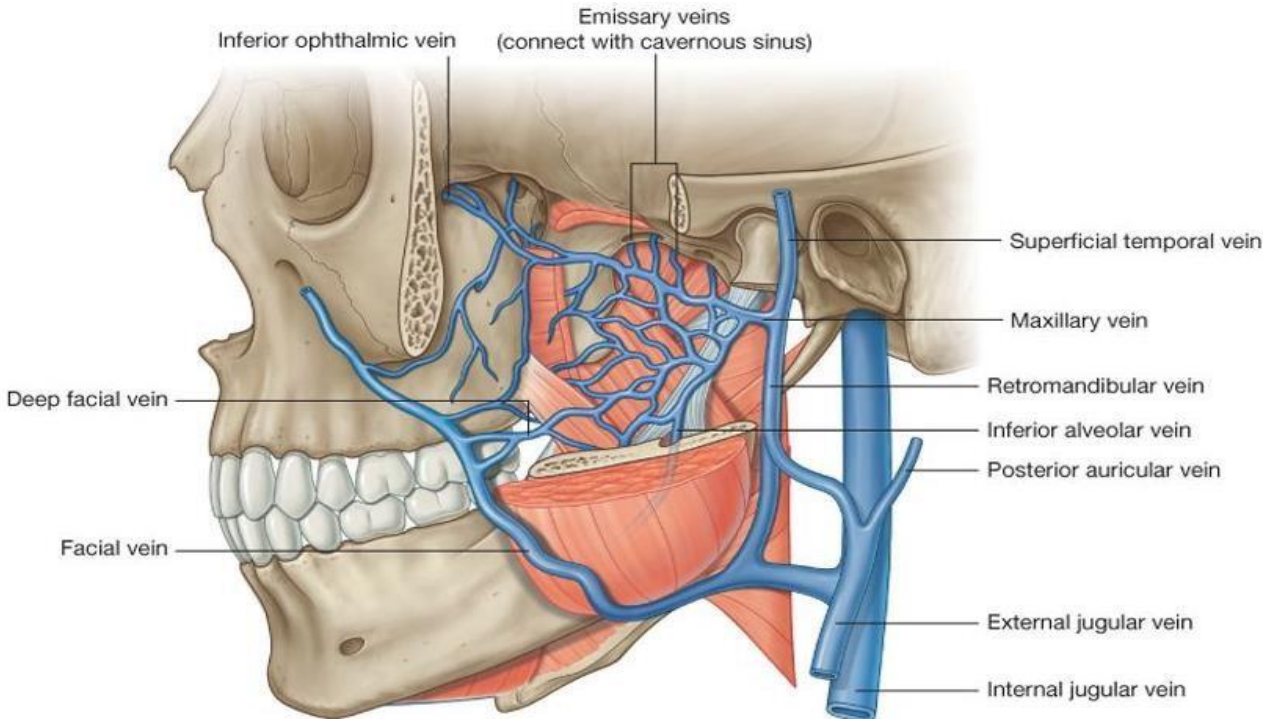
Inferior ophthalmic vein
Emissary veins
(connect with cavernous sinus)
Superficial temporal vein
Maxillary vein
Deep facial vein
Retromandibular vein
Inferior alveolar vein
Posterior auricular vein
Facial vein
External jugular vein
Internal jugular vein