Periodontium

The periodontium is defined as those tissues supporting and investing the tooth and consists of cementum, periodontal ligament (PDL) , alveolar bone and dentinogingival apparatus (that part of gingiva facing the tooth).

Periodontium

The periodontium is defined as those tissues supporting and investing the tooth and consists of:

1. Cementum
2. Periodontal ligament (PDL)
3. Bone lining the alveolus
4. Parts of the Gingiva facing the tooth



Cementum

Cementum is a mineralized dental tissue covering the anatomical part of the root.
It begins at the cemento-enamel junction and continues to the apex.
It serves as a medium for attachment of collagen fibers of periodontal ligament.
It is a hard avascular connective tissue that covers the roots of teeth.
The cementum is thinnest at its junction with the enamel and thickest at the apex.

Cementum

Cementum covers the anatomic roots of human teeth.

It begins at the cervical portion of the tooth at the cemento-enamel junction and continues to the apex.

Cementum furnishes a medium for the attachment of collagen fibers that bind the tooth to surrounding structures.

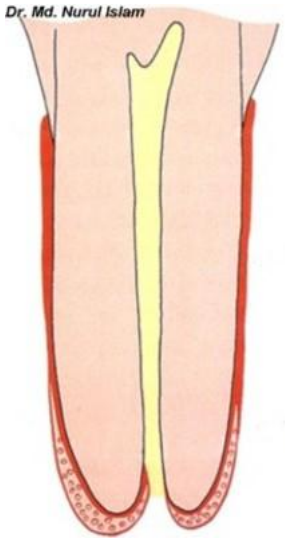

Physical properties:

1. Avascular with no nerve supply
2. **Thickness**: in cervical area 20-50 µm and is gradually increases in thickness till it reaches its maximum thickness (150-200 µm) in the apical third and at bifurcation of the root.
3. Some times cementum extends to the inner wall of the root dentin for a short distance and so lining of the root canal is formed.
4. **Color:** cementum is lightly yellow in color, lighter in color than dentin. It could be distinguished from enamel by lack of luster and dark hue.
5. **Permeability:** Cementum is permeable to a variety of materials. It is permeable from dentin side and from PDL side.

Chemical properties:

1. Organic substance (50-55%):
   a. .It is mainly in a form of collagen type I(33%). The collagen of cementum is similar to that of PDL and bone. The origin of collagen is coming from two sources:
      i. Intrinsic: synthesized by cementoblast during the process of cementogenesis.
      ii. Extrinsic: As Sharpey's fibers which represent the periodontal ligament fibers inserted inside the cementum during early phases of cementogenesis before the calcification of the cementoid.

   b. Proteoglycans

Dr. Akram Yousif Yasear

2. Inorganic substance (45-50%):The inorganic substances consists mainly of calcium and phosphate ions in a form of hydrixyapatite crystals. The cementum also contains the greatest amounts of fluoride in all mineralized tissue.

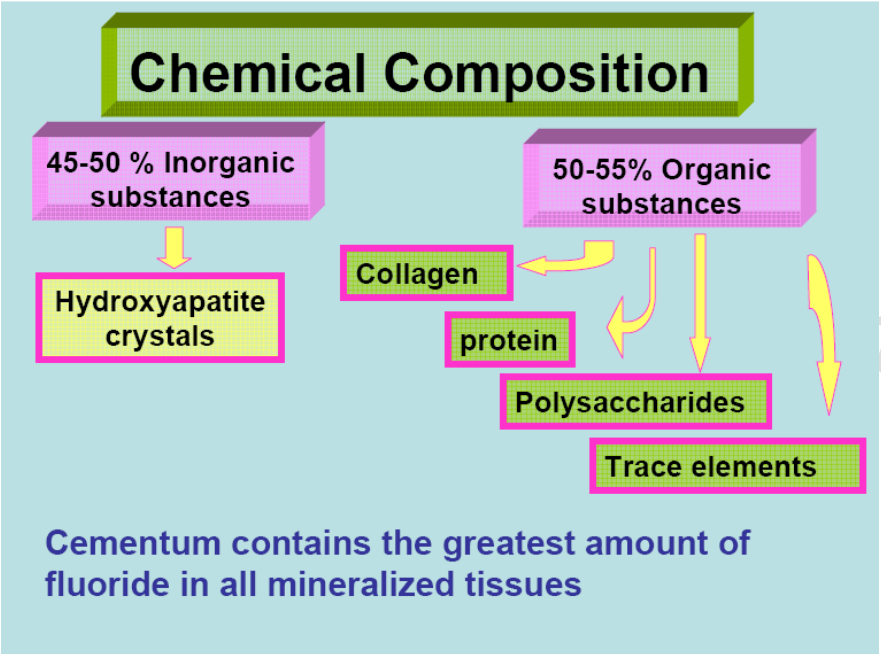

Types of cementum:

There are three types of cementum:

i. **Acellular cementum:** It is layed down mainly in the cervical area of the root. It covers the dentin starting from the cementoenamel junction to nearly two third of the root. As the first formed cement during the process of root formation. The Acellular cementum represents the main site of the PDL fibers attachment.

ii. **Cellular cementum:** It is layed down after eruption and throughout life and is located in the apical one third of the root and in the interradicular region of the root. It has the same structure as the acellular cementum, but contains cells (cementocytes).The cementocytes are cells incorporated into cellular cementum, these cells are similar to the osteocytes of the bone. The cementocytes have processes, the cementocytes cell bodies lie inside lacunae, while their processes present inside canaliculi.Most of these processes are directed toward the

periodontal surface of the cementum to provide nutrition for the cementocytes. Cementocytes present in the deepest layer of cementum shows signs of degeneration.

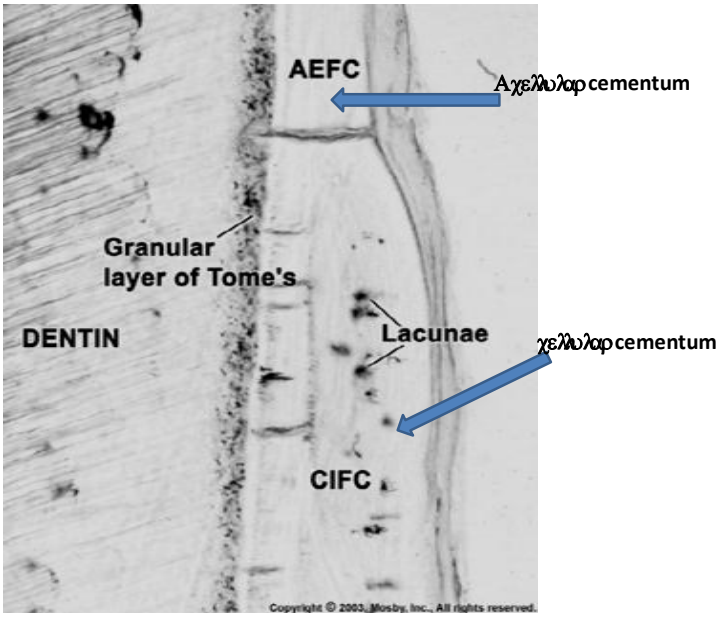

iii. **Afibrillar acellular cementum:** It is limited to part of the enamel close to the cementoenamel junction. It lacks collagen so plays no role in attachment. It is formed when part of the reduced enamel epithelium degenerates at its cervical termination permitting the undifferentiated ectomesenchymal cells of the dental follicle to come in direct contact with the enamel surface. The undifferentiated cells differentiate into cells that produce calcified material to covers cervical end of the enamel surface close to the cementoenamel junction.

Comparison between cellular cementum and acellular cementum:

Cellular cementum	Acellular cementum
1.Has cells(cementocytes)	**1.Has no cells**
2.Formed rapidly after eruption	**2. Formed slowly before eruption.**
3. Its matrix contains intrinsic (from Cementoblasts) and fewer extrinsic fibers originate from PDL.	**3. Its matrix contains mainly extrinsic fibers from PDL.**
4. Offers very little sites for PDL fibers	**4.Principle site for PDL fibers attachment**
5. Seen in apical one third of the root.	**5. Seen in coronal two third**

Comparison between bone and cementum:

Bone	cementum
1.Vascular **2.Has nerve supply** **3. Normally undergo remodeling and resorption.** **4. Has collagenous protein.** **5. Has incremental lines called rest lines and reverse lines.** **6. Has cells called osteocytes present inside lacunae.**	**1. Avascular** **2.Has no nerve supply** **3. More resistance to resorption or remodeling permitting orthodontic tooth movements.** **4. Has collagenous protein** **5. Has incremental lines called Salter's lines.** **6. Has cells called cementocytes present inside lacunae**

Incremental lines:

Both cellular and acellular cementums are having incremental lines called incremental lines of Salter's, which indicate periodic formation of the cementum. These lines are highly mineralized areas with less collagen and more ground substance.

Intermediate cementum: Is the first thin 10 um thickness layer of cementum which is actually formed by the inner cells of the epithelial root sheath and is deposited on the root's surface. Intermediate cementum is situated between the granular dentin layer of Tomes and the secondary cementum that is formed by the Cementoblasts (which arise from the dental follicle). It does not resemble neither dentin nor cementum. It is usually present in the apical two thirds of the root of molars and premolars rarely seen in incisors or deciduous teeth.

Cementoenamel junction:

The relation between cementum and enamel at the cervical region of the tooth is variable.

i. In 30% of all teeth, cementum meets the cervical end of the enamel (edge to edge).
ii. In 10% of the cases there is a gap between the enamel and cementum leading to the exposure of the dentin .This occurs when the epithelial root sheath is delayed in its separation from the dentin leading to the formation of a zone of the root devoid of cementum

Dr. Akram Yousif Yasear

iii. In about 60% of the teeth the cementum(afibrillar acellular cementum) overlaps the cervical end of enamel for short distance.

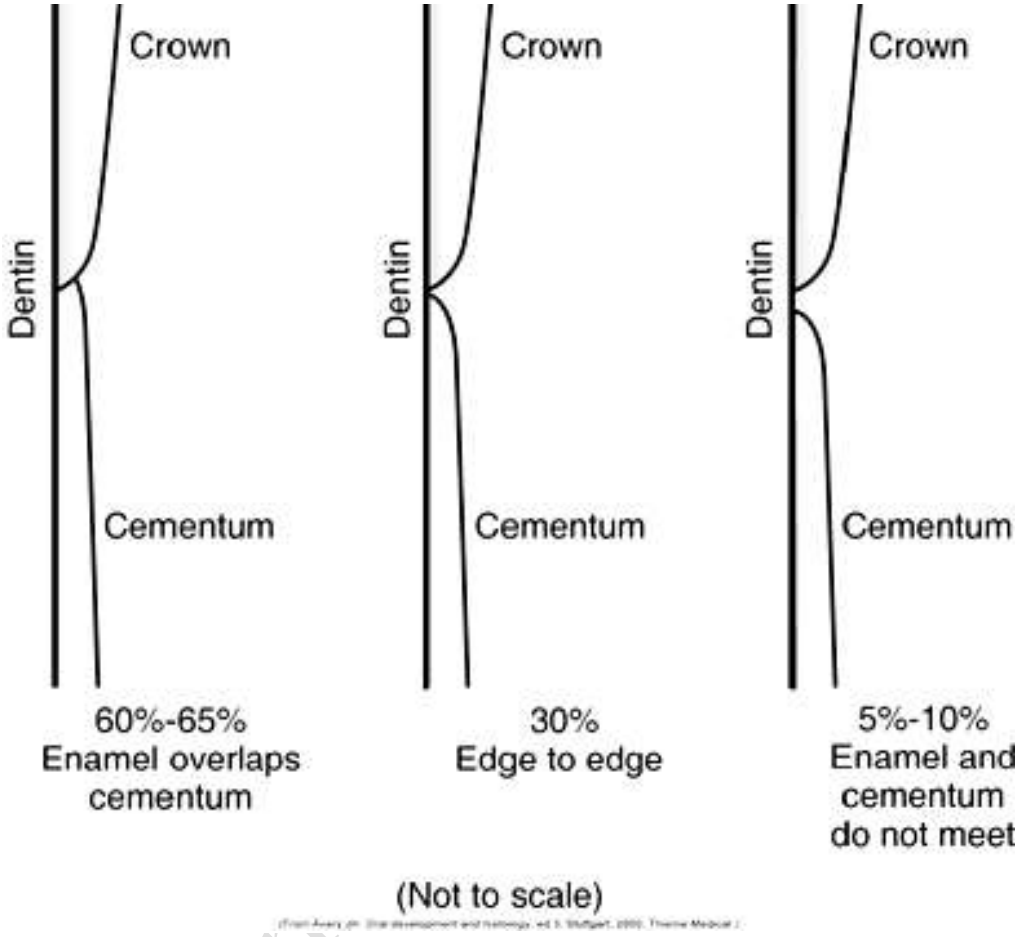

Cemento-dentinal junction:

It is relatively smooth in permanent teeth, but in deciduous teeth it is scalloped.

Dr. Akram

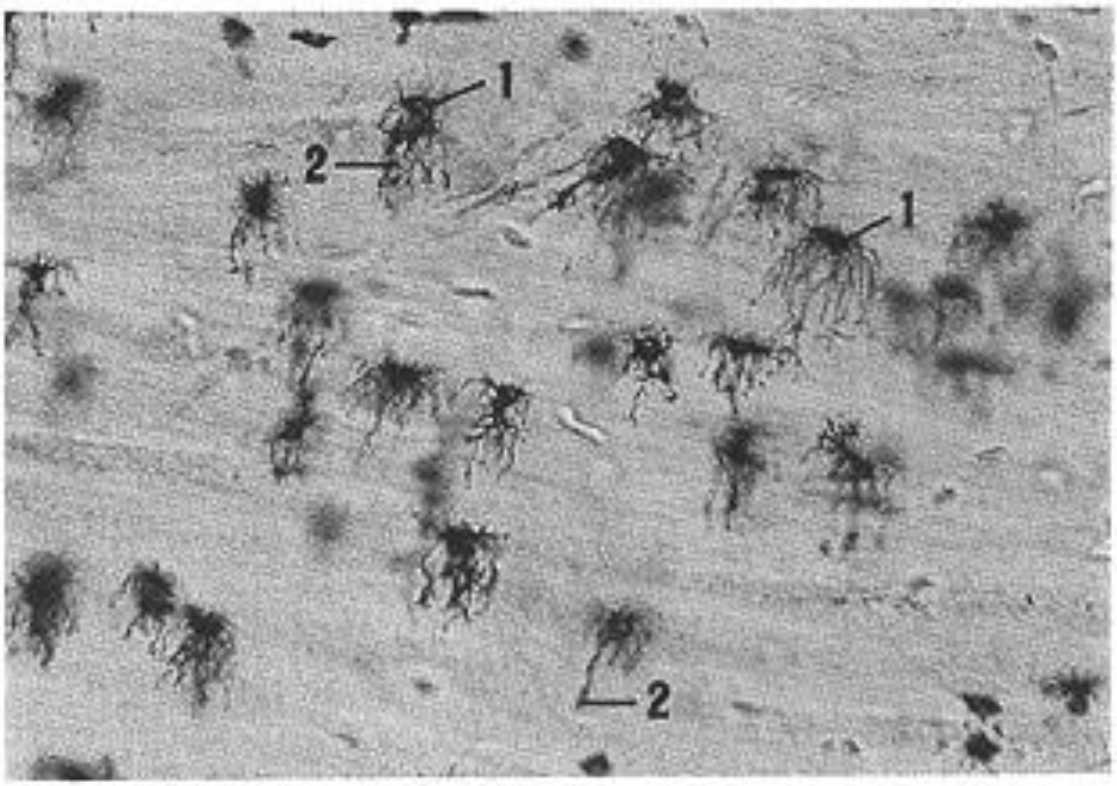

The figure is showing the direction of cementocytes lacunars canalculi towards the PDL

Functions of the cementum:

1. It provides attachment for the periodontal fibers to bind the tooth to the alveolar bone.
2. It covers and protects the root dentin (covers the opening of dentinal tubules)

3. The continuous formation of the cementum keeps the attachment apparatus intact.
4. Cementum deposition apically compensate for the occlusal wear in the enamel.
5. Cementum serves as a major reparative tissue for the root surface damage as fracture or resorption can be repaired by deposition of new cementum.

Cmentogenesis(Development of Cementum):

Cementogenesis is a continuous process throughout the life of the tooth. This comprises

1. Matrix formation
2. Mineralization.

Dr. Akram Yousif

1. Matrix formation :

i. The development of the root begins after the crown is formed. The outer and inner enamel epitheliums form the epithelial root sheath of Hertwig.
ii. The inner enamel epithelium will induce the neighboring cells of dental papilla to differentiate into odontoblasts. Odontoblasts start deposition of dentin in a similar manner to that of the crown.
iii. Once the dentin formation is started , the epithelial root sheath will loosen its continuity allowing the recently formed dentin to be in direct contact with the ectomesenchymal cells of dental follicle. The remnant of the epithelial root sheath become the rest cells of Malassez found in the periodontal ligament of the fully formed root.
iv. The ectomesenchymal cells of the dental follicle, adjacent to the dentin, will differentiate into cementoblasts.
v. The cementoblasts have the character of protein secreting cells.

vi. The cementoblasts first layed down the **cementum matrix which is called cementoid.**

vii. The main constituent of the matrix is collagen , which made up the major part of organic matrix of cementum ,also the cementoblasts produce the ground substance.

viii. Growth of the cementum is a rhythmic process and as a new layer of cementoid is formed, the old one calcifies. A thin layer of cementoid can usually be observed on cemental surface which is is covered by cementoblasts.

2. Mineralization:

i. Mineralization occurs after some matrix production has taken place.
ii. The mineral crystals of calcium and phosphate ions are deposited within and on the surface of and between the collagen fibers.

Dr. Akram Yousif Yasear

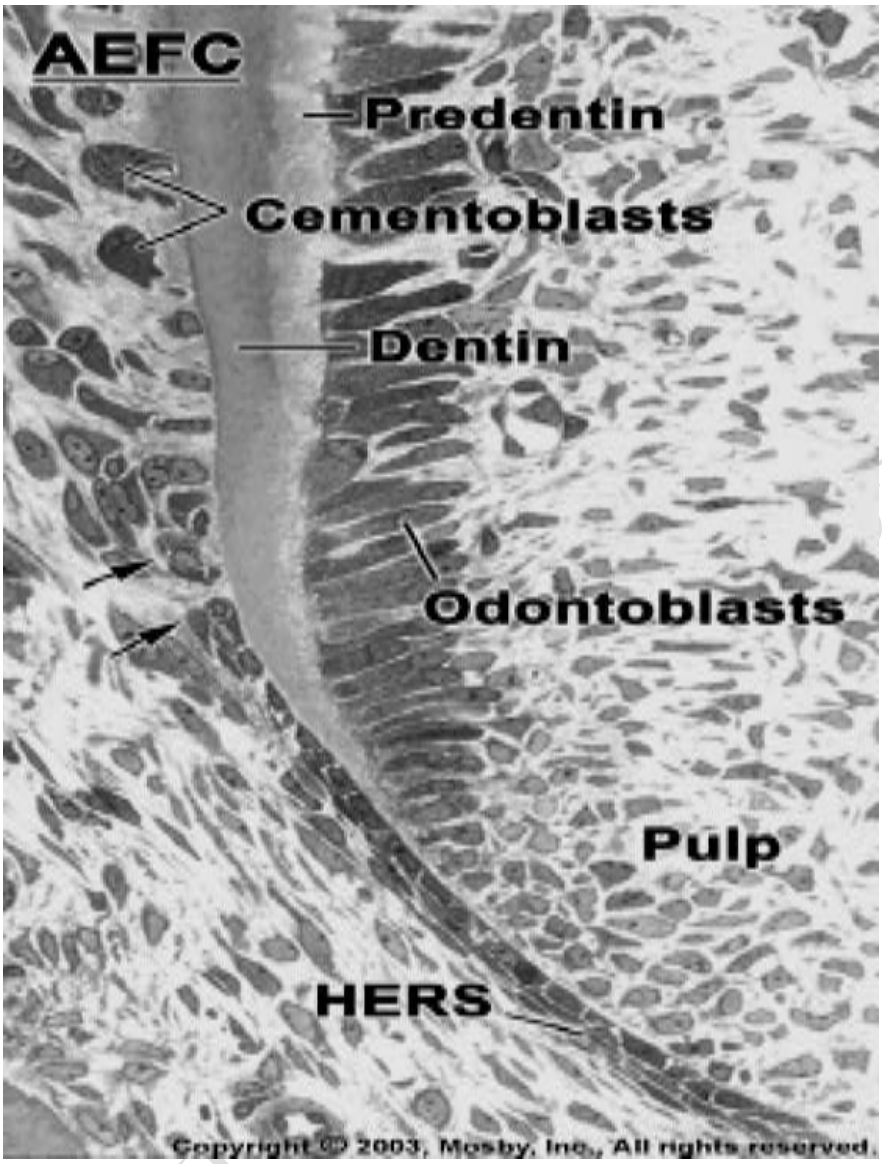

Age changes of the cementum

1. Hypercementosis

It is abnormal thickening of the cementum. It may affect one tooth or may be generalized in all teeth. Hypercementosis, also it is either limited to small area of the root or through the whole root length. When the increase in thickness of cementum occurs in good functioning tooth, it could be considered as a response to improve the functional quality of through increasing the root surface areas and thus permitting more periodontal ligament fibers to be attached to the root, this is termed cementum **hypertrophy.**

But if the growth occurs in nonfunctioning teeth or the increase occurs in embedded teeth this is called cementum **hyperplasia.**

Hyperplastic cementum in nonfunctioning teeth is characterized by the absence of Sharpey's fibers.

2. Permeability:

By the age the permeability of the cementum decreases gradually



Cementicles

Cementicles are small-mineralized bodies, which may be found in the periodontal ligament.

They may be attached to the cementum or the alveolar bone, or occur free in the periodontal ligament. When present, cementicles are generally found about all or most of the teeth.

Cementicles may be formed by mineralization of degenerating epithelial rests or thrombosed vessels.

