Dental Anatomy

- د. سجاد عذاب شويل

Lecture -1

Introduction

Nomenclature

Dense = tooth

Dental = anything related to teeth

Man is a **heterodent**, which means that he has different-shaped teeth.

Man is a **diphyodont**, which means that he has two sets of teeth; deciduous teeth (primary teeth) and permanent teeth.

The Deciduous Teeth

At birth, there are no teeth present in the mouth, but many teeth in various stages of development are found in the jaws.

After birth (post-natal period), the eruption of deciduous teeth starts at six months and lasts until two and a half years.

The deciduous teeth stay until the permanent teeth erupt at about 6 years of age, when the transition to the permanent dentition begins.

The deciduous teeth are 20 in number. They have the following formula:

$$I\frac{2}{2}\ C\frac{1}{1}\ M\frac{2}{2} = 10 \text{ (for each side)}$$

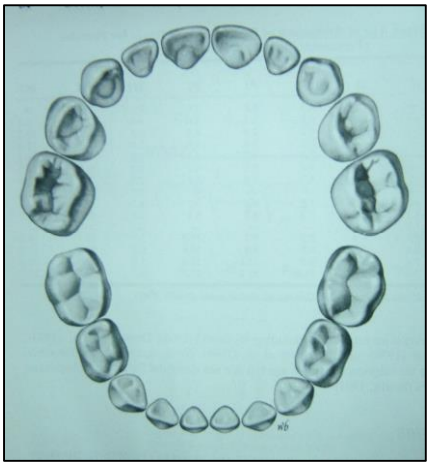

I = Incisors (central and lateral).

C = Canine.

M = Molars (first and second).

The Permanent Teeth

The transition to permanent dentition begins with the emergence and eruption of the first permanent molars at the age of six years, followed by shedding of the deciduous teeth and emergence and eruption of the remaining permanent teeth. This process requires about 20 years to be completed. The number of permanent teeth, including third molars when present, is 32.

$$I\frac{2}{2}\ C\frac{1}{1}\ P\frac{2}{2}\ M\frac{3}{3} = 16 \text{ (for each side)}$$

I = Incisors (central and lateral).

C = Canine.

P = Premolars (first and second).

M = Molars (first, second and third).

Anterior and Posterior Teeth

Teeth are grouped into:

1. Anterior teeth which include the incisors and the canines.
2. Posterior teeth which include the premolars and molars.

The Jaw

The jaw is the bone which carries the teeth. There are two jaws:

1. The upper jaw, which is fixed, and is called “The Maxilla”.
2. The lower jaw, which is movable, and is called “The Mandible”.

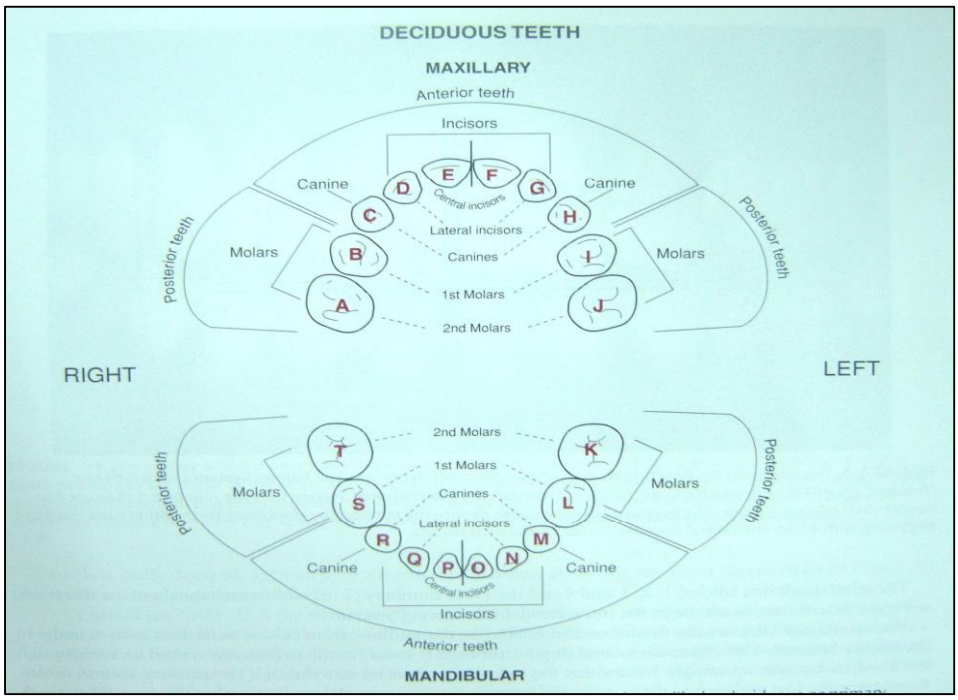
DECIDUOUS TEETH
MAXILLARY
Anterior teeth
Incisors
Canine
Canine
Central incisors
Lateral incisors
Canines
1st Molars
2nd Molars
Posterior teeth
Molars
Molars
Posterior teeth
RIGHT
LEFT
2nd Molars
1st Molars
Canines
Lateral incisors
Central incisors
Canine
Canine
Incisors
Anterior teeth
MANDIBULAR

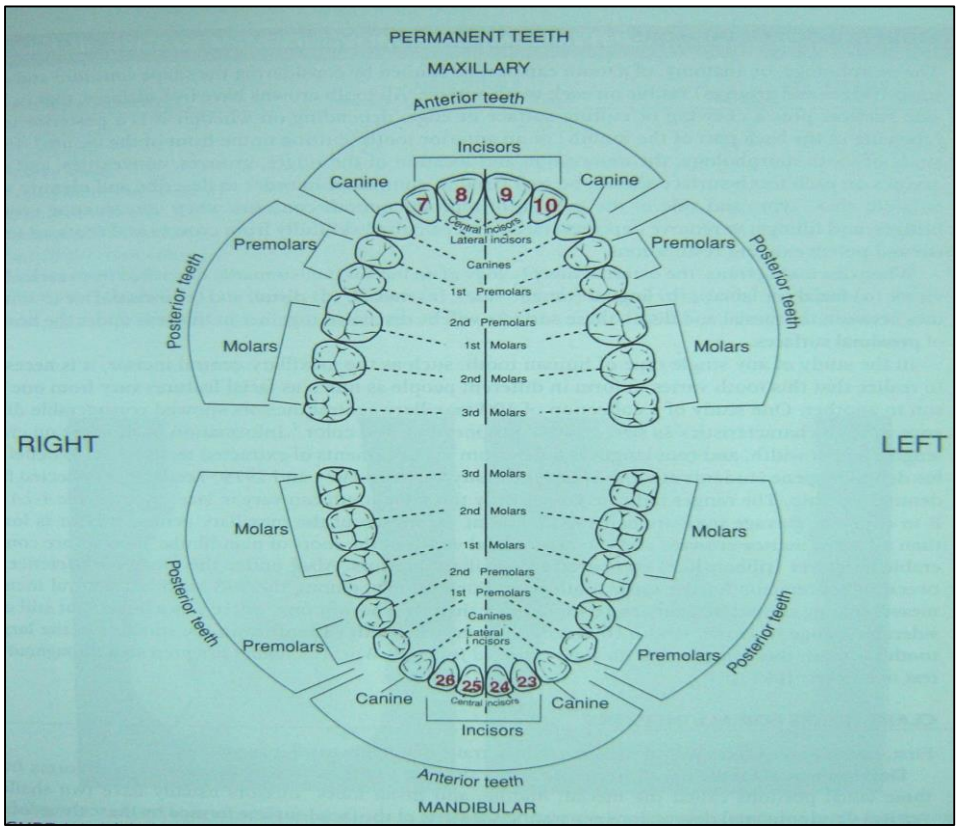
PERMANENT TEETH
MAXILLARY
Anterior teeth
Incisors
Canine
Canine
Central incisors
Lateral incisors
Canines
1st Premolars
2nd Premolars
1st Molars
2nd Molars
3rd Molars
Premolars
Premolars
Posterior teeth
Posterior teeth
Molars
Molars
RIGHT
LEFT
3rd Molars
2nd Molars
1st Molars
2nd Premolars
1st Premolars
Canines
Lateral incisors
Central incisors
Molars
Molars
Premolars
Premolars
Canine
Canine
Incisors
Anterior teeth
MANDIBULAR