Dental Anatomy

Dr. Sajad A. Shwaiel

Dental Anatomy

Lecture 5

Dr. Sajad A.Shwaiel

Permanent Maxillary Lateral Incisors



The maxillary lateral incisor resembles the maxillary central incisor in function, form and anatomy, but is generally smaller in all dimension except the length of the root.

Principle Identifying Features:

Dental Anatomy

1. The crown is more rounded, shorter and narrower mesio-distally than the maxillary central incisor.
2. The mesio-incisal angle is acute and the disto-incisal angle is more rounded.
3. It has a single root with a tapered, distally curved, pointed apex.
4. The lingual fossa is more concave than that of the maxillary central incisor.

Labial Aspect:

1. The crown is shorter and narrower than that of the maxillary central incisor, but the root is as long as that of the maxillary central incisor or longer.
2. The labial surface of the crown is more convex than that of the maxillary central incisor.
3. The mesial outline resembles that of the maxillary central incisor with more rounded mesio-incisal angle, with the crest of curvature (contact point) located between the middle and incisal thirds.
4. The distal outline is more rounded, with the crest of curvature (contact point) at the center of the middle third.
5. The root tapers evenly, and curves distally at the apex.

Mesial Aspect:

1. The crown is narrower labio-lingually than the maxillary central incisor.
2. The curvature of the cervical line is less than that of the maxillary central incisor.
3. The root appears as a tapered cone, and a line bisecting the root bisects the incisal ridge, which is well developed.

Distal Aspect:

1. The curvature of the cervical line is less than that mesially.
2. It is not uncommon to find a developmental groove extending to the root.

Lingual Aspect:

1. The mesial and distal marginal ridges and the lingual portion of the incisal ridge are well marked with a more concaved lingual fossa.
2. The cingulum is prominent, with a tendency toward seeing a deep developmental groove within the lingual fossa.

Dental Anatomy

Incisal Aspect:

1. The incisal aspect resembles that of the maxillary central incisor, but:
   - **A.** The cingulum and incisal ridge may be large.
   - **B.** The labio-lingual to mesio-distal measurement is larger, therefore, it resembles as a small canine.
2. From the incisal aspect, all maxillary lateral incisors exhibit more convexity labially and lingually.

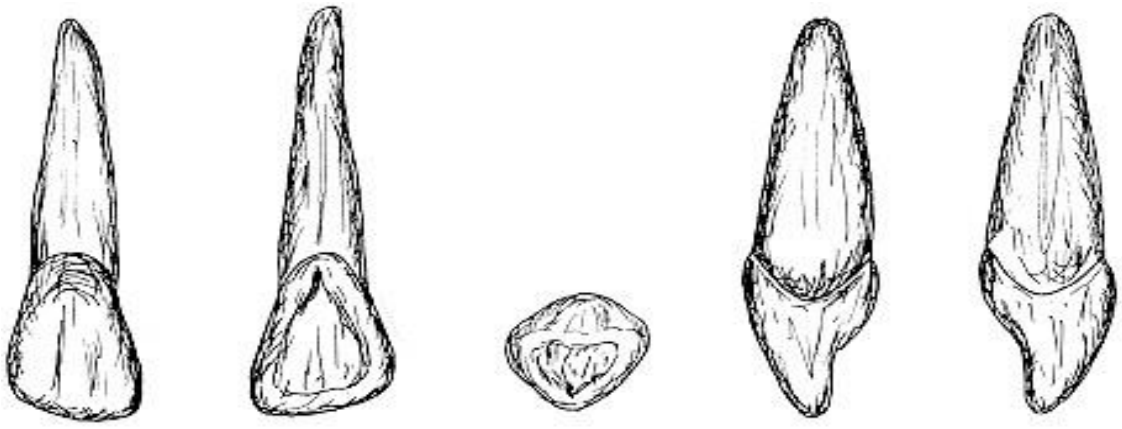

Maxillary Right Permanent Lateral Incisor

Variations from the typical form(anomalies)

1.Peg- shaped lateral incisor, with a thin root and a small conical crown.

2.The maxillary lateral incisor may be congenitaly missing.

3.Large developmental groove on the distal aspect extending to the root.





Dental Anatomy

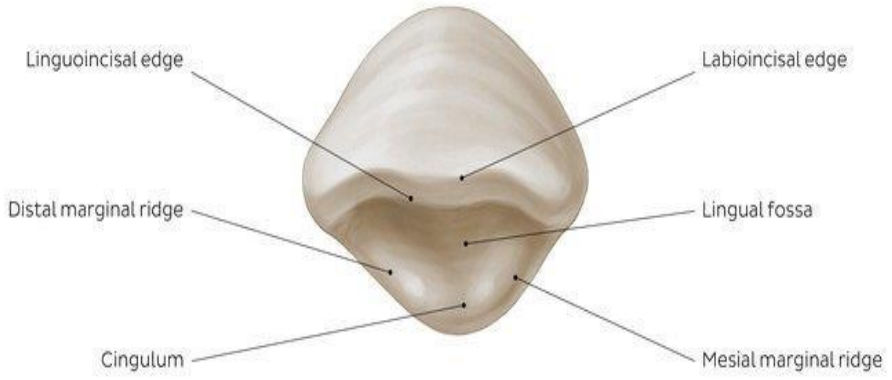

Main Differences between Maxillary Central AND Lateral Incisor

Aspect	Maxillary Central Incisor	Maxillary Lateral Incisor
Labial Aspect	1. The crown is longer and wider mesio-distally. 2. Mesial outline is slightly convex with a crest of curvature near the mesio-incisal angle. 3. Distal outline is more convex than mesial outline with the crest of curvature closer to the middle third. 4. The root is shorter with a cone shaped and blunt apex.	1. The crown is shorter and narrower. 2. Mesial outline is similar to the maxillary central incisor with acute and more rounded mesio-incisal angle with the crest of curvature at the junction between middle and incisal thirds. 3. Distal outline is more rounded and the crest of curvature is at the center of the middle third. 4. The root is longer than maxillary central incisor, tapers evenly and curves distally in a pointed apex.
Mesial Aspect	5. The crown is wider labio-lingually with a pronounced curvature of the cervical line.	5. The crown is narrower labio-lingually with the curvature of the cervical line less pronounced.
Distal Aspect	6. No developmental groove extending to the root.	6. A developmental groove extending from the side of the cingulum to the root may be found.
Lingual Aspect	7. Well defined lingual anatomical features.	7. More prominent cingulum with a more concave lingual fossa.

Dental Anatomy

End