Dental anatomy

Lecture (6)

Dr. Sajad A. Shwaiel

Permanent Canine General Characteristic Features of the Canines

1. The canines are placed at the "corners" of the mouth, which help in keeping facial expressions at the cosmetic value.
2. The canines are the longest teeth in the mouth.
3. The canines are the strongest teeth in the mouth.
4. The canines are the most stable teeth in the mouth because of the followings: -

-They have large labio-lingual dimension.

-They have long roots, which are well anchored in the alveolar bone.

-The crown shape of the canine allows for "self-cleansing", so they stay for longer time.

5. The middle labial lobe is highly developed incisally into a strong, well-formed cusp.



The Permanent Maxillary Canine

Principal Identifying Features

1. Single pointed cusp.
2. The distal slope of the cusp is longer than the mesial slope.
3. Marked convex labial outline and bulky palatal cingulum.
4. Very long single root.

The Labial Aspect

1. The mesial outline of the crown is convex from the cervical line to the crest of curvature, which is located at the junction of the incisal and middle thirds.
2. The distal outline of the crown is slightly concave from the cervical line to the crest of curvature, which is located at the center of the middle third.
3. The tip of the cusp is in a line with the center of the root.
4. The distal slope of the cusp is longer than the mesial slope.
5. The cervical line is convex toward the root.
6. The labial surface is smooth except for a shallow depression mesially and distally dividing the three lobes, with the middle one much more developed producing the labial ridge.
7. The root is long and conical, with the apex curved distally.

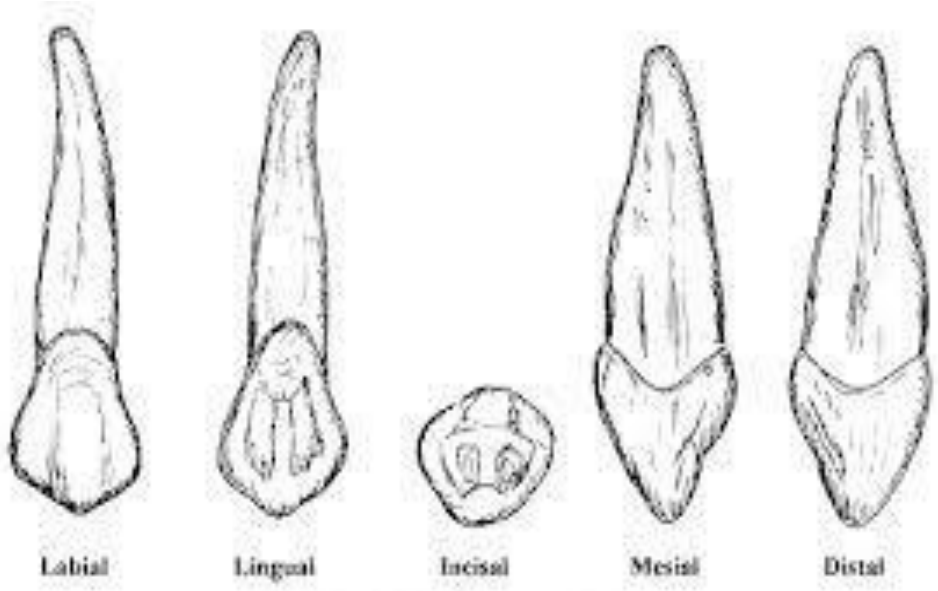

Maxillary Right Permanent Canine

Lingual Aspect

1. The tooth is narrower lingually than labially (i.e., tapered lingually).
2. The cingulum in the maxillary canine is larger than that in the maxillary central and lateral incisors.
3. There is a well-developed lingual ridge confluent with the cusp tip, which divides the lingual fossa into two fossae.
4. There is a developmental depression mesially and distally extending for most of the root length.

Mesial Aspect

1. The labial and lingual outlines of the crown are more convex than that in the maxillary central and lateral incisors, with the crest of curvature (labially and lingually0 located at the cervical thirds.
2. The curvature of the cervical line is 2.5mm towards the cusp.
3. A line bisecting the cusp is labial to a line bisecting the root.
4. There is a developmental depression extending on part of the root.

Distal Aspect

1. The curvature of the cervical line is less distally than mesially (as in the maxillary central and lateral incisors).
2. The developmental depression of the root is more pronounced distally than mesially.

Incisal Aspect

1. The labio-lingual dimension is greater than the mesio-distal dimension.
2. The ridge of the labial lobe is very noticeable labially, with its greatest convexity at the cervical third.
3. The cingulum is well developed and makes a small are when compared with the labial outline which makes a large are.
4. The tip of the cusp is labial to the center labio-lingually, and at or slightly mesial to the center mesio-distally.

The Permanent Mandibula Canine

Principal Identifying Features

1. The mandibular canine is narrower mesio-distally and labio-lingually than the maxillary canine.
2. The lingual surface of the crown of the mandibular canine is shorter than that of the maxillary canine, with less developed cingulum and less prominent marginal ridges.
3. The cusp of the mandibular canine is not as well-developed as that of the maxillary canine.
4. The tip of the cusp is not in a line with the center of the root.
5. The mesial slope of the cusp is shorter than the distal slope.
6. The distal outline of the crown is more rounded than the mesial outline.
7. The mesial surface of the crown is nearly straight with the mesial surface of the root, with the contact area being near the mesio-incisal angle.
8. The distal contact area is located more incisally than the maxillary canine.

