# DENTIN

## General features:

**Dentin** form the bulk and general form of the tooth, it is present in both the crown and root.
It is characterized by presence of dentinal tubules (**as structural units of dentin**).
The odontoblasts (the cells forming the dentin) are found in the pulp and not in the dentin.
Dentin is laid down throughout the life of the tooth.

The dentin is the first hard tissue to be formed during the period of tooth development.
It is ectomesenchymal in origin developed from the cells of the dental papilla.
Unlike the enamel which is not considered as a true tissue because it is a product of epithelial cells (ectodermal in origin).
The **dentin is** considered as **a living true tissue** because it is containing ground substance, collagen type I (produced by odontoblasts) and an extension from the odontoblasts inside the dentinal tubules called odontoblastic processes.
Dentin is enclosing the pulp with which it shares a common origin from the dental papilla.
Thus the dentin and the pulp can be considered as a single development and functional unit, often described as the **dentin-pulp complex.**
The dentin of primary teeth is less hard than that of permanent teeth.
**The dentin ranges in thickness from 3-10 mm.**
The method to examine the dentin is through the use of ground sections.

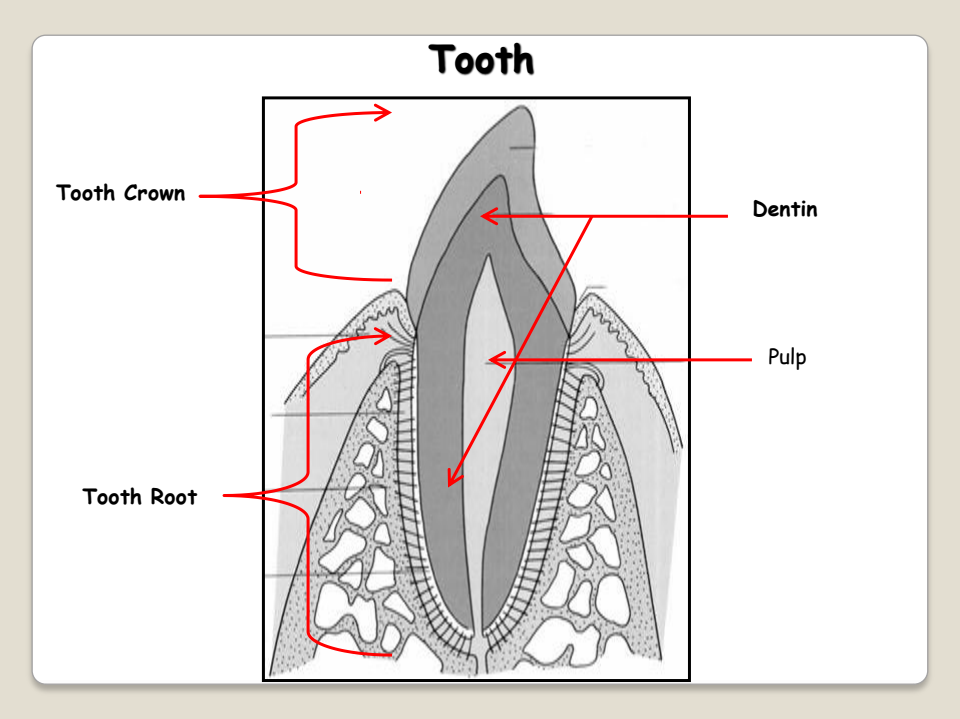

## Physical properties:

It is pale yellow in color. Because the enamel is translucent, the dentin gives the crown of the tooth its color. It is less hard than enamel but harder than either cementum or bone.

**Chemical properties:**

Dentin consists of 30% organic matter and water; and 70% inorganic material.
The organic material consists of:
Collagen fibril (type I)

**Similarity with the bone:**

a. growth by apposition
b. Hydroxy apatite crystals of similar dimension.
c. Presence of canilicular system
d. Presence of extracellular fluid.
e. The organic matrix made of collagen.

**Differences from the bone:**

a. Dentin is not vascular as the bone
b. Bone is highly cellular containing the cell bodies (osteocytes) and their processes; dentin is acellular.

**Histological structural features of the dentin**:

When the dentin is viewed microscopically, several structural features can be identified: dentinal tubules, peritubular and intertubular dentin, areas of deficient calcification (called interglobular dentin), incremental growth lines, and granular layer of Tome's (in the root only).

**Dentinal tubules: These are** the unit structure of the dentin that traverse the entire thickness of the dentin from the dentinoenamel junction to the pulp .They are containing the odontoblastic processes, and their configuration indicates the course taken by the odontoblasts during dentinogenesis. The course of dentinal tubules resembles a gentle **S** in shape. The presence of these tubules is making the dentin as highly permeable tissue.

**The** ratio between outer and inner surfaces area of the dentin is about **5:1**.
**The** dentinal tubules are **1-4 µm** in diameter .
**The** ratio between the numbers of tubules on the pulpal: outer surface of dentin is 4:1. Near the pulpal surface of dentin the number of dentinal tubules is between 50000-90000 $mm^2$. Near the dentinoenamel junction the number is about 15000/$mm^2$.
**The** dentinal tubules have lateral branches throughout dentin termed canaliculi. These canaliculi are 1µm or less in diameter. Few dentinal tubules extend through DEJ into the enamel for several millimeters as **enamel spindles**.
**One $mm^2$ cavity preparation in the tooth exposes 30000 dentinal tubules.**
Nearest the DEJ (within the mantle dentin) the dentinal tubules demonstrate a **terminal bifurcation.** The dentinal tubules show a tapered morphology, being wider nearest the odontoblastic cell body than at the DEJ.

The dentinal tubules are lined, throughout their length, by a narrow zone of hypermineralized substance known as peritubular dentin.

**Dentinal tubules**

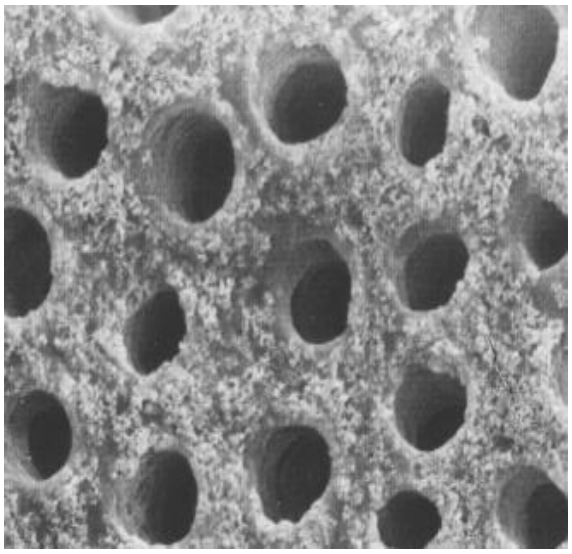

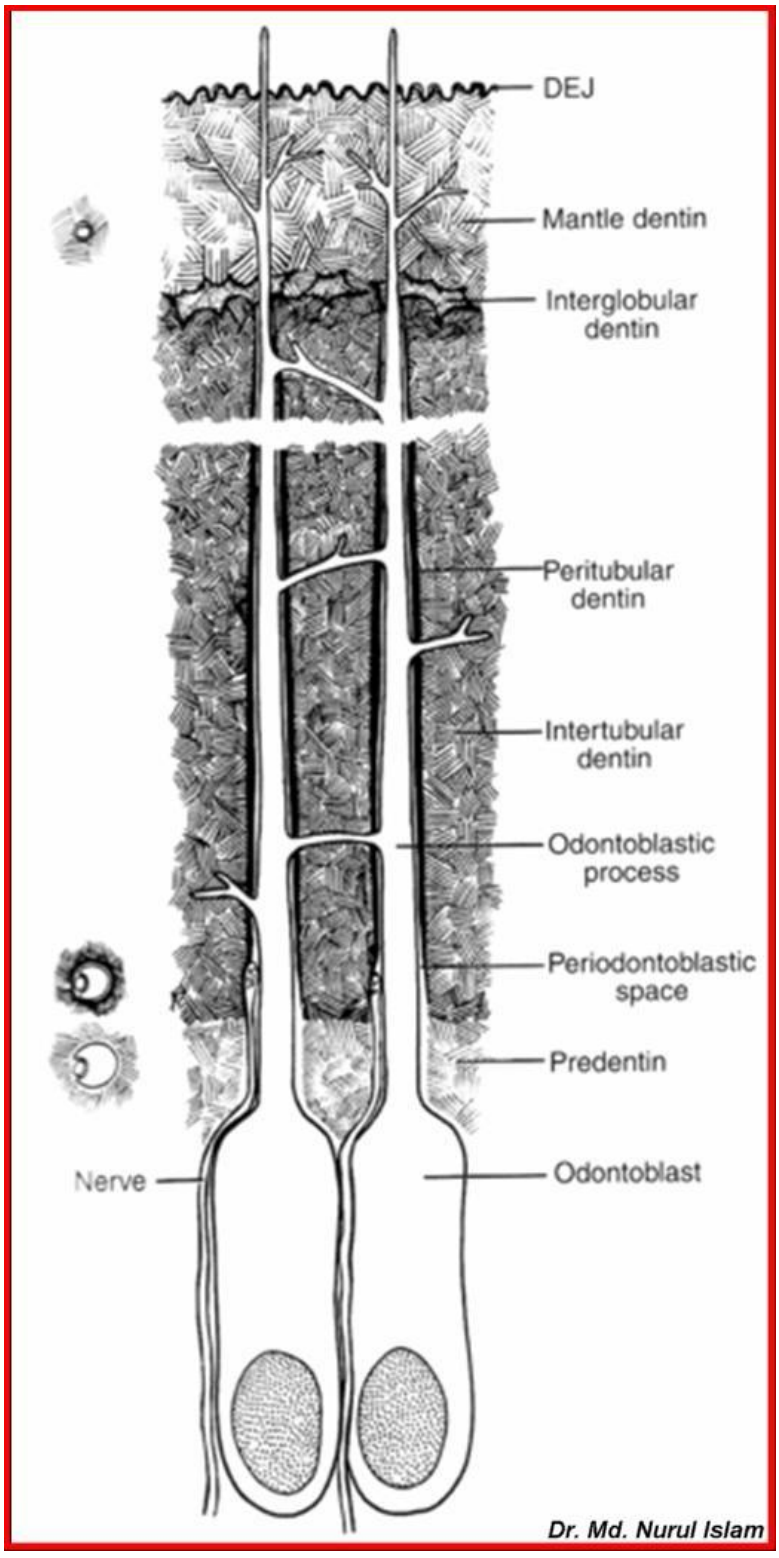


***Fig.40: Odontoblasts and their processes .The dentinal tubule has tapered end.***

**The content of dentinal tubules:**

**1.** Odontoblastic process, 2. Unmylinated nerve fiber which does not extends along the full length of the tubules for up to 0.2 mm only, 3. Circulating extracellular fluid, 4.collagen fibers, 6. Hydroxyapatite crystals.

**The presence** of patent (open) dentinal tubules renders the dentin to be permeable to:

1. Microorganisms and their products.
2. Cell debris from degenerated odontoblastic process.
3. Various dental restorative materials, which can permeate to the pulp and thus produce pulpal injury.

**N.B. : The elasticity of dentin is depending on:**

1. Presence of odontoblastic process inside dentinal tubules.
2. High amount of organic matter
3. Presence of tissue fluid inside dentinal tubules.

**The intertubular dentin:**

The name of the dentin between the dentinal tubules is called the intertubular dentin. It is forming **the bulk of the dentin** structure formed during the process of dentinogenesis. It is less calcified by 9% than the peritubular dentin

**Peritubular dentin:**

It is also called intratubular dentin. It is deposited inside the dentinal tubules, surrounding the periodontoblastic spaces of dentinal tubules. Thus it forms the lining of the inner wall of dentinal tubules. There is more peritubular dentin in the crown than in the root. Peritubular dentin is more mineralized than intertubular dentin by 9% (hypercalcified). Its formation starts as soon as the first formed 60-100 µm thickness of dentin is completely mineralized.

**Its matrix is not collagenous**, but contains mucopolysaccharides as organic matrix. At the time of primary dentin formation is completed all peripheral tubules have a lining of peritubular dentin. Peritubular dentin is absent in area of interglobular dentin area. Its formation and deposition is a continuous process and often fills completely the dentinal tubules. The filled tubules are prominent in the root dentin to form the sclerotic dentin.

**Types of dentin:**

**There are** three types of dentin:

1. The primary dentin: it is the dentin which is formed when the tooth has reached functional occlusion, and before root completion.4um It has two types:

a. Mantle dentin: Is the name of the first formed dentin in the crown forming the outer most 10-30 um thick layer running parallel with DEJ. It is the dentin which arises during the initial phases of dentinogenesis. It is also characterized by presence of terminal branches of dentinal tubules. Its matrix is less densely mineralized than that of main mass of dentin by 4%.

b. Circumpulpal dentin: It is forming the bulk of the dentin both in the crown and root.

2. Secondary dentin: Is the dentin which is forming a narrow band bordering the entire pulp and representing that dentin which is formed after root completion. It is formed in slower rate

(one um daily) than primary dentin. Its formation is due to functional stimuli ( due to the force of mastication), slow erosive caries

Between the primary and secondary dentin there is often a demarcation line. The number of dentinal tubules in secondary dentin is fewer. The continued deposition of this type of dentin gradually decreases the size of pulp cavity (recession of the pulp).Thus making the liability of pulp exposure during cavity preparation much less likely to happen

3. Tertiary dentin :

a. **Reactive**: Formed by preexisting odontoblasts.

b. **Reparative dentin:** The term reparative dentin relates to dentin forming after stimulus in which the original odontoblasts have been destroyed and new calcified tissue (reparative dentine) has been formed by newly differentiated cells referred to here as odontoblasts-like cells.

The odontoblasts-like cells are differentiated from stem cell in the pulp called perivascular cells( **pericytes**). The Differenion of the stem cells to be odontoblasts-like cells is under the control of bioactive molecules (e.g. cytokines, growth factor) which are locally synthesized and released during the inflammatory process accompanying the stimulus such as dental caries.

The reparative dentin is formed in rapid way (4µm\day) at a localized area on the dentin –pulp border in reaction to:

a. Trauma such as caries

b. Extreme heat and extreme cold.

c. Chemical agents such as calcium chloride, therapeutic intervention.

d. In case of erosion or wherever dentinal tubules and odontoblaststic processes become exposed by sever attrition.

e. Cavity preparations

Only small number of odontoblasts may be involved in its formation as most of the odontoblasts in this area degenerate. The odontoblasts which have been killed are replaced by the migration of undifferentiated cells from pulpal tissue.

Types of reparative dentin:

i. Reparative dentin with few tubules.

ii. Osteodentin, due to the presence of cells within its matrix like the bone.

iii. Irregular reparative dentin: The dentinal tubules are irregularly arranged.

iv. Vasodentin : blood vessels are trapped inside the reparative dentin during its formation

v. Combination of different types in one type.

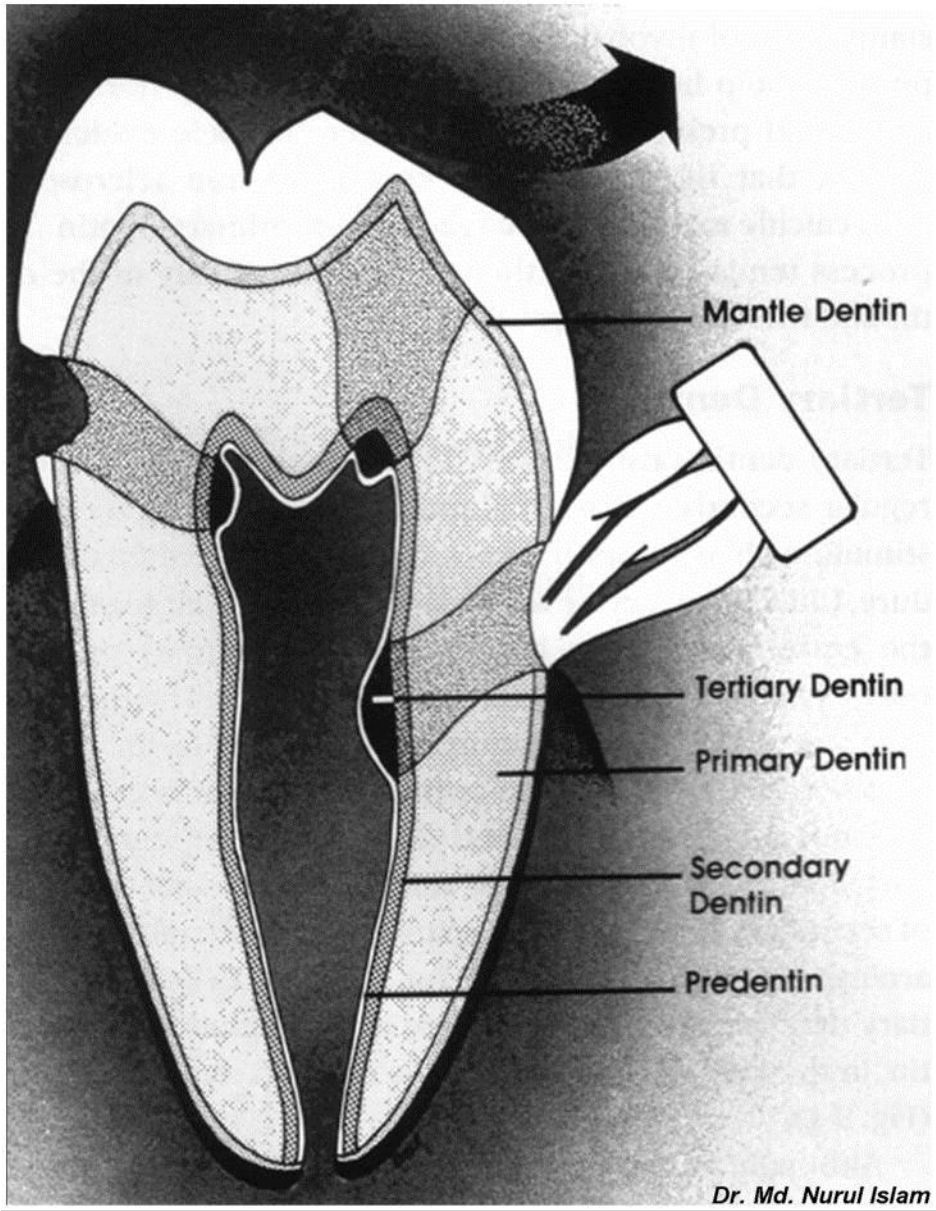


If the carious process is less sever, its tubular pattern is more regular, and there are (if any) few cellular inclusion. For the most part there is no continuity between dentinal tubules of reparative dentin and the overlying primary or secondary dentin. This in effect minimizes dentin permeability at the site of deposition and affords protection to the underlying dentinal pulp.

# Types of Dentin

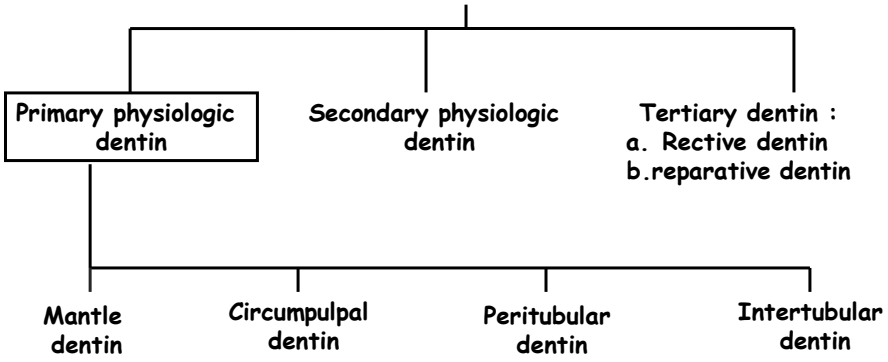


4. Sclerotic ( transparent) dentin:

Is a regressive alteration in the tooth hard tissue due to an age changes .It is characterized by calcification of dentinal hard tissue. Sclerotic dentin also occurs as a result of injury to the dentin by slow caries or abrasion. The most probable source of the calcium salts is the extracellular fluid within the tubules. The dentinal tubules are occluded by widening of the peritubular dentin. Sclerotic dentin appears translucent in transmitted light, while with reflected light these areas appear dark.

In teeth from elderly subjects it is frequently found that most of the dentin, especially in the root, has become sclerotic. Sclerotic dentin is slowing down the spread of carious process.

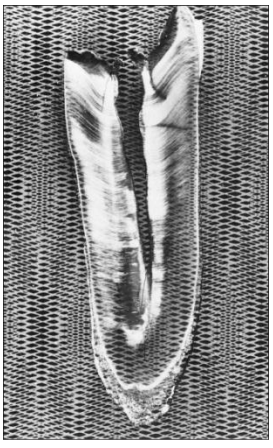

***Fig. 45: Sclerotic dentin***

**Predentin**

It is a layer of 10-47 um thickness that lines the pulpal portion of dentin. It is unmineralized dentin matrix and consists of collagen, glycoprotein and proteoglycans. It is similar to osteoid in bone. Predentin is thick in cases of active dentinogenesis .Predentin always seen in stained decalcified section of the tooth. That was an indication that dentinogenesis is occurring throughout the life of the tooth.

A= Odontoblasts;C=Predentin;
B=circumpulpal dentin

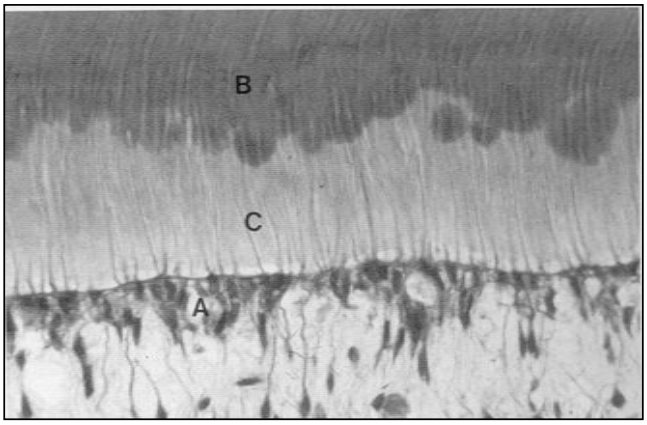


**Incremental lines in dentin:**

Dentinogenesis is occurring throughout life of tooth by appositional growth like bone and cementum.

The incremental lines are hypocalcified areas.

Types:

1. Incremental lines of von Ebenr's: these are analogous to enamel cross striations. They are 4-6 um apart.

2. Contour lines of Owen: They are like the incremental lines of Retzius in enamel. Certain pathological conditions can lead to increase in number of these lines.

3. Neonatal line in enamel present in all deciduous teeth and first permanent molar. It is separating between prenatal and postnatal dentin. This line reflects the abrupt change in environment that occurs at birth. The neonatal line may be a zone of hypocalcification.

# von Ebner's lines

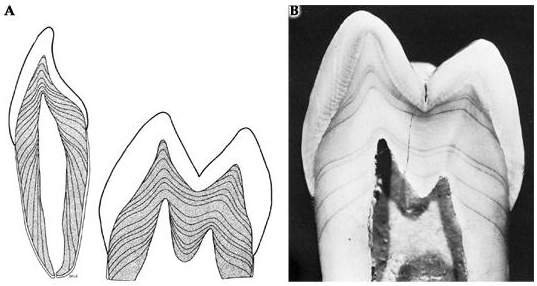


Copyright © 2003, Mosby, Inc., All rights reserved.

Hypocalcified areas:

1. Incremental lines.

**2. Interglobular dentin:**

It is one type **of hypocalcified** areas in dentin. It is considered as a structural defect that occurs in the dentin especially the coronal dentin. This dentin is represented by small islands of noncalcified or imperfectly calcified dentin. It is located in the crown or may extend into the root. Interglobular dentin is found mostly along the outer aspects of circumpulpal dentin, representing developmental defect in the process of dentin calcification. The dentinal tubules pass through interglobular dentin, but the peritubular dentin is absent.

In ground section the interglobular dentin appears dark. In human it is occurring due to deficiency of vitamin D, or exposure to high level of fluoride at the time of dentin formation.




**Granular layer of Tome's**

**It** is an area of hypocalcified dentin which appears as dark granules. It is found at the cemental surface of the dentin. It follows the course of dentino-cemental junction.

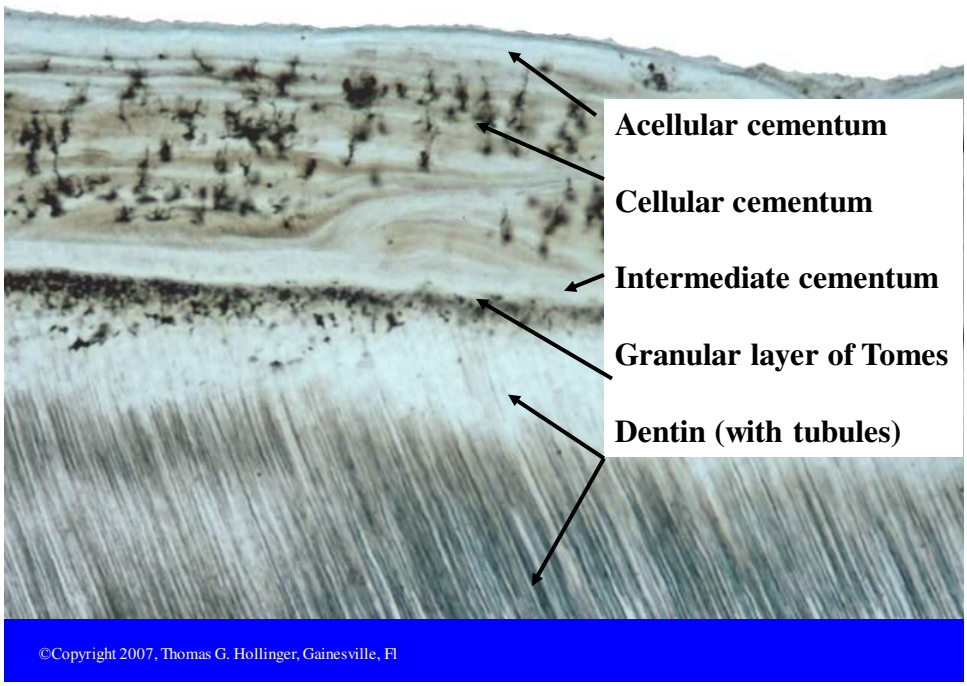


**Dead tracts**

They are empty dentinal tubules which have lost their odontoblastic processes due to sever stimulation in dentin, such as trauma, caries, or cavity preparation. In ground sections, they

appear black in transmitted light. They are frequently sealed off at their pulpal end by reparative dentin.

**A: Dead tracts;**
**B: secondary dentin;**
**C: reparative dentin**

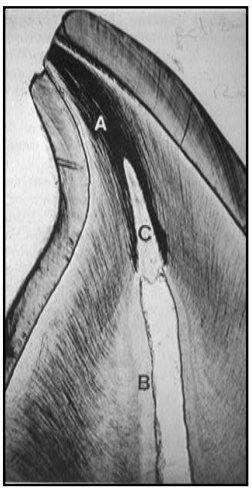


**Innervations of dentin and pain perception**

Dentinal tubules are containing nerve endings in the predentin and up to 200um from the pulp. The nerves are found in close association with the odontoblastic processes within the dentinal tubules. No nerve ending run along the entire length of dentinal tubules.

The pain perception is sever at the DEJ less so in the middle of dentin, more sever near the pulp. There are three theories of pain conduction through dentin:

a. Direct transmission theory: The nerve endings in the inner dentin are affected directly; there is little scientific support for this theory.

b. Transduction theory: Which presume that the odontoblastic process is the primary structure excited by the stimulus and the impulse is transmitted to the nerve endings in the inner pulp.

c. The hydrodynamic theory: Is the most acceptable theory. In this theory the fluid movement inside the dentinal tubules carries the impulse to the nerve endings. Various stimuli such as heat, cold, air blast, mechanical or osmotic pressure affect fluid movement in the dentinal tubules. Fluid movement, either inward or outward, stimulates pain mechanism in the tubules by mechanical disturbance of the nerves associated with the odontoblast and its process .

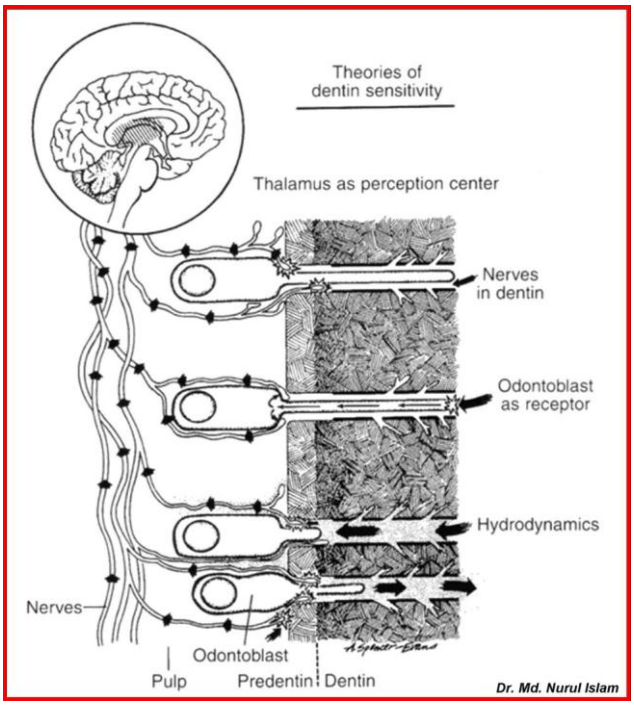


***Fi.g.51: Theories of pain perception by the tooth***

## Dentin Development

Life cycle of odontoblasts:

1. Differentiation of odontoblasts: The odontoblasts are highly specialized connective tissue cells that differentiated from the peripheral ectomesenchymal cells of the dental papilla. Under the influence of the inner enamel epithelium the peripheral cells of the dental papilla differentiate into odontoblast . As differentiation progresses, the cells grow in length and reach about 40um in height and 7um in width and often closely packed together.

2. Formation of predentin.

## Dentinogenesis:

Dentin is the first formed hard tissue. This process begins during the late bell stage in the occlusal area, and then proceeds cervically. Dentinogenesis has two stages:

1. Predentin formation (formation of uncalcified matrix).

2. Mineralization: Which occurs after a second layer of predentin subsequently formed. Formation and calcification begins at the tip of the cusps or incisal edges and proceed inwards in a rythermic manner.

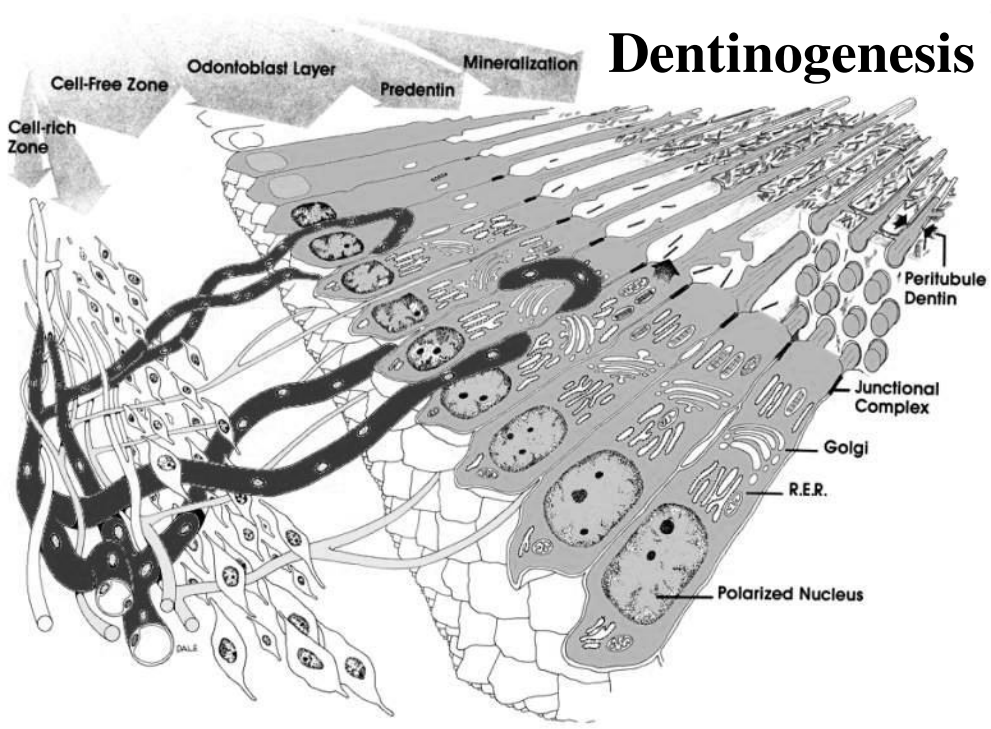


©Copyright 2007, Thomas G. Hollinger, Gainesville, Fl

Oral Histology, 5th edition, A R Ten Cate

## Age changes in dentin

1. Dentin production is continuous throughout the life of the tooth. The dentin deposition, after root completion, is in a form of secondary, reparative or sclerotic dentin.

Sclerotic dentin formation.

Sclerotic dentin may also found under slow progressing caries.Sclerosis reduces the permeability of the dentin and may help prolong pulp vitality. Sclerotic dentin forms an important barrier to the spread of caries toward the pulp.

2.Recession of the pulp: The continuous deposition of dentin throughout life is leading to reduce the space occupied by the pulp.

3.Continuous formation of secondary and reparative dentin increases the time taken by caries to reach to the pulp.

## Vitality of the dentin:

The vitality can be defined as the ability of the tissue to react to physiological and pathological stimuli. There are two expressions for the vitality of dentin:

a. Pain perception.

b. Functional structural adaptation. The kinds of adaptation include formation of secondary dentin, reparative dentin, and sclerotic dentin.

These adaptive processes must be regarded as a defense reaction, which can only accomplished by vital dentin-pulp complex.