ENAMEL

Enamel is forming a hard protective covering of variable thickness over the entire surface of the crown of the tooth. It is the hardest biological substance. Unlike dentin, cementum and bone, enamel is ectodermal in origin. Enamel provides shape to the crown of teeth and covers part of the tooth exposed to the oral environment.

It meets the dentin at the dentinoenamel junction (DEJ) and the cementum at cementoenamel junction (CEJ)(figure 30).Enamel is composed of interlocking rods that resist masticatory forces. Enamel is not sensitive. There is no blood and nerve supply. That's why patient does not feel any pain until the cavity extend in to the dentin, which is a sensitive layer. It's means decay process crosses your enamel barrier against decay or cavity. That's why enamel caries are Silent caries.

Enamel:
most highly mineralized extracellular matrix

96% mineral
4% organic material & water

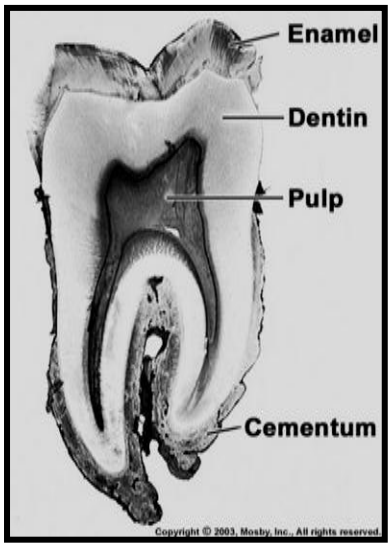

Figure 30: The relationship between enamel and dentin and cementum is demonstrated.

Physical properties:

1. **Thickness:** The maximum thickness of enamel is on the cusps of human molars and premolars where the impact of mastication is greatest. It is 2-2.5 mm thinning down, in

cervical region, to almost a knife edge at the neck of tooth where masticatory impact is the least.
2. **Hardness**: Enamel is considered as the hardest calcified structure in human body . Thus the enamel is forming a resistance covering of the teeth, making it suitable for mastication.
3. **Permeability**: The enamel is acting as a semi permeable membrane.
4. **Color:** The color is ranging from yellowish white to grayish .It is **translucent reflecting the color of the dentin .**

Chemical properties

The enamel consists mainly of inorganic materials (96%), mainly in the form of calcium phosphate, and small amount of organic substance and water (3% water, and 1% organic substance).The inorganic material of enamel is arranged in a form of hydroxy apatite crystals.. The protein of the enamel is **noncollagenous protein**, which includes enamelin and amelogenin.

The hydroxy apatite crystals of the enamel are four times much larger than those of other calcified tissue in the body.

Structure:

Structurally, enamel is composed of millions of enamel rods or prisms, rod sheath and cementing interprismatic substance (figure 31).
An enamel rod is the basic unit of tooth enamel .

Each rod begins at the dentinoenamel junction (DEJ) and extends to the outer surface of the crown.
Enamel is formed by epithelial cells (ameloblasts) that lose their functional ability when the crown of the tooth has been completed. Therefore, enamel, after formation, has no power of further growth or repair.

The number of enamel rods is ranging from 5 million in the lower lateral incisors to 12 million in the upper first molars. They ran from DEJ to the surface of tooth in a somewhat tortuous course. The length of most rods is greater than the thickness of enamel because of the oblique direction and wavy course of the rods. The diameter of the rods is about 4 um and increases from DEJ towards the surface of enamel at a ratio of 1:2.

Hunter-Schreger bands:

The change in the direction of enamel rods is responsible for the appearance of these bands, which are alternating dark and light bands of varying width (nearly 50 um apart) , best seen in longitudinal ground sections under oblique reflected light (figure 33). They originate at the DEJ and pass outwards ending at some distance from the outer enamel surface. These **bands represent:** variations in the course of enamel rods.

Dr.Akram Yousif Yasear

171



Figure (33): Showing Hunter-Schreger bands

Gnarled enamel:

It is an optical appearance of enamel. Near the dentin in the region of cusps or incisal edges the rods arrangement appear to be further complicated as the bundles of rods seems to intertwine more irregularly (figure 34). This arrangement in the cuspal or incisal regions is to withstand and bear the high force of masticatory load imposed on these regions.

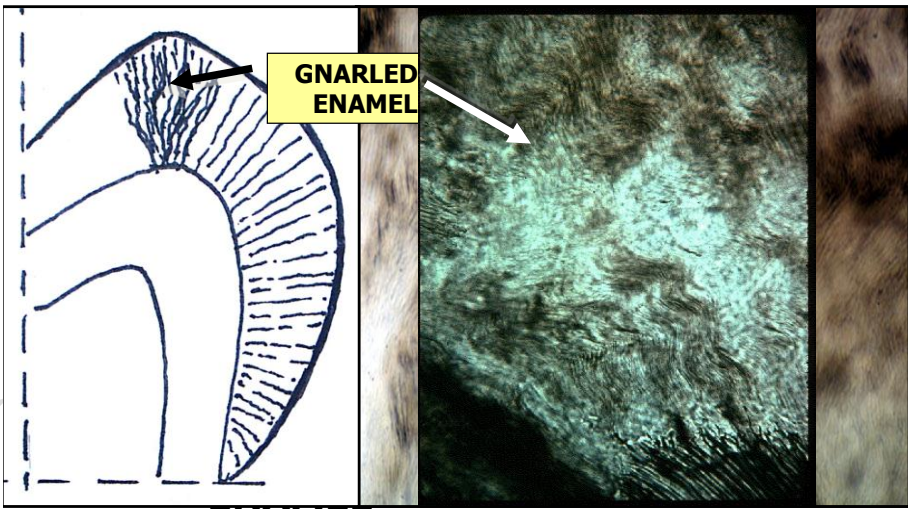

Figure 34: Showing the gnarled enamel

Dr. Akram Yousif Yasear

Incremental lines of enamel:

The incremental lines in enamel are the result from deposition of the enamel layer after layer.

Types

1. **Cross striations (figure 35):**
   Represent incremental lines indicative of daily deposition of enamel
2. **Incremental lines of Retzius (Brown striae):**

They are a series of bands appear in ground sections of enamel. In transverse section (figures 37 and 38) these incremental lines appear as concentric circles. The lines are **Hypomineralized structure .**

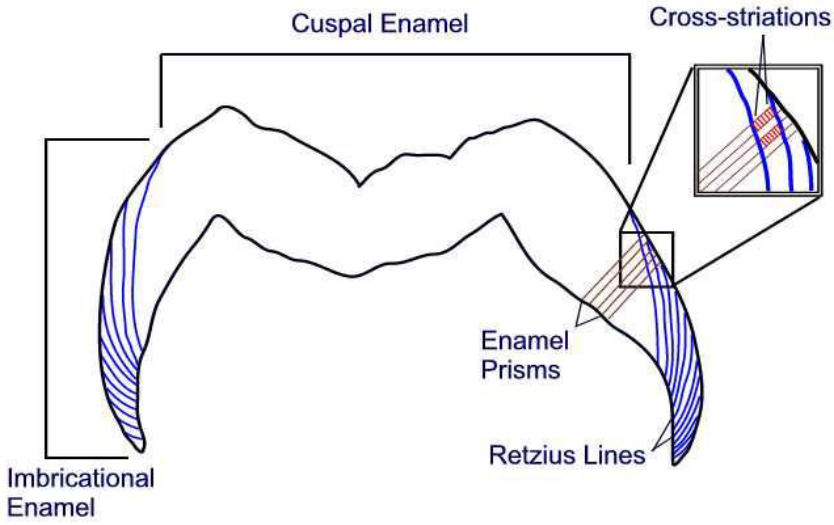

Figure 35: Schematic diagram of enamel showing the cross striations and incremental lines of Retzius.

3. The neonatal line in enamel: It is considered as one kind of incremental line of Retzius and represents the boundary between the prenatal enamel and postnatal enamel. This line is seen in all deciduous teeth and also in the region of the mesial cusps of all first permanent molars. It arises at the time of birth, marking the boundaries between prenatal and postnatal enamel and dentin (figure 36). It appears to result of the abrupt change in the environment and metabolic disturbances of the new born infant.

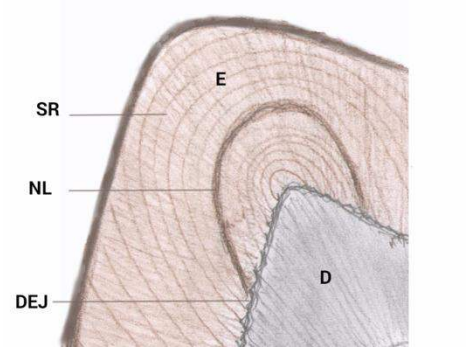

NL: neonatal line in enamel

Surface structures of enamel:

1. Prismless enamel: This is a structureless layer of enamel with a 30um thickness below the surface of enamel.. Prismless enamel is formed due to absence of Tome's process from the ameloblasts .Prismless enamel contains more fluoride than the deeper enamel.

2. **Perikymata**: are transverse waves like grooves believed to be the external manifestation of the incremental lines of Retzius (figure 37a)..

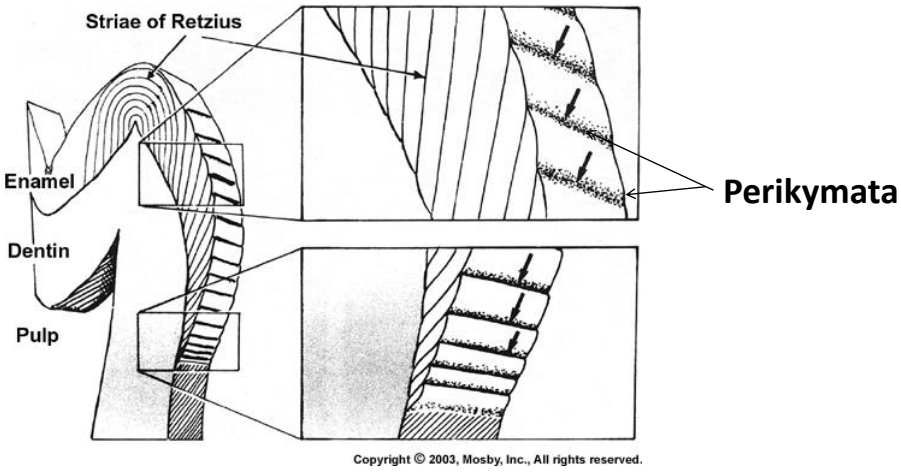

3. **Enamel rod ends**: They are concave and vary in depth and shape. They are shallowest in the cervical regions of surfaces and deepest near the incisal or occlusal edges.

Yousif Yasear

4**. Cracks**: Surface narrow fissure like structures representing the outer edge of enamel lamellae. They extend for varying distance along the surface, at right angle to DEJ, from which they originate. Most of them are less than one um in length but some are longer and a few reach the occlusal or incisal edge of the surface.
5. **Enamel cuticle** it is considered as typical basal lamina apparently secreted by ameloblasts when enamel formation is completed.

6. **Enamel pellicles**: Erupted enamel is normally covered by a pellicle which is a precipitate of salivary proteins. This pellicle is reformed within hours after an enamel surface is mechanically cleaned. Within a day or two after the pellicle has formed, it becomes colonized by microorganisms to form bacterial **plaque**. When the plaque is calcified it will be converted to form **calculus**. These three structures (Pellicle, plaque and calculus) are called the biofilm.

Hypocalcified structures in enamel:

1**. Enamel lamellae:**

They consist of organic materials with little mineral content.

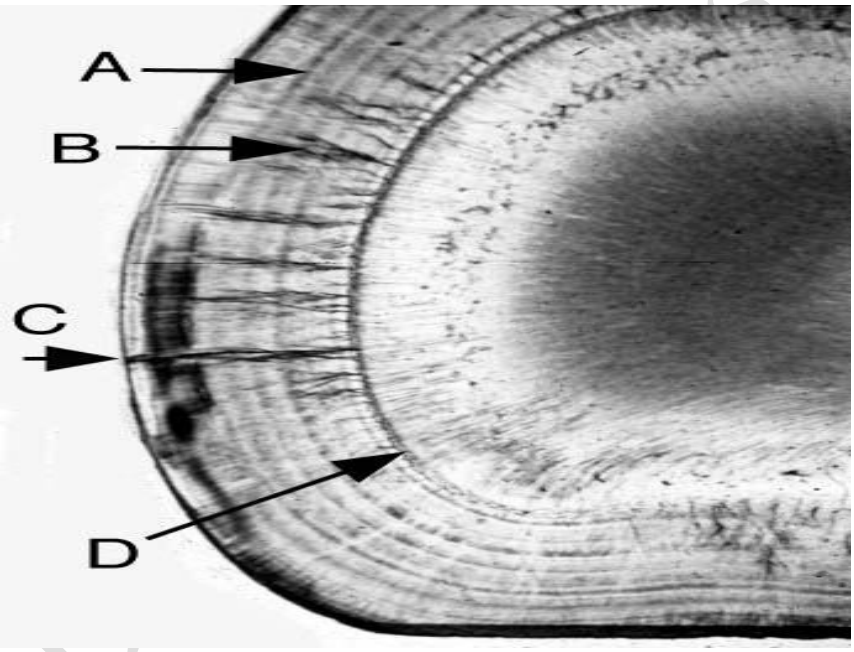

Figure (38): Micrograph of cross ground section of crown showing dentino-enamel junctional area(D) ; enamel tuft(B);enamel lamellae(C) and incremental lines of Retzius..

Enamel lamellae may be a site of weakness in the teeth and may form a road of entry for bacteria that initiates caries.

2. Enamel tufts: These are hypocalcified areas in enamel occurring in enamel due to defects in process of calcifications of enamel rods leading to an increase in the percentages of organic matters .They arise at the DEJ and reach to about one fifth to one third of the thickness of the enamel (figure 38).

Dentinoenamel junction (DEJ):

The surface of the dentin at the DEJ is pitted. In to the shallow depressions of the dentin, fit rounded projections of the enamel figure (39). This relation assures firm hold of the enamel on the dentin to prevent tissue shearing apart during mastication.

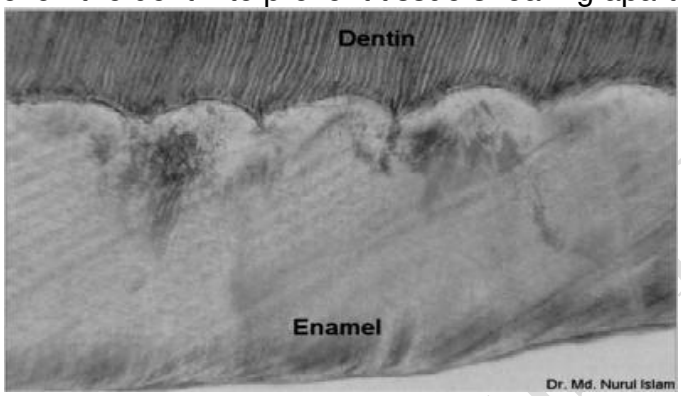

Figure (39): Scalloped appearance of the dentinoenamel junction.

Enamel spindles:

One type of structural defects in the enamel
Occasionally odontoblastic processes cross the DEJ into the enamel, since many are thickened at their end. They have been termed enamel spindles. They seem to originate from processes of odontoblasts that extended (insinuate) in between the ameloblast before hard substance were formed. Enamel spindles extend from the dentin surface, 10-40 um into the enamel (figure 40).

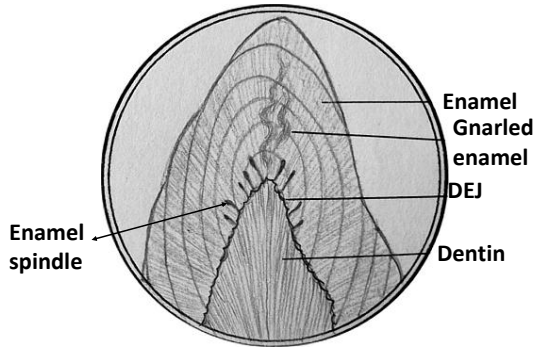

DEVELOPMENT OF ENAMEL: -

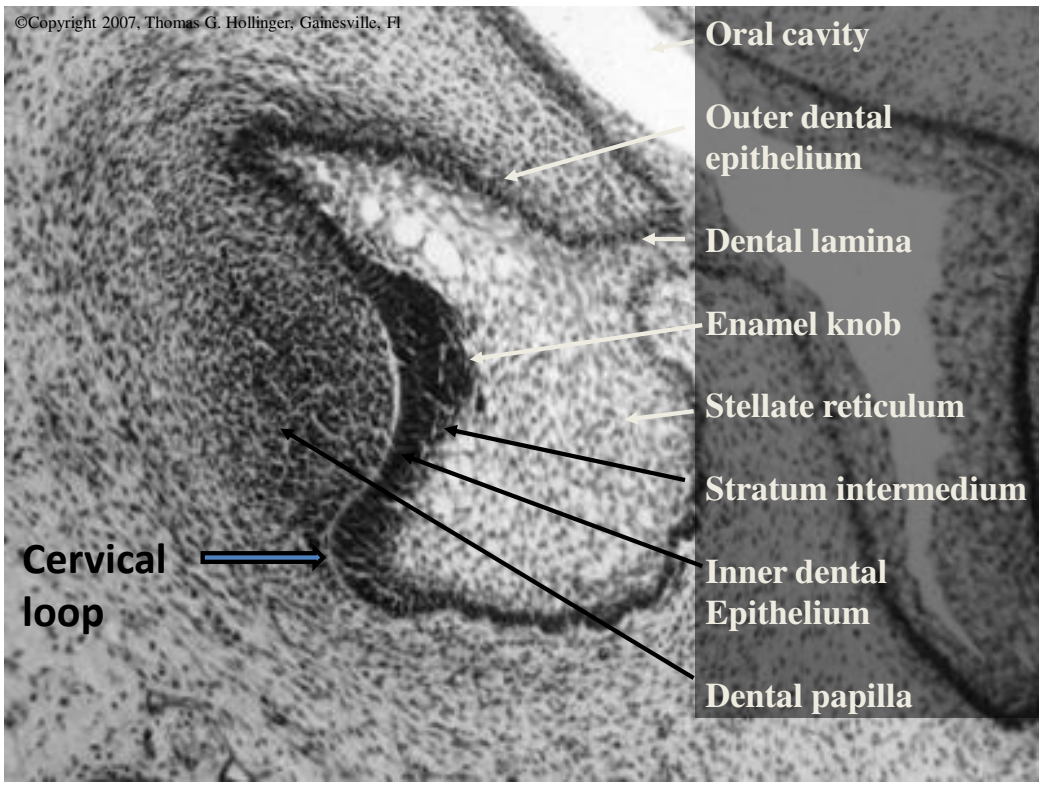

Figure 41: Photomicrograph of different structures seen at bell stage

LIFE CYCLE OF AMELOBLAST: -

1. **Morphogenic stage:**

Before the ameloblasts are fully differentiated and produce enamel, they interact with the adjacent ectomesenchymal cells of dental papilla, to determine the shape of the DEJ and the crown. During this stage(bell stage) the cells are still called **inner enamel epithelium (IEE)**.

Functional stages in life cycle of ameloblasts:

1. Morphodifferentiation
2. organizing
3. Secretory (initial)
4. Secretory (Tomes' process)
5. Maturation (ruffle-ended)
6. Maturation (smooth-ended)
7. Protective(as part of reduced enamel epithelium)

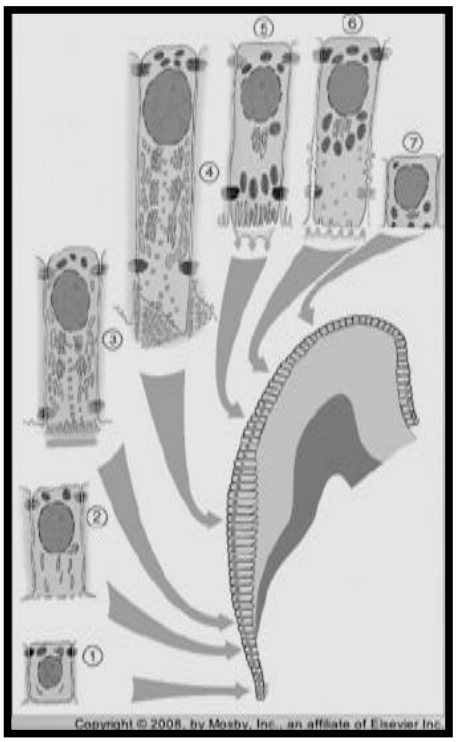

Figure (42): Showing the different stages of life cycle of ameloblasts.

2. **Organizing stage:**

In this stage the IEE interacts becomes tall columnar cell.

3) **Formative stage:**

This stage starts after the first layer of dentin has been formed. . The earliest apparent change is the development of blunt cell processes on the distal end of the ameloblast, which penetrate the basal lamina and enter the dentin. This process is called **Tome's process** (figure 43).

Dr.Akram

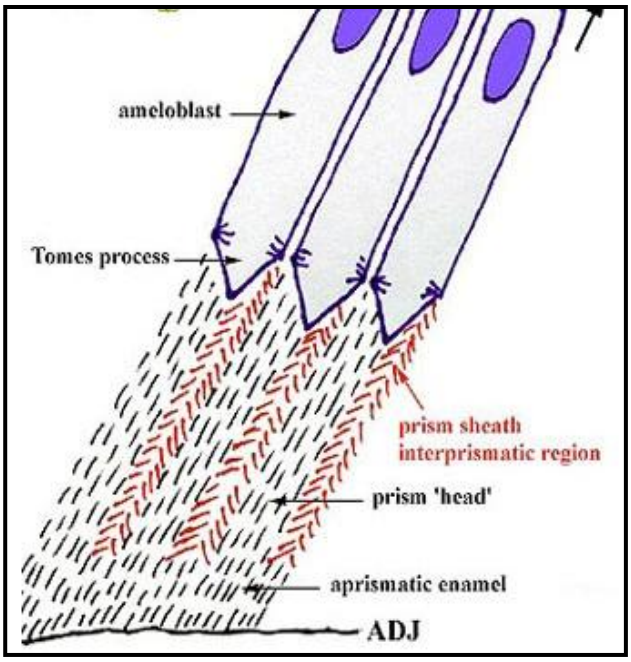

Figure 43: Development of Tome's process of ameloblasts during amelogenesis.

N.B: **The Tome's process**:

Is a conical blind distal extension at the distal end of each ameloblast. The Tome's processes are necessary to give shape of the enamel rods. Absence of Tome's processes lead to the formation of prismless enamel.

4**) Maturative stage:**

Enamel maturation (full mineralization) occurs after most of the thickness of enamel matrix has been formed in the occlusal or incisal areas. During maturation the ameloblasts display microvillus (figure 44) at their distal ends . This arrangement indicates an absorptive function of these cells.

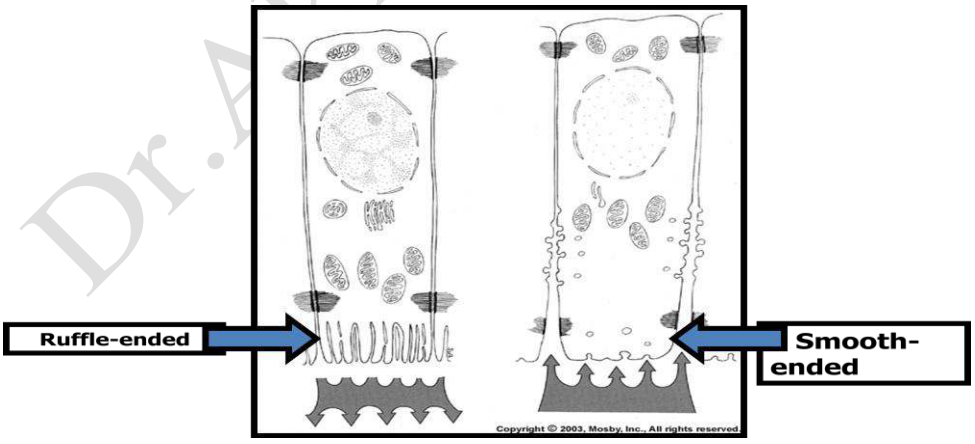

Figure (44): Ameloblast at the maturative stage of its life cycle.

Dr.Akram Yousif Yasear

5) Protective stage:

After enamel maturation, the ameloblasts cease to be arranged in a well-defined layer and can no longer be differentiated from the cells of the stratum intermedium and OEE. These cells layers then form a stratified covering on the surface of enamel called **reduced enamel** epithelium (figure 45) The function of the reduced enamel epithelium is to protect the mature enamel by separating it from the connective tissue until the tooth erupts.

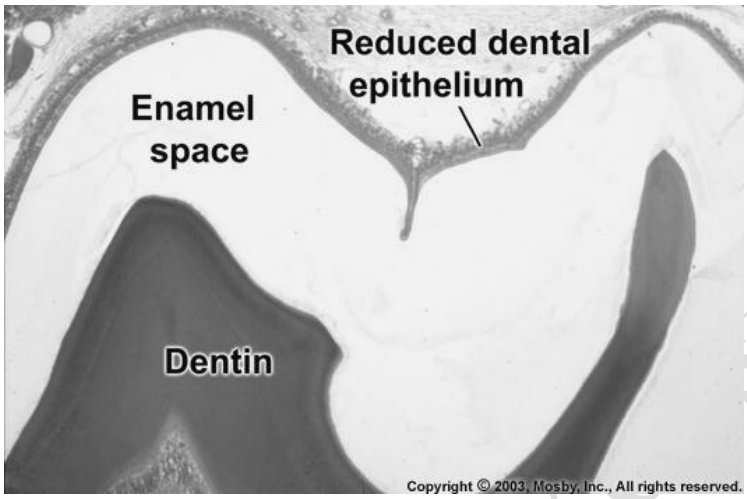

Figure (45) : Ameloblast at protective stage of its life cycle, as part of reduced enamel epithelium covering the recently formed enamel.

6**) Desmolytic stage: -**

The reduced enamel epithelium proliferates and seems to induce atrophy of the C.T separating it from the oral epithelium. Thus the fusion between the two epithelium can occurs. The cell of reduced enamel epithelium secretes enzymes that are able to destroy C.T fibers by desmolysis. Premature degeneration of reduced enamel epithelium may prevent the eruption of the tooth.

AMELOGENESIS:

The development of enamel involves two processes:

a. **Organic matrix formation.**

b. **Calcification (mineralization or maturation).**

Dr.Akram Yousif Yasear

a. organic matrix formation:

The ameloblasts begin their secretory activity when small amount of dentin has been laid down . As enamel deposition continues, a thin, continuous layer of enamel matrix is formed along the dentin.

The newly formed (deposited) enamel matrix is containing 65% water, 20% organic material and 15% inorganic).

b. Mineralization or maturation of enamel matrix maturation:

Is defined as the process by which the immature (partially calcified) enamel is converted to mature (highly calcified) enamel. Two major processes occur during maturation of the enamel:

1. Changing of the content of enamel matrix:

The 65% of water decrease to become 3%

The 20 % organic materials decrease to become 1%

The 15 % inorganic materials increase to become 96 %.

2. Maturation and growth of the crystals which increase to about 25nm-in .



Figure 46: The micrograph is showing the growth of enamel crystals during maturation of its organic matter.

CLINICAL CONSIDERATIONS ON DEVELOPMENT OF ENAMEL:-

Three types of aberrations can occur during amelogenesis:
a. Hypoplasia.
b. Hypocalcification
c. Discoloration of the teeth.

Because enamel development occurs in two phases
a. Matrix formation

b.Maturation.

Thus the disturbances may occur during developmental stages of enamel, the effect of which are seen clinically on examination of eruptive teeth. These **disturbances** can affect the formation of the enamel matrix or its calcification. **Disturbances of matrix formation result in hypoplasia, while disturbances of calcification or (maturation) results in hypocalcification of the enamel.**

Discoloration of teeth from administration of tetracycline during childhood is a very common problem due to deposition of tetracycline in the dentin**.**

.

Hypoplasia and hypocalcification may be caused by systemic, local or hereditary factors

I. Local causes: infection, trauma, and irradiation.

II. Systemic causes:

1) Environmental which include:

a) Prenatal: rubella, syphilis, and fluoride ions.

b) Neonatal: hemolytic disease of new born, hypocalcaemia.

c).Postnatal: measles, chicken pox, scarlet fever, congenital heart disease, hypoparathyrodism, fluoride ion, vitamins A, C, D, deficiency.

III. Genetics (hereditary): like amelogenesis imperfecta

- Hypoplasia is manifested by pitting, furrowing or even total absence of enamel.
- Hypocalcification: appear in the form of opaque or chalky areas on surface of enamel.

Systemic hypoplasia is termed chronologic hypoplasia.

The presence of fluoride in saliva speeds up crystal precipitation, forming a fluorapatite-like coating more resistant to caries than the original tooth structure.

Dr.Akram Yousif Yasear