Endodontic Diagnosis

Diagnosis: It is the procedure that:

1. Accepts the patient.
2. Recognizes that he/she has a problem.
3. Determine the cause of the problem.
4. Develop a treatment plan to treat the problem.

Requirements of a diagnostician

1. Knowledge: A dentist must depend on himself and his scientific background.
2. Interest and curiosity: The dentist must be interested in solving the problem of the patient and curious about the result of the diagnosis.
3. Patience: The dentist needs time and patience to understand the reasons for the problem, which are not always visible, and needs some time and investigations to reveal the cause of the problem.

Subjective Findings:

These can be obtained by questioning the patient and are not evident to the examiner:

A. **Chief complaint**: It is a description of the dental problem of the patient. It should be noted by the patient's own words. After recording the chief complaint, the history of present illness is recorded.

B. **Present dental illness**: Pain is the main reason for the patient's complaint. It ranges from dull to severe, which indicates the severity of the problem. It may indicate the source, which may be dental or the surrounding structures. A dentist should ask the following questions regarding pain:

1. **Quality:** Dull, sharp, throbbing, constant
2. **Location:** Localized, diffuse, referred, radiating
3. **Duration:** Constant or intermittent, lasting for seconds, minutes, or hours
4. **Onset:** Stimulation required, intermittent, spontaneous
5. **Initiation factors:** Cold, heat, palpation, percussion
6. **Relieving factors:** Cold, heat, any medications, sleep

	Type of pain	*Reason for pain*	*Provisional diagnosis*
Location	• Localized pain	Presence of proprioceptive A-β fibers present in periodontal ligament	• Periodontal pain
	• Diffuse pain	Lack of proprioceptive fibers in pulp	• Pulpal pain
Duration	• Momentary pain on stimulation		• Reversible pulpitis
	• Spontaneous pain for long duration		• Irreversible pulpitis
Nature	• Sharp shooting momentary pain on applying stimulus	Stimulation of Aδ fibers because of movement of dentinal fluid present in odontoblastic processes	• Dentinal pain • Reversible pulpitis
	• Sharp shooting pain on mastication		• Irreversible pulpitis • Fracture of tooth
	• Spontaneous dull, throbbing pain for long duration	Stimulation of C-fibers	• Irreversible pulpitis
Stimulus	• Sweet and sour	Due to stimulation of Aδ fibers present in odontoblastic processes	• Reversible pulpitis
	• Heat	Vasodilatation caused by heat stimulates C-fibers of pulp	• Irreversible pulpitis
	• Cold	Stimulation of Aδ fibers due to fluid movement in odontoblastic processes	• Dentin hypersensitivity
	• Heat and cold		• Early stages of irreversible pulpitis
	• Stimulated by heat and relieved by cold		• Late stages of irreversible pulpitis
	• On lying down or sleep		• Acute irreversible pulpitis

Medical history: There are no medical conditions that specifically contraindicate endodontic treatment, but there are several that require special care. Scully and Cawson have given a checklist of medical conditions which are needed to be taken with special care.
If there is any doubt regarding the state of health of the patient, consult a medical practitioner before initiating endodontic treatment

Checklist for medical history (Scully and Cawson)

- **A**nemia
- **B**leeding disorders
- **C**ardiorespiratory disorders
- **D**rug treatment and allergies
- **E**ndocrine disease
- **F**its and faints
- **G**astrointestinal disorders
- **H**ospital admissions and attendance
- **I**nfections
- **J**aundice
- **K**idney disease
- **L**ikelihood of pregnancy or pregnant itself

Clinical examination: Examining the patient clinically with the patient's history will make the diagnosis of the problem.

Vital signs:

1. Blood pressure: The normal pressure is 120/80 mm Hg for patients under the age of 60 years, and 140/90 mm Hg for patients over the age of 60 years. Any pressure exceeding this limit needs consultation with a cardiologist before dental treatment.
2. Pulse rate and respiration: The normal pulse rate is 60-100 beats/minute, and the respiration is 16-18 breaths/minute. They may be elevated due to stress and anxiety.
3. Temperature: The normal temperature of the body is 37° C (98.6 F). Any elevation in body temperature may be a sign of general illness.
4. Cancer screen: This examination should include the face, lips, neck, and intraoral soft tissues for lumps and white spots.

Objective Findings:

These are examinations and tests that should be performed by the clinician to identify the diagnosis:

Extraoral examination:

Inflammatory changes originating intraorally and observable extraorally may indicate a serious spreading problem. Signs that need to be looked for are:

1. Physical limitations, such as limitations in mouth movement during speaking.
2. Facial asymmetry that results from facial swelling.
3. Lymph nodes involvement
4. Presence of skin open sinus tract

Visual and palpation examinations of the face and neck are warranted to determine. Palpation allows the clinician to determine whether the swelling is localized or diffuse, firm or fluctuant. These latter findings will play a significant role in determining the appropriate treatment. Sinus tracts of odontogenic origin may also open through the skin of the face. These openings in the skin will generally close once the offending tooth is treated and healing occurs, leaving a scar on the skin surface.





Intraoral examination:

The oral vestibules and buccal mucosa should be examined for localized swelling and sinus tracts or color changes. The lingual and palatal soft changes should then be checked. Any raised lesions or ulcerations should be documented and, when necessary, evaluated with a biopsy or referral. Teeth should be inspected for a carious lesion, faulty restoration, loss of teeth, and presence of deciduous or supernumerary teeth.

Intraoral swellings should be visualized and palpated to determine whether they are diffuse or localized and whether they are firm or fluctuant. These swellings may be present in the attached gingiva, alveolar mucosa, mucobuccal fold, palate, or sublingual tissues.

Intraoral sinus tracts may be opened in the alveolar mucosa, in the attached gingiva, or through the furcation or gingival crevice. They may exit through either the facial or the lingual tissues, depending on the proximity of the root apices to the cortical bone. Tracing the sinus tract will provide objectivity in diagnosing the location of the problematic tooth. To trace the sinus tract, a size #25 or #30 gutta-percha cone is threaded into the opening of the sinus tract. The cone should be inserted until resistance is felt. After a periapical radiograph is exposed, the origin of the sinus tract is determined by following the path taken by the gutta-percha cone.







Pulpal evaluation:

There are many tests that indicate the pulpal health state. These tests reveal the extent of the problem and give a clue about the treatment, as irreversible pulpitis needs endodontic treatment, whereas reversible pulpitis may need a normal filling.

Pain history:

Initially, information on pain is obtained by asking questions regarding the current problem(s). This examination is subjective; frequently asked questions include:

- Location: Occasionally, a patient may identify the location of the pain; however, one must be cautious, as pulpal pain may be referred to a different area. Pain may be felt in any of the orofacial structures.
- Type and intensity of pain: The patient may describe pain in many ways. Examples include sharp, dull, throbbing, stabbing, burning, electric shock-like, deep, or superficial. The more the pain disrupts the patient's lifestyle because of its intensity, the more likely it is to be irreversible in origin.
- Duration: For how long after removal of the stimulus does the pain continue? The longer the pain continues after the stimulus, the more likely it is to be irreversible.
- Stimulus: Many different stimuli may initiate the pain, for example, hot, cold, sweet, biting, and posture. Alternatively, the pain may be spontaneous. Special tests may be selected based on what causes the main complaint.
- Relief: Pain-relieving factors, especially the type and frequency of analgesics, antibiotics, and sipping cold drinks.

Periodontal evaluation

The complete diagnosis is performed when an examination is done on the tooth and surrounding tissues. The periodontal pathology, such as gingivitis and periodontal pockets, may affect the pulp; therefore, periodontal treatment may be necessary before/with the endodontic treatment.

Clinical endodontic tests

These tests determine the condition of the tooth's pulp and supporting structures. One test is not enough for a decisive diagnosis; therefore, a combination of tests is necessary.

Pulp testing

Pulp test (pulp sensibility test) is a diagnostic procedure to determine pulp status. It can be performed by applying thermal, electrical, or mechanical stimuli.

Objectives of pulp testing:

1. To assess the health of pulp based on its qualitative sensory response before restorative, endodontic procedures.
2. To differentially diagnose periapical pathologies of pulpal or periodontal origin.
3. To assess the status of pulp as a follow-up after trauma to teeth.
4. To check the status of a tooth, especially one that has a history of pulp capping or deep restoration.
5. To diagnose oral pain, whether it is of pulpal or periodontal origin, or because of another reason.

A. Thermal tests.

The baseline or normal response to either cold or hot is a patient's report that a sensation is felt but disappears immediately upon removal of the thermal stimulus. Abnormal responses include a lack of response to the stimulus, which means the tooth is nonvital, or intensified pain on placement or after removal of stimuli, which means the tooth is inflamed. The cold or hot stimuli should be placed on the middle third of the labial or lingual surface to be more effective.

1. **Cold testing:** It is the most commonly used test for assessing the vitality of pulp. Cold causes contraction of fluid within dentinal tubules, resulting in outward flow of fluid from tubules and thereby pain. This test is used to differentiate between reversible and irreversible pulpitis and to identify necrotic teeth. If a tooth is sensitive to a cold stimulus, which subsides after removal of the stimulus, then the condition is reversible. If the sensitivity takes more than a few

seconds, then the condition may be irreversible. Teeth with calcified canals need more time for the cold stimulus to reach the pulp.
This test is especially useful for patients presenting with porcelain jacket crowns or porcelain-fused-to-metal crowns where no natural tooth surface (or much metal) is accessible.
Cold testing may be done by air blast, cold drink, ice stick, or ethyl chloride.





2. **Hot testing:** It is most advantageous in the condition where the patient's chief complaint is intense dental pain upon contact with any hot object or liquid. The use of a hot stimulus can help locate a symptomatic tooth with necrotic pulp. Heated gutta-percha stick or hot water may be used. A disadvantage of using gutta-percha stick is that, because of high temperature, pulpal damage can occur. Heat test should not be done for >5 s because prolonged heat application causes biphasic stimulation of Aδ fibers followed by C fibers, which can result in persistent pain.

B. Electric pulp testing:

An electrical pulp tester is a battery-operated device that acts by generating pulsatile electrical stimuli and stimulation of Aδ nerve fibers. Many factors affect the level of response, such as enamel thickness, area of probe placement (in the middle third of the labial surface), dentin calcification, restorations, and the patient's level of anxiety. False positive and negative results may happen. A newly erupted tooth may give a

negative response, whereas a traumatized young tooth may not respond to testing. Multirooted teeth give inconclusive readings because there are many roots with different degrees of pulp inflammation in each root canal.

Procedure:

1. Isolate the tooth to avoid any false positive response. The best way to do that is by using a rubber dam.
2. Apply an electrolyte to the tooth electrode and place it on the facial surface of the tooth.
3. Precautions should be taken to avoid it contacting adjacent gingival tissue or metallic restorations to avoid a false-positive response.
4. Confirm the complete circuit by clipping a ground attachment onto the patient's lip.
5. Once the circuit is complete, slowly increase the current and ask the patient to point out when the sensation occurs.
6. Each tooth should be tested two to three times, and the average reading is noted. If the vitality of a tooth is in question, the pulp tester should be used on the adjacent teeth and the contralateral tooth, as a control.





C. Cavity test:

Occasionally, as a last resort, an access cavity is cut into dentine without local anaesthesia as an additional way of vitality testing. The sensitivity or the pain felt by the patient indicates pulp vitality. If no pain is felt, it indicates the tooth is not vital, and endodontic therapy may be carried out.

Percussion:

It is performed by gently tapping on the incisal or occlusal surfaces of the accused tooth with a blunt instrument, usually by the back end of a metal instrument handle, and comparing that with a normal tooth. The tooth crown should first be tapped vertically; if sensitivity obtain this could be an indication of the presence of periapical pathosis. Horizontal tapping should also be performed to differentiate between periapical and lateral periodontal lesions.

Palpation:

A palpation test is performed by applying firm pressure with the index finger to the mucosa covering the roots and apices, and questioning the patient about any areas that feel unusually sensitive during examination. This can detect the presence of periradicular abnormalities or specific areas that produce a painful response to digital pressure. A positive response to palpation may indicate an active periradicular inflammatory process. However, this test does not indicate whether the inflammatory process is of endodontic or periodontal origin.

Mobility:

Tooth mobility is directly proportional to the integrity of the attachment apparatus or to the extent of inflammation in the periodontal ligament. Often, the mobility reverses to normal after the initiating factors are repaired or eliminated. This test can be done by the back ends of two mirror handles, one on the buccal aspect and one on the lingual aspect of the tooth. Pressure is applied in a facial-lingual direction as well as in a vertical direction, and the tooth mobility is scored. Any mobility that exceeds +1mm should be considered abnormal. However, the teeth should be evaluated on the basis of how mobile they are relative to the adjacent and contralateral teeth.



Occlusal analysis:

It is important to examine suspected teeth for interferences on the retruded arc of closure, intercuspal position, and lateral excursions. Interferences in any of these positions could result in a degree of occlusal trauma and initiate acute apical periodontitis.

Staining and transillumination:

To determine the presence of a crack in the surface of a tooth, the application of a stain (Methylene blue dye) to the area is often of great assistance. The procedure includes:

1. It may be necessary to remove the restoration in the tooth to better visualize a crack or fracture.
2. Painted Methylene blue dye on the tooth surface with a cotton tip applicator. This dye can penetrate cracked areas.
3. Remove the excess dye with a moist application of 70% isopropyl alcohol.
4. The remaining dye will indicate the possible location of the crack.

Also, transillumination using a bright fiberoptic light probe to the surface of the tooth may be very helpful in detecting cracks and fracture lines.

Procedure includes:

Directing a high-intensity light directly on the exterior surface of the tooth at the cementum-enamel junction (CEJ) may reveal the extent of the fracture. Teeth with fractures block transilluminated light and appear dark, while the part of the tooth that is proximal to the light source will absorb this light and glow.

Although the presence of a fracture may be evident using dyes and transillumination, the full extent of the fracture cannot always be determined by these tests alone.

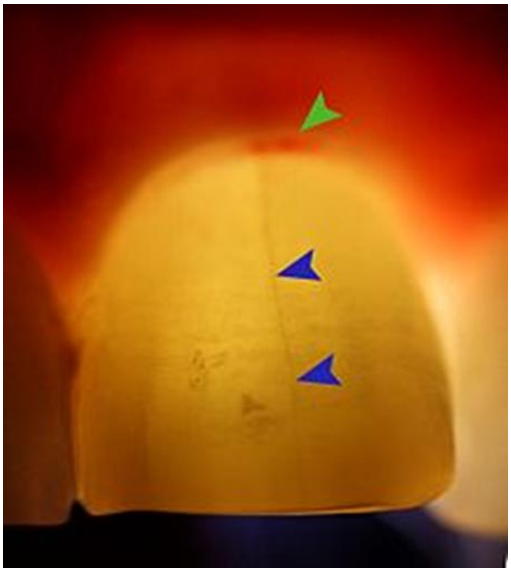

Periodontal probing:

The periodontal pathology, such as gingivitis and periodontal pockets, may affect the pulp; therefore, periodontal treatment may be necessary before or with the endodontic treatment.



Detailed periodontal probing around suspected teeth may reveal a sulcus within normal limits. However, deeper pocketing will be identified. A narrow defect may be an indication of a root fracture or an endodontic lesion draining through the gingival crevice. This causes an endodontic-periodontal lesion.

Bite test:

The bite test helps in identifying a cracked or fractured tooth. This is done if the patient complains of pain on mastication. A tooth is sensitive to biting if pulpal necrosis has extended to the periodontal ligament space or if a crack is present in a tooth. This test can be done by asking the patient to bite on a hard object such as a cotton roll or wood sticks. Tooth Slooth is another commercially available device for a bite test. It has a small concave area on its top, which is placed in contact with the cusp to be tested. Pain present on biting indicates apical periodontitis, and pain present on release of biting force indicates a cracked tooth.



Selective anaesthesia testing:

Selective anaesthesia can be useful in cases of referred pain to distinguish whether the source of pain is mandibular or maxillary in origin. It is less useful for distinguishing pain from adjacent teeth, as the anaesthetic solution may diffuse laterally.

Radiographs:

The radiographic interpretation of a potential endodontic pathosis is an integral part of endodontic diagnosis and prognosis assessment. However, dentists should not rely solely on radiography to prematurely give a definitive diagnosis without using other diagnostic tests. When not coupled with a proper history and clinical examination and testing, the radiograph alone can lead to a misinterpretation of normality and pathology.

Radiographs do not show early signs of pulpitis, as there is no periodontal widening at this stage of pulpal degeneration. Radiographic findings may include the loss of lamina dura (laterally or apically) or a periradicular radiolucency indicative of pulp necrosis.

Alternatively, radiographs may show pulp chamber or root canal calcification, which may explain reduced responses to pulp sensitivity testing. This emphasises the need to consider using more than one test. Radiographic examination may also reveal tooth/root resorptive defects.



Clinical Findings in Reversible Pulpitis

Visual	Check for decay, fracture lines, swelling, sinus tracts, orientation of tooth, and hyperocclusion
Palpation	Not sensitive
Percussion	Not sensitive
Mobility	None (unless periodontal condition exists)
Perio probing	None (unless extensive periodontal disease exists)
Thermal	Hypersensitive to heat or cold (quick response lasting for seconds)
Electric Pulp Test	Responds
Translumination	Not used unless a fracture is suspected
Selective anesthesia	Not necessary
Test cavity	Not necessary, tooth is vital
Radiographic	Periapical x-ray shows normal periapex

Clinical Findings in Irreversible Pulpitis

Visual	Check for decay, fracture lines, swelling, sinus tracts, orientation of tooth, and hyperocclusion
Palpation	No response initially; may be sensitive in later stages
Percussion	No response initially; may be sensitive in later stages
Mobility	None (unless periodontal condition exists)
Perio Probing	None (unless extensive periodontal disease exists)
Thermal	Hypersensitive to hot and cold with prolonged response
Electric Pulp Test	Responds
Transillumination	Not used unless fracture is suspected
Selective Anesthesia	May help identify offending tooth
Test cavity	Not necessary, tooth is vital
Radiographic	Normal or thickened periodontal ligament

Clinical Findings in Necrotic Pulp

Visual	Check for decay, fracture lines, swelling, sinus tracts, orientation of tooth, and hyperocclusion
Palpation	Sensitive
Percussion	Mild to severe pain (depends on periapical inflammation)
Mobility	None to moderate (depends on bone loss)
Perio Probing	None (unless extensive periodontal disease exists)
Thermal	No response
Electric Pulp Test	No response
Translumination	Not used unless fracture is suspected
Selective **anesthesia**	May help identify offending tooth
Test cavity	May be used if vitality is suspected
Radiographic	Periapical radiograph may show normal or thickened periodontal ligament, or radiolucent lesions