Restoration of Endodontically Treated Teeth

Compositional changes in nonvital teeth and the influence of endodontic therapy:

The loss of pulpal vitality is accompanied by a slight change in tooth moisture content. This loss of moisture (9%) is attributed to a change in free water but not in water bonded to the organic and inorganic components. This alteration was associated with a slight change in values for the Young modulus and proportional limit.

However, no decrease in compressive and tensile strength values was associated with this change in water content. No difference in collagen cross-linkage was found between vital and nonvital dentin. Thus nonvital teeth undergo rather minor changes in physical characteristics. Sodium hypochlorite and chelators such as ethylenediamine tetra-acetic acid (EDTA), and calcium hydroxide (Ca[OH]2) commonly used for canal irrigation and disinfection interact with root dentin, with either mineral content (chelators) or organic substrate (Sodium hypochlorite). Chelators mainly deplete calcium by complex formation and also affect noncollagenous proteins , leading to dentin erosion and surface softening. Depending on concentration, duration of exposure, and other factors, Sodium hypochlorite can demonstrate a proteolytic action by hydrolysis of long peptide chains such as collagen. These alterations are likely to impact dentin and root structure and alter bonding properties of this substrate. Thus The chemicals used for canal irrigation and disinfection, as already mentioned, interact with mineral and organic contents and then reduce dentin elasticity and flexural strength to a significant extent, as well as microhardness. Major changes following endodontic treatment which altered tissue physical characteristics is due to loss of tooth structure, So Restoring a tooth after endodontic treatment needs to conserve as much remaining tooth structure as possible. Posterior teeth should be restored with restorations that cover and protect the occlusal surface of the tooth as onlay. Crown coverage of teeth is only indicated

when the tooth has multiple large restorations or it lost great amount of tooth structure.

Types of treatments according to tooth loss

1. Direct Composite Restorations

When a minimal amount of coronal tooth structure has been lost after endodontic therapy, a direct resin composite restoration can be done. Composites have compressive strengths of about 280 MPa, and the Young modulus of composite resins is generally about 10 to 16 GPa, which is close to that of dentin.



2. Indirect Restorations: Composite or Ceramic Onlays.

Ceramic or resin composite onlays can be used to restore endodontically treated teeth. Endocrowns combine the post in the canal, the core, and the crown in one component.

Both onlays and endocrowns allow for conservation of remaining tooth structure, whereas the alternative would be to completely eliminate cusps and perimeter walls for restoration with a full crown.

Onlays are constructed in the laboratory from either hybrid resin composite or ceramics. Onlays, overlays, and endocrowns can also be fabricated from resin composites processed in the laboratory.

Using various combinations of light, pressure, and vacuum, these fabrication techniques may increase the conversion rate of the polymer and consequently the mechanical properties of the restorative material.



3. Full Crowns

When a significant amount of coronal tooth structure has been lost by caries, restorative procedures and endodontics, a full crown may be the restoration of choice.

The crown can be directly built on the remaining coronal structure which has been prepared accordingly. More frequently, the cementation of a post inside the root canal is necessary to provide retention for the core material and the crown. The core is anchored to the tooth by extension into the root canal through the post and replaces missing coronal structure. The crown covers the core and restores aesthetics and function of the tooth. An additional role of the post and core is to protect the crown
margins from deformation under function therefore preventing coronal leakage. The post and its luting material used to cement it, the core and the crown will all influence the longevity of the tooth.

When a post is needed it gives retention to the core but it does not strengthen the tooth against fracture especially metal posts. Adequately condensed gutta percha can be safely removed immediately after endodontic treatment. Both rotary and hot instruments can be safely used to remove gutta percha.

Tapered posts are the least retentive posts and threaded posts are the most retentive but these threads increase the possibility of stress concentration at the edges of the post and end in root fracture.



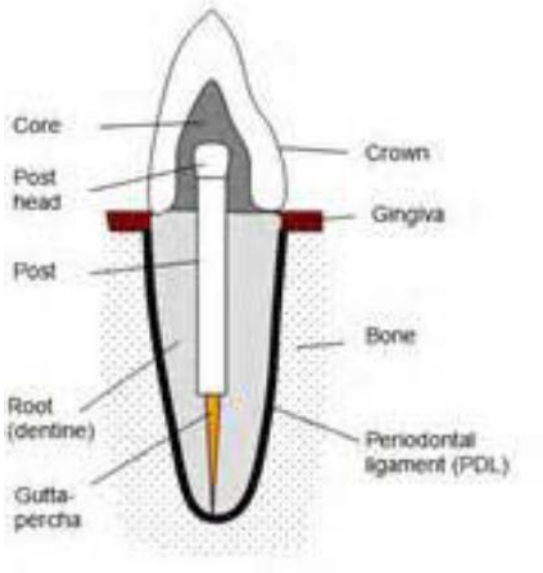

Clinical guidelines for post dimension

1. The post should be 3/4 the length of the root when treating long rooted teeth or keeping 5 mm of apical gutta percha.
2. The post should be confined to the straight part of the root canal.
3. Post width should be as wide as the width of the treated root canal without extra widening to keep as much tooth structure as possible.

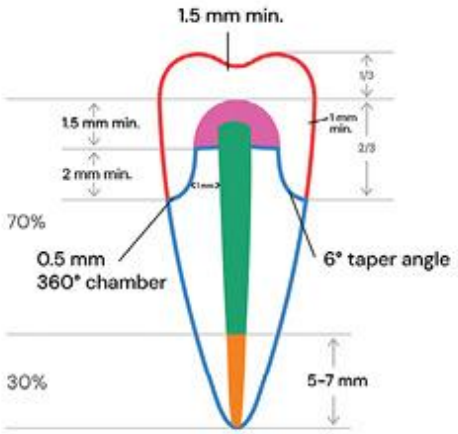

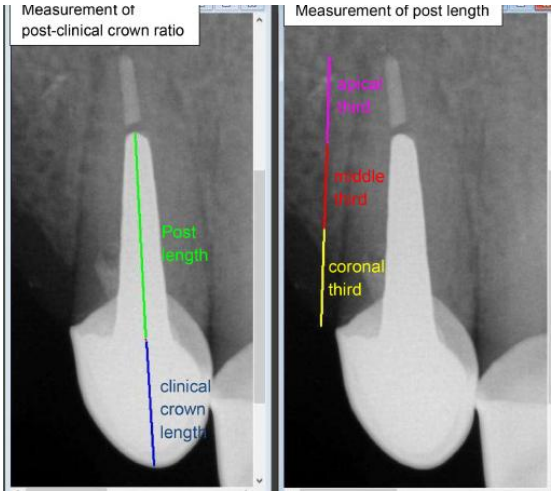

The Ferrule

The more tooth structure that remains, the better the long-term prognosis of the restoration. The coronal tooth structure located above the gingival level will help to create a ferrule. The ferrule is formed by the walls and margins of the crown, encasing at least 2 to 3 mm of sound tooth structure.



A properly made ferrule significantly reduces the incidence of fracture
in endodontically treated teeth by reinforcing the tooth at its external surface and dissipating forces that concentrate at the narrowest circumference of the tooth. A longer ferrule increases fracture resistance significantly. The ferrule also resists lateral forces from posts and leverage from the crown in function and increases the retention and resistance of the restoration.

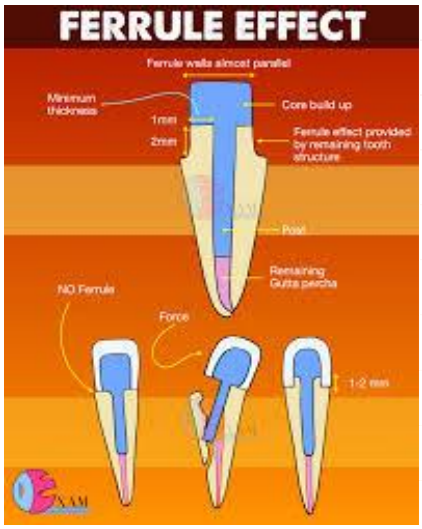

Requirements of crown shape and crown preparation:

1. The ferrule (dentin axial wall height) must be at least 2 to 3 mm.
2. The axial walls must be parallel.
3. The restoration must completely encircle the tooth.
4. The margin must be on solid tooth structure.
5. The crown and crown preparation must not invade the adjacent tissues.

Roots fracture :

Structures subjected to low but repeated forces can appear to fracture suddenly for no apparent reason. This phenomenon, also known as fatigue failure, occurs when a material or a tissue is subjected to cyclic loading. Fatigue may be characterized as a progressive failure phenomenon that proceeds by the initiation and propagation of cracks; many failures of teeth or materials observed in the mouth are fatigue-related.

Because teeth are subjected to fluctuating cycles of loading and unloading during mastication, fatigue failure of dentin, posts, cores, crown margins, or adhesive components is likely to occur. Mechanical loading will favor the propagation of micro cracks that will progress from the coronal to the apical region of the tooth.

Fatigue failure of nonvital teeth restored with a post is more catastrophic because it may result in a complete fracture of the root. A post placed into a dentin root will function physically like any structural rod anchored in another material. This means that the forces applied on the post are

transmitted to the root dentin with characteristic patterns depending on the modulus of elasticity of both the post and the dentin. If the post has a higher modulus than the dentin, the stress concentration is adjacent to the bottom of the post. This is evident in clinical cases of root fracture originating at the apex of a rigid post. When the stiffness of the endodontic post is similar to that of dentin, stresses are not concentrated in the dentin adjacent to the apex of the post but rather are dissipated by both the coronal and the root dentin . A resilient post can also prevent a sudden blow by stretching elastically, which reduces the transient forces against the tooth, but a post that is too elastic becomes too flexible for retaining a core and a crown when the tooth cannot do so on its own. A resilient post that is overloaded fails with less force than a stiffer post. This limits the amount of resilience that can be designed into a post.

Posts

Dentin has a degree of flexibility and posts can be flexible or stiff. Although no material can behave exactly like dentin, a post with functional behavior similar to that of dentin is beneficial when the post must be placed next to dentin.

Fiber posts have a modulus of elasticity closer to dentin than that of the metal posts.





An ideal post should be resilient enough to cushion an impact by stretching elastically, thereby reducing the resulting stress to the root. It would then return to normal without permanent distortion. Therefore, the perfect post would combine the ideal degree of flexibility and strength in a narrow-diameter structure.

Classification of posts

1. Custom made posts (gold or base metal alloys)
2. Prefabaricated posts
   A. Metal (gold, stainless steel or titanium posts)
   B. Carbon fiber
   C. Glass fiber
   D. Quartz
   E. Zirconia





Posts should provide as many of the following clinical features as possible:

1. Maximal protection of the root from fracture
2. Maximal retention within the root and retrievability
3. Maximal retention of the core and crown
4. Maximal protection of the crown margin seal from coronal leakage
5. Pleasing aesthetics, when indicated
6. High radiographic visibility
7. Biocompatibility

Procedure for post space preparation and post placement

1. Take an X-ray to evaluate the condition, length and width of the tooth.
2. Preserve as much as possible of the tooth structure coronally but at the same time offer an easy access of the Pesso drill to the root canal.
3. The gutta percha is removed by the Pesso drill with as minimum tooth structure removal as possible.
4. A suitable sized post should be placed to fit the space in the root canal.
5. The post is cemented in the root canal with a luting agent (composite luting cement or glass ionomer cement) in the root canal.
6. The core is built up with a suitable material as composite or amalgam.