# Endodontic Radiography

The dental radiograph allows indirect vision of the dentition and supporting structures and provides standardization of intracanal procedures. As a result, radiographs are a very important aid for endodontic diagnosis and treatment.

**Basic radiographic concepts**

1. X-rays are similar to light rays in that both travel in a straight line until deflected or absorbed. Deflected rays reduce image clarity.

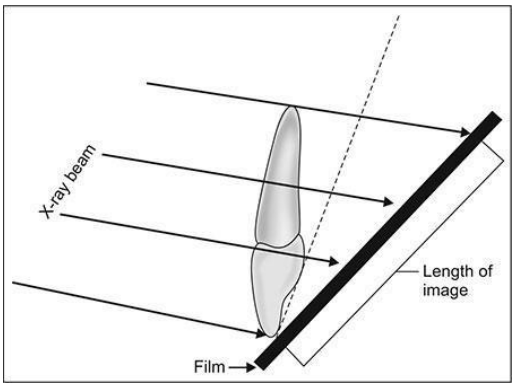


2. The radiograph is a shadow image representing differences in the density of objects in the X-ray path. Therefore, the radiograph is a two-dimensional image of a three-dimensional structure.





3. The size, shape, and contrast of the shadow image are subjected to many distortions since they are dependent on the physical properties of:
   A. The object through which the X-ray passes.
   B. The radiation source.
   C. The film on which the image is recorded.

Therefore, dentists should be familiar with the normal and abnormal radiographical appearance of the tooth and its surrounding tissue, in addition to different restorative materials.

**Interpretation of radiograph according to appearance**

| *Appearance* | *Tentative finding* |
|---|---|
| Black/gray area | a. Decay |
| | b. Pulp |
| | c. Gingiva or space between teeth |
| | d. Abscess |
| | e. Cyst |
| White area | a. Enamel |
| | b. Restoration (metal, gutta-percha, etc.) |
| Creamy white area | Dentin appears as creamy white area |
| White line around teeth | Lamina dura around teeth |

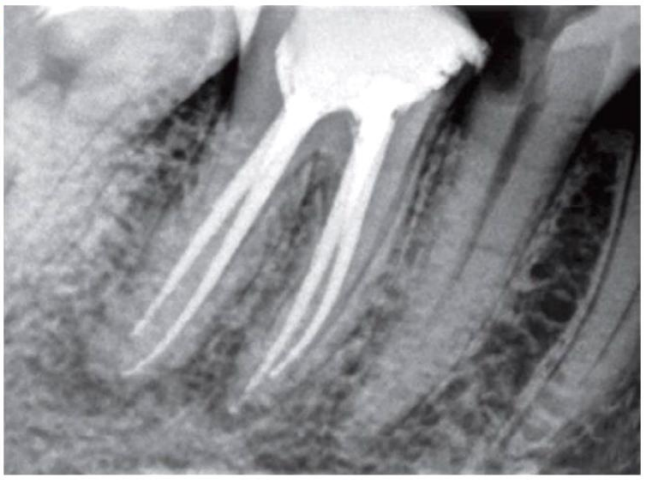

Types of radiographs used for endodontic purposes:

1. Intraoral
   A. Intraoral periapical
   B. Bitewing
2. Extraoral
   A. Panoramic
   B. Computed tomography

**Intraoral periapical:**
It can be divided according to techniques for exposing teeth into:

**Bisecting angle technique:**
The X-ray beam is directed perpendicular to an imaginary plane that bisects the angle formed by the recording plane of X-ray film and the long axis of the tooth.

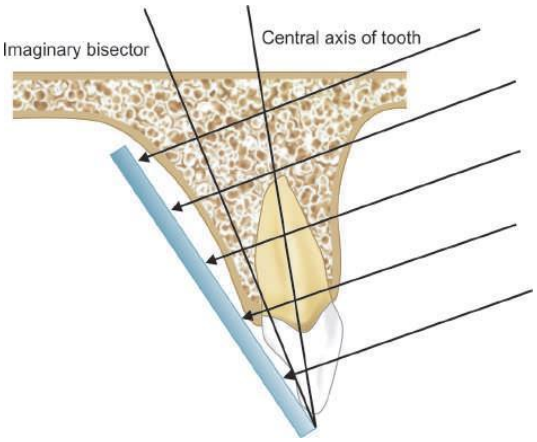


**Advantages:**
1. Easy and comfortable for the patient.
2. Quick and does not require a holder.
3. Easier when the rubber dam is in place

**Disadvantages:**
1. More image distortion and superimposition of anatomical landmarks.
2. More artifacts, such as a cone cut.
3. Since the film holder is not used, it's difficult to visualize where the X-ray cone should be directed.
4. Difficult to reproduce.

**Paralleling technique:**
In this technique, X-ray film is placed parallel to the long axis of the tooth to be exposed by
using a film holder, and the X-ray beam is directed perpendicular to the film.

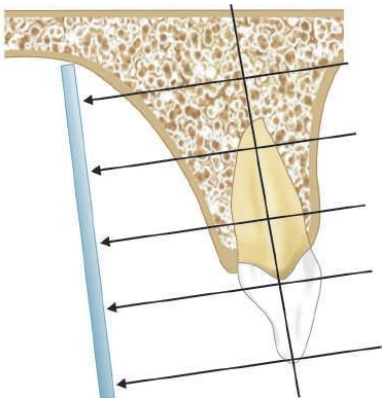

**Advantages:**
1. Better accuracy with fewer distorted images.
2. Because of the parallel instrument with the aiming ring, the X-ray beam is easy to align irrespective of the position of the head.
3. Images can be reproduced.

**Disadvantages:**

1. Since film is more upright in paralleling technique, it impinges more on the floor of the mouth or palate, which makes it more uncomfortable.
2. Difficult to use in patients with a shallow palatal vault, gag reflex, and extremely long teeth.
3. Difficult to use with a rubber dam.

**Suggestions for good endodontic radiography**

1. For periapical exposures, the edge of the film is positioned parallel to and near the incisal or occlusal surface of the teeth so that the tooth apices are near the center of the film.

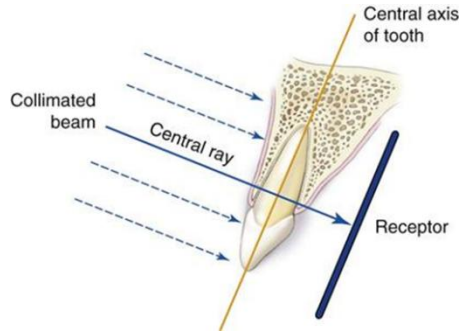




2. The plastic film holder facilitates the standardization of a radiographic technique by aiding in film positioning and preventing movement of the film during exposure.



3. Because of the angle of the hard palate, the films that are held by the finger usually show maxillary molars with short buccal roots and a very long palatal root.



**Buccal object rule**

When treating premolars and molars, it is often difficult to recognize radiographically which canal is nearer the buccal side. When the exposure is done to a multicanaled tooth, the canals may be superimposed, and the difficult to differentiate them. If the X-ray cone is deviated mesially or distally with a given angle, the roots will separate in the film. Therefore, when the cone is moved distally, the buccal canal appears mesial to the lingual or palatal canal, and when the cone is moved mesially, the buccal canal appears distal to the lingual or palatal canal. This is called the SLOP rule, which means the canal that moves in the Same direction is Lingual, whereas the canal that moves in the Opposite direction is Buccal.

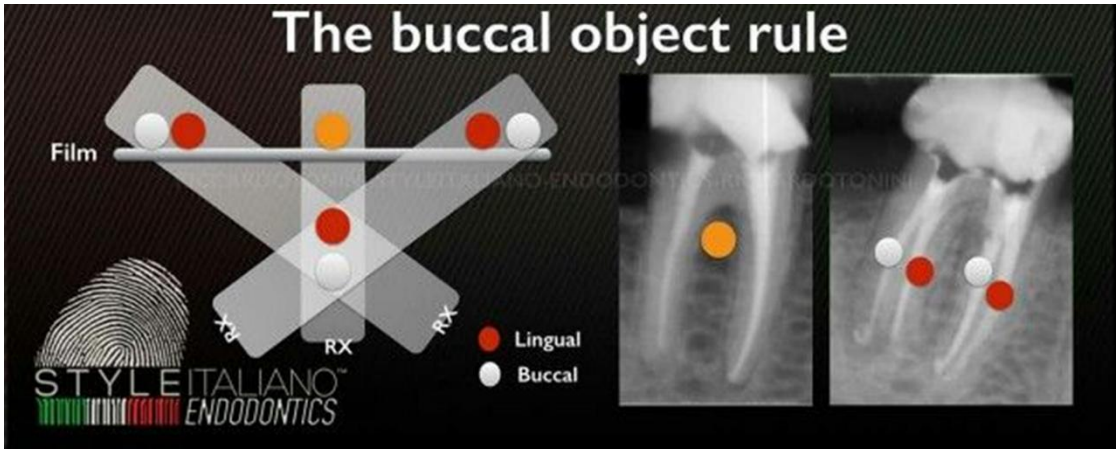


**Factors that affect the quality of the radiograph and its interpretation.**

1. Radiolucent rubber dam frames do not interfere with taking radiography. Metal frames may mask important structures on the film.






2. A quick automated processing technique offers a clear radiograph. It maintains a water bath heated by a thermostatically controlled heater that maintains the developer and fixer at 100 F, so shortening the time needed to process a radiographic film. The exposed film is immersed in the developer for 5-10 seconds, rinsed with water, and then placed in the fixer until it becomes clear (15-20 seconds).



3. All endodontic radiographs must be dated and mounted in chronological sequence to allow for immediate reference.
4. Film magnification is essential to see clearly detailed structures in the film, and this is done with a magnifying lens. Nowadays, there is no need for this lens because digital radiography allows detailed pictures that can be zoomed in clearly.



**Information gained from the radiograph**

1. The crown and pulp anatomy
2. Hard tissue alterations in the tooth (sclerosis or resorption)
3. Number, size, location, and direction of the roots
4. Estimation of the working length
5. Related anatomical structures such as the mental foramen, maxillary sinus, etc.
6. Confirm the position of the master cone
7. Evaluation of the success of obturation
8. Instrument separations or perforations.

**Digital radiography:**

As dentistry moves to a more precise quality, so does diagnosis; therefore, it was important to change the traditional X-ray films to a more precise film, and here digital radiography entered the diagnostic field. Digital radiography used in dentistry is available in three variations:

A. **<u>Direct digital system:</u>** It uses a solid-state sensor such as a charge-coupled device (CCD). These systems have a cable that connects the sensor to the computer and, in turn, to the screen monitor.







**Direct digital systems have three components:**

1. <u>Radio component</u>: It consists of a high-resolution sensor with an active area that is similar in size to conventional film. For infection control, disposable plastic sheaths are used to cover the sensor when it's in use.
2. <u>Visio component</u>: It consists of a video monitor and a display-processing unit. As the image is transmitted to the processing unit, it's digitized and stored by the computer.



3. Printing component: High-resolution printer providing a hard copy of the screen image.



**Advantages:**

1. Low radiation dose.
2. Darkroom is not required, as an instant image is viewed with the elimination of the hazards of the film processing procedure.
3. The quality of the image is consistent.
4. Diagnostic capability is increased through digital enhancement and enlargement of specific areas for closer examination.
5. Storage and archiving of patient information

**Disadvantages**

1. Expensive.
2. The life expectancy of CCD is not fixed.
3. Bulky sensor with cable attachment, which can make placement in the mouth difficult.
4. Large disk space is required to store images.

B. **Storage phosphor system**: It uses a photo-stimulable phosphor plate that stores the image in the phosphor for subsequent readout by an extra-oral laser scanner.

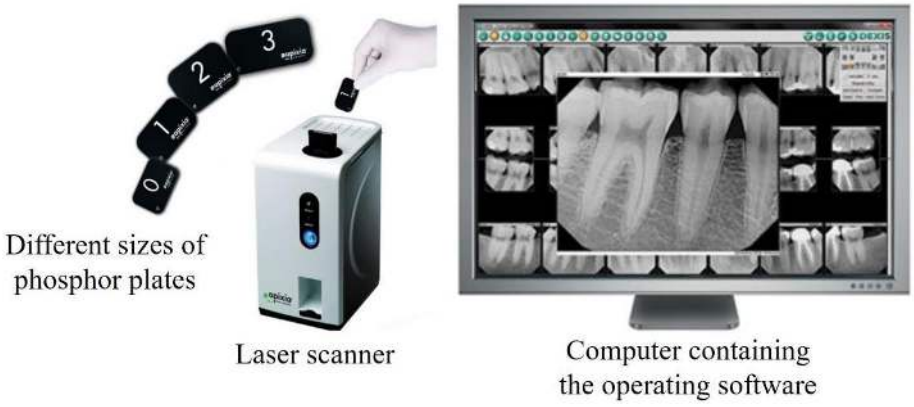

**Advantages:**

1. Low radiation dose (90% reduction).
2. Almost instant image (20–30 s).
3. Storage and archiving of patient information.
4. Flexible with similar sizes to X-ray films.
5. The X-ray source can be remote from the PC.

**Disadvantages:**

1. Cost.
2. Life expectancy of phosphoric plates.
3. Storage of images (same as with CCD systems).

C. **Indirect digital system**: It uses a scanning device connected to a computer for digitizing traditional silver halide dental films.

**Cone-Beam Computed Tomography (CBCT)**

Since the introduction of maxillofacial CBCT in 1996, it has provided the first clinically practical technology demonstrating the application of 3D imaging for endodontic considerations.



CBCT has a coneshaped X-ray beam that captures a cylindrical or spherical volume of data, described as the field of view. Here, a 3D volume of data is achieved with a single sweep of the scanner, using a simple and direct relationship between the beam source and sensor; the latter rotating 180–360° around the patient's head. During the exposure sequence, hundreds of planar projection images are obtained from the field of view. Thus, immediate 3D radiographic images are obtained.

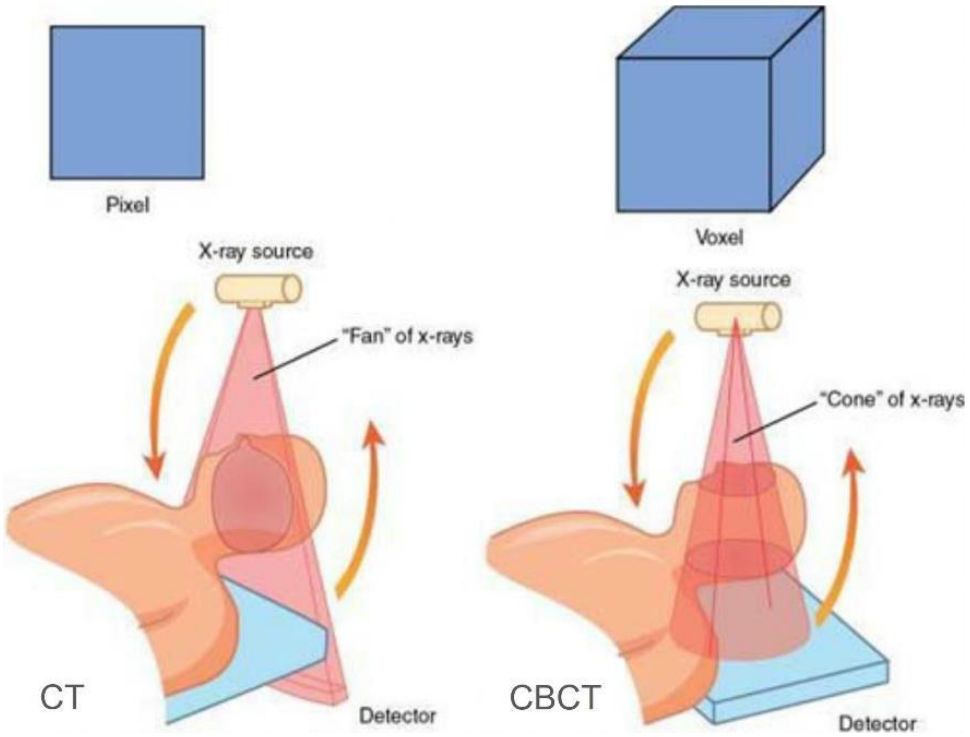


**Field of view (FOV)**

The FOV ranges from as small as a portion of a dental arch to an area as large as the entire head. Usually, for endodontic purposes, a small or limited FOV is required (may reach 4x4 cm or less). This type has the maximum resolution, which is measured by voxel. It may reach between 75 to 60µm voxel in some machines.

**Advantages:**

1. CBCT overcomes the shortcomings of conventional radiography by producing 3D images that show accurate anatomy and spatial relationships of the pathosis and anatomical structures.
2. A clinician can choose and view slices of the volumetric data in all the planes.
3. Reduced patient exposure to ionizing radiation and superior image quality of dental hard tissues.
4. CBCT voxels are isotropic, ensuring geometrical accuracy of the images.

**Limitations:**

1. The resolution and contrast of CBCT are lower than those of intraoral radiography.
2. Chances of radiographic artifacts are higher with CBCT, for example, when the CBCT X-ray beam encounters a very high-density object, such as enamel or metallic restorations.
3. The patient has to stay absolutely still, because movement can affect the sharpness of the final image during the scan.

**Applications of CBCT in endodontics:**

1. Evaluation of total tooth morphology, such as root numbers, curvatures, or anomalies, in addition to root canal numbers and configurations.
2. Identification of dental periapical pathosis and apical periodontitis.
3. Diagnosis of different types of root resorption and root perforations.
4. Proper assessment of dentoalveolar trauma and root fracture.
5. Used in the planning of surgical endodontic treatment.
6. Postoperative assessment in monitoring root canal obturation and healing of apical lesions, accurately as compared to conventional radiography.