Etiology of Malocclusion

The local etiological factor of malocclusion

- Anomalies of number
  - Supernumerary teeth
  - Missing teeth
- Anomalies of tooth size
- Anomalies of tooth shape
- Premature loss of deciduous teeth
- Prolonged retention of deciduous teeth
- Delayed eruption of permanent teeth
- Abnormal labial frenum
- Dental caries
- Improper dental restorations
- Ankylosis
- Abnormal eruptive path.

- **ANOMALIES OF TOOTH NUMBER**

include the presence of extra teeth or the absence of one or more teeth that can predispose to malocclusion.

Supernumerary Teeth

- Extra teeth in relation to the normal complement of teeth are generally referred to as supernumerary teeth. These teeth usually have abnormal morphology and do not resemble normal teeth. Extra teeth, which closely resemble the normal teeth, are called supplemental teeth, which are often observed to occur on lateral incisors **(Fig.1 A)** and premolar regions.
- The occurrence of supernumerary teeth may be single or multiple, unilateral or bilateral, erupted or impacted **(Fig. 1B)** in one or both jaws.
- The term mesiodens is used for extra tooth in the midline between two permanent maxillary central incisors; the most common site for

supernumerary teeth. Mesiodens are usually conical shaped although they can be tuberculated. Mesiodens can be erupted or impacted and when present may cause malocclusion by displacing one or both the central incisors **(Fig. 1C)**.

- An extra tooth adjacent to the molar is called as a paramolar and when present distal to the last molar is called as distomolar. The term parapremolar is sometimes used for an extra tooth in premolar regions **(Fig. 1D)**.
- Supernumerary teeth may cause arch length tooth material discrepancy and crowding when erupted; may delay, prevent or deviate the path of eruption of adjacent teeth.

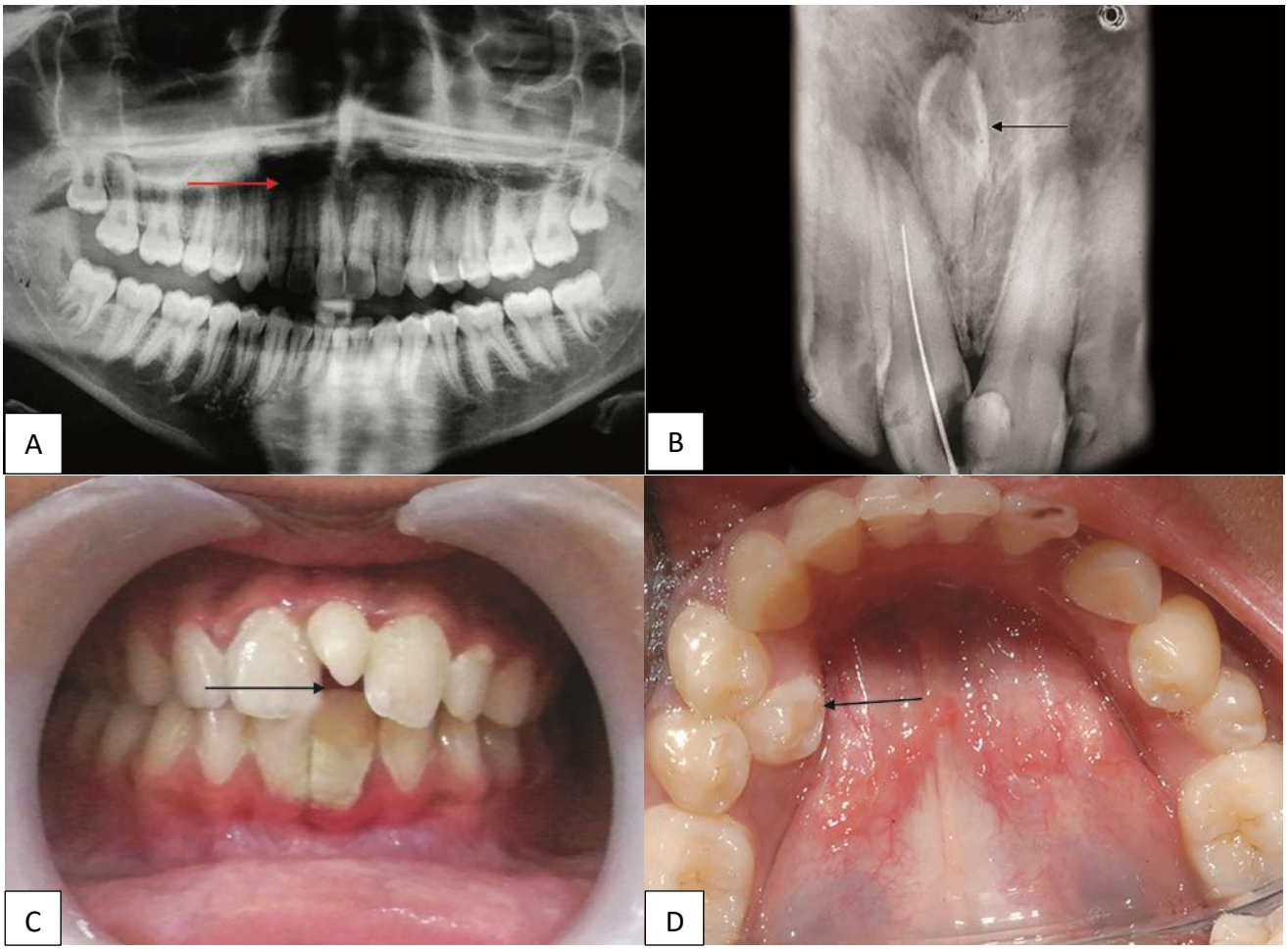

Figure 1 Demonstrates supernumerary teeth in general.

Congenitally Missing Teeth

- The occurrence of congenitally missing teeth may be single or multiple, unilateral or bilateral, and in one or both jaws **(Figs 2 A and B)**.
- Anodontia or congenital absence of teeth may be of two types, total and partial. Total anodontia in which all teeth are missing may involve both deciduous and permanent teeth.
- Total anodontia is quite rare and usually occurs in association with hereditary ectodermal dysplasia whereas, partial anodontia, involving one or more teeth is rather common.
- The term hypodontia is used for the absence of only a few teeth; oligodontia refers to the absence of many but not all teeth.



FIG 2 (A) Bilateral congenitally missing permanent lateral incisors causing spacing.

(B) Radiographic representation of the same

ANOMALIES OF TOOTH SIZE

Anomalies of tooth size may occur in two forms: microdontia or macrodontia. The term microdontia is used to describe teeth, that are smaller than normal (Fig. 3A). Microdontia can be generalized involving all the teeth in a dentition, or localized involving a single tooth. Localized microdontia most commonly affects maxillary lateral incisors and third molars (Fig. 3B). □ The term macrodontia (Fig. 3C) refers to teeth that are larger than normal. Like microdontia, macrodontia can also be generalized or localized.

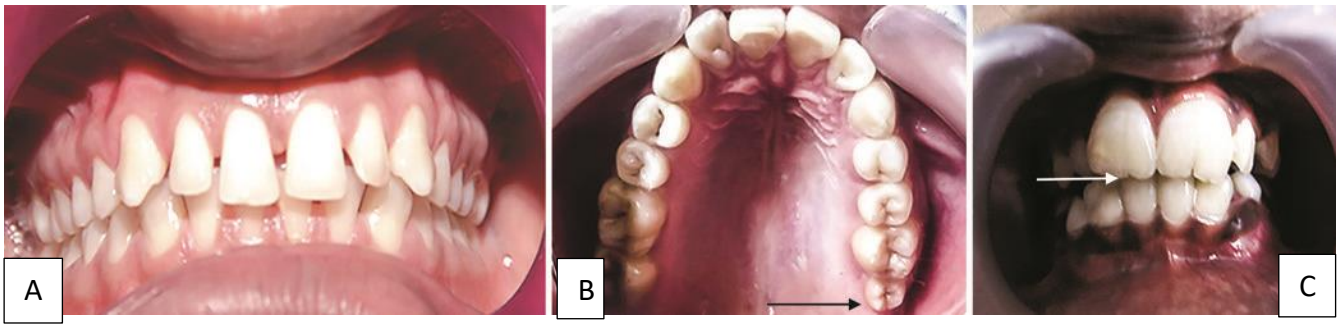

Figure 3 (A) Relative microdontic causing spacing in the anterior region of the arches; (B) Microdontic right maxillary second molar; □&□ Macrodontic right maxillary central incisor causing crowding in the arches—Intraoral frontal view

ANOMALIES OF TOOTH SHAPE

Anomalies of tooth shape often occur in association with anomalies of tooth size. Some of the anomalies of tooth shape with considerable significance in orthodontia are listed They may predispose to malocclusion.

Talon's Cusp Anomalous structures projecting from the cingulum of maxillary permanent incisors **(Figs 4 A and B)**	When large, Talon's cusp may prevent establishment of normal overbite and overjet Forces from the antagonistic tooth in occlusion with Talon's cusp may cause labial tipping of the affected tooth
Peg Laterals The maxillary lateral incisors with incisally converging mesial and distal surfaces to give a peg-shaped appearance **(Fig. 4 C and D)**	Spacing in the arch Migration of adjacent teeth Abnormal incisors relationship
Leong Premolar An accessory cusp or a globule of an enamel on occlusal surface between buccal and lingual cusps of premolars **(Fig. 4 E and F)**.	The *extra* cusp may prevent normal intercuspation with the opposing tooth
Mulberry Molars/Moon's Molar globules of enamel on occlusal surface rather than well-formed cusps "Screw drivers" shaped incisors with a notch by the incisal edges may also be seen in congenital syphilis	Irregular occlusal surface of molars may prevent formal intercuspation of posteriors
Fusion Fusion of adjacent teeth due to union of two normally separated tooth germs	Spacing in the arch
Gemination Division of a single tooth germ with resultant incomplete formations of two teeth **(Figs 4 G an)**	Discrepancy in arch length and tooth material that may cause crowding (if multiple teeth are affected)
Dilaceration An abnormal angulation in the root of a tooth or between crown and the root	The tooth may fail to erupt up to normal level

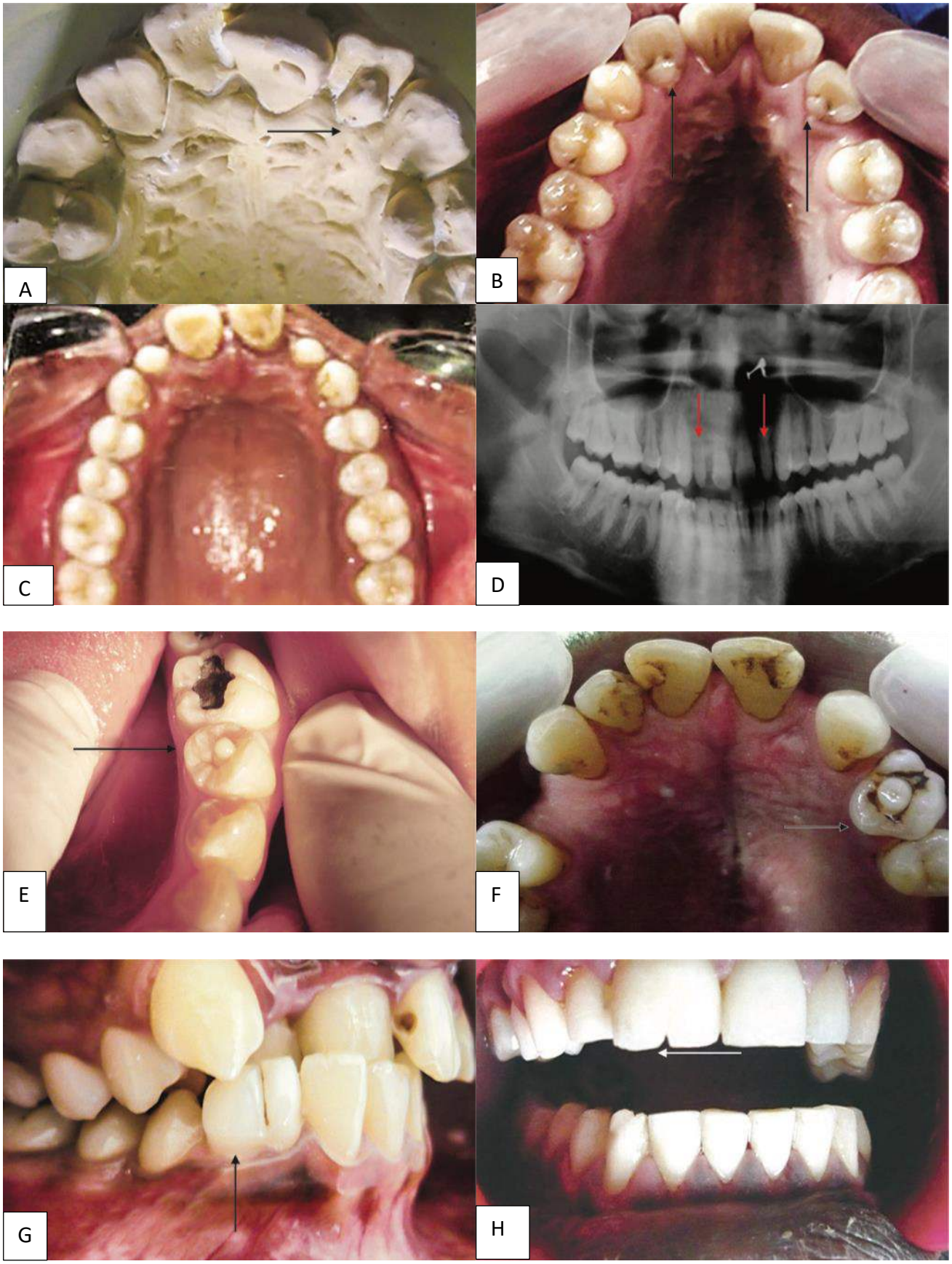
A
B
C
D
E
F
G
H

PREMATURE LOSS OF DECIDUOUS TEETH

This is a condition where a primary tooth is lost before its permanent successor is ready to erupt. The adjacent teeth get sufficient time to migrate into the created space, thereby delaying, preventing, and deviating the path of eruption of the succeeding permanent tooth. Premature loss of deciduous teeth, if not intercepted often leads to malocclusion. Deciduous teeth may be lost prematurely due to dental caries, trauma, and hyperthyroidism.

Possible consequences of premature loss of deciduous teeth on occlusion are listed

Premature loss of	*Possible consequences*
Deciduous anterior teeth	**Spacing in the arch.** **A shift in the midline, if primary canine is lost from one side of the arch only**
Deciduous molars	**Premature loss of deciduous second molar** **Mesial migration of the permanent molar** **Loss of arch length** **Lack of space for permanent second premolar to erupt** **Permanent second premolar forced to erupt lingually/buccally** Crowding in posterior segment
Premature loss of deciduous Maxillary second molar	**Mesial migration of permanent molars** **Loss of arch length** **Maxillary canine, the last anterior tooth to erupt may cause changes its path of eruption and erupt labially** **crowding in the anterior segment**

PROLONGED RETENTION OF DECIDUOUS TEETH

There are a number of causes for the prolonged retention of deciduous teeth as listed below:

- ·Absence of underlying permanent tooth
- ·Nonvital deciduous tooth, which fails to resorb
- ·Ankylosed deciduous teeth that do not resorb
- ·Endocrinal disturbances, for example, hypothyroidism.

A retained deciduous tooth may be left untouched if its permanent successor is congenitally missing as evidenced by radiographic evaluation.

DELAYED ERUPTION OF PERMANENT TEETH

Some of the common causes of delayed eruption of permanent teeth are listed below:

- The presence of supernumerary teeth, for example, mesiodens can delay the eruption of maxillary centrals.
- Retained deciduous root fragments in the jaw may delay or displace the erupting successor tooth
- The presence of a thick mucosal barrier overlying the erupting tooth or teeth.
- Premature loss of the deciduous tooth can delay the eruption of the successor.
- Ankylosed deciduous teeth that do not resorb can delay the eruption of their successor.
- Endocrinal disturbances like hypothyroidism.

Abnormal labial frenum

At birth, the labial frenum is attached to the alveolar ridge, with fibers running into the lingual interdental papilla. As the teeth erupt and as alveolar bone is deposited, the frenum attachment migrates superiorly with respect to the alveolar ridge. In some cases, fibers may persist below the maxillary central incisors and in the "V" shaped intermaxillary suture.

Abnormal labial frenum attachment can be diagnosed clinically by a blanch test. When the upper lip is pulled forward upward, blanching of the tissue just lingual to the maxillary central incisors in the region of the incisive papilla is observed.

Radiographic examination reveals a notch-like radiolucency seen interdentally between two maxillary centrals near the alveolar crest. The presence of an abnormal labial frenum attachment prevents the approximation of two central incisors leading to spacing between these two teeth called midline diastema (**fig 5**). Nevertheless, other possible causes of midline diastema, such as mesiodens, abnormal pressure habits, racial tendencies, and congenitally missing or microdontic teeth should be ruled out before attempting frenectomy.



Figure 5 shows blanch test.

DENTAL CARIES

Dental caries is one of the most common local causes of malocclusions.

Proximal caries or complete loss of affected tooth with dental caries may cause the following effects:

- Premature loss of the affected tooth or proximal caries.
- Proximal caries can cause drifting of adjacent teeth into space created with resultant loss of arch length
- Premature loss of the affected tooth can cause migration of adjacent teeth into the space.
- Abnormal inclination of adjacent teeth.
- Over eruption of antagonistic teeth.

The end of part 1