Lec 15: Extraoral Radiography د.هبه عزت بيرم

(Craniofacial projections, Cephalometric projections, TMJ projections)

The extraoral radiographs are so named because the film is placed outside the oral cavity and the extraoral views are used when it is necessary to examine areas not fully covered by intraoral films or to visualize the skull and facial structures. These radiographs are made by placing the film in a cassette against the side of the head or face and projecting the X-rays from the other side.

Main indications of extra-oral radiographs:

- Examine large areas of the jaws and Skull.
- Study growth and development of bone and teeth
- Detect fractures and evaluate trauma
- Detect pathological lesions and Diseases of the jaws
- Detect and evaluate impacted teeth.
- Evaluate TMJ Disorders.

Uses of extra-oral radiographs:

Orthodontists: Uses lateral cephalometric radiograph to measure and compare changes in growth and development of bone and teeth through pre & progress and post treatment records.

Prosthodontists: Use facial profile radiographs (lateral cephalometric) to record:
- The contour of the lips and the face
- The relationship of the teeth before removal, this will help them construct prosthetic appliances that look natural.

Oral surgeons: use extra-oral radiographs extensively to valuate trauma, determine the location and extent of fractures, locate impacted teeth & abnormalities, malignancies and injuries to TMJ.

Craniofacial and skull projections:

➢ Lateral jaw projection (lateral oblique projection):

Lateral jaw projection is useful to examine the posterior region of the mandible, valuable for use in children, and in patients who have difficulty in

stabilizing or tolerating intraoral film placement, patients with restricted mouth opening due to a fracture or swelling and locate impacted teeth or large lesions.

Two types of lateral jaw projection are:

- Body of the mandible projection
- Ramus of the mandible projection

1- Body of the mandible projection:

This projection is used in the evaluation of impacted teeth, fracture of the body of the mandible and any pathology (cysts or tumors) involving the mandibular premolar-molar region and inferior border of the mandible.

Technique:

- The film is kept flat against the cheek of the required side and is centered over the body of the mandible. The head is tilted 15 degrees to the side being imaged and the chin is elevated and extended upward.
- The central X-ray beam is directed perpendicular to the horizontal plane of the cassette with a vertical angulation of -15 to -20 degrees. The x-ray beam should enter at a point centered on the body of the mandible.



2- Ramus of the Mandible Projection:

It gives view of the ramus from the angle of the mandible to the condyle. It is very useful for examining third molar region of maxilla and mandible.

Technique:

- The film is held flat on the cheek of the required side and centered over the ramus of the mandible. The head is tilted 15 degrees towards the required side and the chin is elevated and extended.
- The central X-ray beam should be perpendicular to the plane of the cassette at a vertical angulation of -15 to -20 degrees and centered on the ramus of the mandible.



➢ Submentovertex projection:

Submentovertex (SMV) or Base Projection: In this projection the patient's neck is extended as far backward as possible and the central beam is perpendicular to the image receptor, directed from below the mandible toward the vertex of the skull (so named SMV), it displays the base of the skull, the zygomatic arches fracture, and the sphenoid sinuses, hard palate, and mandible.

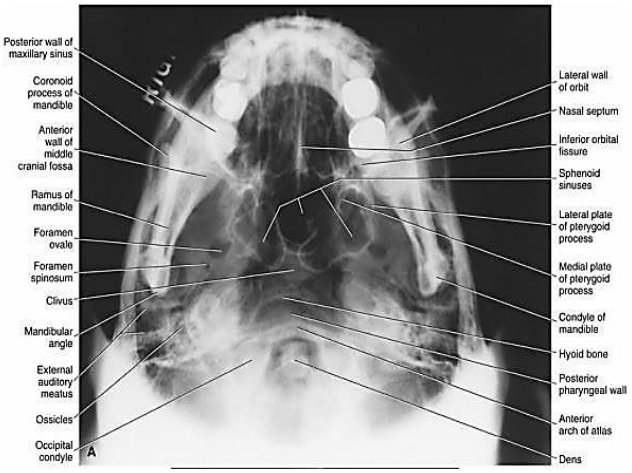

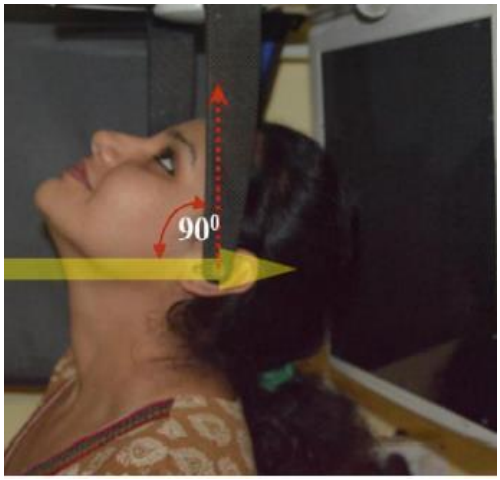

➢ Waters projection (paranasal sinus or PNS view):

This projection is used in the evaluation of the maxillary sinus, also demonstrates the frontal and the ethmoid sinuses, the orbits, zygomatico-frontal suture, and the nasal cavity.

Technique:

- The midsagittal plane is perpendicular to the film.
- The patient faces the cassette with the chin touching the cassette. The tip of the nose is positioned 1/2 to 1 inch away from the cassette.
- The central x-ray beam is perpendicular to the film.



➢ Postero - anterior projection (P-A view):

Posteroanterior projection or PA view is so named because the X-ray beam passes in a posterior- to anterior direction through the skull. This projection is used in the evaluation of facial growth and development, asymmetry, trauma, any pathology and developmental anomalies. This projection demonstrates the frontal and ethmoidal sinuses, the orbits and the nasal cavity.

Technique:

- The patient faces the cassette in such a way that the forehead and the nose touch the surface. Frankfort plane is parallel to the floor.
- The central x-ray beam is aligned perpendicular to the center of the head and the cassette.

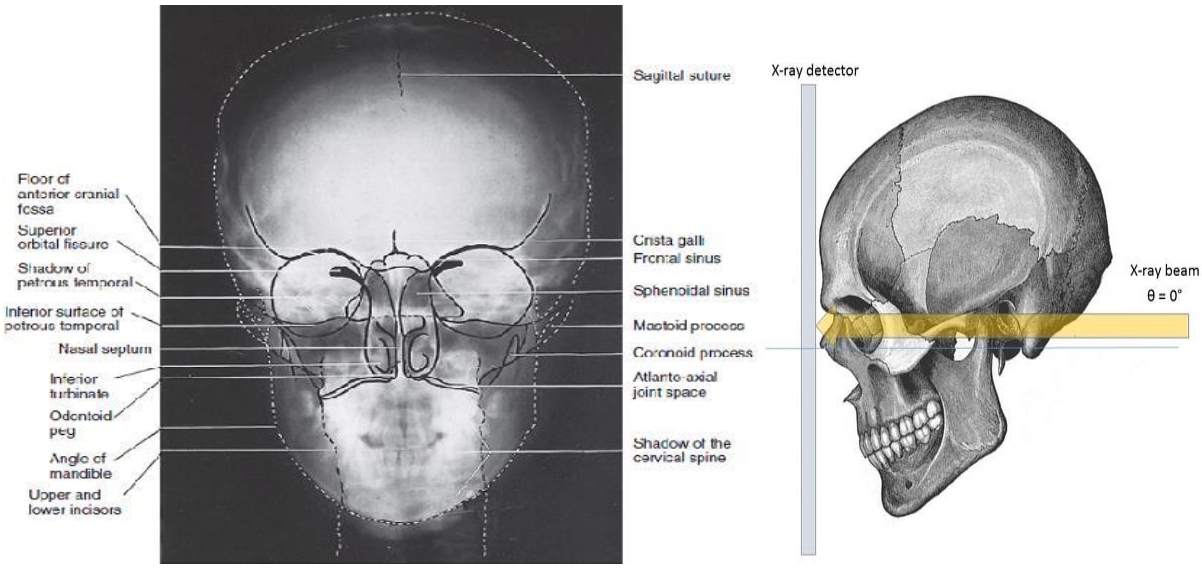

➢ Towne's and Reverse Towne's projection:

Towne's projection: performed with the face toward the X-ray device. It is also called AP (Antero-posterior) projection. It is helpful in evaluating the occipital (posterior/ back) skull bone.

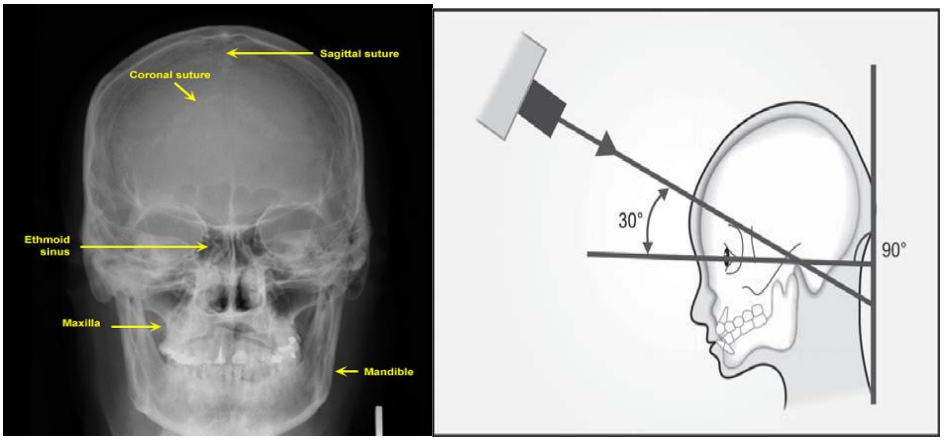

Reverse Towne's projection: It helps in the identification of fractures involving the condylar neck and the ramus area. The patient faces the cassette and the head is tipped down with the mouth in wide open position. The chin almost rests on the chest, whereas the top of the forehead touches the cassette. The central x-ray beam is directed through the center of the head and the cassette.

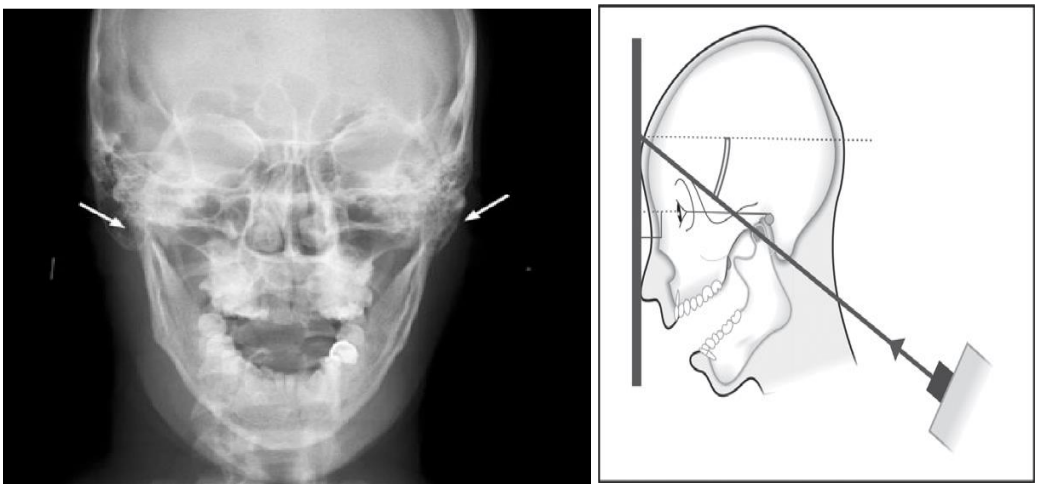

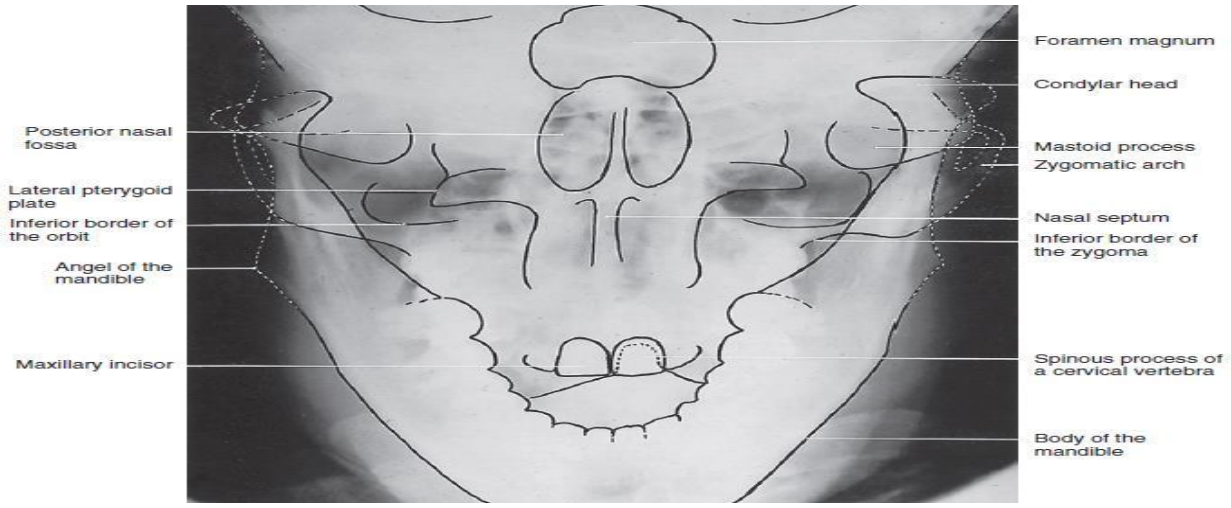

	LATERAL CEPH	SMV	WATERS	PA CEPH	REVERSE TOWNE
Patient placement	Film parallel to midsagittal plane	Canthomeatal line parallel to film	Canthomeatal line at 37° with film	Canthomeatal line at 10° with film	Canthomeatal line at –30° with film
Central beam	Beam perpendicular to film	Beam perpendicular to film	Beam perpendicular to film	Beam perpendicular to film	Beam perpendicular to film
Diagram of patient placement	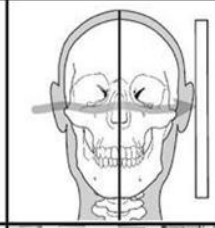	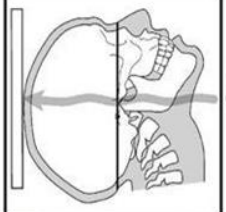	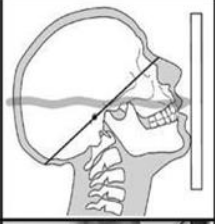	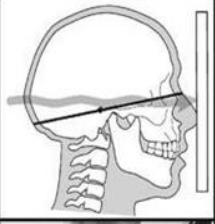	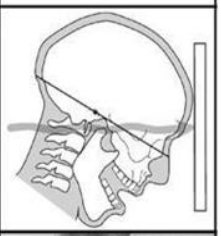
Illustration of patient placement					
Skull view	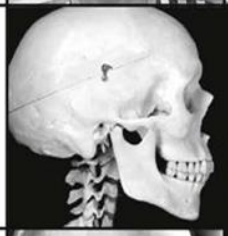	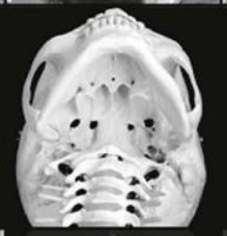			
Resultant image			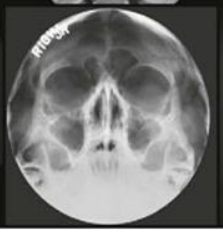		

Cephalometric projections:

They are standardized projections made with a Cephalostat, which helps to maintain a constant relationship between the skull, the receptor, and the x-ray beam. A cephalometric projection used a long source-to-object distance of 5 ft; to minimizes image magnification. The object-to-receptor distance is typically 10 to 15 cm. These projections using film or digital receptors. There are 2 main types of cephalometric projections:

Lateral Cephalometric Projection (Lateral Skull Projection):



Indications:

1) A pretreatment record prior to the placement of appliances.
2) Evaluate the relationships between the maxilla, mandible, and cranial base, in addition to soft-tissue relationships.
3) Monitor progress of orthodontic treatment and treatment outcomes.
4) Proceed with orthognathic surgical treatment planning.

Technique and positioning: The image receptor positioned parallel to the patient's midsagittal plane, the patient is placed with the left side toward the image receptor and asked to occlude in his normal intercuspation position. The central beam is perpendicular to the midsagittal plane and the image receptor centered over the external auditory meatus. Exact superimposition of right and left sides is impossible because the structures on the side near to the image receptor are magnified less than the same structures on the side far from the image receptor.

Postero-anterior cephalometric projection:

Indications

1) Evaluate craniofacial asymmetry.
2) Assess jaw skeletal relationships.
3) Monitor progress of treatment and treatment outcomes.
4) Proceed with orthognathic surgical treatment planning.

Technique and positioning: The image receptor placed in front of the patient, perpendicular to the midsagittal plane and parallel to the coronal plane. The central beam is perpendicular to the image receptor, directed from posterior to anterior

(hence the name PA) at the level of the bridge of the nose. Another lateral skull and PA projection are made without cephalostat or standardization; used when a single lateral view of the skull is required like middle third facial fractures but not in orthodontics or growth studies.

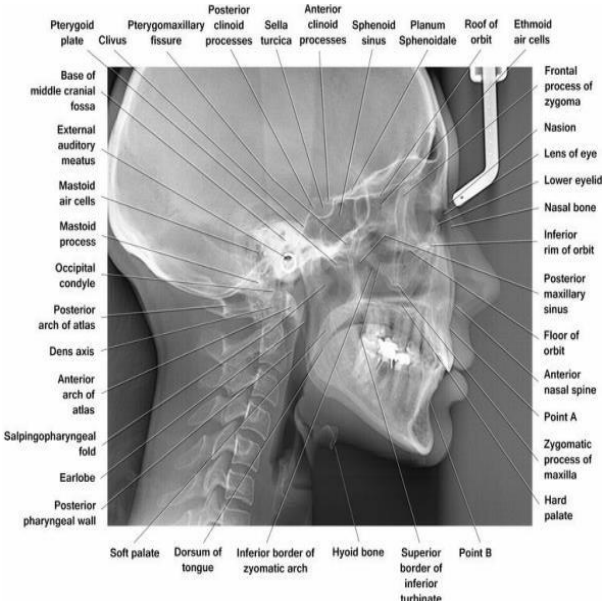

Anatomic landmarks identified in the lateral cephalometric projection.

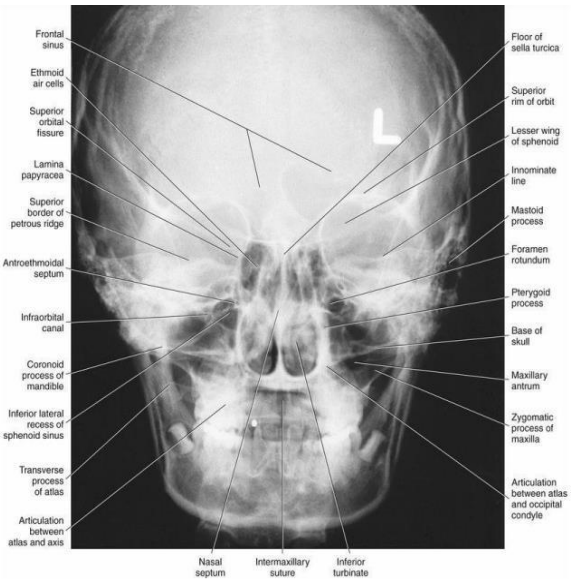

Anatomic landmarks identified in the PA cephalometric projection.

Most common Cephalometric Landmarks

Skeletal Landmarks

1. Porion (P): Most superior point of the external auditory canal
2. Sella (S): Center of the hypophyseal fossa
3. Nasion (N): Frontonasal suture
4. Orbitale (O): Most inferior point of the infraorbital rim
5. PNS: Tip of the posterior nasal spine
6. ANS: Tip of the anterior nasal spine
7. A point (A): Deepest point of the anterior border of the maxillary alveolar ridge concavity
8. B point (B): Deepest point in the concavity of anterior border of the mandible
9. Pogonion (Po): Most anterior point of the symphysis
10. Gnathion: Midpoint of the symphysis outline between pogonion and menton
11. Menton (M): Most inferior point of the symphysis
12. Gonion: Most convex point along the inferior border of the mandibular ramus

Soft Tissue Landmarks

1. Soft tissue glabella: Most anterior point of the soft tissue covering the frontal bone
2. Soft tissue nasion: Most concave point of soft tissue outlines at the bridge of the nose
3. Tip of nose: Most anterior point of the nose
4. Subnasale: Soft tissue point where the curvature of the upper lip connects to the floor of the nose
5. Soft tissue A point: Most concave point of the upper lip between the subnasale and the upper lip point
6. Upper lip: Most anterior point of the upper lip
7. Lower lip: Most anterior point of the lower lip
8. Soft tissue B point: Most concave point of the lower lip between the chin and lower lip point
9. Soft tissue pogonion: Most anterior point of the soft tissue of the chin
10. Soft tissue gnathion: Midpoint of the chin soft tissue outline between the soft tissue pogonion and soft tissue menton
11. Soft tissue menton: Most inferior point of the soft tissue of the chin

Definition of Cephalometric Landmarks

A. Skeletal Landmarks

1) Porion (P): Most superior point of the external auditory canal
2) Sella (S): Center of the hypophyseal fossa
3) Nasion (N): Frontonasal suture
4) Orbitale (O): Most inferior point of the infraorbital rim
5) PT point: Most posterior point of the pterygomaxillary fissure
6) Basion (Ba): Most anterior point of the foramen magnum
7) PNS: Tip of the posterior nasal spine
8) ANS: Tip of the anterior nasal spine
9) A point (A): Deepest point of the anterior border of the maxillary alveolar ridge concavity
10) B point (B): Deepest point in the concavity of anterior border of the mandible
11) Pogonion (Po): Most anterior point of the symphysis
12) Gnathion: Midpoint of the symphysis outline between pogonion and menton
13) Menton (M): Most inferior point of the symphysis
14) Gonion: Most convex point along the inferior border of the mandibular ramus
15) Ramus point: Most posterior point of the posteroinferior border of the mandibular ramus
16) Condyle top: Most superior point of the condyle

B. Soft Tissue Landmarks

1) Soft tissue glabella: Most anterior point of the soft tissue covering the frontal bone
2) Soft tissue nasion: Most concave point of soft tissue outline at the bridge of the nose
3) Tip of nose: Most anterior point of the nose
4) Subnasale: Soft tissue point where the curvature of the upper lip connects to the floor of the nose
5) Soft tissue A point: Most concave point of the upper lip between the subnasale and the upper lip point
6) Upper lip: Most anterior point of the upper lip
7) Lower lip: Most anterior point of the lower lip
8) Soft tissue B point: Most concave point of the lower lip between the chin and lower lip point
9) Soft tissue pogonion: Most anterior point of the soft tissue of the chin
10) Soft tissue gnathion: Midpoint of the chin soft tissue outline between the soft tissue pogonion and soft tissue menton
11) Soft tissue menton: Most inferior point of the soft tissue of the chin

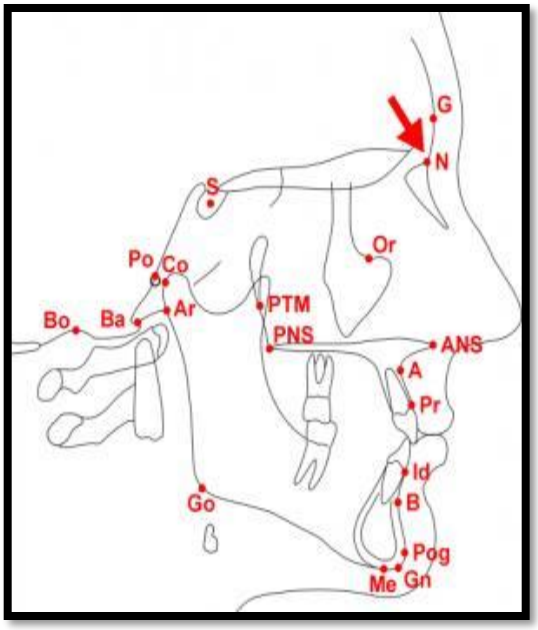

cephalometric landmarks (skeletal landmarks)

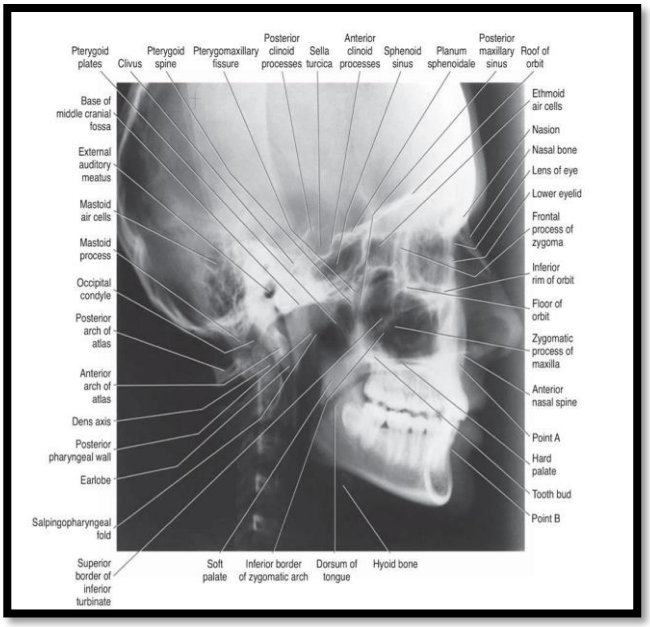

Anatomic landmarks in the lateral cephalometric projection.

TMJ projections:

It helps in visualization of the glenoid fossa, the mandibular condyle and the articular eminence of the temporal bone. It can also be used to determine the joint space and to evaluate the extent of the movement of condyle when the mouth is opened.

Types of imaging techniques

1. Plain radiographs (transcranial, transorbital, transpharyngeal projections)
2. Panoramic radiography (OPG)
3. Cone beam computed tomography (CBCT) and Multidetector computed tomography (MDCT)
4. MRI and ultrasonography (for soft tissue imaging)

The various TMJ views are:

- Transcranial view
- Transorbital view
- Transpharyngeal view
- TMJ tomography

Transcranial view:

It helps to evaluate the joint's bony relationship include condyle, articular eminence and joint space. The cassette is placed flat against the patient's ear and centered over the TM joint of interest, against the facial skin parallel to the sagittal plane. Point of entry of the central beam projected across the cranium passing through the TMJ from other side either with Closed-mouth or Open mouth position.

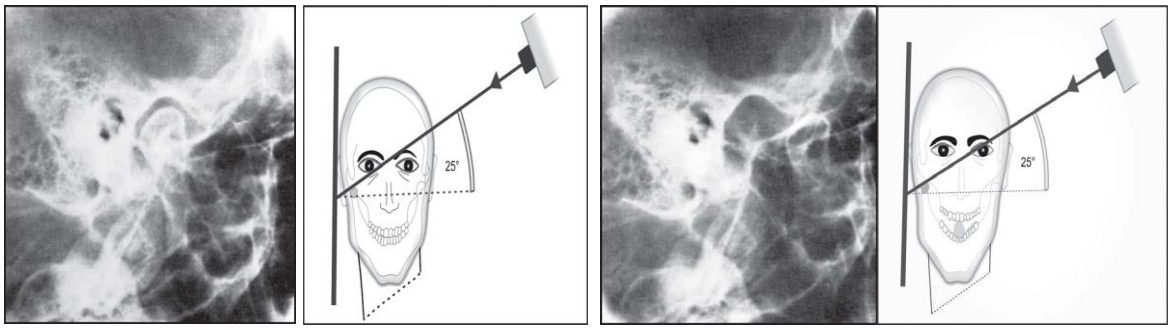

Transorbital view: also called (Zimmer or transmaxillary projection)

It helps in visualization of the joint with less superior imposition. It allows to view the condyle, the articular eminence and condylar neck. The head of the patient is tipped down about 10 degrees in such a way that the canthomeatal line is horizontal. The midsagittal plane is kept at 30 degrees to the central x-ray beam by moving the head to the left for left side projection and to the right for right side projection. The cassette is positioned behind the patient's head and the central x-ray beam is directed through the ipsilateral orbit and through the required TMJ, exiting from the skull behind the mastoid process. During the exposure, the patient is asked to open the mouth as wide as possible.

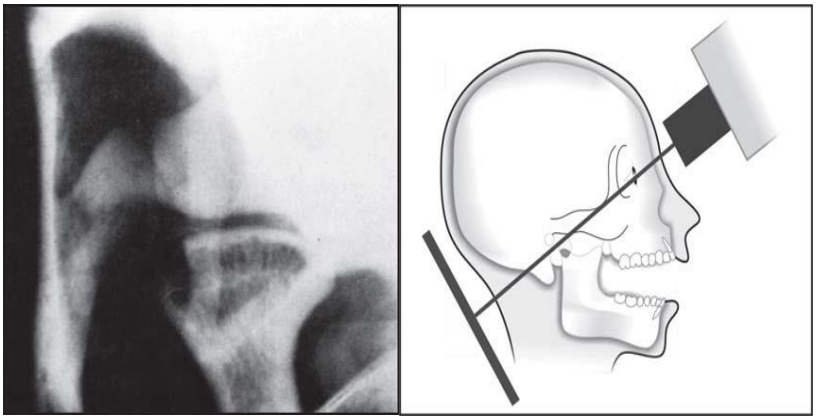

Transpharyngeal view:

It also called infracranial view. This projection demonstrates fractures of the condyle and the condylar neck and in detecting alterations in the condylar morphology. The film cassette is positioned against the side of patient's head, parallel to the sagittal plane next to TMJ of interest. The central X-ray directs below the base of the skull through the oropharynx to TMJ 5–10 degrees, before film exposure the patient opens the mouth wide.

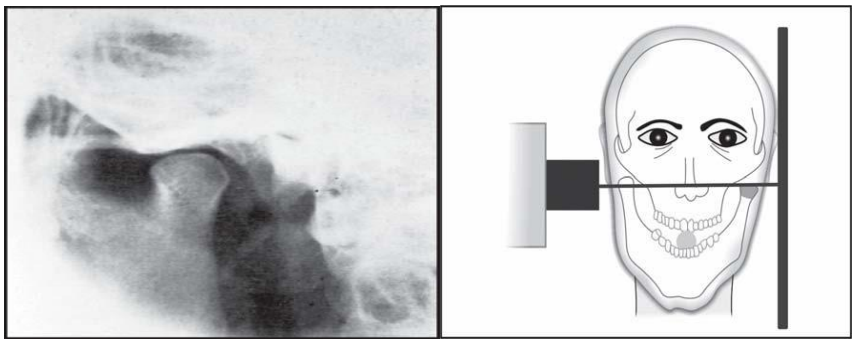

TMJ tomography view:

It helps in the visualization of the condyle, articular eminence, and the glenoid fossa. It can also be used to determine the joint space and to evaluate the extent of movement of the condyle when the mouth is opened. It is accomplished by moving the film and the x-ray tube head in opposite directions around a rotation point.

