Furcation involvement:

The term furcation involvement" refers to invasion of the bifurcation and/or trifurcation of multirooted teeth by periodontal disease.The primary etiological factor for furcation involvement is bacterial plaque which plays an important role in the etiology of gingivitis and destructive periodontal disease & the long – standing inflammation of periodontal tissues.

Consequently, therapeutic measures aimed to eliminate gingival inflammation and arresting progression of periodontal tissue breakdown must include the careful removal of microbial deposits from the tooth surfaces and the establishment of home-care program which prevents recurrence of gross amount of plaque and calculus.

The progression of the bacterial plaque apically along the root surface not occur only vertically, but also horizontally leading to furcation involvement.

Terms frequently used in furcation involvement

Root complex :

is the portion of a tooth that is located apical to the cemento-enamel junction (CEJ), i.e. the portion that normally is covered with a root cementum.The root complex may be divided into two parts: the root trunk and the root cone(Fig.1).

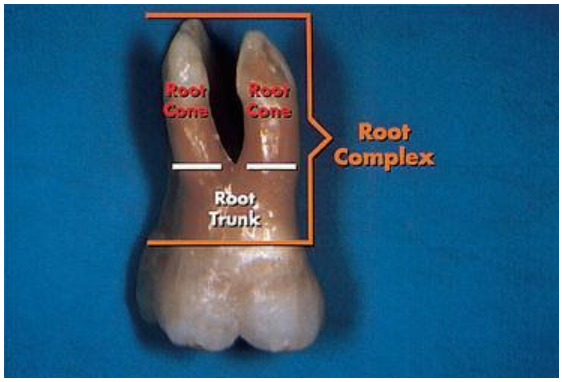

Fig.1

Root trunk :

represents the undivided region of the root. The height of the root trunk is defined as the distance between the CEJ and the separation line (furcation) between two root cones (roots). Depending on the position of the separation line the height of the root trunk may vary from one surface to the next in one given molar or premolar.

The root cone:

is included in the divided region of the root complex. The root cone (root) may vary in size and position and may at certain levels be connected to or separated from other root cones. Two or more root cones make up the furcated region of the root complex .

The furcation:

is the area located between individual root cones.

The furcation entrance:

is the transitional area between the undivided and the divided part of the root (Fig.2)

The furcation fornix:

is the roof of the furcation (Fig.2)



Fig. 2

Anatomical characteristics:

The anatomy of the roots and the topography of the alveolar bone in the furcation areas of multi-rooted teeth in a periodontal patient can be examined if a muco-periostal flap is elevated. General information regarding the anatomy of the furcation areas of multi-rooted tooth may be gained from " autopsy material".

If the buccal bone plates are removed from an autopsy preparation, the buccal furcas are exposed as well as the location of the furcas in relation to cemento-enamel junction.

The position and spread of the roots of the maxillary molars often give rise to a large areas of inter radicular supporting bone. A thin buccal bone plates is sometimes associated with the presence of fenestrations (window-like exposed area) and/or dehiscence in combination with gingival recession.

The use of radiographs to identify the structures in the furcations area is generally of limited value. Hences in maxillary molars, frequently only the buccal furca can be properly identified and in the mandibular molars the images of the buccal and tooth and bone structures often become super imposed over the furcation areas. Parallel and bitewing films can be used to discover these areas.

The fact that furcas may be present in teeth which normally have only one root should be also in consideration. Thus 2-rooted incisors or canines and

mand. Premolars may exist. Occasionally, 3-rooted max. premolars and 4-rooted mand. molars can be found.

There are some morphological variations that must be considered in the diagnosis and treatment of furcation involved teeth .These are:

1- Fusions between divergent roots (Fig.3)

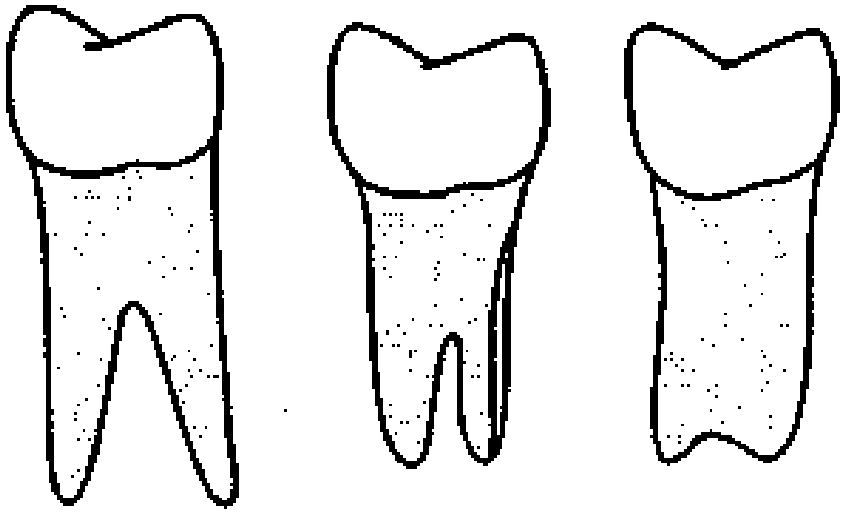

Widley seperated roots Close to one another Fused roots

2- cervical enamel projection or enamel pearl in the furcation areas
They occur approximately in 15 percent of molars. They favor plaque accumulation and must be removed to facilitate scaling and root planing. It was classified by Masters and Hoskins in 1964 as:

Grade I: The enamel projection extends from the cementoenamel junction of the tooth towards the furcation entrance.

Grade II: The enamel projection approaches the entrance to the furcation but does not enter the furcation and hence has no horizontal component.

Grade III: The enamel projection extends horizontally into the furcation.

3-the presence of accessory pulp canals which communicate with the furcation area:

It is believed that once the pulp is infected through the accessory canal, endo-perio communication may result, which in turn can cause either

destruction of inter radicular periodontium or interfere with the healing response of either periodontal or endodontic procedures

4-The distance between CEJ & furcation area(Fig.4)

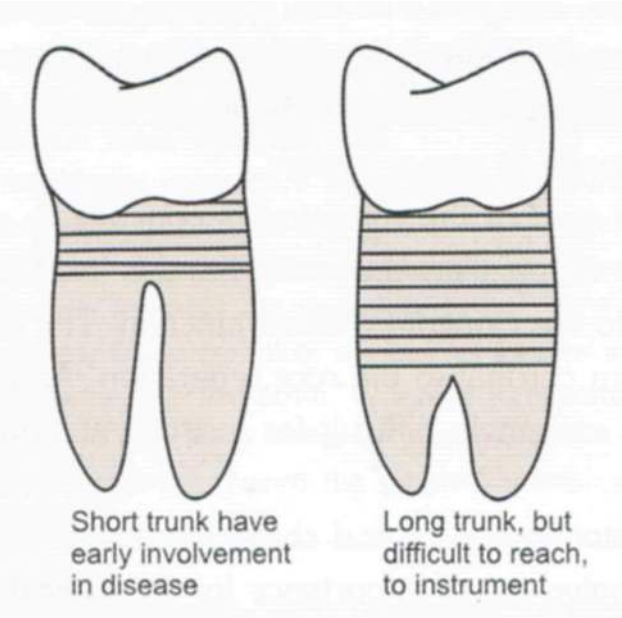

Fig.4

5-The position of the tooth in the arch.(Fig.5a,b,c,d)

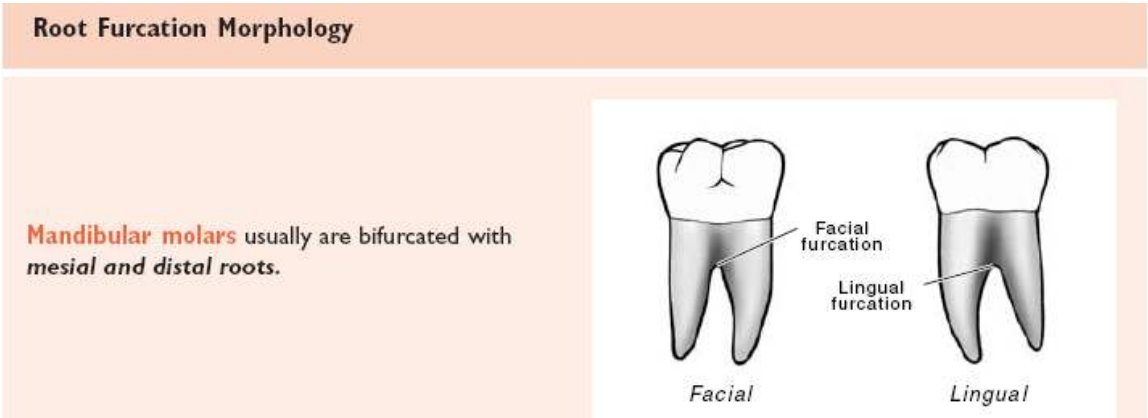

Fig.5 a

Maxillary first premolars can be bifurcated with ***buccal and palatal roots.*** When bifurcated, the roots of a maxillary first premolar separate many millimeters apical to the cemento-enamel junction.

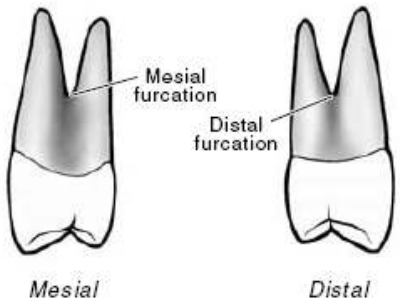

Fig.5.b

Maxillary molar teeth usually are trifurcated with ***mesiobuccal, distobuccal, and palatal*** (lingual) ***roots.***

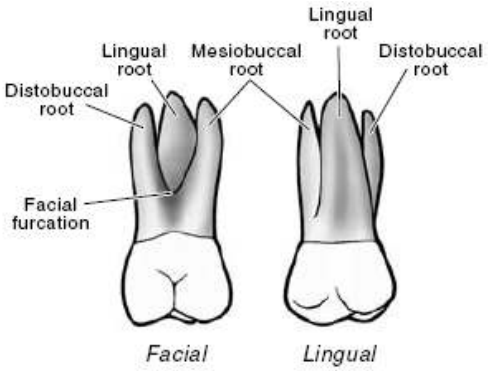

Fig.5.c

On the mesial surface of a maxillary molar, the furcation is located more toward the lingual surface.

On the distal surface of a maxillary molar, the furcation is located near the center of the tooth.

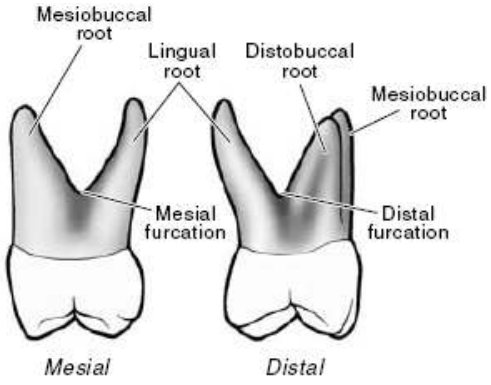

Fig.5.d

Classification of furcation involvement

Furcation involvement may be classified into 3 degrees depending on the extention of the destruction within inter-radicular area.This classification was suggested by Hamp et al. (1975) which include the following criteria

of the involved furcation:

- Class I (initial): denotes horizontal loss of periodontal tissue (PD) support not exceeding 1/3 of the width of the tooth.(fig.6a)

- Class II (partial): denotes horizontal loss of PD tissue support exceeding 1/3 of the width of the tooth but not encompassing the total width of the furcation area.(fig.6b)

- Class III (total) denotes horizontal "through and through" destruction of the PD tissues in the furcation area.(fig.6 c)

- **Class IV** when the gingiva recedes apically so that the furcation opening is seen clinically.(fig.6 d)

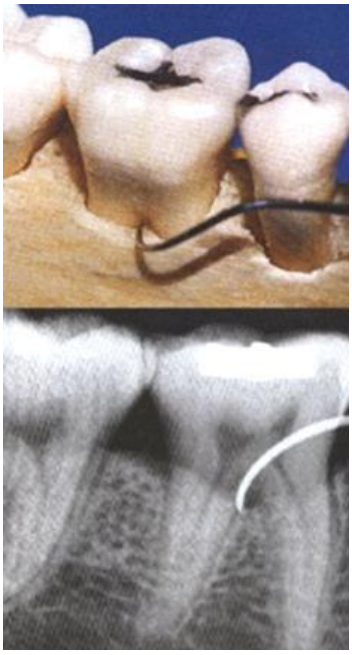

Fig.6.a



Fig.6.b

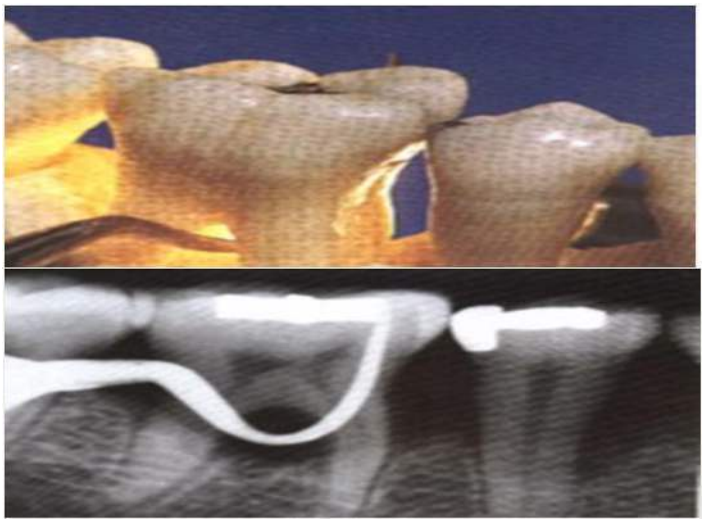

Fig.6.c

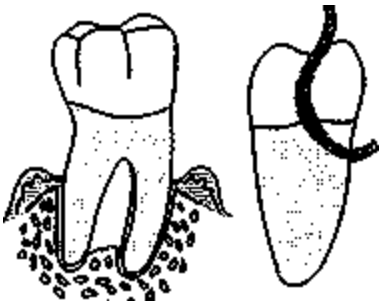

Fig.6.d

Diagnosis:

The examination should comprise both clinical probing and radiographic analysis.

Probing: The buccal furca of the max. molars and buccal and lingual furcas of the mand. molars are normally accessible for examination by clinical probing by using graduated curved periodontal Probe, explorers or small curettes(fig7). Special furcation probes are available which are rounded & have millimeter indications .These probes are called Naber probes.



Fig,7



The clinical examination of furcas on the proximal tooth surfaces may

be more difficult when neighboring teeth are present, especially if the contact area between the teeth is wide, this is particularly in case of max. molars, in which the mesial furcation entrance is located much closer to the palatal than to the buccal tooth surface. Thus, the mesial furcation should be probed from the palatal aspect of the tooth(fig8),while the furca in the distal surface is probed from either the buccal or the palatal aspect.



Fig. 8

In maxillary premolars the root anatomy often varies considerably. The roots may also harbor irregularities such as longitudinal furrows, invaginations or true furcations, which may open at varying distances from the CEJ.The clinical examination of max. premolars is often difficult due to limited access for probing. It may not always be possible to identify the presence and the degree of furcation involvement in such teeth until a flap is raised in a surgical procedure in the area.

Radiographical analysis:

Radiographs must always be obtained to confirm findings made during probing of a furcation-involved tooth. The radiographic examination should include both paralleling “periapical” and vertical “bite-wing” radiographs. In the radiographs the location of the interdental bone as well as the bone level within the root complex should be examined (fig9).



Fig.9

Situations may occur when findings from clinical probing and from the radiographs are inconsistent. Thus, the localized but extensive attachment loss which may be detected within the root complex of a maxillary molar with the use of a probe, will not always appear in the radiograph. This may be due to the superimposition in the radiograph of the palatal root and of remaining bone structures.(fig10)



Fig.10

Differential diagnosis

A lesion in the inter-radicular space of a multi-rooted tooth may be associated with problems originating from the root canal or be the result of occlusal overload. The treatment of a furcation-involved tooth, therefore, should not be initiated until a proper differential diagnosis of the lesion has been made.

Pulpal pathosis may sometimes cause a lesion in the periodontal tissues of the furcation . The radiographic appearance of such a defect may have some features in common with a plaque associated furcation lesion. In order to differentiate between the two lesions the vitality of the affected tooth must always be tested. If the tooth is vital, a plaque associated lesion should be suspected. If the tooth is non-vital, the furcation involvement may have an endodontic origin. In such a case, proper endodontic treatment must always precede periodontal therapy. In fact, endodontic therapy may resolve the inflammatory lesion, soft and hard tissue healing may occur and the furcation defect will disappear (fig11).

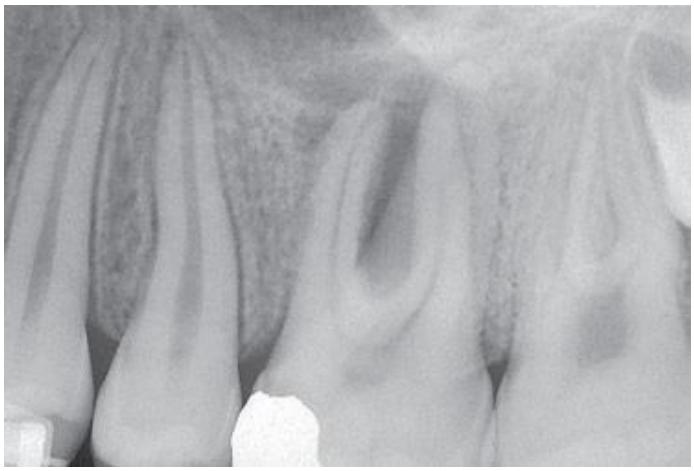

Fig.11

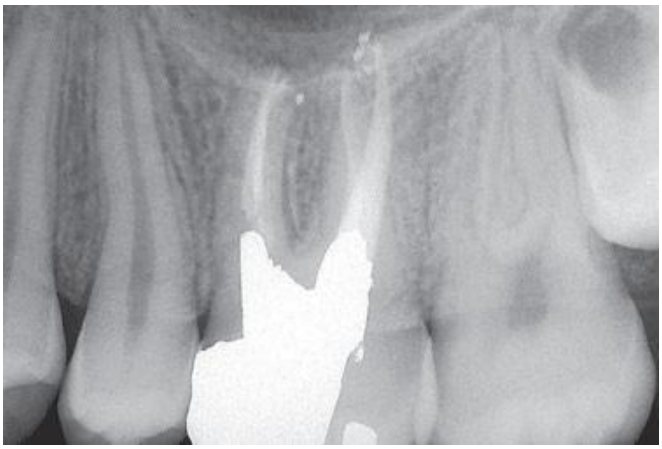

Trauma from occlusion :forces elicited by occlusal interferences, e.g. bruxers and clenchers , may cause inflammation and tissue destruction or adaptation within the inter-radicular area of a multi-rooted tooth. In such a tooth a radiolucency may be seen in the radiograph of the root complex. The tooth may exhibit increased mobility. Probing, however, fails to detect an involvement of the furcation. In this particular situation, occlusal adjustment must always precede periodontal therapy.

Prognosis :

Maxillary first premolars and maxillary as well as mandibular molars are the teeth with multiple roots. Furcation involvement will be likely to occur in these multirooted teeth. Maxillary first premolar often shows fusion of the roots and the furcation area may be located very much apically and also the roots of the maxillary first premolars are placed buccally and palatally with furcation opening in a mesiodistal direction. For these reasons, furcation involvement in maxillary first premolar has poor prognosis. In the case of maxillary molars furcations may open bucally, mesially and distally because of the presence of the three roots. Since access from proximal areas is difficult for plaque control, prognosis of furcation involvement in maxillary molars is not good. Mandibular molars have two roots, placed mesially and distally and the furcation opens buccolingually. The roots are usually divergent especially in mandibular first molars. As a result prognosis of furcation involvement in mandibular molar (especially the first molar) is considered good.