GENERAL PATHOLOGY

Lecture 11,12 HEMODYNAMIC DISORDERS

Edema:

Sixty percent of lean body weight is water, 2/3 intracellular & 1/3 is in extracellular. The latter is mostly interstitial fluid; *only 5% of total body water is in blood plasma.*

Edema *refers to" increased fluid in the interstitial tissue spaces."*
Extravascular fluid can also collect in body cavities such as the pleural cavity *(hydrotho- rax),*

pericardial cavity *(hydropericardium)*

peritoneal cavity *(hydroperitoneum,* or *ascites).*
Anasarca is severe, generalized edema marked by profound swelling of subcutaneous tissues and accumulation of fluid in body cavities.

Mechanisms of edema:

Water extravasations (outward movement) across the vascular wall into the interstitial spaces.

The movement of fluid between vascular and interstitial spaces is controlled mainly by the opposing effects of vascular hydrostatic pressure and plasma colloid osmotic pressure. Normally, the exit of fluid from the arteriolar end of the microcirculation into the interstitium is balanced by inflow at the venular end; the lymphatics drain a small residual amount of excess interstitial fluid. So any disturbances will lead to edema.

Types of edema:

1- Inflammatory edema, is a protein-rich exudate with a specific gravity that is usually greater than 1.020, occurs due to increased vascular permeability.
2-Non inflammatory edema, is a protein-poor transudate that has a specific gravity less than 1.012, occurs due to other reasons other than inflammation

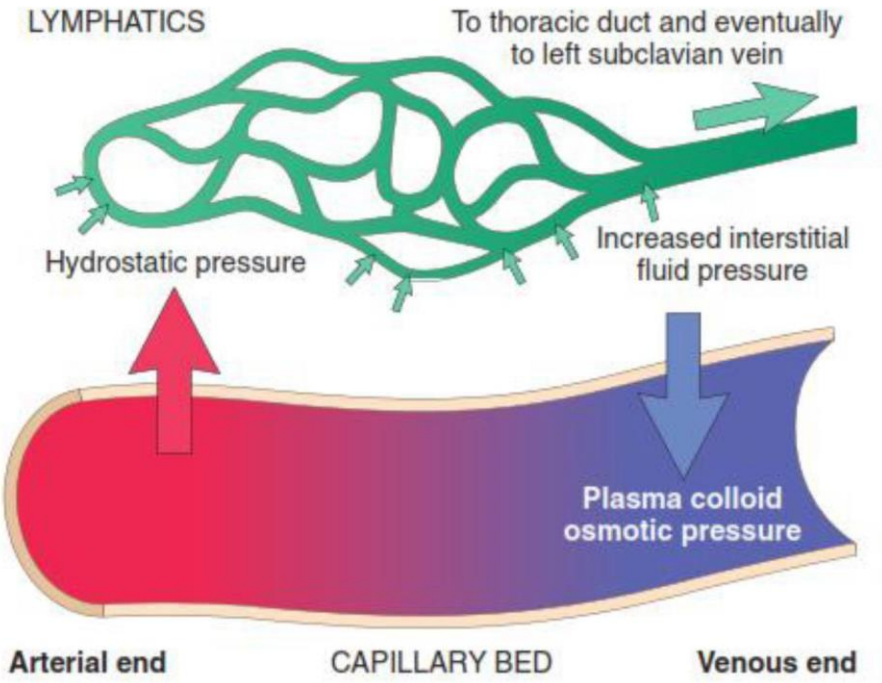

Factors influencing fluid movement across capillary walls.Capillary hydrostatic and osmotic forces are normally balanced so there is little net movement of fluid into the interstitium.

Causes of non-inflammatory edema:

1- Increased Hydrostatic Pressure.
2- Reduced Plasma Osmotic Pressure.
3- Lymphatic Obstruction.
4- Sodium and Water Retention.

1- <u>Increased Hydrostatic Pressure</u>:

Localized increases in intravascular pressure can result from impaired venous return; for example,
a- deep venous thrombosis in the lower extremities can cause edema restricted to the distal portion of the affected leg.
b. Portal hypertension caused by liver cirrhosis. This produces a transudate in the peritoneal cavity (ascites).
c. Pressure of gravid uterus on the iliac veins produces congestion and edema of the lower limbs.
d- Acute left ventricular failure causes acute pulmonary edema

Generalized increases in venous pressure, with resultant systemic edema, occur most commonly in congestive heart failure in which reduced cardiac output results in reduced renal perfusion, inducing sodium and water retention by the kidneys and eventually, edema.

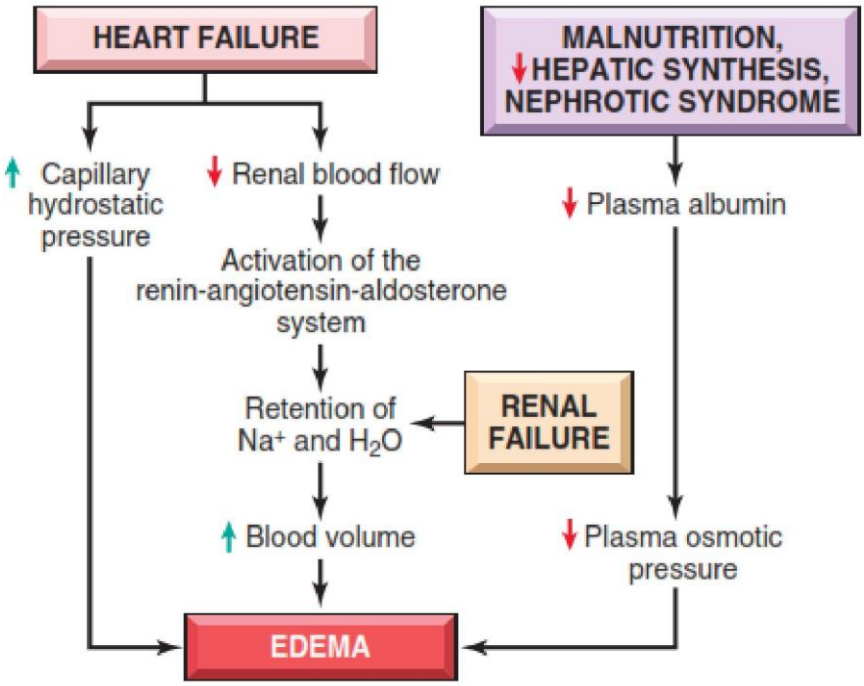

Pathways leading to systemic edema due to heart failure, renal failure, or reduced plasma osmotic pressure.

2-Reduced Plasma Osmotic Pressure:

Albumin is the serum protein synthesized by the liver, most responsible for maintaining intravascular colloid osmotic pressure; reduced osmotic pressure occurs when:

1- **Albumin is lost** from the circulation. An important cause of albumin loss is the **nephrotic syndrome**, in which glomerular capillary walls become leaky; patients typically present with generalized edema.

2- **Albumin synthesis is reduced** which occurs in diffuse liver diseases (e.g., liver cirrhosis)

3- Protein malnutrition

In each case, reduced plasma osmotic pressure leads to a net movement of fluid into the interstitial tissues resulting in edema.

3-**Lymphatic Obstruction:**

Obstruction of lymphatic drainage and consequent lymphedema is usually localized; it can result from inflammatory or neoplastic lesions. Cancer of the breast can be treated by resection and/or irradiation of the associated axillary lymph nodes; the resultant scarring and loss of lymphatic drainage can cause severe upper extremity edema.

In breast carcinoma infiltration and obstruction of superficial lymphatics can also cause edema of the overlying skin, the so-called *peau d'orange* (orange peel) appearance. Such a finely pitted surface results from an accentuation of depressions in the skin at the site of hair follicles

4-Sodium and Water Retention:

Increased salt and water causes both increased hydrostatic pressure (due to expansion of the intravascular volume) and reduced vascular osmotic pressure. Salt retention can occur in poststreptococcal glomerulonephritis and acute renal failure.

Morphology of edema:

Macroscopically, edema is most easily recognized as a swelling. Microscopically, edema fluid appears as a clearing and separation of the extracellular matrix elements with individual cell swelling.

Although any tissue can be involved, edema most commonly is encountered in subcutaneous tissues, lungs, and brain.

Subcutaneous edema: This can be diffuse or more prominent in regions with high hydrostatic pressures .Finger pressure over significantly edematous subcutaneous tissue displaces the interstitial fluid and leaves a finger-shaped depression, so-called ***pitting edema***

Edema due to renal dysfunction or nephrotic syndrome often manifests first in loose connective tissues (e.g., the eyelids, causing periorbital edema).
Pulmonary edema: This is a common clinical problem that is encountered with left ventricular failure

***Brain Edema*:** This may be localized to sites of focal injury (e.g., infarct, abscesses or neoplasms) or may be generalized, as in encephalitis, hypertensive crises, or obstruction to the brain's venous outflow. Trauma may result in local or generalized edema, depending on the nature and extent of the injury

Clinical significance of edema: Depending on its location, edema may have:

1- Minimal effects.
2- Subcutaneous tissue edema in cardiac or renal failure is important primarily because it indicates underlying disease.
3- In the lungs, edema fluid will fill alveoli and can result in life-threatening breathing difficulties.

Hyperemia and Congestion:

Both indicate a local increased volume of blood in a particular tissue. **Hyperemia** is active process resulting from increased blood flow due to **arteriolardilation** (e.g., at sites of inflammation or in skeletal muscle during exercise). The affected tissue is redder than normal because of engorgement with oxygenated blood.

Congestion is a passive process resulting from **impaired venous return** out of a tissue. It may occur systemically, as in cardiac failure, or it may be local, resulting from an isolated venous obstruction. The tissue has a blue-red color (cyanosis), especially as worsening congestion leads to accumulation of deoxygenated hemoglobin in the affected tissues..

Congestion of capillary beds is closely related to the development of edema, so that congestion and edema commonly occur together.

Chronic passive congestion: It is long-standing congestion, in which the stasis of poorly oxygenated blood causes chronic hypoxia (decrease oxygen supply), result in degeneration or death of cells and subsequent tissue fibrosis. Capillary rupture at such sites of chronic congestion can also cause small foci of hemorrhage; phagocytosis and catabolism of the erythrocyte debris can result in accumulations of hemosiderin-laden macrophages.

Morphology:

Macroscopically: Cut surfaces of hyperemic or congested tissues are hemorrhagic and wet.

Microscopically:

Acute pulmonary congestion is characterized by alveolar capillaries engorged with blood; alveolar septal edema and/or focal minute intra-alveolar hemorrhage.

In chronic pulmonary congestion the septa become thickened and fibrotic, and the alveolar spaces may contain numerous hemosiderin-laden macrophages which are called "**heart failure cells**".

In acute hepatic congestion the central vein and sinusoids are distended with blood, and there may even be central hepatocyte degeneration; the periportal hepatocytes, better oxygenated because of their proximity to hepatic arterioles, undergo less severe hypoxia and may develop only fatty change.

In chronic hepatic congestion, the central regions of the hepatic lobules are grossly red-brown and slightly depressed (because of a loss of cells) and are accentuated against the surrounding zones of uncongested tan, sometimes fatty liver, which is called **"nutmeg liver".** Microscopically, there is centrilobular necrosis of hepatocyte, hemorrhage, and hemosiderin-laden macrophages.

Hemorrhage:

It is extravasation of blood from vessels into the surrounding tissues, a hollow organ , body cavity, or to the outside.

causes:

1- Hemorrhage is most often caused by trauma.

2- chronic congestion will result in capillary rapture.

3-Coagulation disorders.

4-Vascular injury, including trauma, atherosclerosis, inflammatory or neoplastic erosion of the vessel.

Types:

1- **Hematoma**: Accumulated hemorrhage can be confined within a tissue, it could be insignificant (e.g., a bruise) or can involve so much bleeding as to cause death (e.g., Rapture of aortic artery)

2- **Petechiae**: Minute (1- 2-mm) hemorrhages into skin, mucous membranes, or serosal surfaces, typically associated with locally increased intravascular pressure, low platelet counts (thrombocytopenia), defective platelet function, or clotting factor deficiencies.

3- **Purpura:** Slightly larger (3- 5-mm) hemorrhages can be associated with many of the same disorders that cause petechiae; in addition, purpura can occur with trauma, vascular inflammation (vasculitis).

4- **Ecchymoses:** Larger (1- 2-cm) subcutaneous hematomas (bruises). The erythrocytes in these local hemorrhages are phagocytosed and degraded by macrophages; the hemoglobin (red-blue color) is enzymatically converted into bilirubin (blue-green color) and eventually into hemosiderin (golden-brown), accounting for the characteristic color changes in a hematoma.

5- Large accumulations of blood in one or another of the body cavities are called **hemothorax, hemopericardium, hemoperitoneum**, or **hemarthrosis** (in joints).

The clinical significance of hemorrhage:

1- Rapid removal of as much as 20% of the blood volume or slow losses of larger amounts may have little effects in healthy adults.
2- Greater losses, however, can cause hemorrhagic shock.
3- The site of hemorrhage is also important; bleeding that would be harmless in the subcutaneous tissues may cause death if located in the brain.
4- Chronic or recurrent external blood loss (e.g., a peptic ulcer or menstrual bleeding) causes a net loss of iron, resulting in an iron deficiency anemia.