Horizontal jaw relationship

❖ **The correct horizontal relationship for fabricating complete dentures is always the centric relation position.**

- **Centric occlusion**: The occlusion of the opposing teeth when the mandible is in centric relation.
- **Centric relation**: The maxillomandibular relationship in which the condyles articulate with the thinnest a vascular portion of their respective disks with the complex in the anterior-superior position against the shapes of the articular eminencies.
- It is restricted to a purely rotary movement about the transverse horizontal axis.

Centric relation is located by detecting the only retruded position of the mandible to the maxilla in which a clinician can obtain a purely vertical hinge movement of the mandible in relation to the maxilla.

❖ **The clinician must be able to manipulate the patient's mandible to the centric relation position, as it is:**

1) the starting reference point for complete denture fabrication,

repeatable and it can be verified, and is a functional position for denture occlusion.

2) Complete dentures should always be fabricated so their initial and complete final occlusal position is coincident with the centric relation; this position then becomes the centric occlusion position for the patient.
3) Because the centric relation position is somewhat dependent on head posture, the head should be held fairly upright.

❖ The position of the dentist's hands

- The position of the dentist's hands is an important factor in making accurate centric relation records and maintaining record bases in their correct position.
- The non-dominant hand is inverted and placed in the mouth so that the soft tissue of the thumb and index fingers lies on the opposing buccal surfaces of the maxillary and mandibular occlusion rims, between the occlusal surfaces in the first molar region.



- The other hand is used to help guide the patient to centric relation position. Care should be exercised to avoid displacing the mandibular record base in the posterior direction.
- Because it is sometimes difficult to get the patient into the CR position, it is a good idea to practice this position with the patient prior to attempting to make the recording.
- Therefore, the patient should be close to the correct OVD prior to attempting to achieve the CR position.
- It is advisable to instruct the patient to "let your jaw relax, close slowly

❖ Methods must be used to position the jaw in centric relation.

1. Having the patient completely relax the mandible while the clinician gently shakes the mandible up and down.

2. Placing the tip of the tongue in the top and back of the mouth.

3. Telling the patient to ".Stick out the upper teeth."

4. Tipping the chair and patient back to allow gravity to help position the mandible.

5. Using a mirror so that the patient can see the CR mandible position.

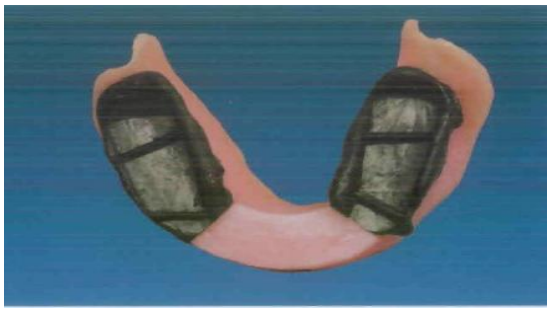

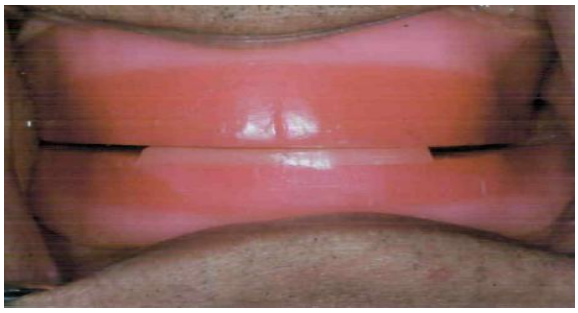

- The maxillary master cast has now been properly placed on the articulator using a face-bow recording.
- The mandibular occlusion rim has been adjusted so that there is unrestricted contact with the maxillary occlusion rim at the correct occluding vertical dimension, and it is in centric relation.
- This horizontal relationship will now be captured with some type of recording material.
- Because we must make the recording at the correct OVD, space must now be created to allow room for the record material**.**

Once the maxillary cast is properly positioned, the occlusion rims are placed on their respective casts, and the records are seated together. Observe the casts for possible contact in the posterior areas. If they make contact, the cast must be trimmed until there is no cast-to-cast contact.