Lecture 4 General Pathology

Intracellular accumulations

Sometimes abnormal amounts of various substances may be accumulated in the cells which may be harmles or causing cell injury. The substance may be located in the cytoplasm, within organelles (typically lysosomes), or in the nucleus, and it may be synthesized by the affected cells or may be produced elsewhere.

Mechanisms of intracellular accumulation.

(1) Abnormal metabolism, A normal substance is produced at a normal or an increased rate, but the metabolic rate is inadequate to remove it as in fatty change in the liver.

(2) Mutations causing alterations in protein folding and transport, so that defective molecules accumulate intracellularly. A normal or an abnormal endogenous substance accumulates because of genetic (mutation) or acquired defects in its metabolism. Ex: storage diseases in which there is inherited defect in an enzyme responsible for degradation of its metabolite.

(3) A deficiency of critical enzymes responsible for breaking down certain compounds, causing substrates to accumulate in lysosomes, as in lysosomal storage diseases.

(4) An inability to degrade phagocytosed particles, as in carbon pigment accumulation in the lung. An abnormal exogenous substance is deposited and accumulates because the cell has neither the enzymatic machinery to degrade the substance nor the ability to transport it to other sites.

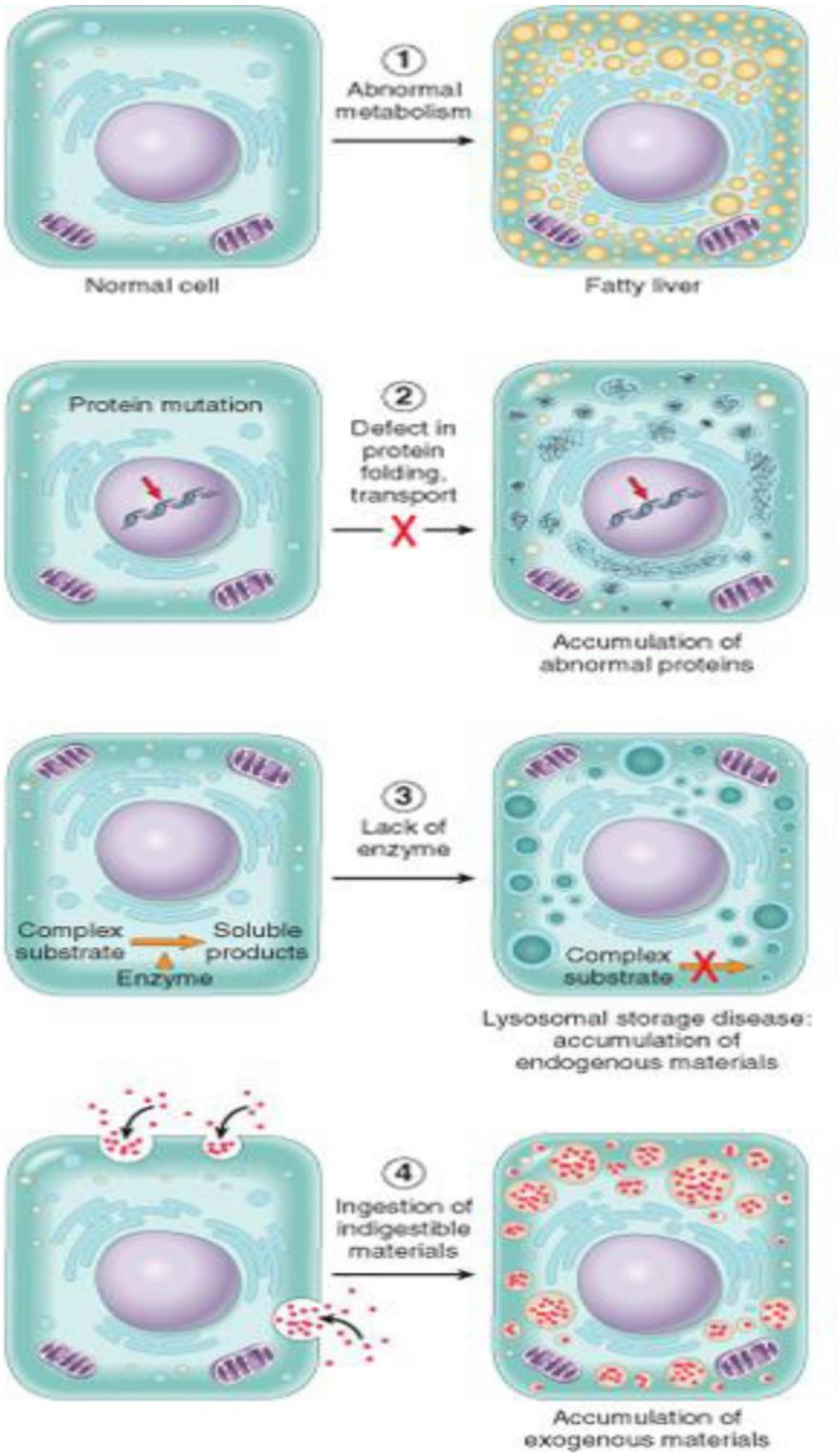

© Elsevier. Kumar et al: Robbins Basic Pathology 8e - www.studentconsult.com

Mechanisms of intracellular accumulation. (1) Abnormal metabolism, as in fatty change in the liver. (2) Mutations causing alterations in protein folding and transport, so that defective molecules accumulate intracellularly. (3) A deficiency of critical enzymes responsible for breaking down certain compounds, causing substrates to accumulate in lysosomes, as in lysosomal storage diseases. (4) An inability to degrade phagocytosed particles, as in carbon pigment accumulation.

Fatty Change (Steatosis)

Fatty change refers to any abnormal accumulation of triglycerides within parenchymal cells. It is most often seen in the liver, because it is the major organ involved in fat metabolism, but it may also occur in heart, skeletal muscle, kidney, and other organs. Steatosis may be caused by toxins, protein malnutrition, diabetes mellitus, obesity, and anoxia. Alcohol abuse and diabetes associated with obesity are the most common causes of fatty change in the liver (fatty liver) in industrialized nations.

The significance of fatty change:

1- Mild fatty change may have no effect on cellular function.
2- More severe may transiently impair cellular function (fatty change is reversible).
3- Severe form lead to cell death ending with serious liver disease.

Morphology:

In any site, fatty accumulation appears as clear vacuoles within the cells. Special staining techniques are required to distinguish fat from intracellular water or glycogen, which can also produce clear vacuoles but have a different significance.

To identify fat microscopically, Sudan IV or oil red O is used (these stain fat orange-red). To identify glycogen, periodic acid-Schiff stain is used (which stains glycogen red-violet). If vacuoles do not stain for either fat or glycogen, they are presumed to be composed mostly of water.

Cholesterol and Cholesteryl Esters:

Phagocytic cells (macrophages) may become overloaded with lipid (triglycerides, cholesterol, and cholesteryl esters) when it come in contact with the lipid debris of necrotic cells. These macrophages may be filled with minute vacuoles of lipid, giving a foamy appearance to their cytoplasm called **foam cells.**

Proteins:

In kidney disease like nephrotic syndrome, there is heavy protein leakage across the glomerular filter so there is a much larger reabsorption of the protein resulting in the histologic appearance of pink, hyaline droplets in the cytoplasm.

Glycogen:

Excessive intracellular deposits of glycogen are associated with abnormalities in the metabolism of either glucose or glycogen. In poorly controlled diabetes mellitus, glycogen accumulates in renal tubular epithelium, cardiac myocytes, and β cells of the islets of Langerhans.

Pigments:

Pigments are colored substances that are either:

1- Exogenous, coming from outside the body, like **carbon** (an example is coal dust). When inhaled, it is phagocytosed by alveolar macrophages giving black pigmentation of the lung. This condition is called **anthracosis.**

2- Endogenous, synthesized within the body itself, include lipofuscin, melanin, and certain derivatives of hemoglobin.

Lipofuscin, or "wear-and-tear pigment," represents complexes of lipid and protein appear as brownish-yellow granular intracellular material that accumulates in heart, liver, and brain as a function of age or atrophy.

Melanin is an endogenous, brown-black pigment produced in melanocytes located in the epidermis and acts as a screen against harmful ultraviolet radiation

Hemosiderin is a hemoglobin-derived granular pigment that is golden yellow to brown and accumulates in tissues when there is a local or systemic excess of iron result from hemorrhage. The condition is called **hemosiderosis.** It is found in the mononuclear phagocytes of the liver, bone marrow, spleen, and lymph nodes.

Pathologic calcification:

1- Dystrophic calcification:
It is abnormal deposition of calcium salts, together with smaller amounts of iron, magnesium, and other minerals occurs in dead or dying tissues.

2- Metastatic calcification The deposition of calcium salts in normal tissues due to derangement in calcium metabolism (hypercalcemia).

Cellular aging:

Cellular aging is the result of a decrease in the proliferative capacity and life span of cells and the effects of continuous exposure to exogenous factors that cause accumulation of cellular and molecular damage.

Several mechanisms are responsible for cellular aging:

1- DNA damage which may happen during normal DNA replication and can be enhanced by free radicals.

2- Decreased cellular replication. All normal cells have a limited capacity for replication, and after a fixed number of divisions cells become arrested in a terminally nondividing state, known as **replicative senescence**. Aging is associated with progressive replicative senescence of cells. Cells from children have the capacity to undergo more rounds of replication than do cells from older people.

3- Reduced regenerative capacity of tissue stem cells. Occur due to accumulation of p 16 protein which is inhibitor of cell proliferation.

4- Accumulation of metabolic damage. One group of potentially toxic products of normal metabolism is reactive oxygen species, which cause covalent modifications of proteins, lipids, and nucleic acids. Increased oxidative damage could result from repeated environmental exposure to such influences as ionizing radiation along with progressive reduction of antioxidant defense mechanisms.