Crown & Bridge Prosthodontics
Introduction

Lecture I

Prepared By :

Dr. Maitham Yahya Altufaili

Board Speciality (MSc) In Restorative Dentistry

Dr.maitham_altufaili

@DR.MAITHAM_ALTUFAILI

University of Hilla
Dentistry college

Crown and bridge department

20-10-2025

Third stage

Prosthodontics (Prosthetic Dentistry Or Prosthodontia)

- The dental specialty that concerned with restoring & maintaining oral functions, comfort, appearance & health of the patients by making artificial replacements for missing parts of the mouth and jaw.

Branches OF Prosthodontics

- 1. Maxillofacial Prosthodontics
- 2. Removable Prosthodontics
  A. Complete Denture
  B. Partial Denture RPDs
- 3. Implant Prosthodontics
- 4. Fixed Prosthodontics FPDs
  A. Crown
  B. Bridge

- **Fixed prosthodontics (Crown & Bridge Prosthodontics):**
- It’s a branch of dental science that deals with restoring damaged teeth with artificial crowns & replacing the missing natural teeth with a dental prosthesis (bridge) permanently cemented in place.

- **Types of Fixed Prostheses**
- **1) Extracoronal:** It involves all restorations that seat **over** the tooth such as all types of crown restorations (Full metal crown, partial crown, PFM, all ceramic crown) & direct or indirect veneer restoration.





- **2) Intracoronal:** It involves all restorations that seat **inside** the tooth such as inlay, onlay and endocrown.





- **The Crown:** is a fixed extra-coronal artificial restoration for the coronal portion of a natural tooth. It must restore morphology, function and the contour of the damaged portion of a tooth and must protect the remaining tooth structure from further damage.



TYPES OF CROWNS: (CLASSIFICATIONS)

- **A) According to the coverage area**
- **1. Complete crown:** It covers the coronal portion of the tooth, such as full metal crown, All- ceramic crown (made of ceramic material).
- **2. Partial Crown:** It is covers part of the coronal portion of the tooth such as 3/4 Crown, 7/8 Crown.
- **3. Complete replacement:** it involves those which replace the natural crown entirely while retains itself by means of a metal extended inside the root canal space of the tooth such as a post crown.





- **According to materials used in the construction of C&B restorations**
- **1. Metal Crowns:** Gold alloy and its alternatives
- **2. Non-Metal crowns:** Acrylic resin, Zirconium or Porcelain as in jacket crown.
- **3. A combination:** of metal and plastic materials as in PFM crown restorations





- **Fixed Partial Denture (Bridge)**
- It is a fixed dental prosthesis which replaces and restores the function and aesthetic of one or more missing natural teeth.
- It cannot be removed from the mouth by the patient and is primarily supported by natural teeth or roots.

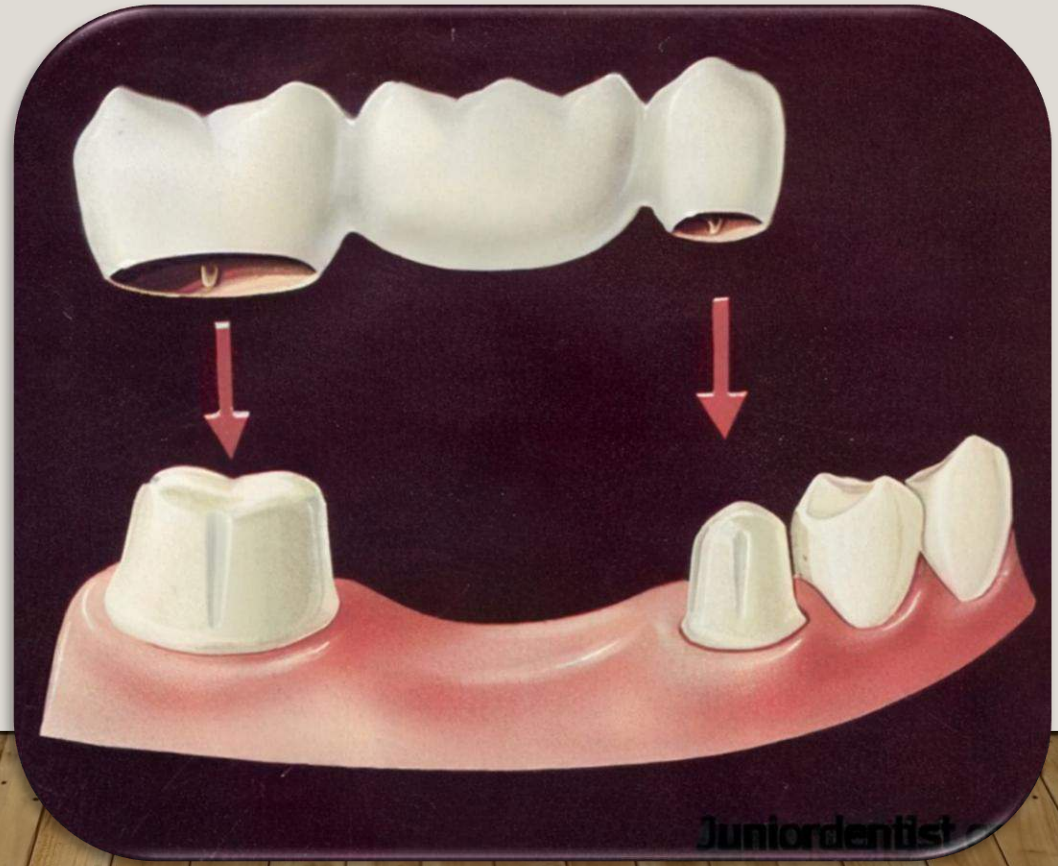

Components of the bridge:

- **1. Retainer:** It's the part that seat over the abutment tooth connecting the pontic to the abutment. It is either a major or minor retainer, or it could be a crown, inlay, post & core.
- **2. Pontic:** It is part of a fixed partial denture that replaces the missed tooth or teeth, usually, it occupies the position of the missing natural tooth.
- **3. Connector:** It's the part that joins the individual components of the bridge together (retainer& politics), which could be a fixed (rigid) or movable (flexible) connector. When the retainer is attached to a **fixed connector,** it's called a major retainer, but when it is attached to a **flexible (movable) connector,** it is called a minor retainer.

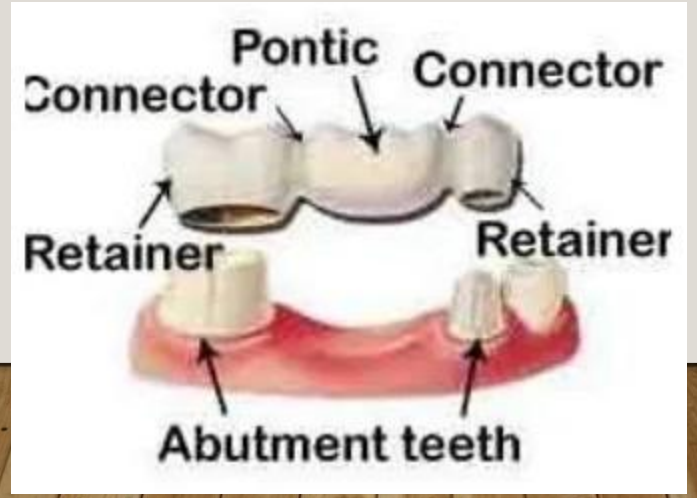

Definitions (terminology)

- **Abutment:** a tooth to which a bridge is attached.
- **Span:** the space between natural teeth that are to be filled by pontics.
- **Saddle:** an area of the edentulous ridge over which the pontic lies.
- **Pier:** an abutment standing between two abutments & supporting two pontics, each pontic being attached to a further abutment.
- **Unit:** when applied to bridgework, means the number of retainers and pontics, thus a bridge that replaces a first premolar using two abutments is referred to as three units bridge.



- **Path of insertion:** An imaginary line along which the restoration can be inserted and removed without any interferences or causing lateral force on the abutment.

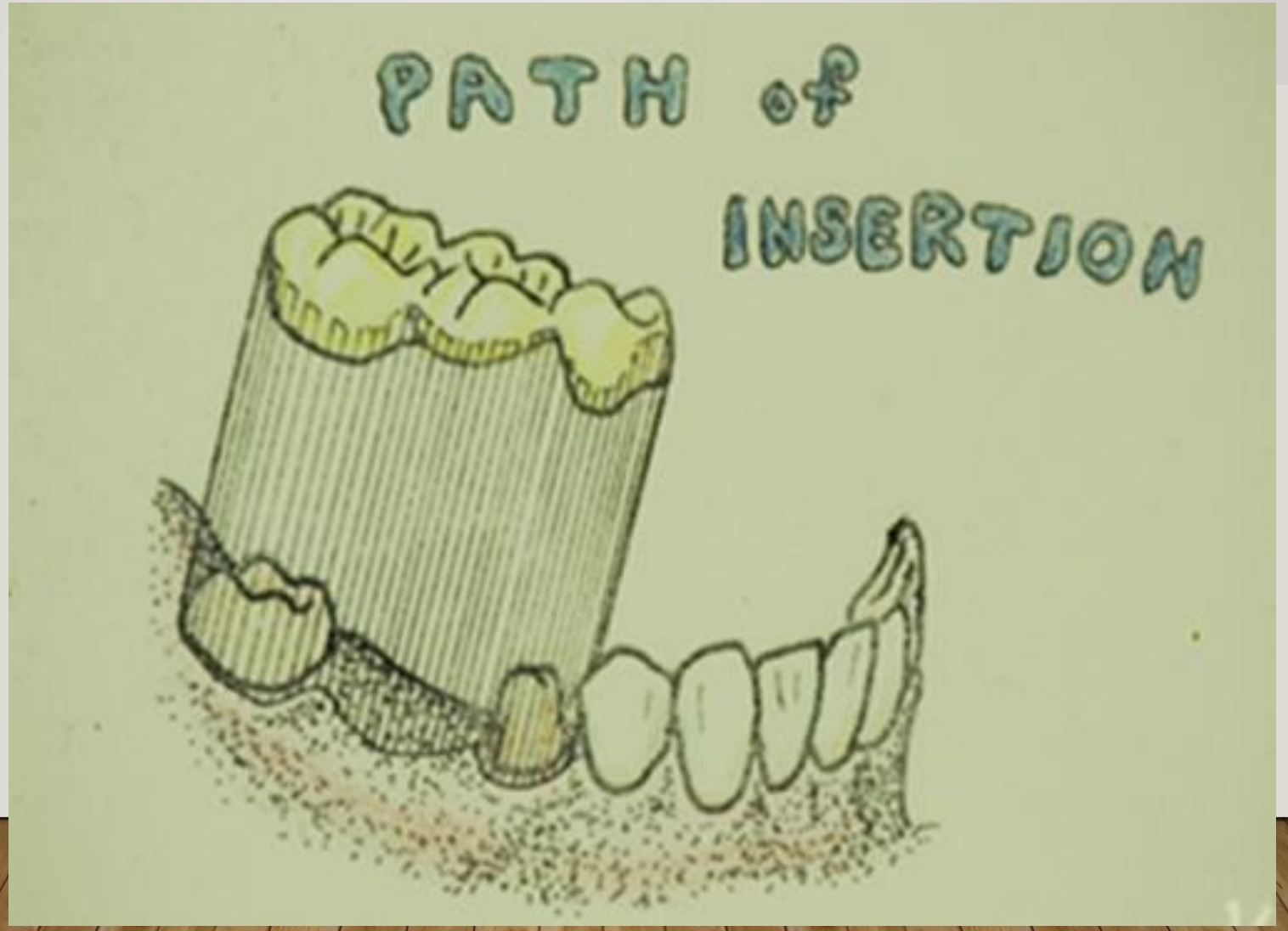

Why do a Fixed Partial Denture?

- The stability of an individual tooth depends on a balance of the forces exerted on that tooth by the adjacent, opposing teeth, supporting tissue & by the soft tissue of the cheek, lips & tongue.

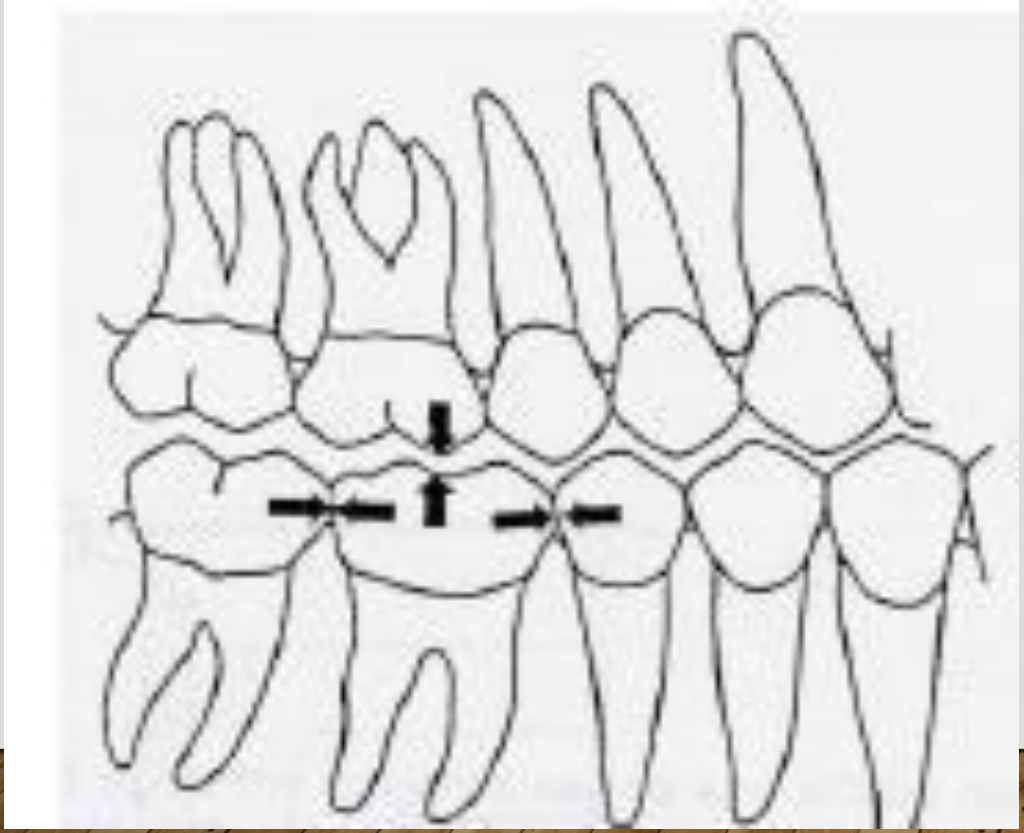



When a single tooth is not replaced (after loss), this balance is upset, & the consequence may by:

1. Super eruption of the opposing tooth or teeth:

a) Gingival recession.

b) Traumatic occlusion or lacking of bite.

c) Loss of bony support for that tooth.

d) Loss of the proximal contact.

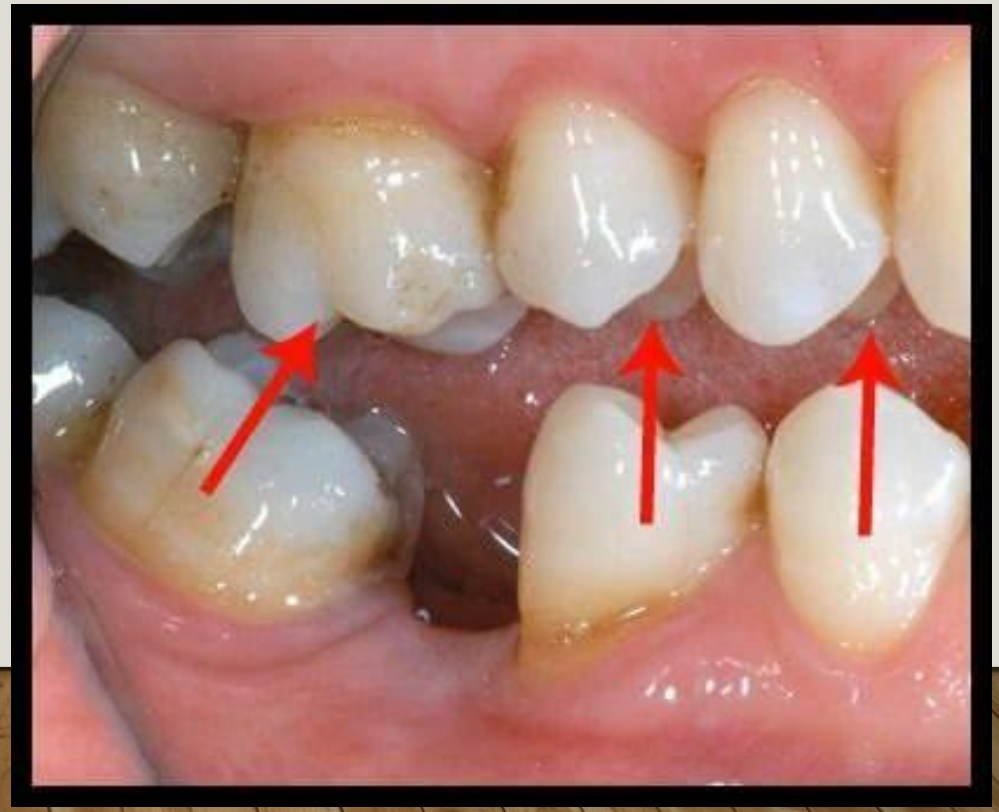

2. Loss of function on the affected side:

a) Diffuse atrophy.

b) Heavy deposition of plaque & which leads to gingivitis & periodontal disease.

c) Trauma to the soft tissue during function.

d) Loss of tissue (contraction of both soft tissue & alveolar bone).

3. Tilting (drifting) of the adjacent teeth.

4. Loss of the proximal contact to:

a) Food stagnation & pocketing

c) Sub-gingival caries

5. Periodontal problem & mobility

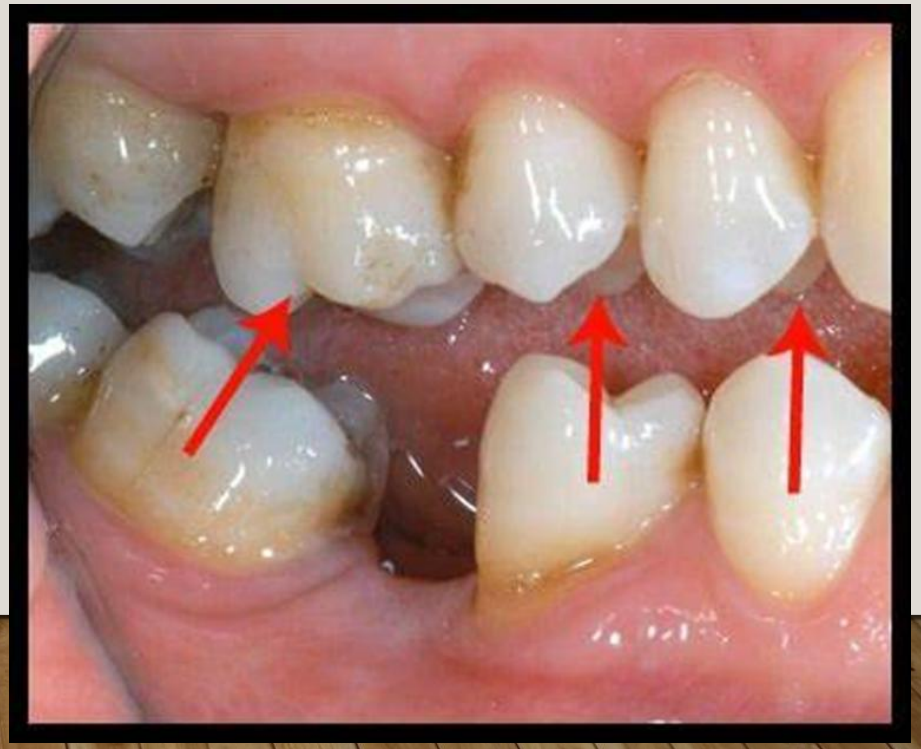

Posterior Bite Collapse:

- The posterior teeth support the vertical height of the face.
- If they are lost, the face tends to lose height and close down; this is called “posterior bite collapse”



- **Figure 1:** The back teeth and front teeth work in harmony. The back teeth support facial height & chew food while the front teeth cut food, protect the back teeth in lateral jaw movements and provide your smile



- **Figure 2:** The loss of the back teeth place excessive pressure on the front teeth causing shifting of teeth and slight loss of facial height.



- **Figure 3:** Without replacement of the back teeth, the teeth start to shift and excessive pressure causes the front teeth to spread forward. Loss of facial height occurs



The general effects of tooth loss:

1) Generalized collapse of lower & upper dental arches.

2) Premature contact causing deviation in the normal movement of the mandible might lead to TMJ dysfunction & muscle spasm that causes pain.

3) Tooth loss may lead to unilateral mastication on the opposite side of the dental arch, resulting in periodontal problems and caries on the affected side due to deficient mechanical cleaning afforded by the act of mastication.

4) Posterior bite collapse: these changes also put pressure on the front teeth tend to move or slope forward.

Reasons for treating tooth loss

1) Aesthetic.

2) Function (ability to eat).

3) Pain due to TMJ dysfunction & muscle spasm.

4) Maintenance of dental arch (occlusal stabilization & prevent tilting)

5) Speech (particularly lower incisors).

Methods of treating tooth loss

- Orthodontic.
- Removable partial denture.
- **Fixed partial denture (tooth supported partial denture).**
- Implant (Osseo-integrated implant).
- Combination.

In some cases, the decision might be no fixed prosthetic

1) Long-standing edentulous space (long span) into which there has been little or no drifting or elongation of the adjacent teeth.

2) Lack of distal abutment.

3) If the patient notices there is no functional, occlusal or aesthetic impairment.





Purposes of crown construction:

1.To restore the grossly damaged tooth, fractured tooth or a tooth with a heavy
filling (amalgam or composite).

2.To restore the masticatory function and speech.

3.To restore the esthetic (hypoplastic condition whether heredity defect or acquired
defect).

4.To maintain the periodontal health by recontouring the occlusion and prevents
food impaction.

5. To alter the occlusion (occlusal relationship) as a part of occlusal reconstruction
to solve occlusal problems or to improve function.

6. As a retainer for the bridge.

Steps in the construction of cast restorations

1. Diagnosis.
2. Tooth preparation.
3. Final impression.
4. Temporary restoration (Provisional restoration).
5. Construction of working model.
6. Waxing.
7. Investing.
8. Burn-out (Wax elimination).
9. Casting.
10. Cleaning and finishing.
11. Try-in and cementation.

Note: Steps (1-4, and 11) are clinical steps, while steps (5-10) are laboratory steps
carried out in the lab by the laboratory technician.

Diagnosis

The first step should be the diagnosis of the case whether it is indicated for crown and bridge work or not. This is decided after a thorough examination of the tooth and surrounding structures, which includes:

(a) Periodontal Examination: The patient should have proper oral hygiene to ensure that no plaque accumulation would occur on the crown margins which might lead, if left, to caries.

(b) Dental examination: which includes:

-Visual examination: we should examine the occlusion of the patient, the presence of crowding, spacing, rotation of teeth, tilting (drifting) and supra-eruption of the abutment tooth (or teeth). Meanwhile, the condition of the remaining tooth structure, the presence of caries and the quality of existing old fillings in the abutment tooth (or teeth) all should be checked.

-Radiographic examination: The radiograph reveals the shape and number of the roots, the condition of the surrounding structures, and the bone support of the tooth (crown/root ratio).

Objectives of tooth preparation

The main objectives of tooth preparation in fixed prosthodontics includes:

1-To eliminate undercuts from the axial surfaces of the tooth.

Note: The axial surfaces are the facial (labial or buccal), proximal (mesial and distal), and palatal (lingual).

2-To provide enough space for the crown restoration to withstand the force of mastication. This space depends on the material used; metal needs little space while plastic materials need more space.

3-Not to enlarge the size of the tooth.

4-To provide good esthetic.

Disadvantages of crowns

1. Heat generation during the cutting procedure of the teeth might affect the health of the pulp; therefore, water coolant must be used during the preparation procedure.
2. Over preparation can cause pulp irritation or even pulp exposure which might lead to death of the pulp. Excessive tooth preparation can also weaken the tooth structure.
3. Periodontal problems: food impaction with subsequent gingivitis and periodontal pocket formation and secondary caries might develop.


THANK
YOU