Dr. Mustafa Fadhil
PhD. Anatomy & Histology

Human Anatomy

Lec.1

The Scalp

The scalp consists of five layers, the first three of which are bound together and move as a whole on the skull. The first letter of each layer combines to spell the acronym **SCALP.** These layers are:

- **S**kin, which is thick and hair bearing and contains numerous sebaceous glands.

- **C**onnective tissue of the superficial fascia beneath the skin, which is fibrofatty. The fibrous septa uniting the skin to the underlying aponeurosis of the occipitofrontalis muscle (**Fig. 1**). Numerous **arteries** and **veins** are found in this layer. The arteries are branches of the external and internal carotid arteries, and a free anastomosis takes place between them.

- **A**poneurosis (epicranial), which is a thin, tendinous sheet that unites the occipital and frontal bellies of the occipitofrontalis muscle (**Figs. 1 & 2**). The lateral margins of the aponeurosis are attached to the temporal fascia.

- **L**oose areolar tissue, which occupies the subaponeurotic space (**Fig. 1**) and loosely connects the epicranial aponeurosis to the periosteum of the skull (the pericranium). The areolar tissue contains a few small arteries, but it also contains some important **emissary veins** which are valveless and connect the superficial veins of the scalp with the diploic veins of the skull bones and with the intracranial venous sinuses (**Fig. 1**).

- **P**ericranium, which is the periosteum covering the outer surface of the skull bones. It is important to remember that at the sutures between individual skull bones, the periosteum on the outer surface of the bones becomes continuous with the periosteum on the inner surface of the skull bones (**Fig. 1**).

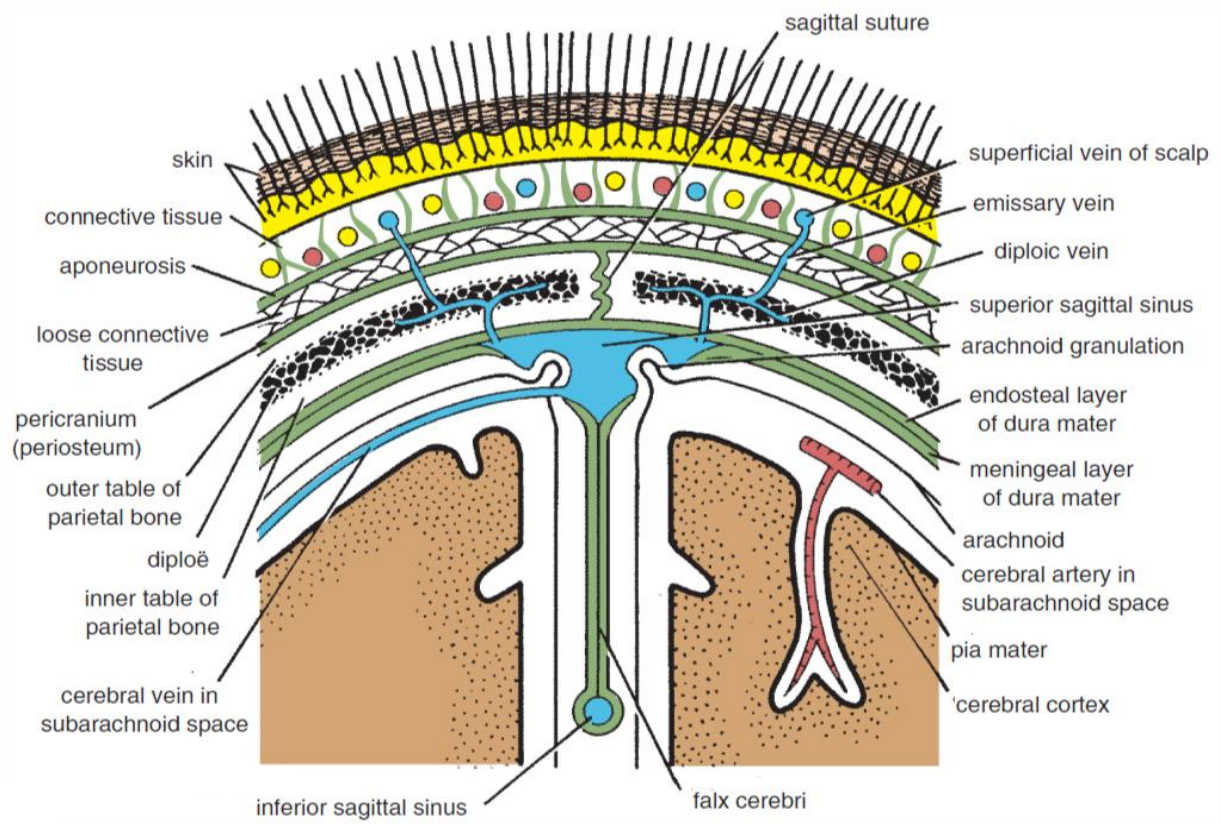

FIGURE 1: Coronal section of the upper part of the head showing the layers of the scalp.

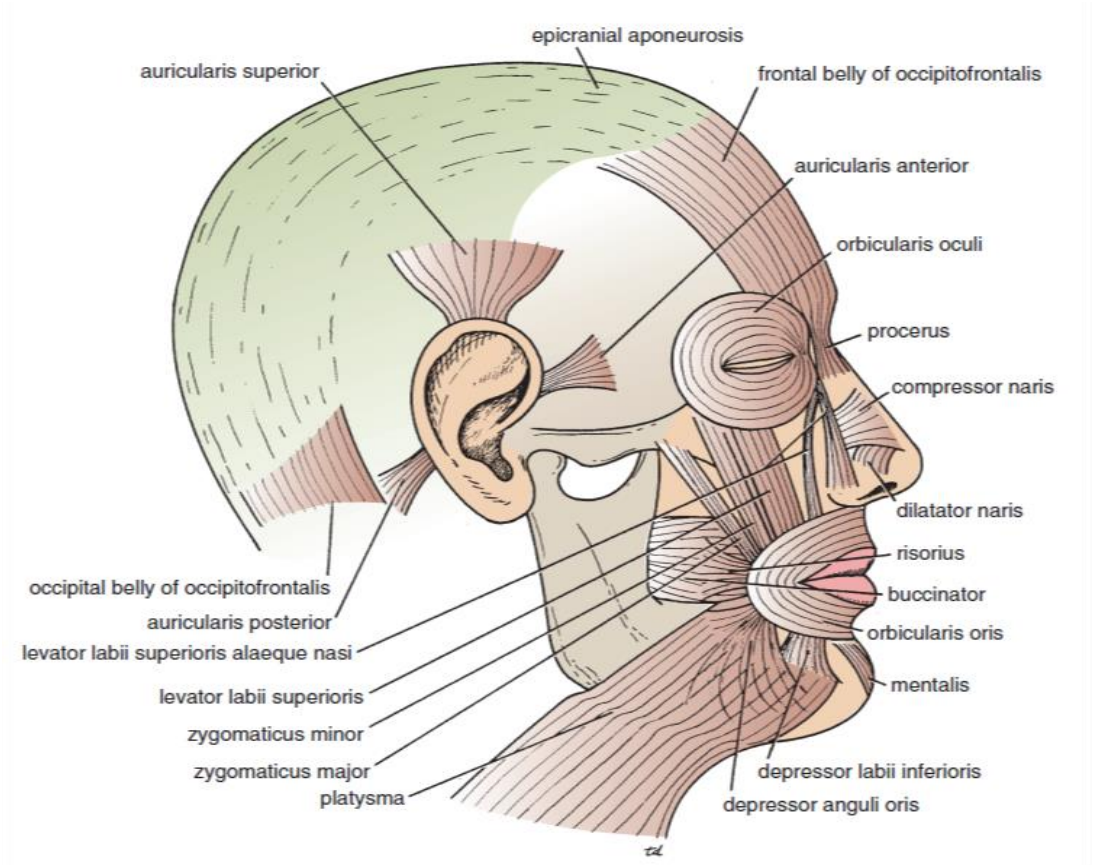

FIGURE 2: Muscles of facial expression.

Muscles of the Scalp

Occipitofrontalis: The origin, insertion, nerve supply, and action of this muscle are described in the following **Table**.

Muscle	Origin	Insertion	Nerve Supply	Action
Muscle of Scalp				
Occipitofrontalis				
Occipital belly	Highest nuchal line of occipital bone	Epicranial aponeurosis	Facial nerve	Moves scalp on skull and raises eyebrows
Frontal belly	Skin and superficial fascia of eyebrows			

Note that when this muscle contracts, the first three layers of the scalp move forward or backward, the loose areolar tissue of the fourth layer of the scalp allowing the aponeurosis to move on the pericranium. The frontal bellies of the occipitofrontalis can raise the eyebrows in expressions of surprise or horror.

Sensory Nerve Supply of the Scalp

The main trunks of the sensory nerves lie in the superficial fascia. The following nerves are present (**Fig. 3**):

The **supratrochlear nerve,** a branch of the ophthalmic division of the trigeminal nerve, winds around the superior orbital margin and supplies the scalp. It passes backward and reaches the vertex of the skull.

The **supraorbital nerve,** a branch of the ophthalmic division of the trigeminal nerve, winds around the superior orbital margin and ascends over the forehead. It supplies the scalp as far backward as the vertex.

The **zygomaticotemporal nerve,** a branch of the maxillary division of the trigeminal nerve, supplies the scalp over the temple.

The **auriculotemporal nerve,** a branch of the mandibular division of the trigeminal nerve, ascends over the side of the head from in front of the auricle. Its terminal branches supply the skin over the temporal region.

The **lesser occipital nerve,** a branch of the cervical plexus (C2), supplies the scalp over the lateral part of the occipital region and the skin over the medial surface of the auricle.

The **greater occipital nerve,** a branch of the posterior ramus of the 2nd cervical nerve (C2), ascends over the back of the scalp and supplies the skin as far forward as the vertex of the skull.

Arterial Supply of the Scalp

The scalp has a rich supply of blood to nourish the hair follicles, and, for this reason, the smallest cut bleeds profusely. The arteries lie in the superficial fascia. The following arteries are present (**Fig. 3**):

The **supratrochlear** and the **supraorbital** **arteries,** branches of the ophthalmic artery, ascend over the forehead in company with the supratrochlear and supraorbital nerves.

The **superficial temporal** **artery,** a branch of the external carotid artery, ascends in front of the auricle in company with the auriculotemporal nerve. It divides into anterior and posterior branches, which supply the skin over the frontal and temporal regions.

The **posterior auricular** **artery,** a branch of the external carotid artery, ascends behind the auricle to supply the scalp above and behind the auricle.

The **occipital** **artery,** a branch of the external carotid artery, ascends in company with the greater occipital nerve. It supplies the skin over the back of the scalp and reaches as high as the vertex of the skull.

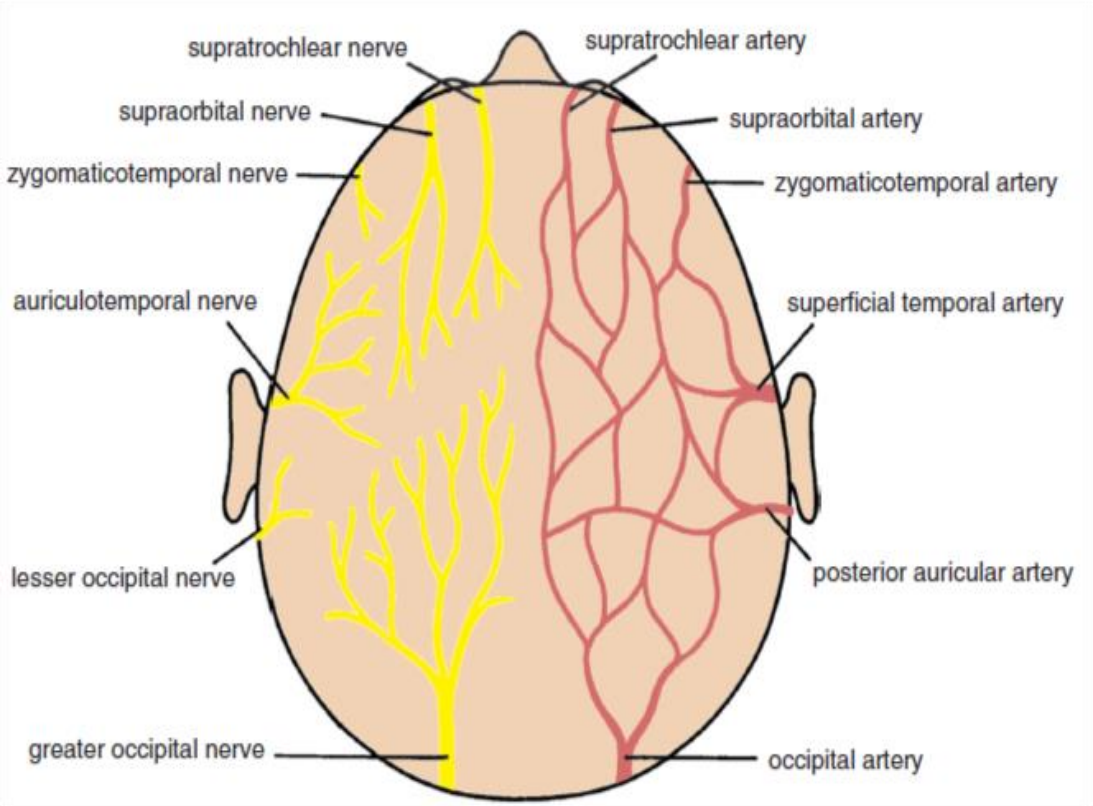

FIGURE 3: Sensory nerve supply and arterial supply to the scalp.

Venous Drainage of the Scalp

The **supratrochlear** and **supraorbital** **veins** unite at the medial margin of the orbit to form the facial vein.

The **superficial temporal** **vein** unites with the maxillary vein in the substance of the parotid gland to form the retromandibular vein (**Fig. 4**).

The **posterior auricular** **vein** unites with the posterior division of the retromandibular vein, just below the parotid gland, to form the external jugular vein (**Fig. 4**).

The **occipital** **vein** drains into the suboccipital venous plexus, which in turn drains into the vertebral veins or the internal jugular vein.

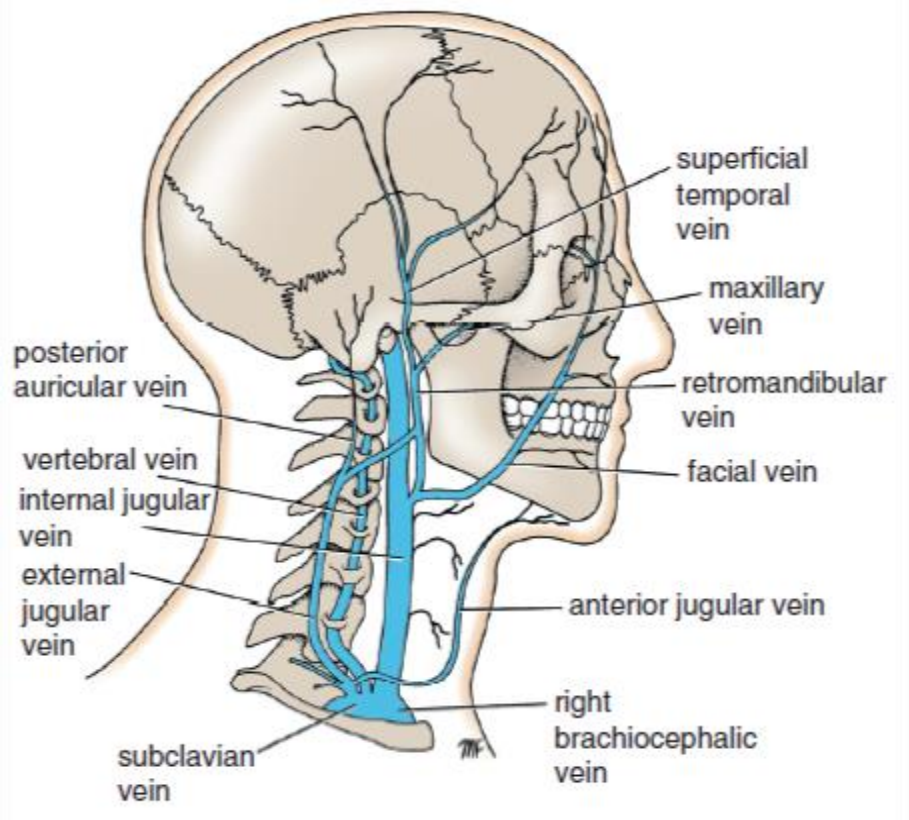

FIGURE 4: Main veins of the head and neck.

Lymph Drainage of the Scalp

Lymph vessels in the anterior part of the scalp and forehead drain into the **submandibular** lymph nodes (**Fig. 5**). Drainage from the lateral part of the scalp above the ear is into the superficial parotid (**preauricular**) nodes; lymph vessels in the part of the scalp above and behind the ear drain into the **mastoid** nodes. Vessels in the back of the scalp drain into the **occipital** nodes.

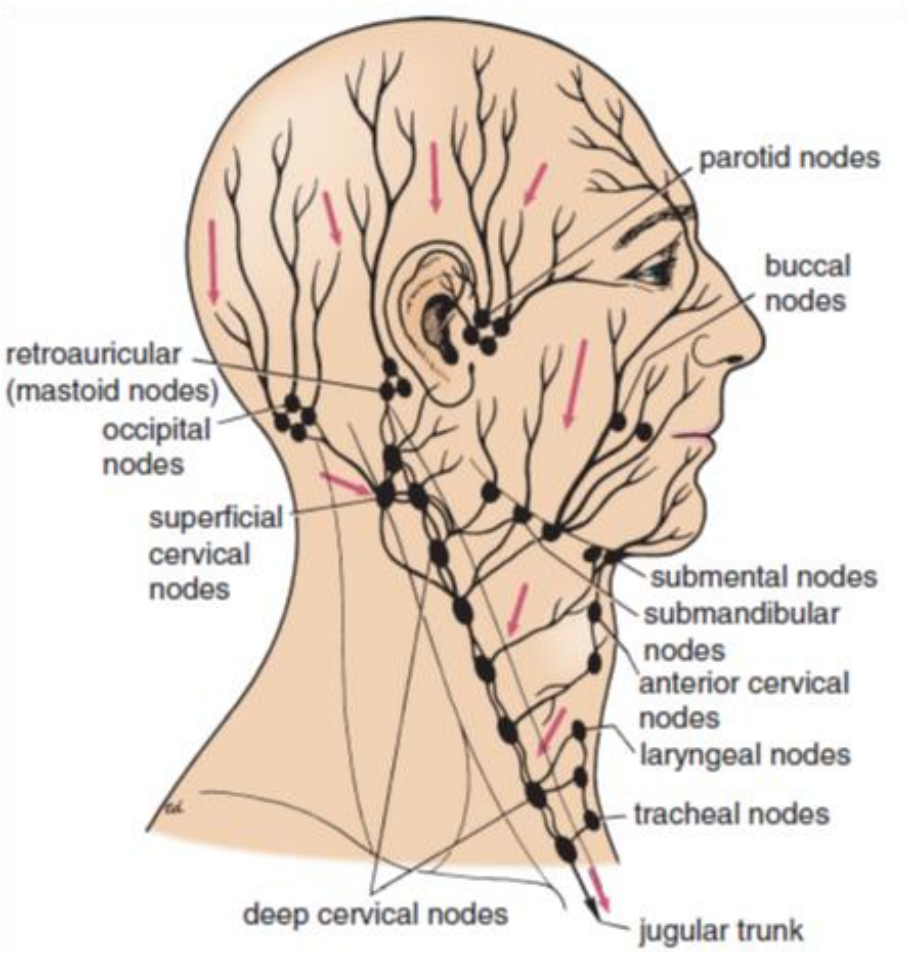

FIGURE 5: Lymph drainage of the head and neck.

Clinical Notes

The skin of the scalp possesses numerous sebaceous glands, the ducts of which are prone to infection and damage by combs. For this reason, sebaceous cysts of the scalp are common.

Even a small laceration of the scalp can cause severe blood loss. It is often difficult to stop the bleeding of a scalp wound because the arterial walls are attached to fibrous septa in the subcutaneous tissue and are unable to contract or retract to allow blood clotting to take place. Local pressure applied to the scalp is the only satisfactory method of stopping the bleeding.

Infections of the scalp tend to remain localized and are usually painful because of the abundant fibrous tissue in the subcutaneous layer. Occasionally, an infection of the scalp spreads by the emissary veins, which are valveless, to the skull bones, causing osteomyelitis. Infected blood in the diploic veins may travel by the emissary veins farther into the venous sinuses and produce venous sinus thrombosis. Furthermore, blood or pus may collect in the potential space beneath the epicranial aponeurosis. It tends to spread over the skull.

Reference

1. Snell RS: Clinical anatomy by regions. Lippincott Williams & Wilkins, 2011.