Lec.12 **Oral Pathology**

Benign tumors of the Bone **د. محمد عبد الحميد**

Benign tumor is a mass of cells (tumor) that lacks the ability to either invade neighboring tissue or metastasize (spread throughout the body). When removed, benign tumors usually do not grow back, whereas malignant tumors sometimes do . The jaw bones may develop the same types of tumors as the other bones of the body.

OSTEOMA

Clinically:

They are benign tumors composed of mature compact or cancellous bone. Found at **any age** .Osteomas are most frequently diagnosed in 2nd to 4th decades of life, being uncommon in the 1st decade. Average patient age is from 25 to 35 years. The majority of cases are seen in young adults. It is generally asymptomatic and may be solitary or multiple. They may be located either superficially **(peripheral or"periosteal osteoma")**, or **intra-osseously** ("**endosteal osteoma**"). on any bone of the cranium or face or within the sinus cavities. When multiple, they are often associated with **Gardners syndrome** (hereditary condition). The syndrome consists of multiple intestinal polyps with malignant potential, multiple osteoma, un erupted normal and supernumerary teeth,

An osteoma involving mandibular condyle may cause a slowly progressing shift in the patient's occlusion, with deviation of the midline of the chin toward the unaffected side. Other signs and symptoms include facial swelling, pain, and limited mouth opening.



Radiographically: osteoma typically appears as a dense, radioopaque, sharply demarcated mass (well defined radio opacity), either centrally or peripherally.

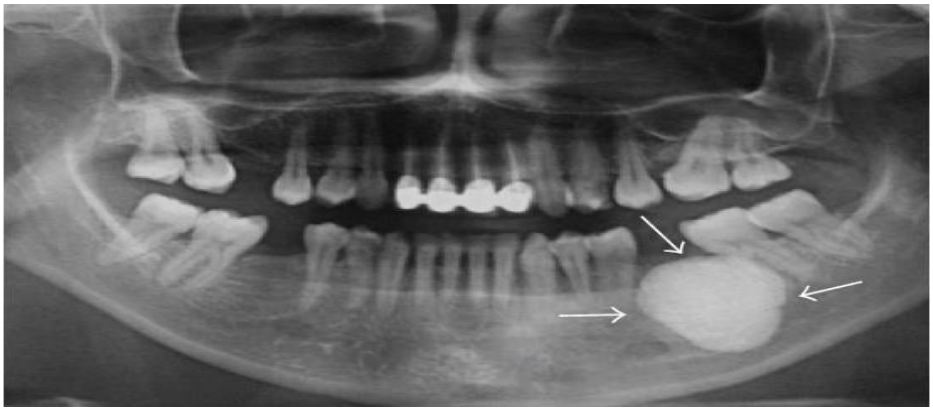

Histopathology

Compact osteomas are composed of normal appearing dense bone showing little marrow tissue. Cancellous osteomas are composed of trabeculae of bone and fibro-fatty marrow.

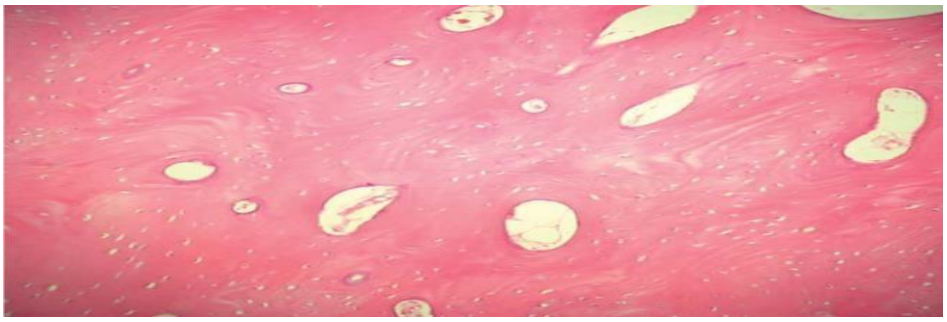

Compact osteoma

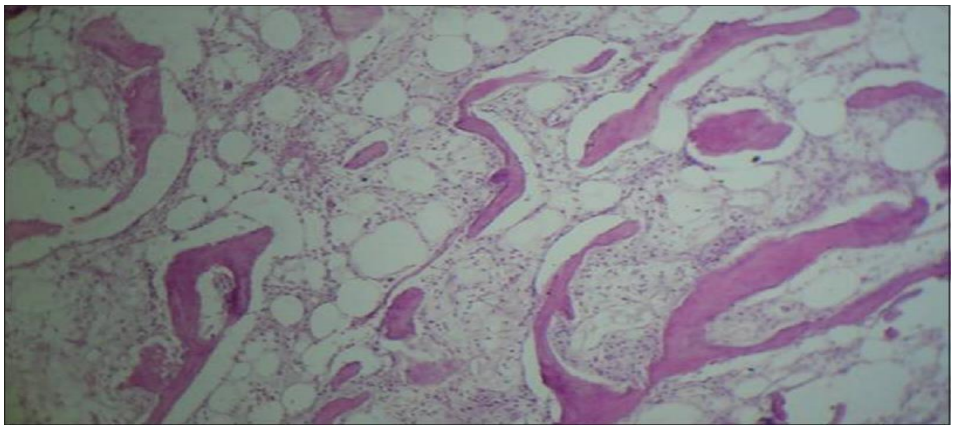

Cancellous osteoma

Treatment and Prognosis

Osteomas found incidentally in asymptomatic patients do not need removal, as follow up studies frequently have shown no increase in size over several years duration. For symptomatic lesions, local excision is curative in almost all cases. Recurrence is quite unusual

Osteoid osteoma

Clinically

Is a benign bone neoplasm that is found more frequently in patients between 10 and 30 years of age, and exhibit 2:1 male female ratio. **Intense pain** is the most prominent symptom, Osteoid osteoma has been reported in every bone but occurs more frequently in femur, tibia, humerus, bones of the hands and feet, vertebrae, and fibula. The tumor is very rare in the jaw bone.

Radiology

A well-defined radioopacity surrounded by a radiolucent rim, the radioopaque mass consisted of a radioopaque nidus measuring usually between 1-1.5 cm in diameter surrounded by the formation of subperiosteal new bone.

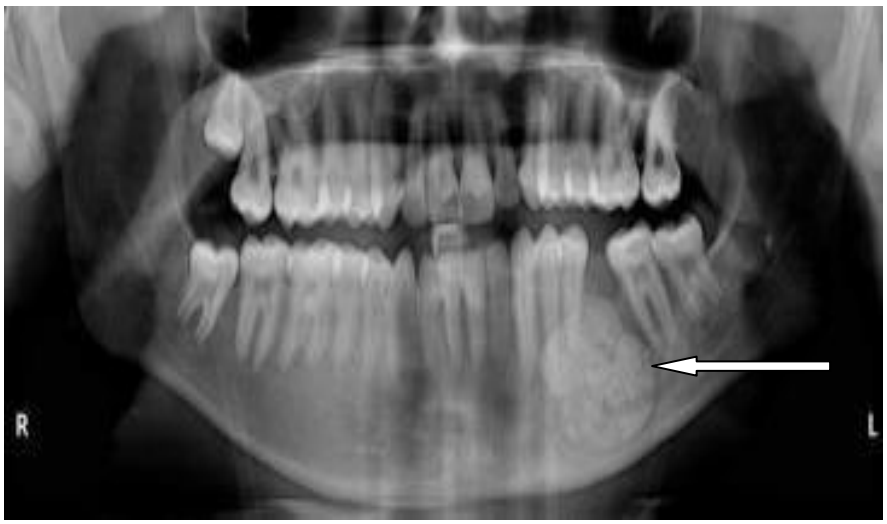

Histopathology

Osteoid osteoma is characterized by varying intermixtures of osteoid, newly formed bone (thin trabeculae show prominent osteoblastic rimming) and central core of highly vascular supporting osseous tissue.

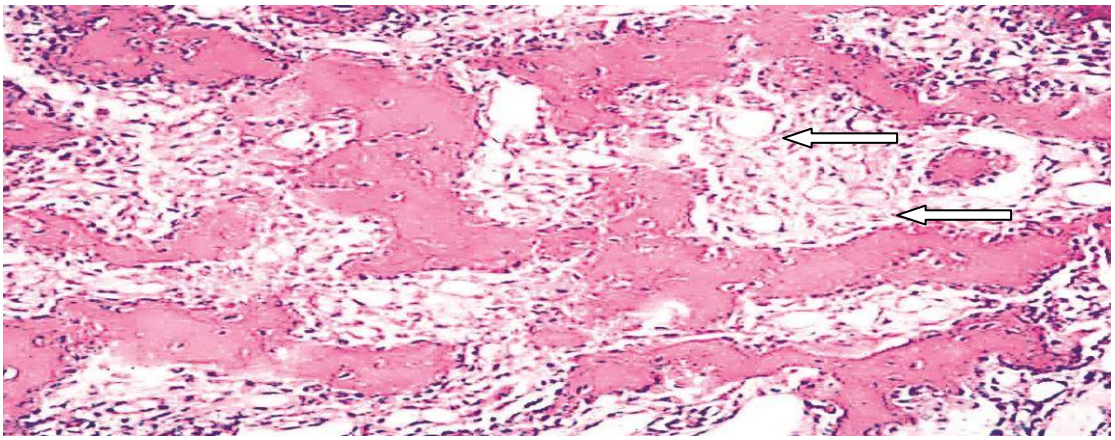

Treatment

Large osteoid osteomas are generally managed by surgical resection. However, for small lesions routine clinical and radigraphic follow up is indicated.

Osteoblastoma "Giant osteoid Osteoma"

Is a tumor closely related to osteoid osteoma both microscopically and ultrastructurally. It is distinguished from the osteoid osteoma by the **larger size of the nidus**, the absence of a surrounding area of reactive bone formation.

Clinically

About 108 well documented examples of osteoblastoma arising both in the maxilla or mandible have been reported in the English literature till date. Rarely affect the jaw bone, with slight mandibular predilection, mostly in the posterior regions. A slight male predominance is noted, and about 85 % occur before age 30. Most of the lesions are between 2 to 4 cm. **Pain** is a common presenting feature. Unlike osteoid osteoma, the pain is not relieved with aspirin.

Radiology

Showing a round to oval radio opaque mass with a radiolucent border at the apex of tooth.

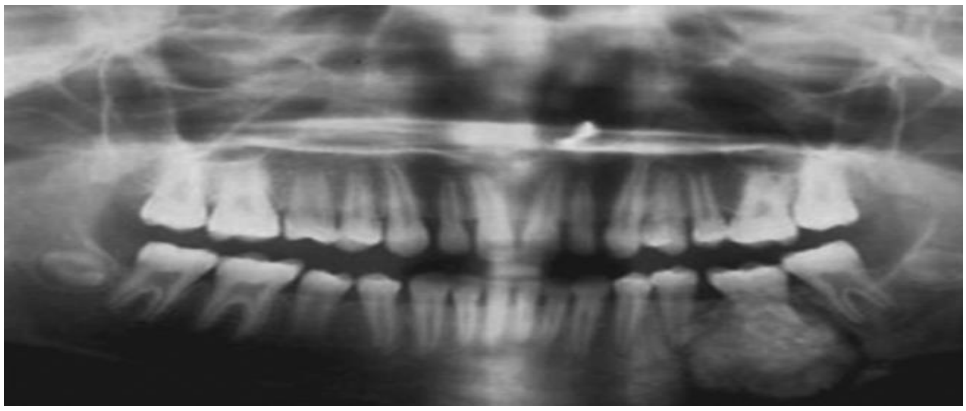

The surgical specimen comprising both tooth and an attached hard tissue mass.



Histopathology

Bone forming tumor comprised of anastomosing trabeculae of osteoid and woven bone rimmed by osteoblasts.

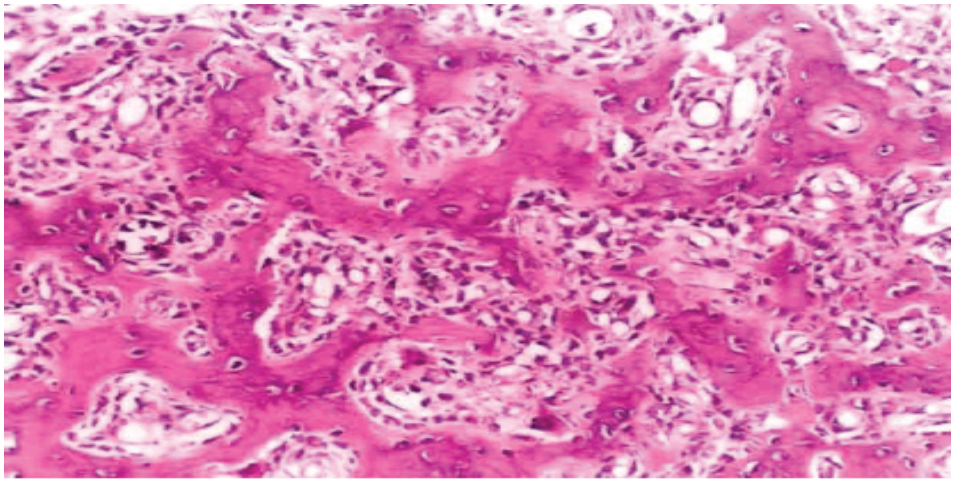

Figure 2 - Classical histologic aspects of osteoblastoma with long inter anastomosing trabeculae of woven bone and osteoid rimmed by a single row of osteoblasts (Case 21, hematoxylin-eosin stain, X 200)

Cementoblastoma

Benign cementoblastoma is a rare odontogenic tumor with only approximately 100 cases reported. **The key to diagnosis** characterized by the formation of a mass of cementum or cementum-like tissue attached to the roots of a tooth. The tumors arise mostly in the permanent dentition with a few incidences being reported in primary teeth. The most common site for occurrence of cementoblastoma is mandibular molar area with 50% of the cases involving the mandibular first molar teeth which have a vital pulp.

Radiology

A cementoblastoma in a radiograph appears as a well-defined, markedly radiopaque mass, with a radiolucent peripheral line, which overlies and obliterates the tooth root. It is described as having a rounded or sunburst appearance. There is usually apparent external resorption of the root where the tumor and the root join. .

Severe hypercementosis and chronic focal sclerosing osteomyelitis are lesions to consider in the differential diagnosis of this lesion.

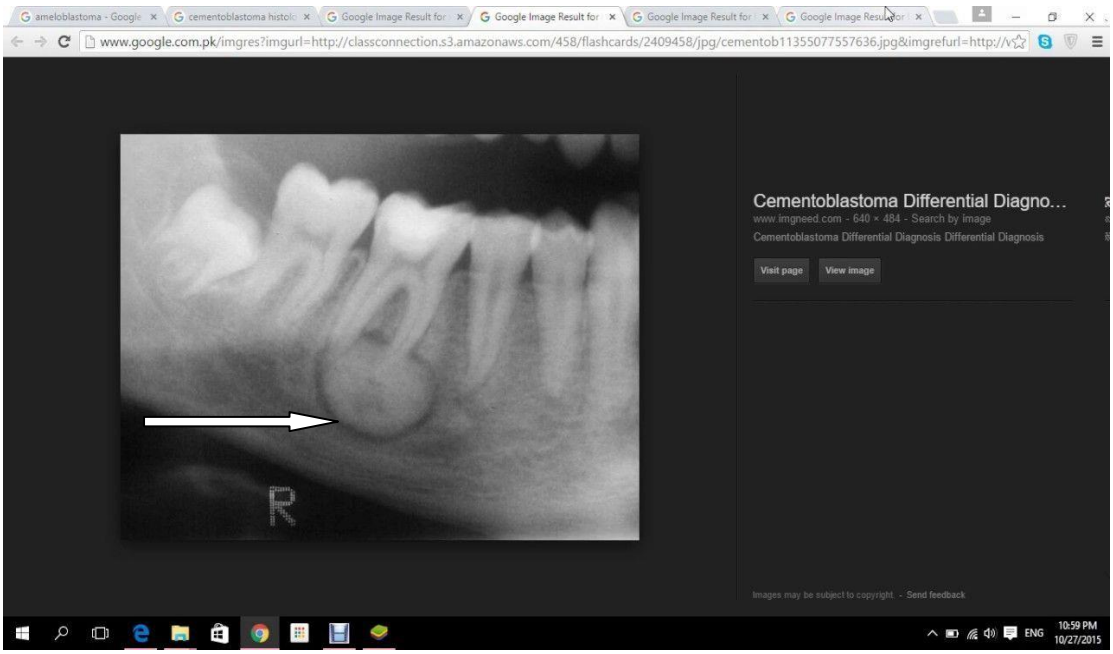

Histopathology

Histologic examination revealed sheets and masses cementum attached to the root of the tooth .The cementum displayed prominent basophilic reversal lines and cementoblastic rimming .

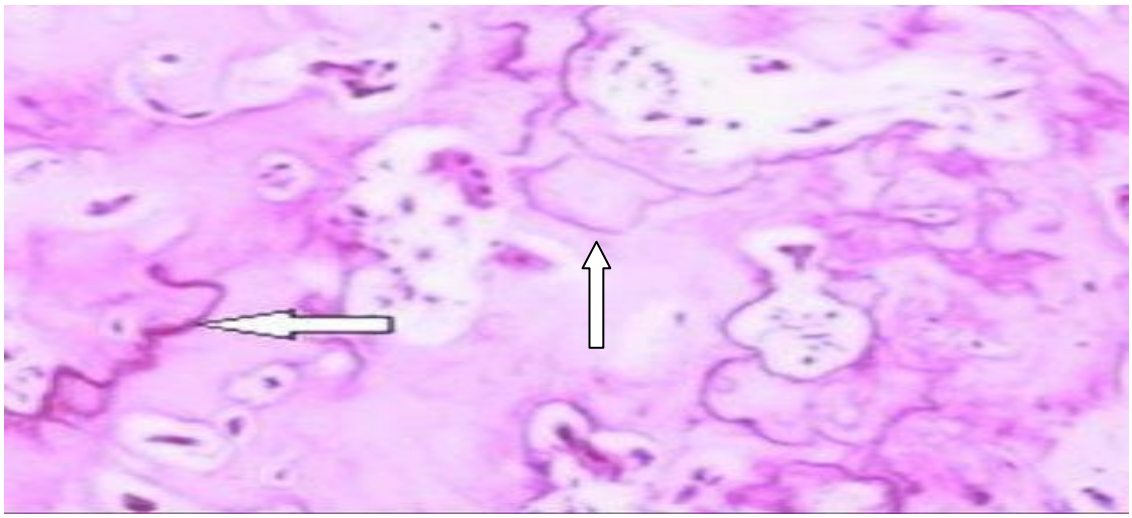

Treatment

Surgical enucleation of the lesion is done, and depending upon the clinical circumstances, this involves removal of the involved tooth. With incomplete removal, recurrence is common; some surgeons advocate curettage after extraction of teeth to decrease the overall rate of recurrence.

Giant Cell Lesions

Peripheral giant cell granuloma(PGCG)

CLINICAL FEATURES

Lesions begin as a reddish to blue- purple swelling of the interdental papillae or alveolar ridge. These lesions produce loosening and movement of the teeth.Most lesions measure less than 2 cm in diameter.



Radiographically

As PGCG is a soft tissue lesion that presents on gingival and alveolar mucosa; X-ray features are thereby nonspecific.



Figure 4: OPG of the patient

Histologically

PGCG is described as a non-encapsulated mass of tissue, containing numerous multinucleated osteoclast-like giant cells lying in a very cellular and vascular stroma.

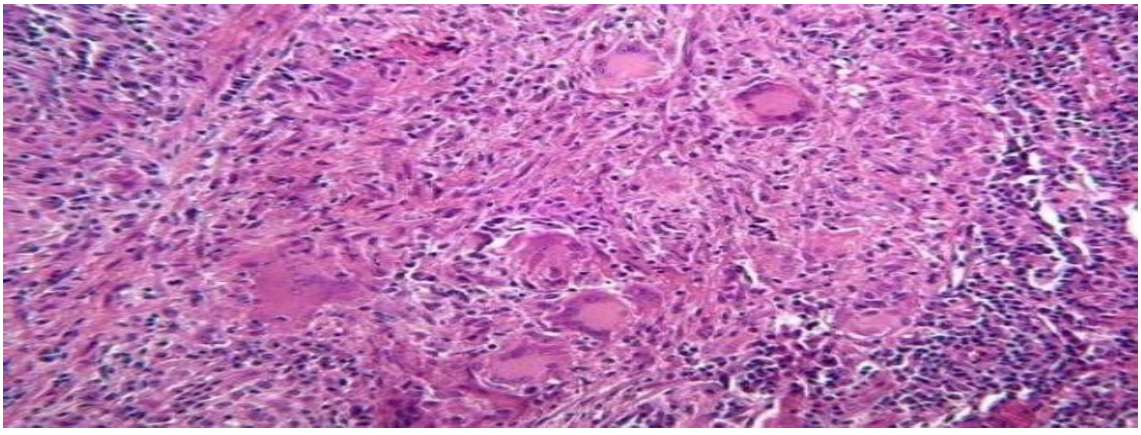

Treatment

Treatment for the peripheral giant cell granuloma consists of complete surgical excision, which should extend down to the underlying bone. The adjacent teeth should be scaled to remove any source of irritation that might contribute to recurrence of the lesion.

Central giant-cell granuloma (CGCG)

It is a localised benign condition of the jaw. It is twice as common in females and is more likely to occur before age 30. Central giant-cell granulomas are more common in the anterior mandible, often crossing the midline and causing painless swellings**.**



Radiographically

Radiographically, CGCGs have a rounded cyst-like radiolucent area with a well-defined margin with 53% showing scalloped margins. They can have a multilocular (honeycomb or soap bubble) appearance**.**



Histology of CGCG

Shows a lobulated mass composed of vascular connective tissue and multinucleated giant cells (osteoclasts). The giant cells may be diffusely located throughout the lesion or focally aggregate in the lesion, often clustered around hemorrhagic areas hemosiderin deposits.

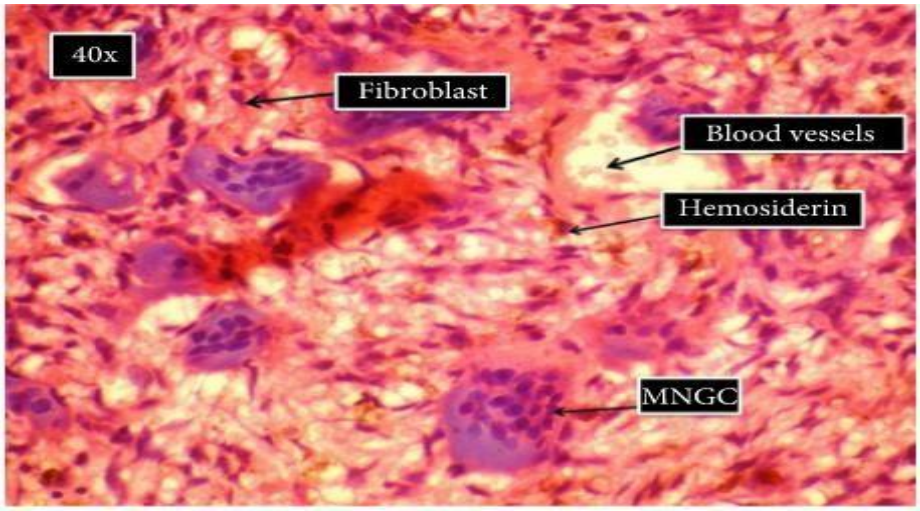

Treatment and prognosis

Primary resected surgically. Recurrence rates of up to 15% have been reported.

Aneurysmal Bone Cyst (ABC)

Uncommon lesion located primarily in the posterior mandible and maxilla with clinical features similar to CGC lesion. ABC Is considered a variant of CGCG but differs by containing many large blood filled spaces.

Clinically

In the jaws, ABC occurs in the 1st three decades of life, with peak incidence in the 10-19 years old age group. Most lesions occur in the posterior mandible and often extend into the ramus, lesion occurs in the maxilla is confined to the molar area. Lesions are **firm, diffuse swellings that produce deformity and malocclusion**. ABC grows **rapidly** and may perforate the cortex.



Radiographically

Lesions are usually well-defined multilocular radiolucency. Teeth roots are often resorbed.

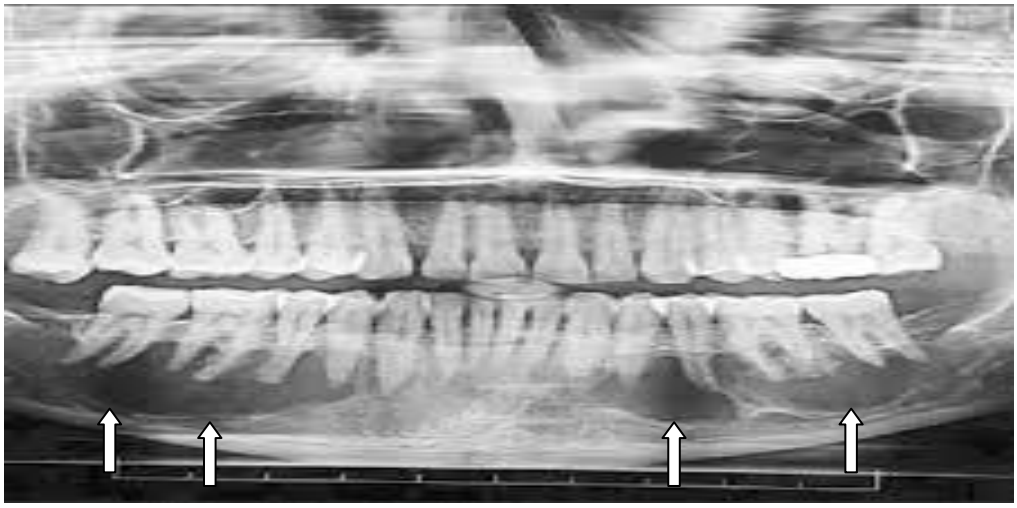

Histopathology

ABC tissue consists of large blood filled spaces separated by fibrous tissue septa, the septa are composed of C.T. containing osteoid deposits, spicules of woven bone, deposits of hemosiderin, and varying numbers of multinucleated giant cells.

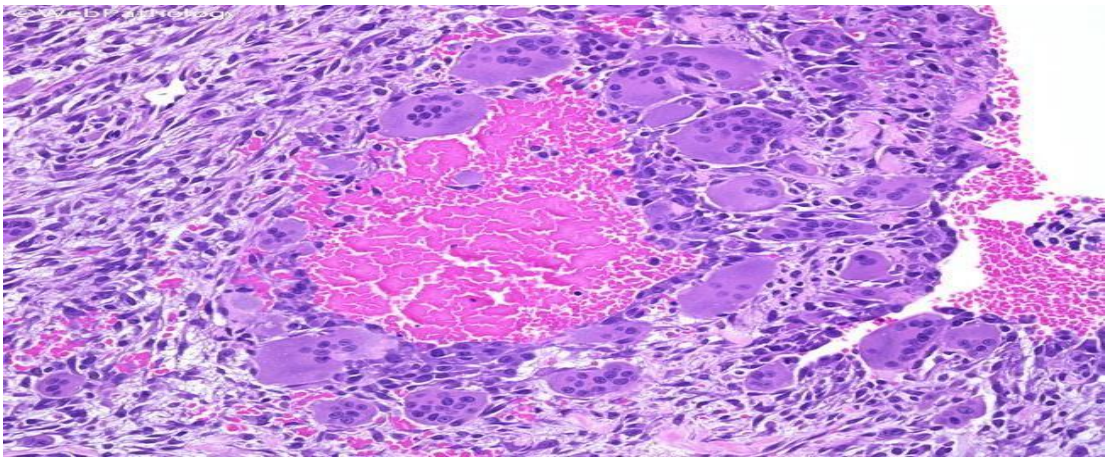

Treatment

Usually treated **by curettage**. Lesions re-occur in **20%** of cases, and re- treated in the same manner.

