DENTAL IMPLANTOLOGY

Advanced Concepts

Dr.Raad Salah Shyaa

IMMEDIATE POSTEXTRACTION PLACEMENT OF IMPLANTS

The implant may be placed :

- Immediately.
- Early
- Late

Advantage:

- Allows the overall shortest healing time.
- Placing a provisional restoration >> maintenance of soft tissue anatomy

Disadvantages:

- Difference in the anatomy of the root compared with the shape and size of the implant.
- The immediate and long-term stability of the implant can be jeopardized.

WHEN ?

- Tooth to be removed is not infected
- Extraction of the tooth with minimal bone removal
- Initial implant stability at the time of placement .
- When the implant is placed, at least 4 mm of the implant apex should be precisely seated in firm bone to provide this initial stability.

NOTES

In the esthetic zone :

- (maxillary anterior), the platform of the implant is ideally placed 3 mm below the free gingival margin.
- In general the implant is also positioned 1 mm palatal to the center of the extracted tooth root.
- The implant should be countersunk slightly below the height of crestal bone to allow for resorption of bone resulting from extraction.

- If the gap is less than 1 mm
- If the gap is greater than 1 mm

BONE GRAFTING AND GRAFT SUBSTITUTES

- Autogenous Grafts
- Allografts
- Xenografts
- Bone Morphogenetic Proteins

belonging to the transforming growth factor-β family, induces new bone formation by inducing differentiation of multi-potent cells.

The BMP is placed on carriers, usually absorbable collagen sponges .

- The BMP is placed on carriers, usually absorbable collagen sponges .

- The primary disadvantages include significant postoperative edema and the cost of the BMP.

- Two problems associated with any type of grafting:

1. Containment and shaping of the graft material
2. Prevention of fibrous tissue ingrowth during the healing phase.
3.

- Guided bone regeneration is a process that allows bone growth while retarding the ingrowth of fibrous connective tissue and epithelium.



MANDIBULAR AUGMENTATION

- Superior border augmentation with a bone graft is often .

- Maxillary Augmentation

Onlay Bone Grafting



SINUS LIFT

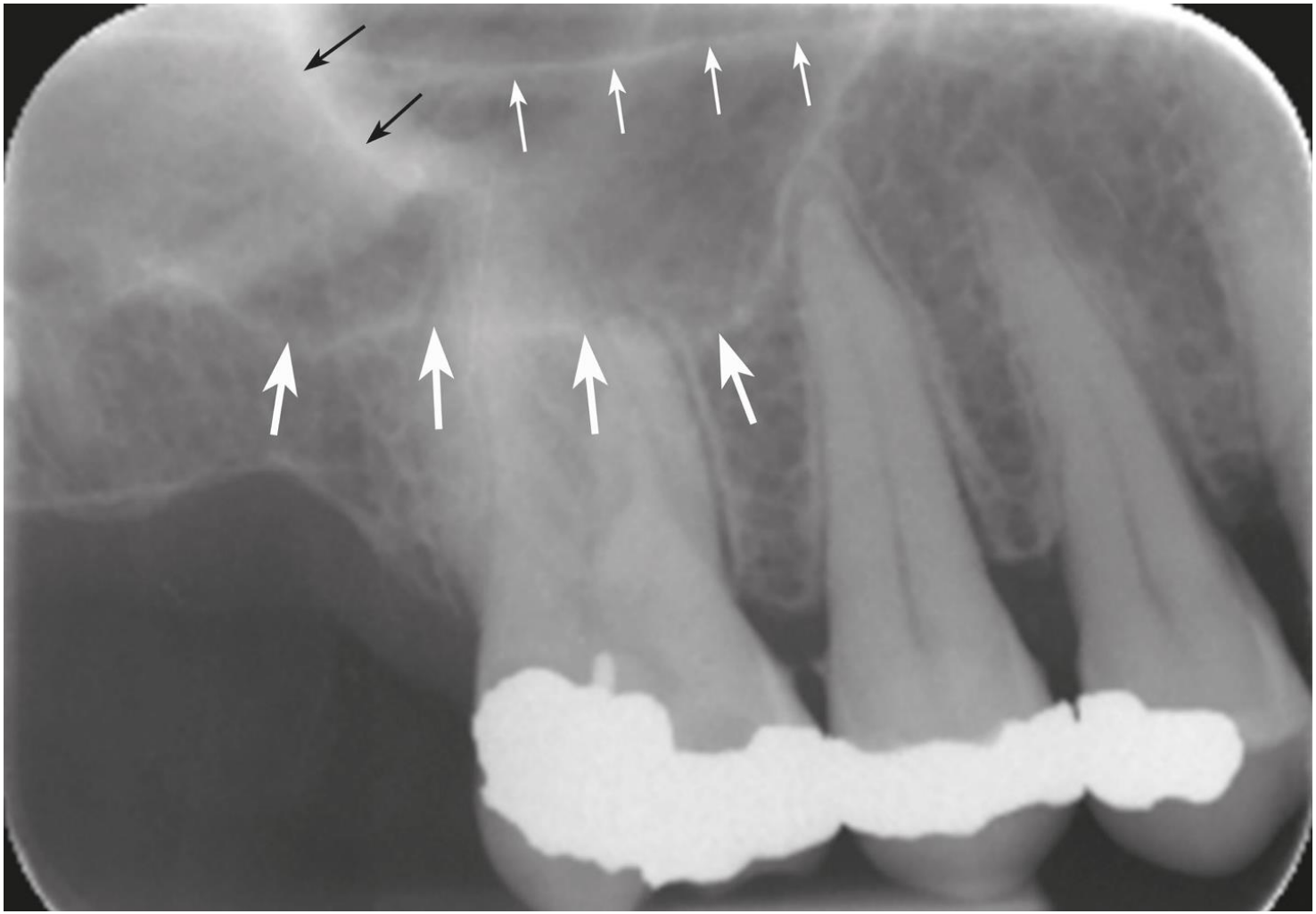

DIRECT

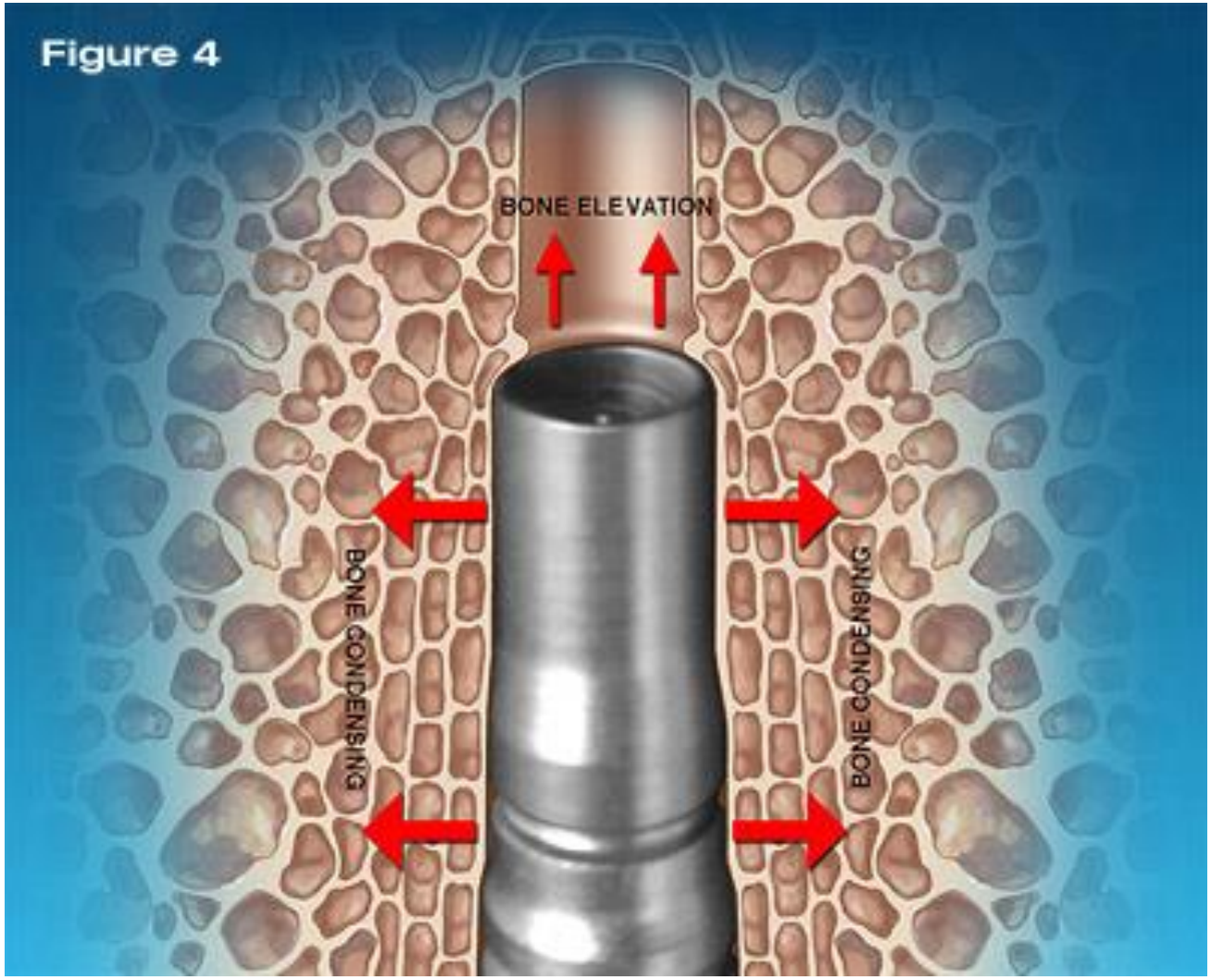



OPEN APPROACH

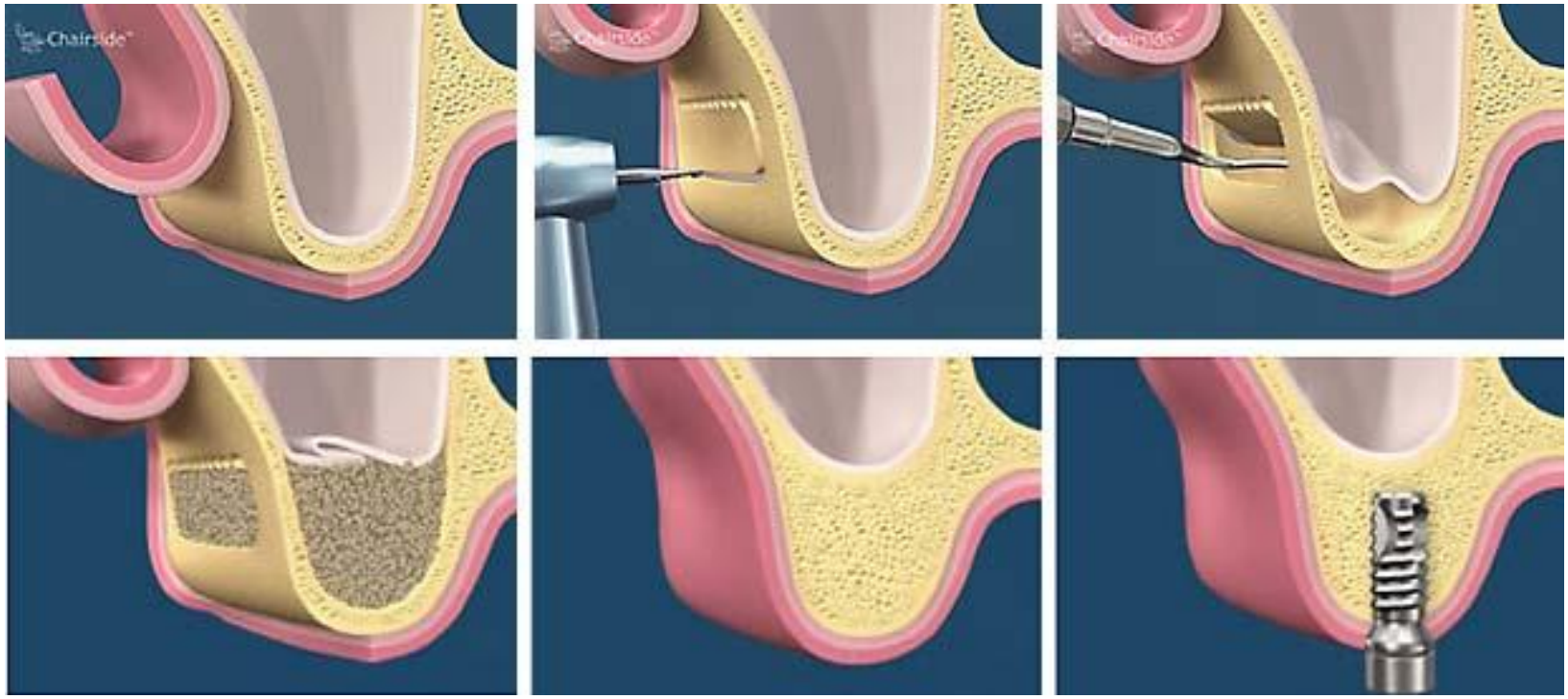

ALVEOLAR RIDGE DISTRACTION

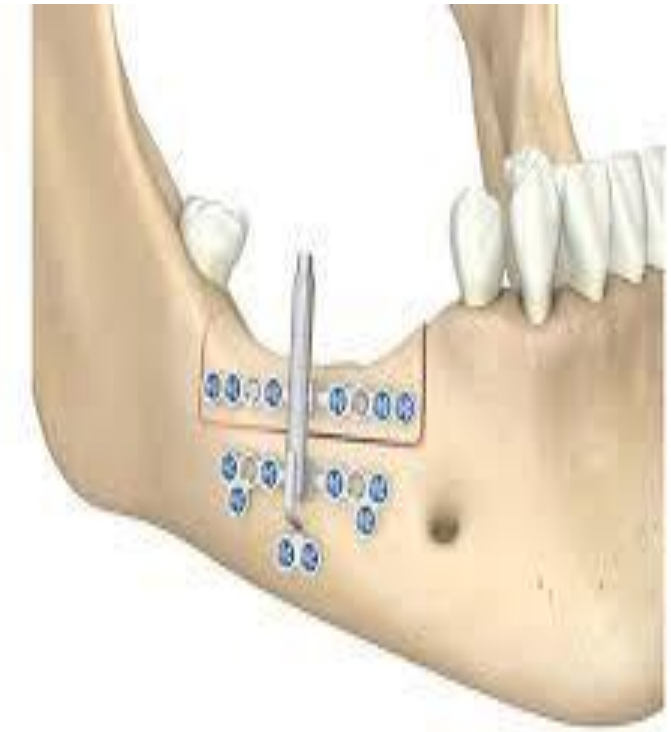

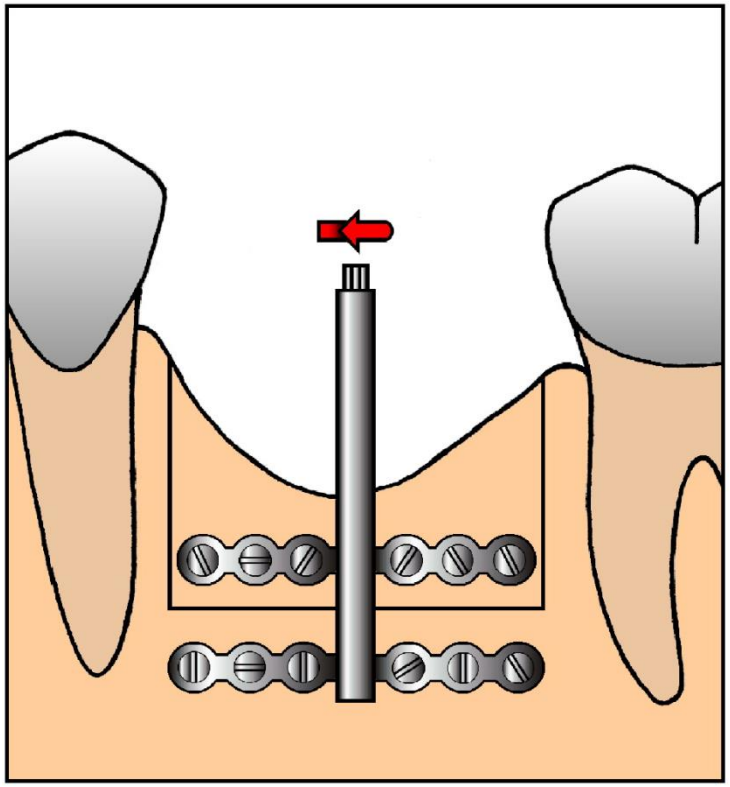

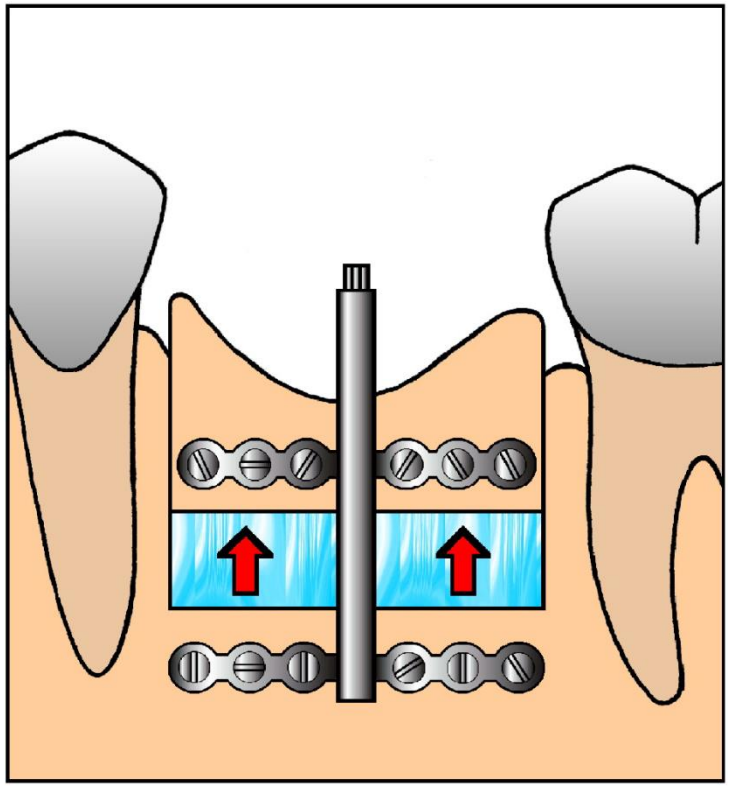

DIAGNOSTIC IMAGING AND VIRTUAL TREATMENT PLANNING

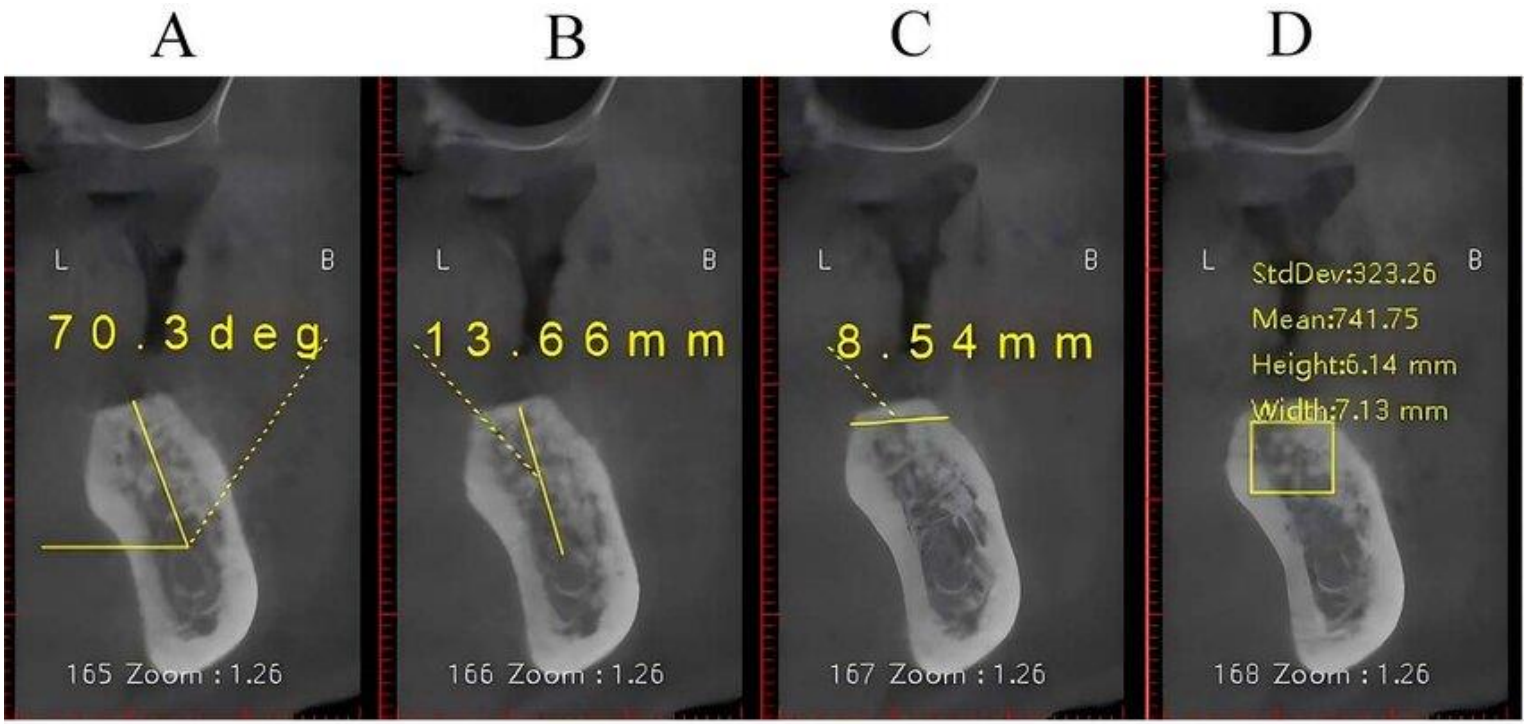

Inclination (°) Canal-crest distance(mm) Ridge width (mm) Bone density (HU)

SURGICAL GUIDE



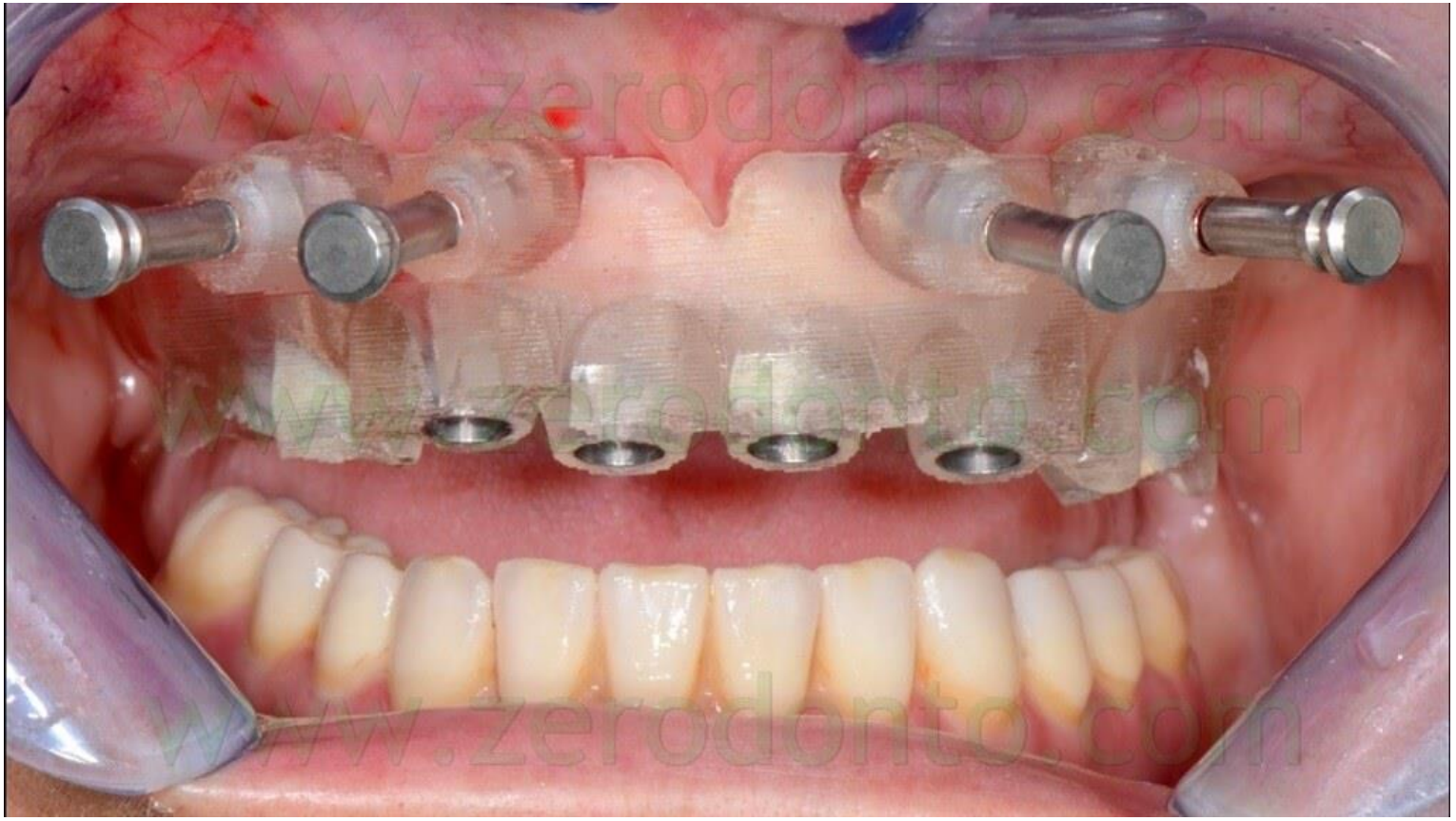
www.zerodonto.com
www.zerodonto.com
www.zerodonto.com

ZYGOMATIC IMPLANTS

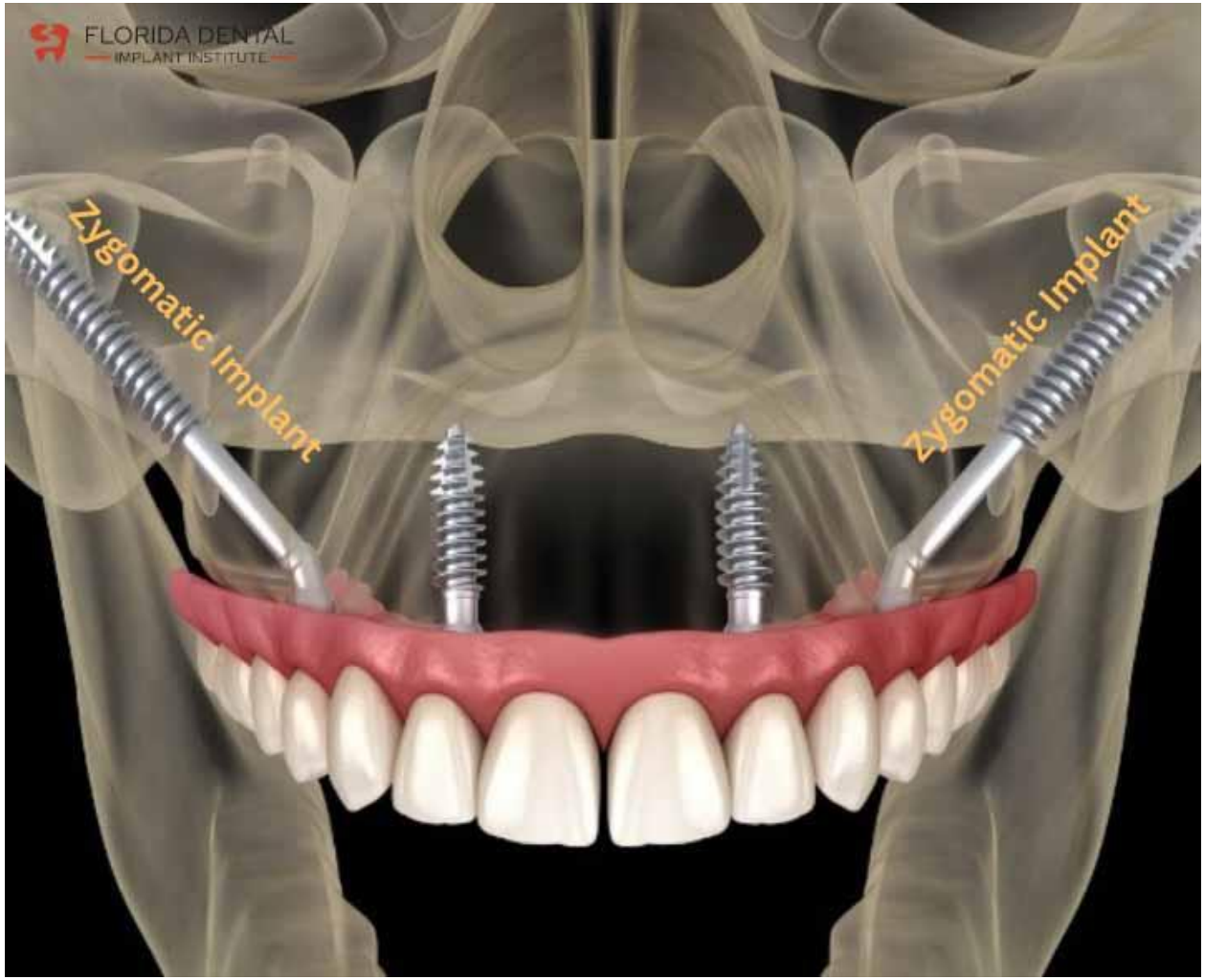

EXTRAORAL IMPLANTS

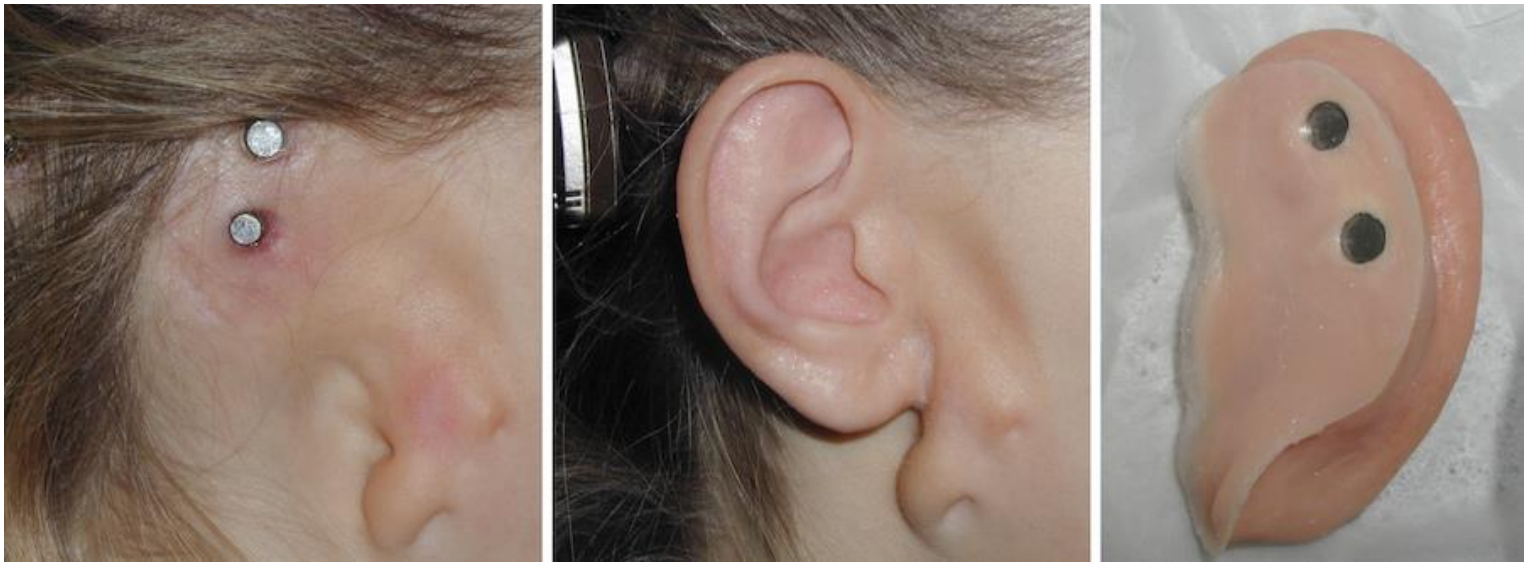

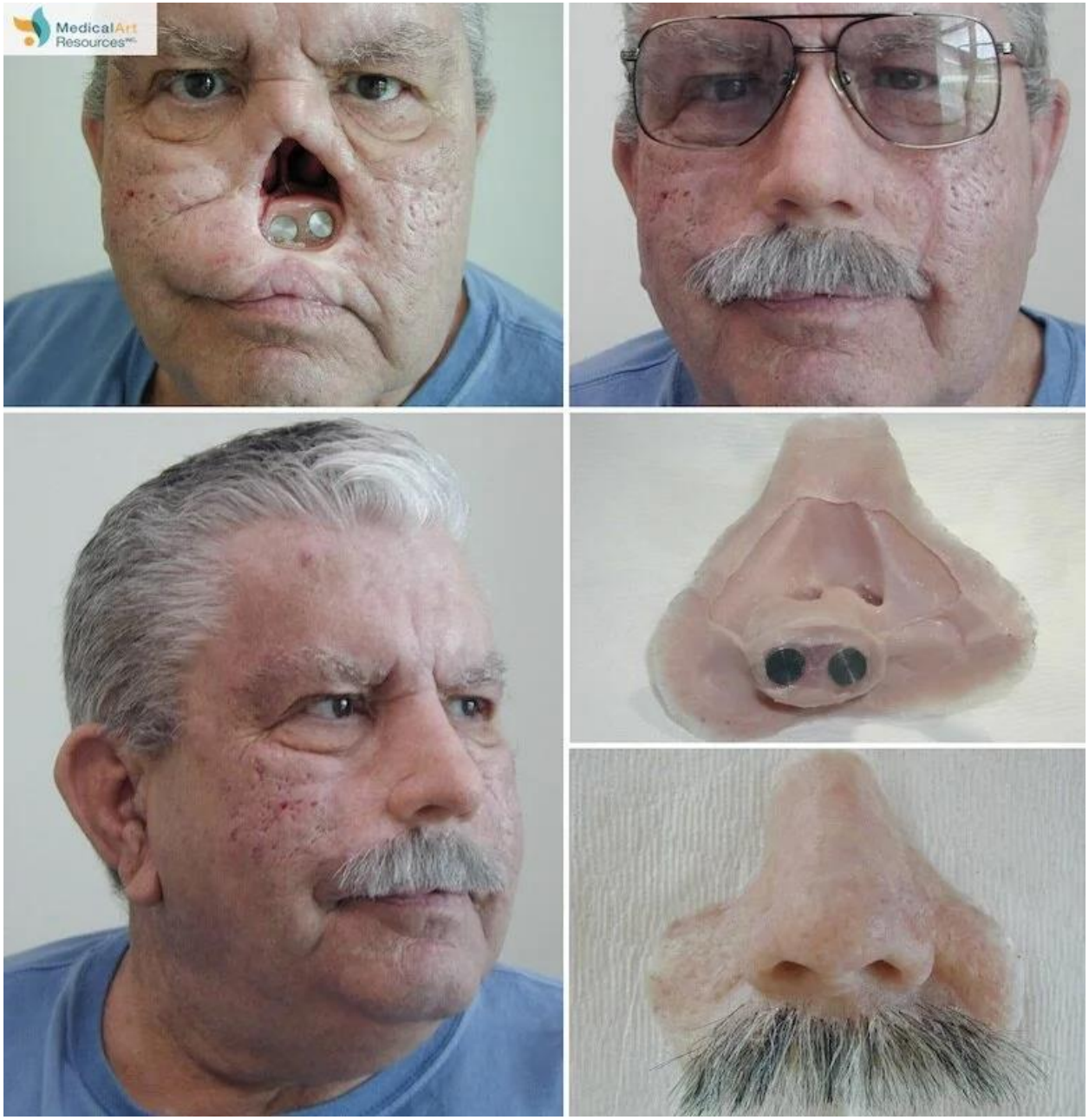
MedicalArt
Resources