Lec.13 **Oral Pathology**

Malignant tumors of the Bone **د. محمد عبد الحميد**

Osteosarcoma

Osteosarcoma is the most frequent primary bone malignancy; Osteosarcomas of the jaws are uncommon and represent 6-8 % of all osteosarcomas. The tumors have been diagnosed in patients ranging from young children to the elderly, but they occur most often in the 3rd to 4th decade of life. The mean age for patients with osteosarcoma of the jaw is about 33 years, with a slight male predominance is noticed.

Most osteosarcomas arise de novo; however, some arise within the context of the following:

1. Paget's disease.
2. Radiation exposure.
3. Chemotherapy.
4. Pre-existing benign bone lesions, e.g. fibrous dysplasia.
5. Foreign bodies, e.g. orthopedic implants

Clinical Features

The maxilla and mandible are equally affected. The mandibular tumors mostly arise in the posterior body and ramus. Maxillary lesions are discovered more commonly in the inferior portion (alveolar ridge, sinus floor, palate). ***Hard Swelling, persistent pain*** *and* ***parasthesia*** are the most common symptoms. Other features include loosening of the teeth, and nasal obstruction.

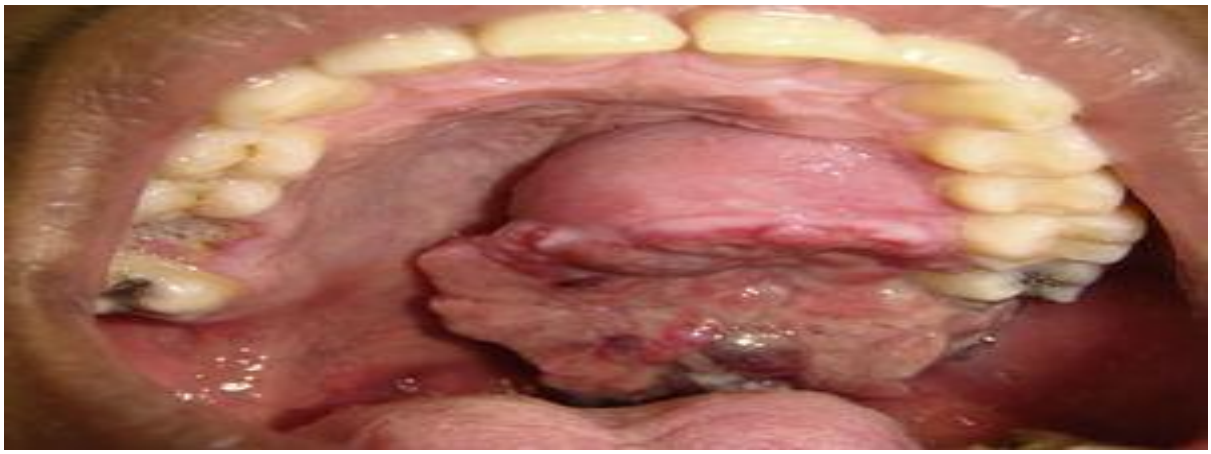

The tumor may spread from the following pathways :

1. Spread along the marrow cavity.
2. Invade the cortex.
3. Elevate or invade the periosteum.
4. Extend into the soft tissue.
5. Metastasize through blood stream to distant sites, particularly to the lung.

Histopathologicl Findings

Osteosarcomas are composed of sarcomatous tumor cells that produce malignant bone or osteoid tissues.

Many pathologists subclassify osteosarcomas into the following types:

1- **Osteoblastic**. The osteoblastic type is the most common in **long bones**, contains **hyper-cellular trabecular malignant bone**

2- **Chondroblastic**. Contains deposits of **hyper cellular cartilage** and **abnormal osteiod tissues**. **This type is the most common variant of the jaws.**

3- **Fibroblastic**. Composed of sarcomatous **spindle- shaped cells (Fibroblasts)** with little malignant osteoid.

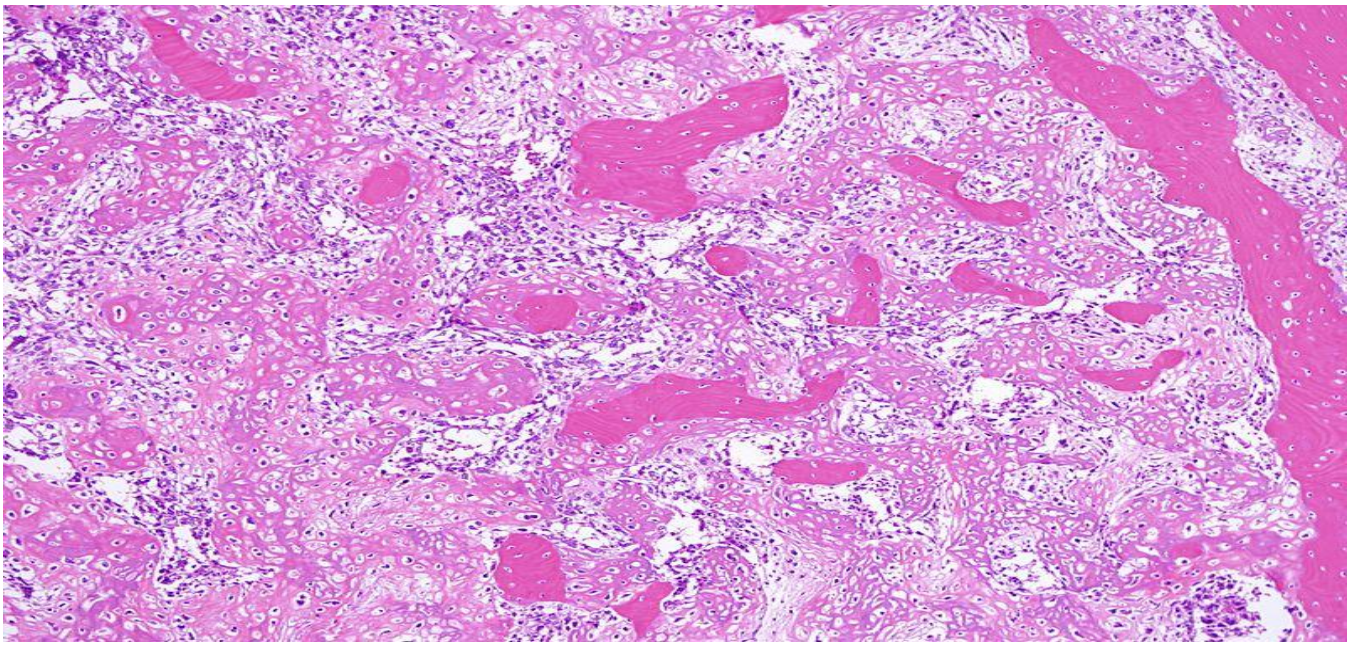

Osteoblastic Osteosarcoma

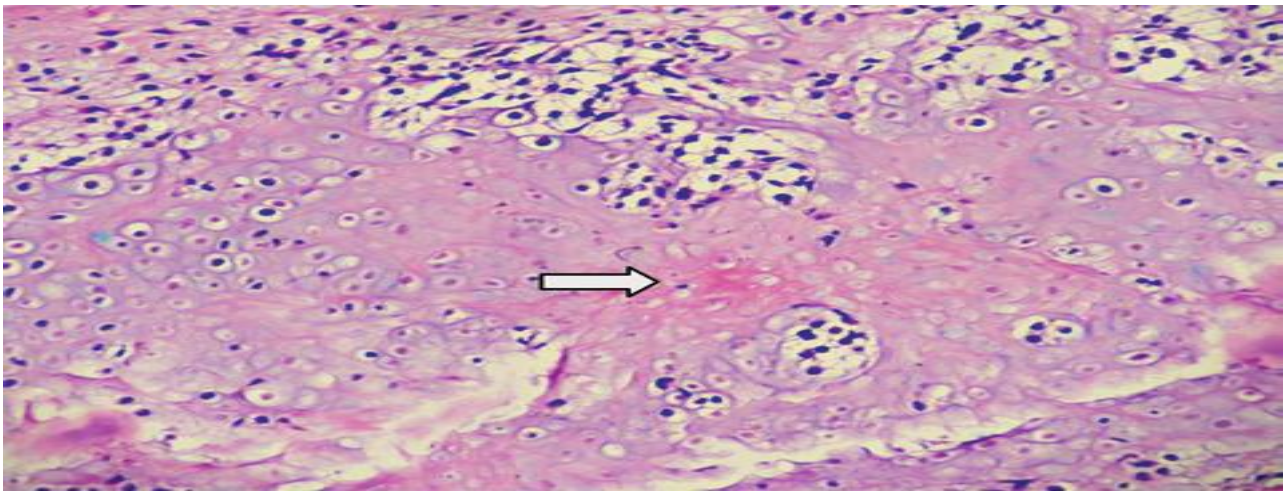

Chondroblastic OS

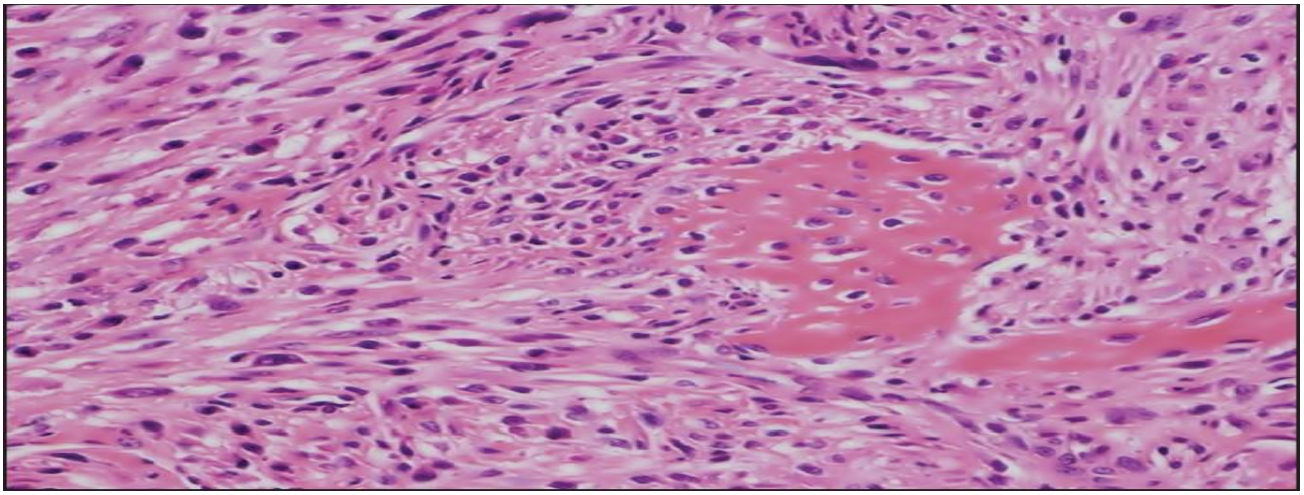

Fibroblastic OS

Radiographically

variable, from dense sclerosis to a mixed sclerotic and radiolucent lesion, to an entirely radiolucent(Can show radiopaque, radiolucent or mixed appearances). The border is mostly ill defined, making it difficult to determine the extent of the tumor. Occasionally, there is resorption of the roots of the teeth involved by the tumor. **The classical sunray appearance is due to the osteophytic bone production on the surface of the lesion noted in about 25% of jaw osteosarcoma, mostly seen on an occlusal projection ,** this pattern is not exclusive to **OS**, and it assists in the diagnosis. A characteristic finding in jaw lesions is **widening of the periodontal ligament** in adjacent teeth. Widening of the **PDL** may be seen as an early finding due to tumor infiltration along the PDL.

The radiographic appearance varies depending on the histological type. Some lesions, such as **fibroblastic type**, have little bone formation and are **radiolucent.** Lesions of **osteoblastic and chondroblastic type** form large amounts of mineralized bone like tissue, producing **large areas of radiopacity within a diffuse non-defined radiolucent** background.,

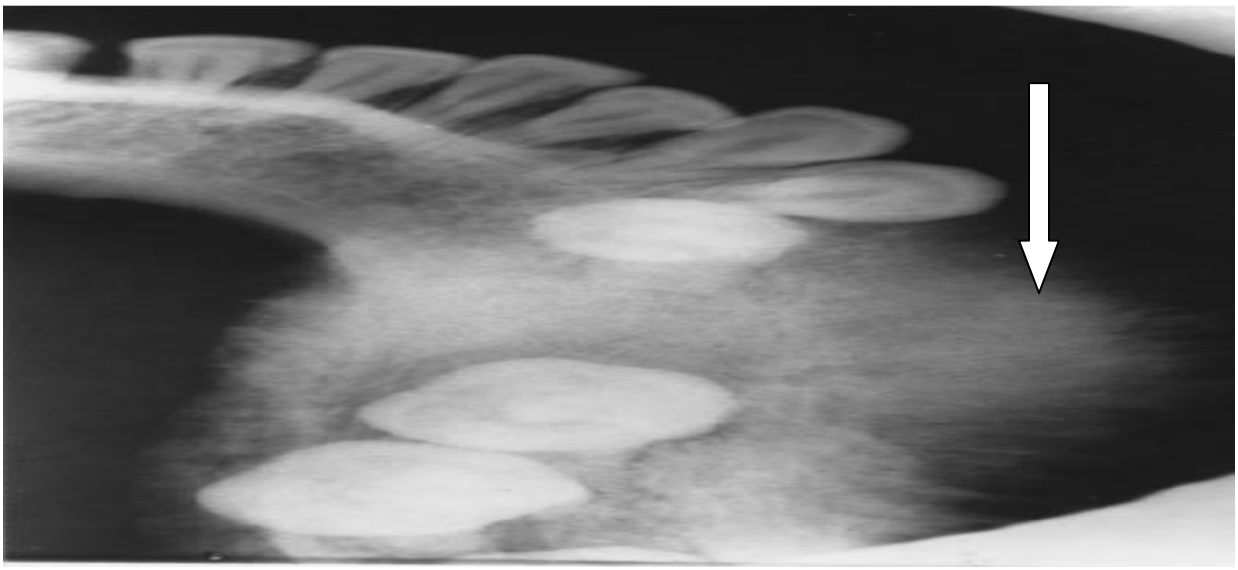

Treatment and Prognosis

It is believed that osteosarcoma of the jaw is less aggressive than those occurring in the long bones. Most of these tumors are low grade and metastases are seen less frequently. The treatment is usually a combination of **surgical resection** with safe margin of normal bone followed by **chemotherapy**.
The prognosis is better in the mandible than in the rest of the skeleton. The prognosis remains serious, with 30-50% survival rates.

Chondrosarcoma:-

Uncommon malignant bone neoplasm in the jaws, **usually** of **the anterior maxilla**, consisting of a proliferation of plump of chondroblasts or spindle shaped mesenchymal cells and producing **abnormal cartilage** but **no osteiod or bone**. Chondrosarchoma is a malignant tumor characterized by the formation of **cartilage, but not bone**, by the tumor cells. Chondrosarcoma comprises about 10% of all primary tumors of the skeleton but are considered to involve the jaws very rarely. Only 1-3 % of all chondrosarcomas arise in the head and neck area.

Lesions may be primary chondrosarcomas (arising directly from bone cells as malignant neoplasms) or secondary chondrosarcomas (arising in a pre-existing benign cartilaginous lesion such as osteochondroma).

Clinical Features

The majority of affected patients are over 50 years of age. When occurring in the head and neck, chondrosarcoma mostly arise in the maxilla, body of mandible, ramus, nasal septum, and paranasal sinuses.



A painless mass is the most common presenting sign. This may be associated with separation or loosening of teeth. In contrast to osteosarcoma, pain is an unusual complaint. Maxillary tumors may cause nasal obstruction, congestion, epistaxis, photophobia, or visual loss.

Radiographically

The tumor shows a **radiolucent** area with poorly defined borders. The radiolucent area usually contains a variable amount of radio-opaque masses, which is caused by calcification or ossification of cartilage matrix. Widening of the p.d. membrane of associated teeth also may occurs.

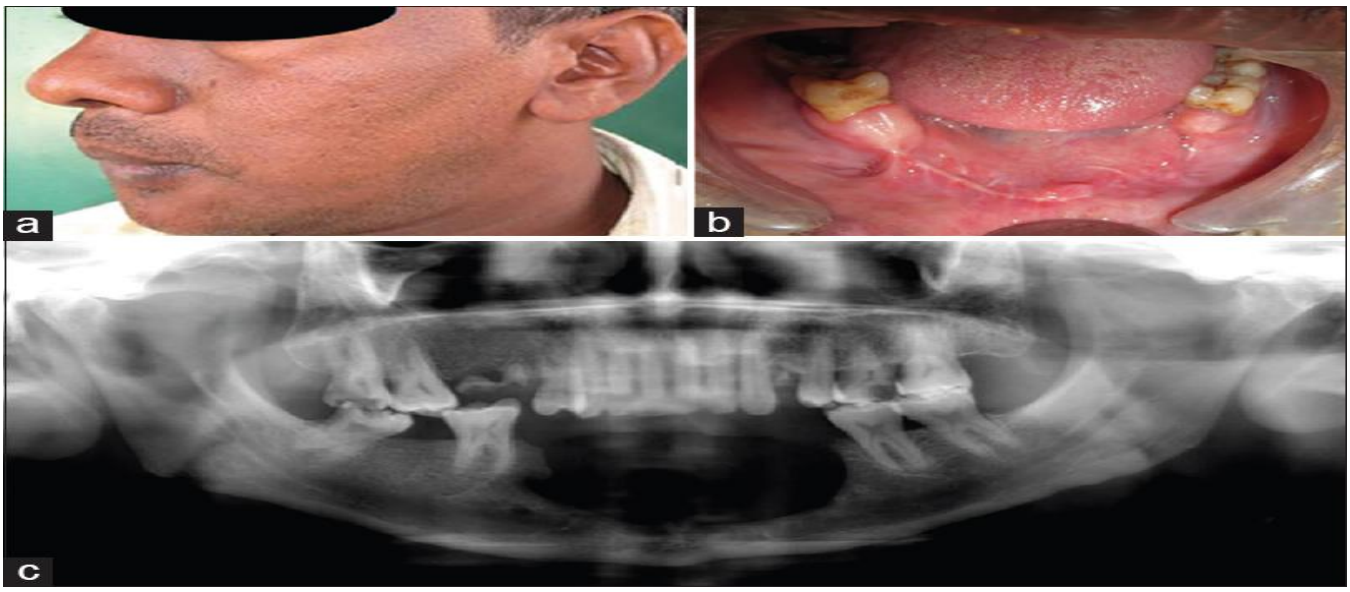

Histopathology

The tumor is composed of cartilage showing varying degrees of maturation and cellularity. The tumor should be considered malignant when large-plump chondroblasts and binucleated chondrocytes are present.

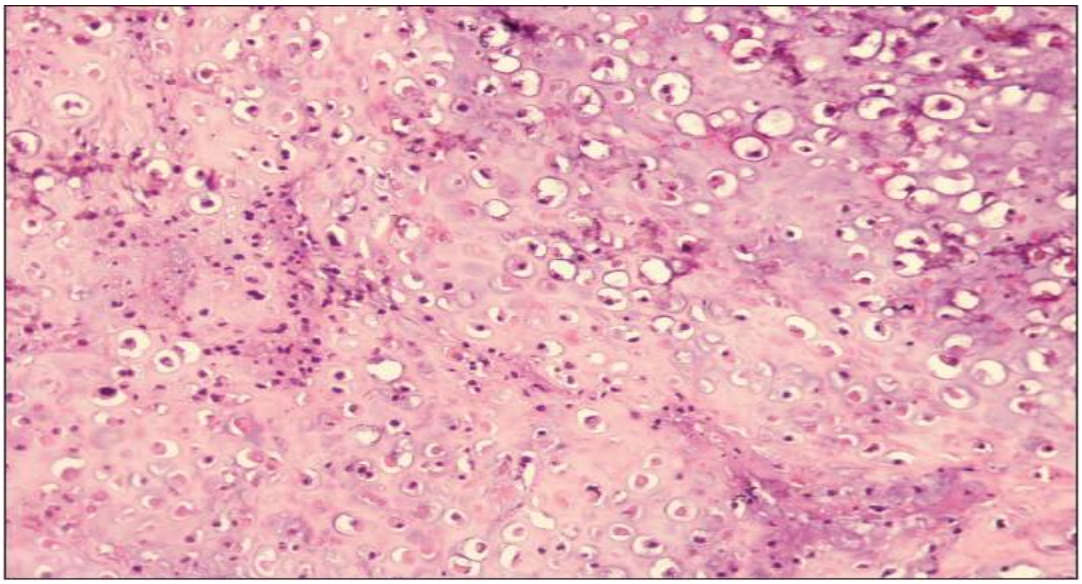

Chondroid areas with few atypical chondrocytes.

Treatment and Prognosis

Treatment is by resection. Wide surgical excision. The extent of surgical margin depends on the size and grade of the lesions. Metastasis is usually to the lungs and other bones. Prognosis is related to size and location. 5-years survival rate varies from 43%-95%.

Ewing's Sarcoma

Ewing's sarcoma (ES) is an uncommon malignancy of childhood and adults that constitutes 6%–8% of all primary malignant tumors and the third-most common tumor after osteosarcoma and chondrosarcoma, frequently involves the mandible among jaw bones. ES was named after ***James Ewing*** who first described it in the year 1921. Although it may involve any bone, the long bones and pelvic girdle are involved most commonly

Clinically

Ewing's sarcoma is an aggressive tumor showing rapid growth and metastasis .The vast majority of affected patients are white, with blacks almost never developing this tumor

Ewing sarcoma is more common in males and usually presents in childhood or early adulthood, with a peak between 10 and 20 years of age. It can occur anywhere in the body but most commonly in the pelvis , femur , followed by the tibia and the humerus.. 10-15% of people present with a pathologic fracture at the time of diagnosis. People usually experience **extreme bone pain**. Signs and symptoms include intermittent fevers, anemia, leukocytosis, weight loss, parasthesia and loosening of teeth, increased erythrocyte sedimentation rate (**ESR**), and other symptoms of inflammatory systemic illness.

It comprises 10% of the malignant bone tumors. 1% of lesions affecting the jaws. The tumor commonly penetrates the cortex, resulting in a soft tissue mass, overlying the affected area of bone.



Radiographically

There is **irregular lytic bone destruction with ill-defined margins** .The involved bone appears as multiple small endosteal lucent lesions or holes, often with poorly defined margins.

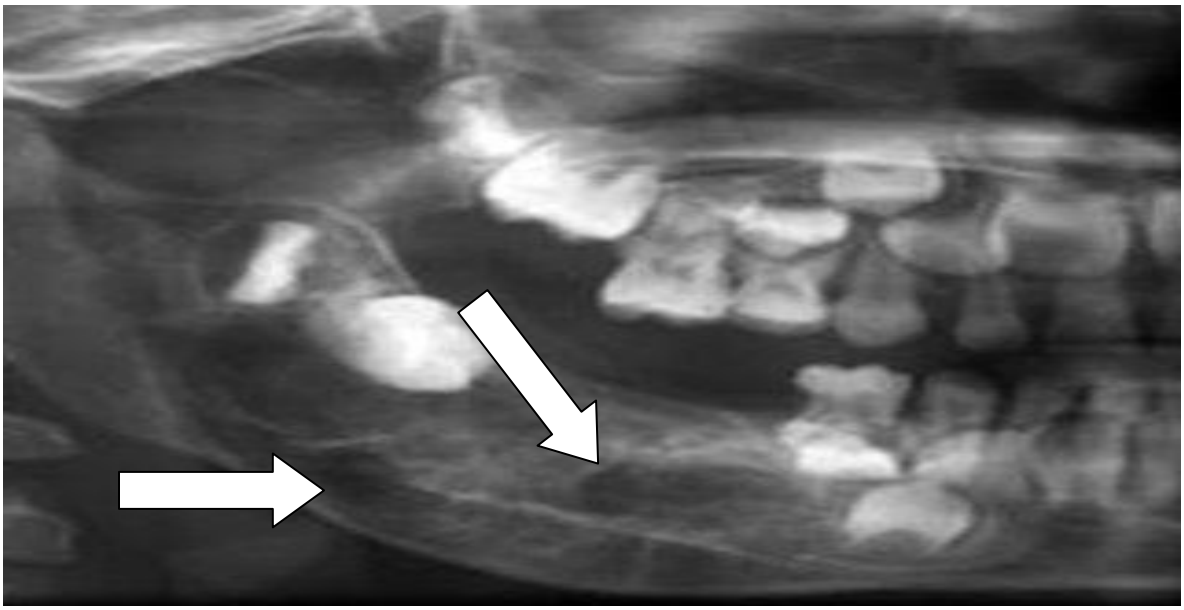

Histopathology:-

The routine light microscopic evaluation is insufficient for diagnosis. It usually requires additional stains, electron microscopy, or immunohistochemical markers. Individual cells may be of 2 types:-

- Clusters of **small round cells** with **darkly staining nuclei** and
- **Larger cells** with **finely granular nucleus** and a faint ill- defined cytoplasm.

PAS stain demonstrates ***glycogen granules*** in neoplastic cells.

About 75% of cases contain ***glycogen granules*** in the cytoplasm of the tumor cells.

This help in the diagnosis.

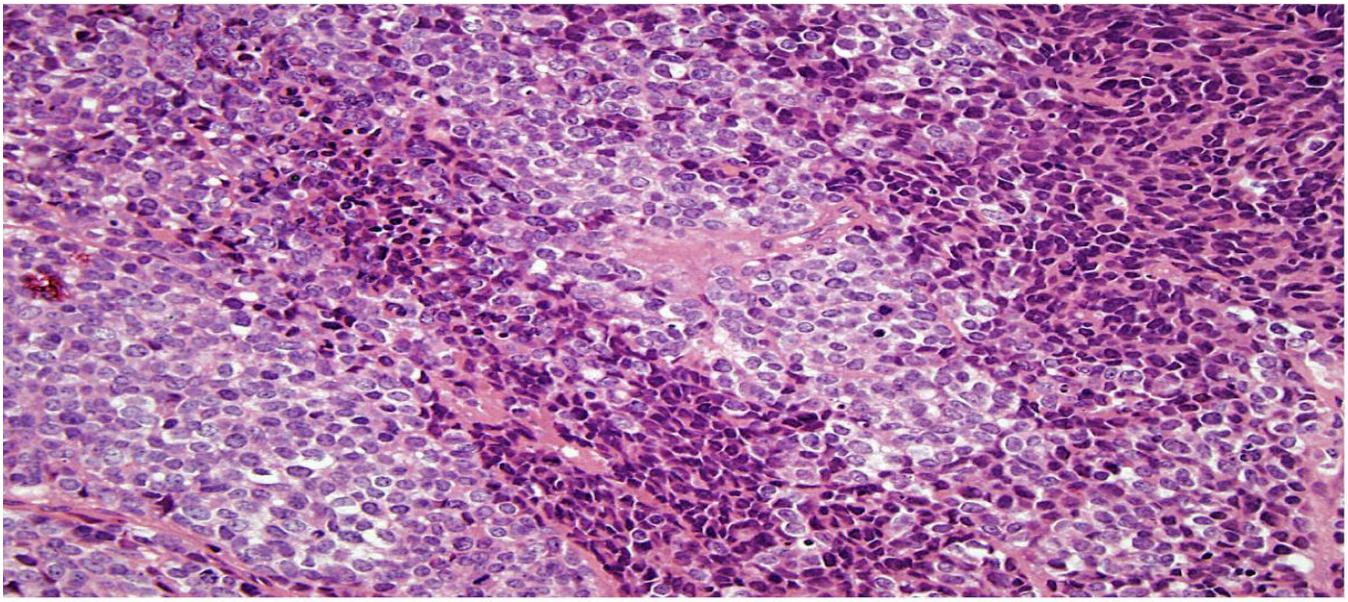

"light" cell and "dark" cell appearance

Spread and Metastases

To lung and pleura, other bones particularly the skull, CNS, and rarely to the lymph nodes.

Treatment:-

Both chemotherapy and radiotherapy. The treatment in the past consisted of surgical excision, and radiation therapy resulting in a 5 year survival rate of less than 10%. The combination of high dose radiotherapy and multidrug chemotherapy has dramatically changed the picture and the 5 year survival rate to 75%.

Burkitt's Lymphoma

Is a malignancy of B-lymphocyte origin**.** Burkitt's lymphoma was first characterized by ***Denis Burkitt in 1958*** ,usually diagnosed in children and young adults, but rarely seen in middle-aged adults. It is now accepted that there are three subtypes:
- The **endemic (African) type**, that has a peak incidence between the ages of 5 and 7 years and involves the jaw in more than 50% of cases;
- The **sporadic (American) type**, with a mean age of 11 years and usually presents as an abdominal mass;
- The third type that is associated with acquired immunodeficiency states. The clinical presentation of Burkitt's lymphoma is characterized by rapid progression of symptoms with frequent multifocal extranodal involvement. Within the oral cavity, this tumour can progress very fast and appears as a **facial swelling or exophytic** mass involving the jaw**.**

Clinical Features

50-70% of the cases presented **with jaw mass**. The malignancy usually affects children (peak prevalence 7 years of age). The posterior segments of the jaws are more commonly affected , maxilla more than the mandible. The American type tends to affect patients over a greater age range, with the abdominal region typically affected, although the jaw has been reported to be affected. This tumor is thought to be related pathogenetically to **Epstein-Bar virus (EBV)**, because more than 90% of the tumor cells, particularly in the African type, show expression of **EBV nuclear Ag**. And the affected patients have a high titer to **EBV**.The tumor may produce facial swelling and proptosis, pain, tenderness, and parasthesia, with marked tooth mobility.



Radiographically, radiolucent destruction of the bone with ragged ill-defined margins.

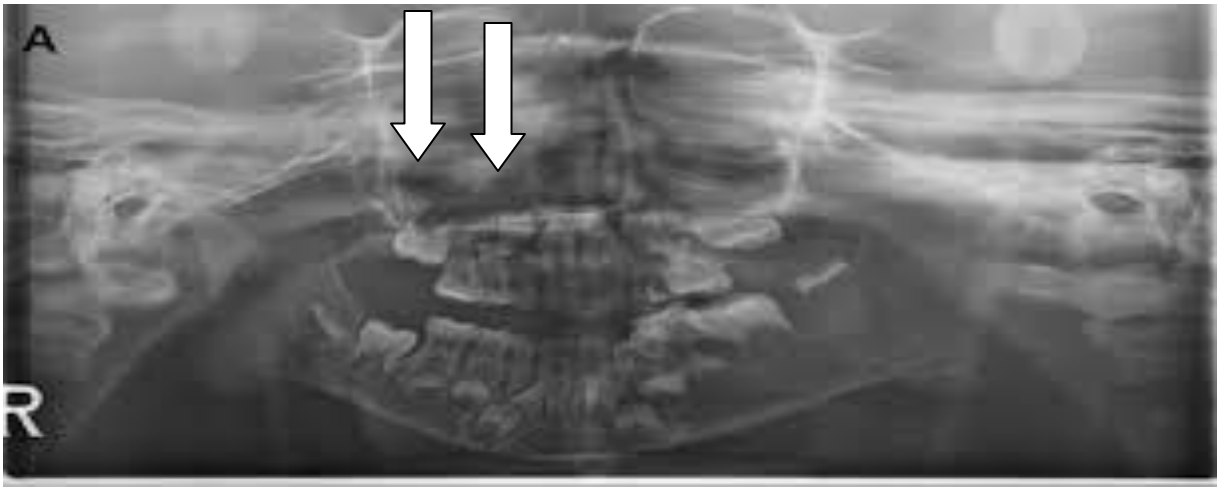

Radiolucent with ill-defined margins

Histopathology

Undifferentiated small B-lymphocytes. The lesion is composed of sheets of tumor cells with prominent mitoses. The classic ***starry sky pattern*** **(the stars are the macrophages phagocyting the apoptotic tumor cells, and the sky is the neoplastic B lymphocytes)**

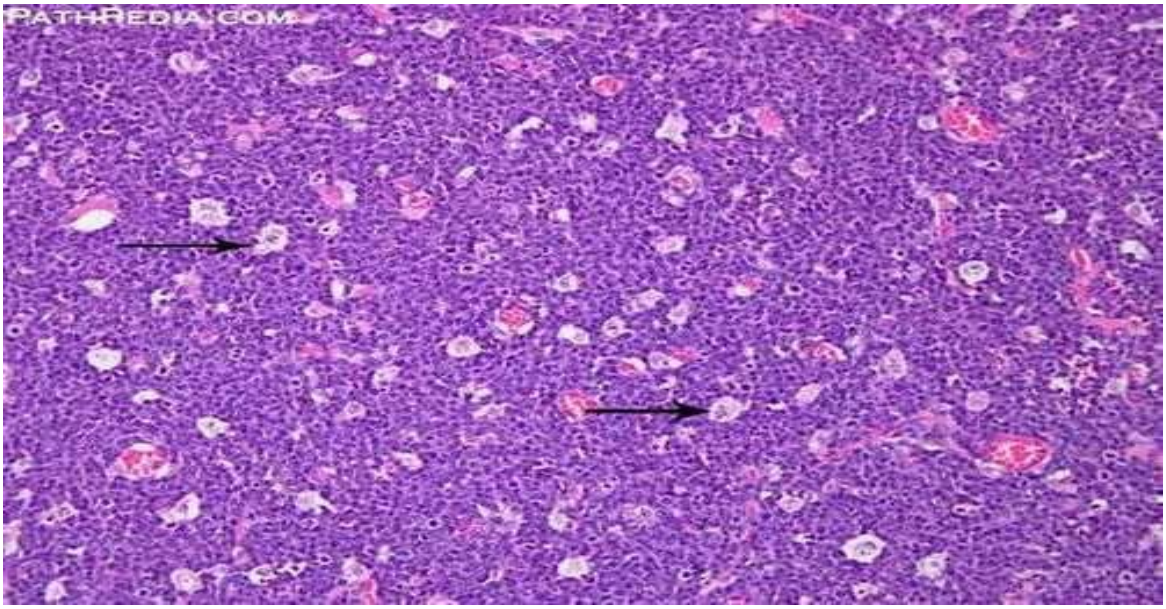

Treatment and Prognosis

The tumor is aggressive; death will result in 4-6 months if not treated. Treatment by intensive chemotherapy.

Multiple Myeloma (MM)

Myeloma is from the Greek *myelo-* meaning "marrow" and *-oma* meaning "tumor
also known as **plasma cell myeloma** and simply **myeloma**, is a cancer of plasma cells, a type of white blood cell that normally produces antibodies. Often, no symptoms are noticed initially. As it progresses, bone pain, anemia, kidney dysfunction, and infections may occur**.** The cause of multiple myeloma is unknown. Risk factors include obesity, radiation exposure, family history, and certain chemicals. **The abnormal plasma cells produce abnormal antibodies (Myeloma protein (M band))** , which can cause kidney problems **.**The plasma cells can also form a tumor mass in the bone marrow or soft tissue**.When one tumor** is present, it is called a **plasmacytoma**; more than one is called **multiple myeloma.**

Clinically

Because many organs can be affected by myeloma, the symptoms and signs vary greatly.
-Fatigue and bone pain are the most common symptoms at presentation.
-Anemia
-Impaired kidney function
-Infection
- Pathological fracture
- Bleeding tendency due to abnormal platelet function.

In the mouth the initial symptoms may involve **pain, numbness, swelling, expansion of the jaw, tooth mobility**. **Multiple myeloma in the mouth can mimic common teeth problems like periapical abscess or periodontal abscess, gingivitis, periodontitis, or other gingival enlargement or masses .**Patients present with painful, lytic bone lesions and fracture. More than 30% of the patients with multiple myeloma develop osteolytic lesions in the jaws.

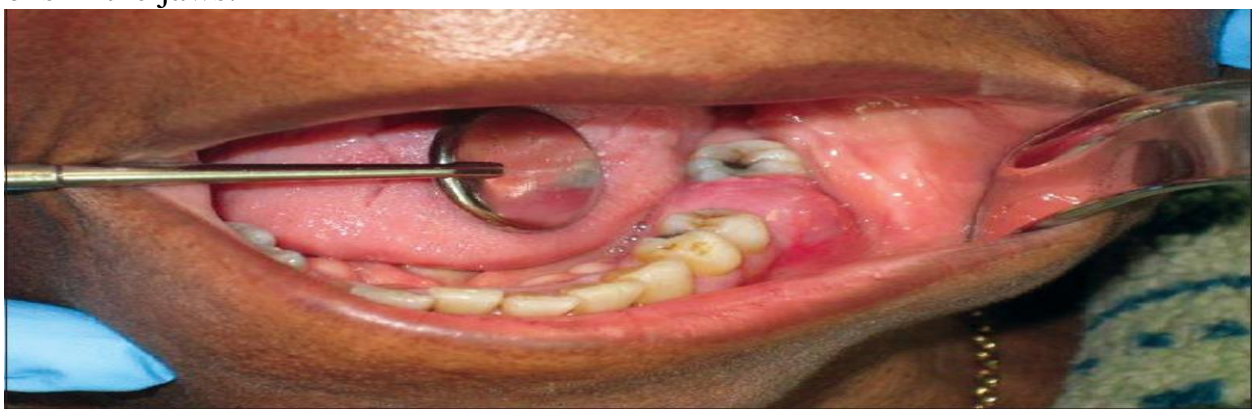

Radiologically

Multiple well-defined, punched out radiolucencies, or ragged radiolucencies may be seen **in MM**. These may affect the skull, although any bone can be affected. The jaws may be involved in 30% of cases.

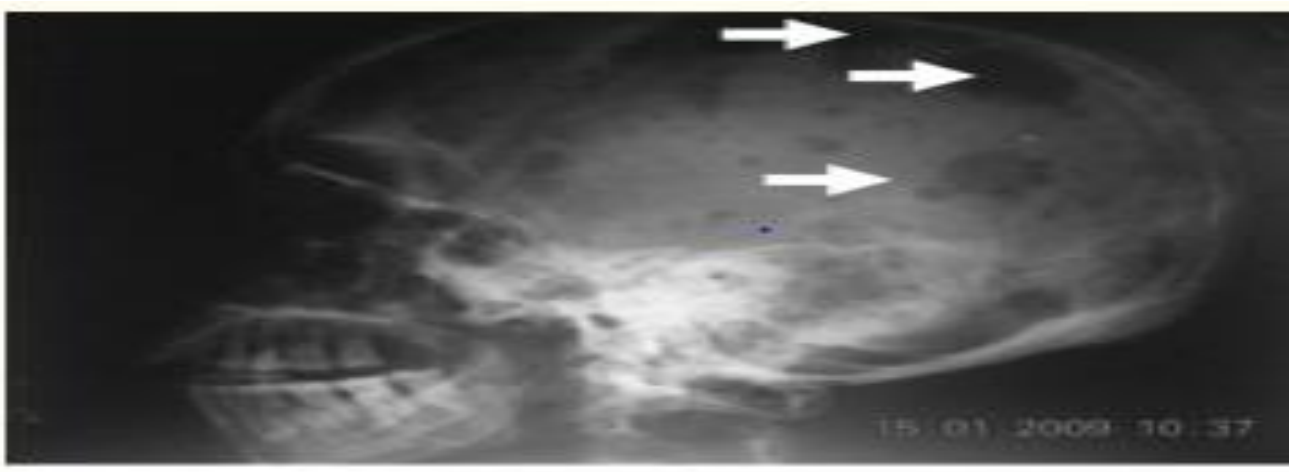

Histopathology

Show diffuse, monotonous sheets of neoplastic, variably differentiated, plasma cells that invade and replace the normal host tissue, with frequent mitoses.,

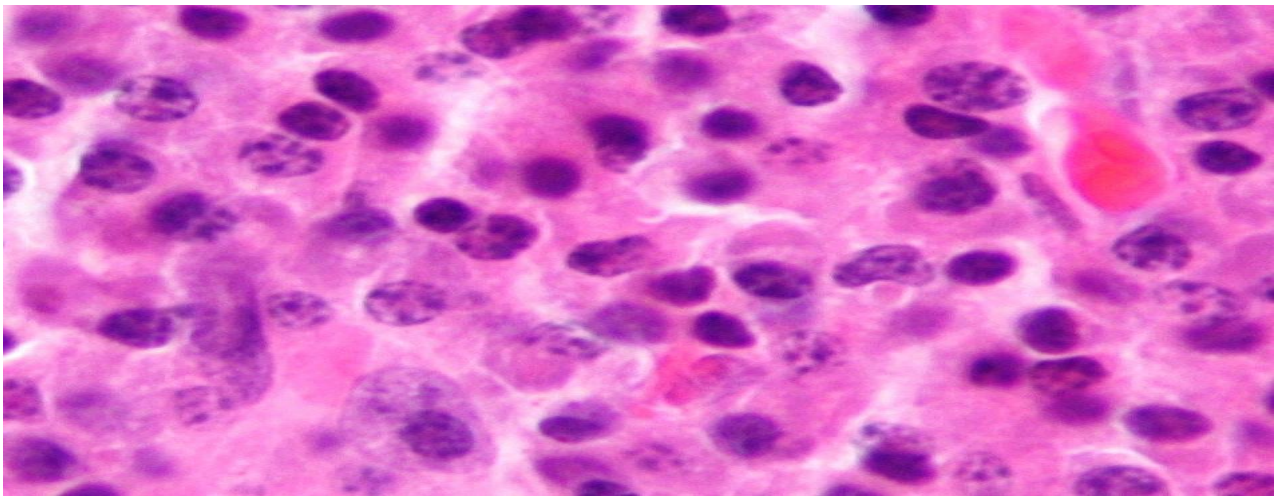

Treatment

Chemotherapy with bone marrow transplantation, with poor prognosis, 5 years survival rate is 25% only.

Metastatic Tumors to the Jaw

Metastatic carcinoma is the most common form of cancer involving bone. Studies show that 2/3 of breast carcinoma. 1/2 of prostate carcinoma, 1/3 of kidney and lung cancer ► bone spread.

Jaw bone metastasis is mainly from breast, lung, kidney, thyroid, prostate ► by hematogenous route.

Clinical Findings

Elderly individuals are mostly affected. The mandible may be involved in about 10% of metastatic extra oral carcinoma. Maxillary metastasis is uncommon.

Clinically, the patient may report pain, lump, loosening of teeth, and parasthesia, or the patient may be completely asymptomatic. The jaw lesion may be the 1st indication of the existence of primary tumor.

Radiographic Features

May be **lytic**, resembling a cyst, sometimes causing **widening** of periodontal ligament. Others may stimulate new bone formation ► **radiopaque or mixed lesion e.g. prostate and breast carcinoma.**