Benign cystic lesions of the oral cavity

Dr.Raad Salah Shyaa

- A cyst is defined generally as an epithelium-lined sac filled with fluid or soft material.
- Palpation with firm pressure may indent the surface of an expanded jaw.
-

NON-ODONTOGENIC CYSTS

1. Incisive canal cyst
2. Nasolabial cyst
3. Sublingual dermoid cyst

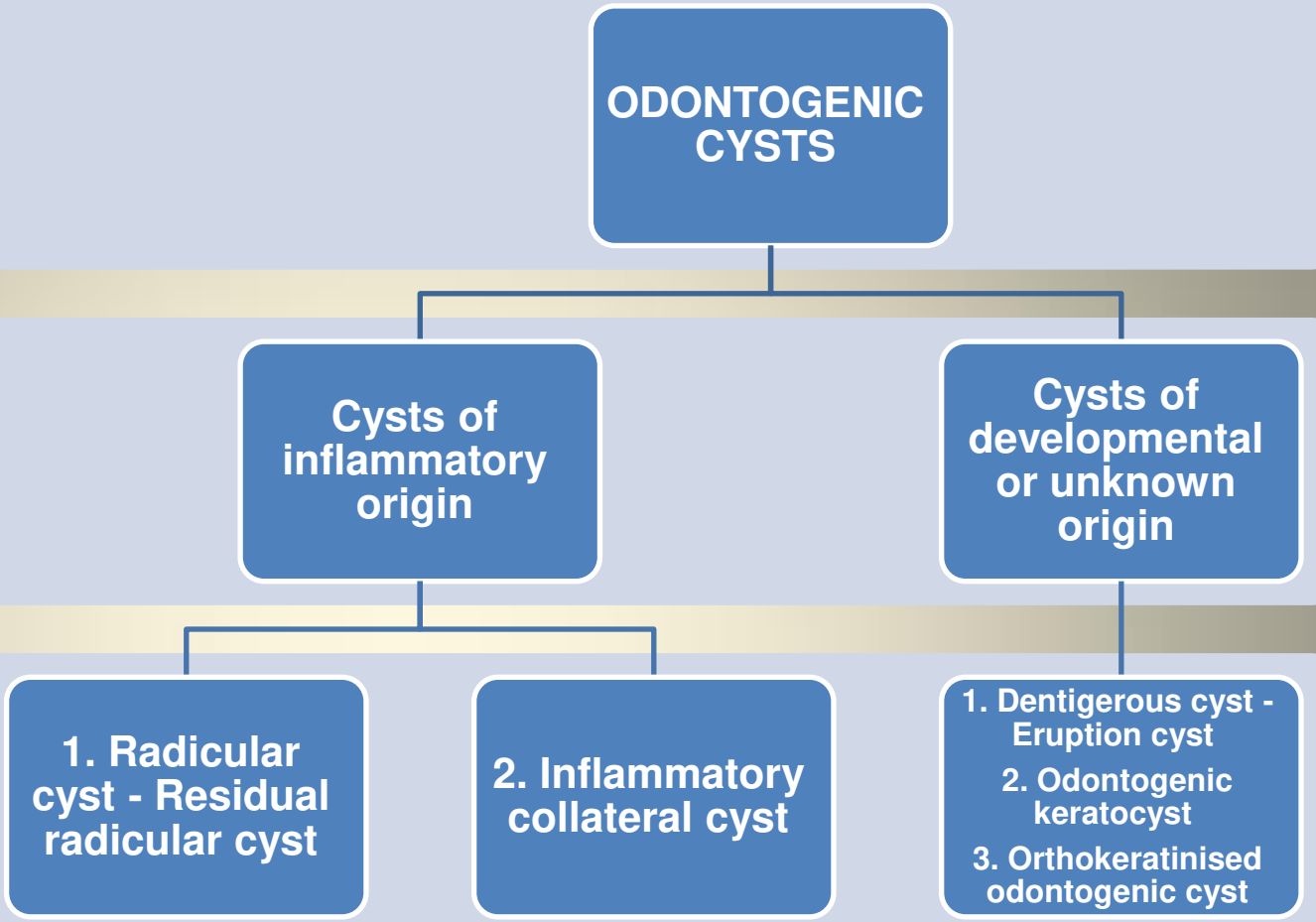

CLINICAL FEATURES

- Asymptomatic unless they are secondarily infected.
- Detected accidentally on routine radiographs.
- The overlying mucosa is normal in color and consistency.
- No sensory deficits from encroachment on nerves are found.

RADIOGRAPHIC FEATURES

- A distinct, dense periphery of reactive bone with a radiolucent center.
- Most cysts are unilocular; however, multilocular forms are often seen in some keratocysts and cystic ameloblastomas.
-

RADICULAR CYST

- **Clinical features**

o The age at presentation 20–60 years.

o More common in males than female (3:2)

.

o The maxilla is affected more than three times as frequently as the mandible.

o Slowly progressive painless swelling, with no symptoms until the cyst becomes large enough to be noticed .

o The swelling is rounded and at first hard. Later, when the bone has been reduced to eggshell thickness, a crackling sensation may be felt on pressure.

o Finally, part of the wall is resorbed entirely away, leaving a soft fluctuant swelling, bluish in colour .

o Infection may supervene because of the associated non-vital tooth, and the swelling becomes painful

- Radiography
- Rounded, radiolucent area with a sharply defined outline. A condensed radiopaque corticated Periphery may be present.

- The dead tooth from which the cyst has arisen often has a large carious cavity or other cause evident.

- When bone has been reduced to egg shell thickness, a crackling sensation may be felt on pressure.




(a)

- Treatment
- Enucleation and primary closure. The associated non-vital tooth is usually extracted because radicular cysts tend to develop in irregular dental attenders, and the tooth is often unrestorable.

- Residual radicular cyst

DENTIGEROUS CYSTS

- Is an expansion of the follicle caused by separation of the reduced enamel epithelium from the enamel.
- The cyst wall is attached to the neck of the tooth, prevents its eruption.

Clinical features

- More than twice as common in males as females, and two-thirds develop on lower third molars.
- Upper canines and lower premolars are also affected,.
- Present between the ages of 10 and 30 years.
- Expand with displacement of adjacent structures.

Radiography

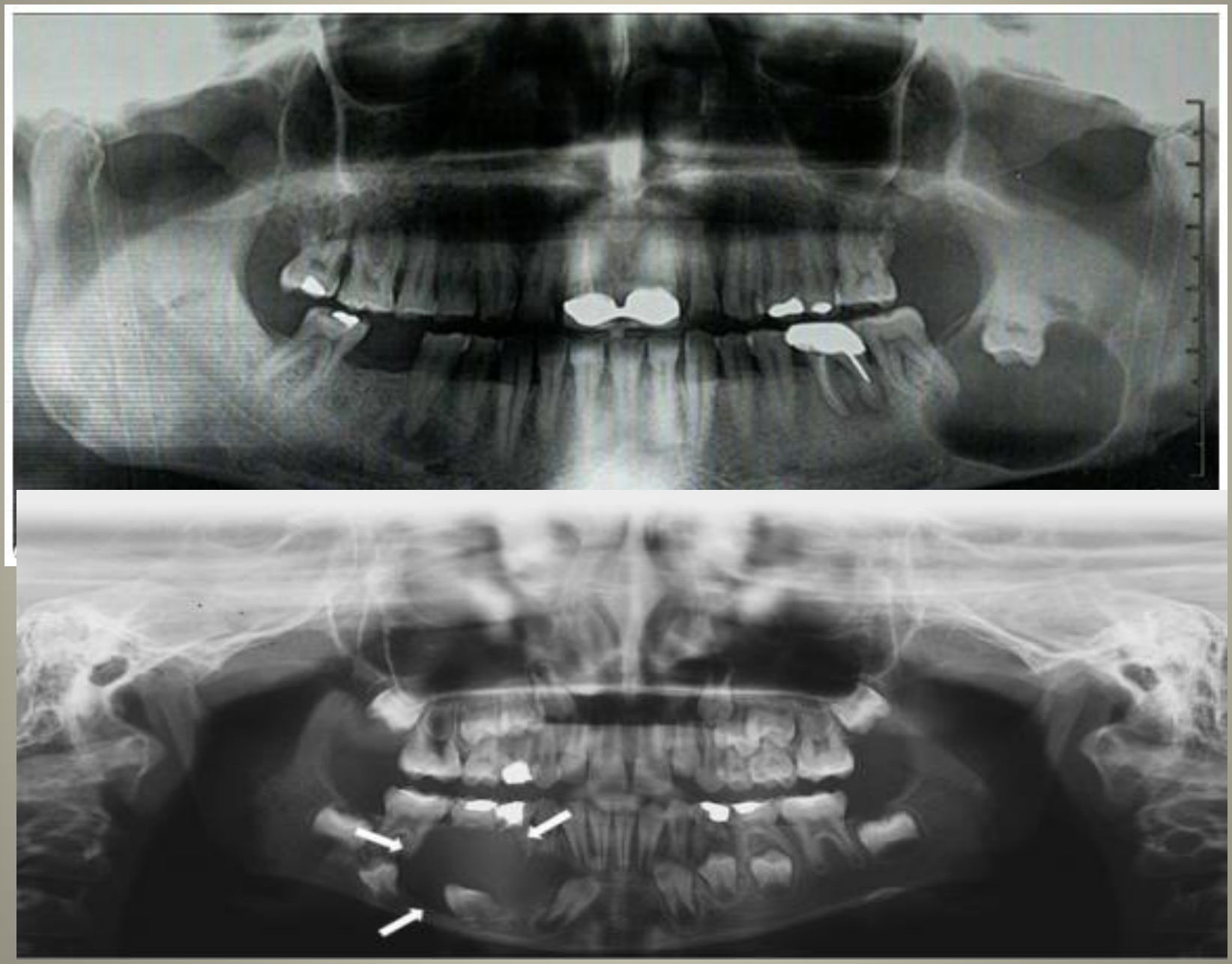

- Treatment
- Enucleation with removal of the unerupted lower third molar.

- for other teeth, such as maxillary canines that are in a favourable position, it may be possible to marsupialise a dentigerous cyst to allow the tooth to erupt,

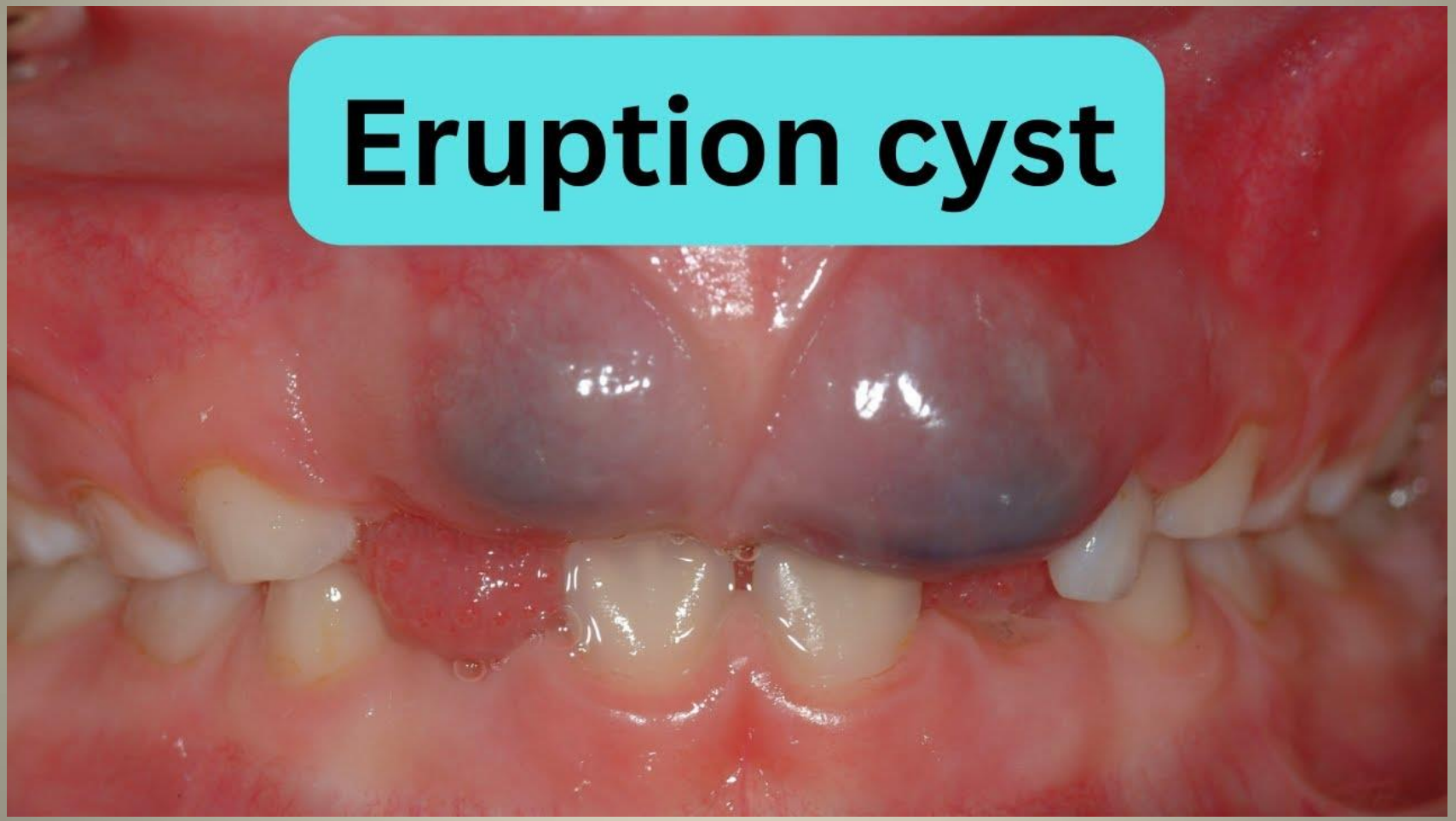
Eruption cyst

ODONTOGENIC KERATOCYST

- Keratin filling the cyst lumen is bright white and when seen at operation is a useful diagnostic feature indicating these cyst types .

Clinical features

- Peak incidence is between ages 20 and 30 years o Mandible is usually affected.
- At least 50% of odontogenic keratocysts form in the posterior body and lower ramus.
-
- Symptomless until the bone is expanded or they become infected, both rare features in this cyst.

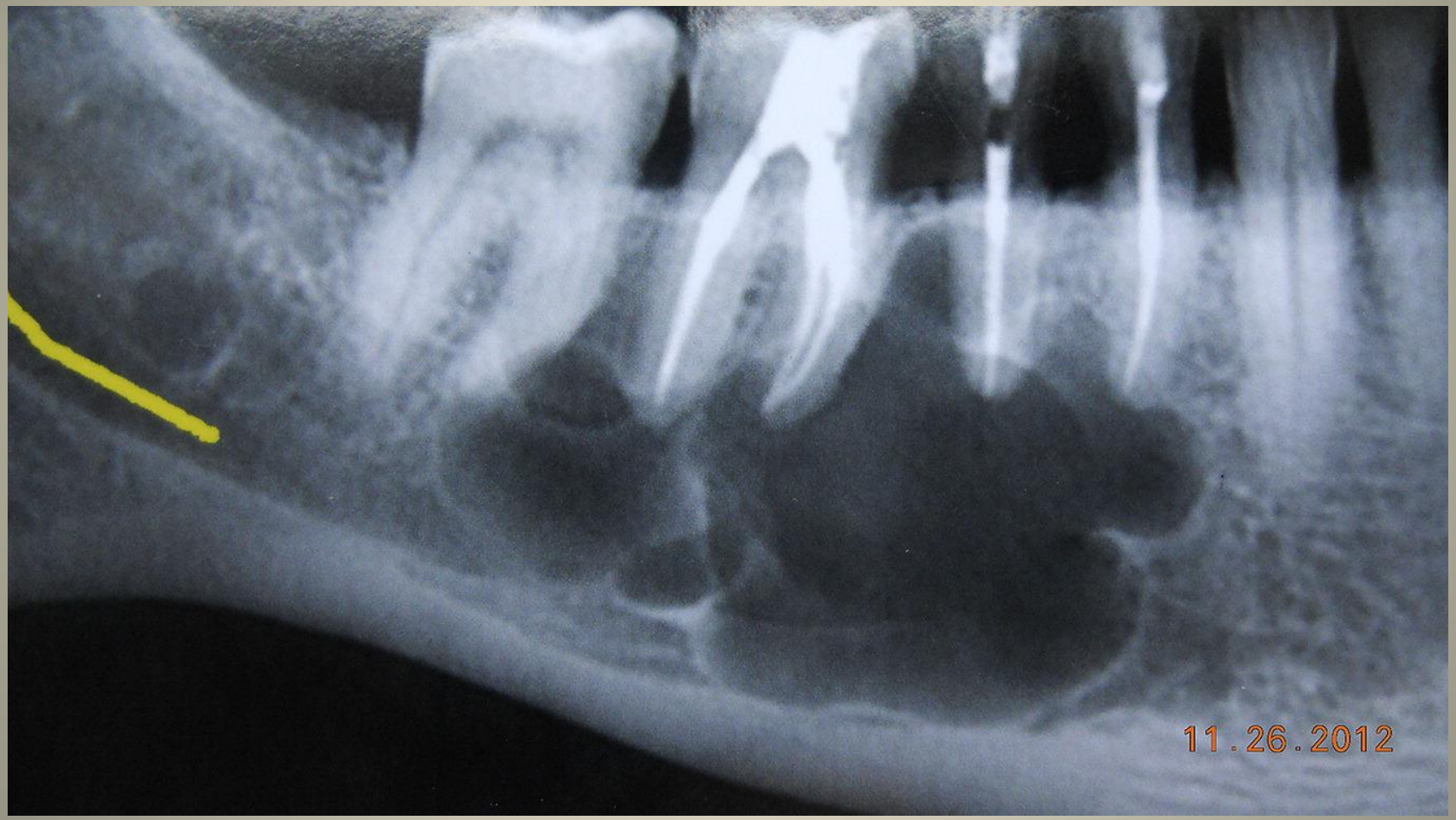
11.26.2012

Treatment

I. Simple enucleation.

II. Marsupialization.

III. Resection and reconstruction.

Basal cell naevus syndrome (Gorlin's or Gorlin-Goltz syndrome)

- Inherited autosomal dominant trait .

- Triad of multiple basal cell carcinomas, odontogenic keratocysts and various skeletal anomalies.




R
L

Other types

- ORTHOKERATINISED ODONTOGENIC CYST
- LATERAL PERIODONTAL CYSTS
- GLANDULAR ODONTOGENIC CYST
- GINGIVAL CYST OF THE NEWBORN
- Epstein’s pearls



SURYA
dental care

Epstein Pearls:
Symptoms, Causes And Treatment Options



NASOPALATINE DUCT OR INCISIVE CANAL CYST



- NASOLABIAL CYST

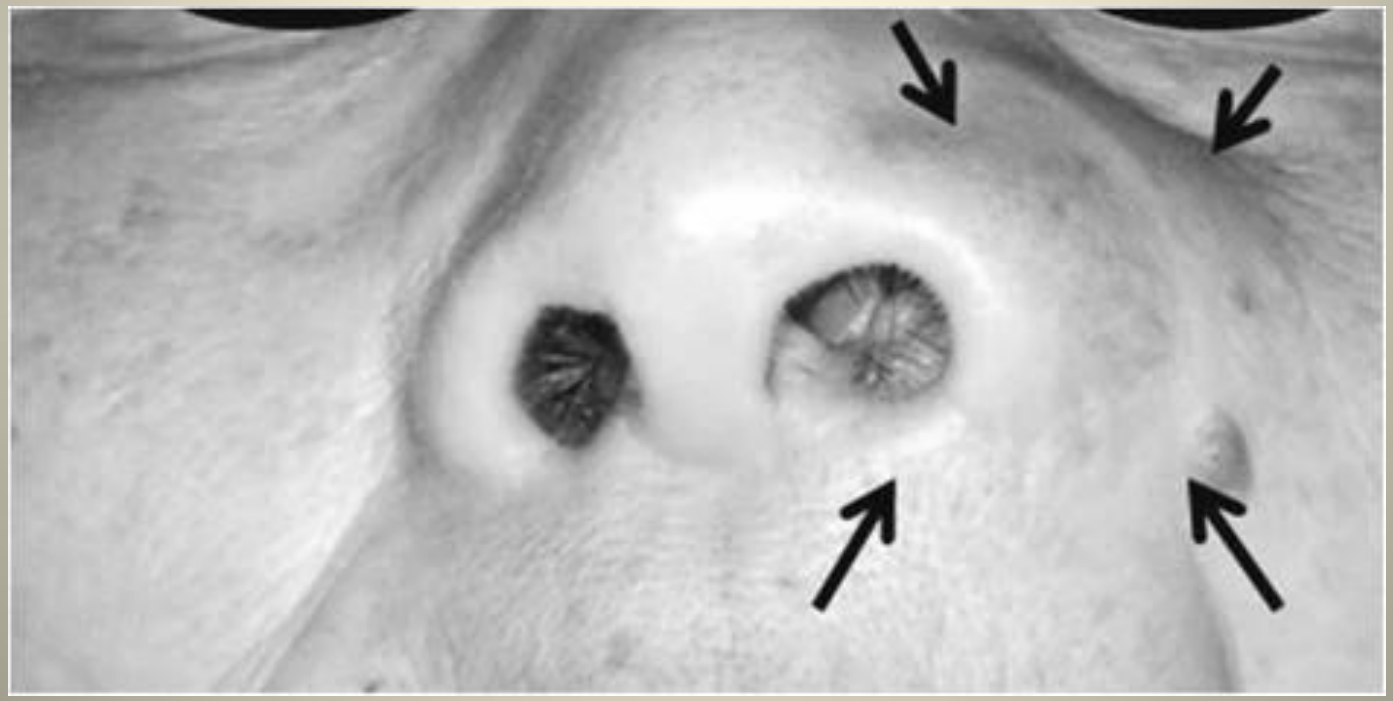

SUBLINGUAL DERMOID CYST



- THYROGLOSSAL DUCT CYST

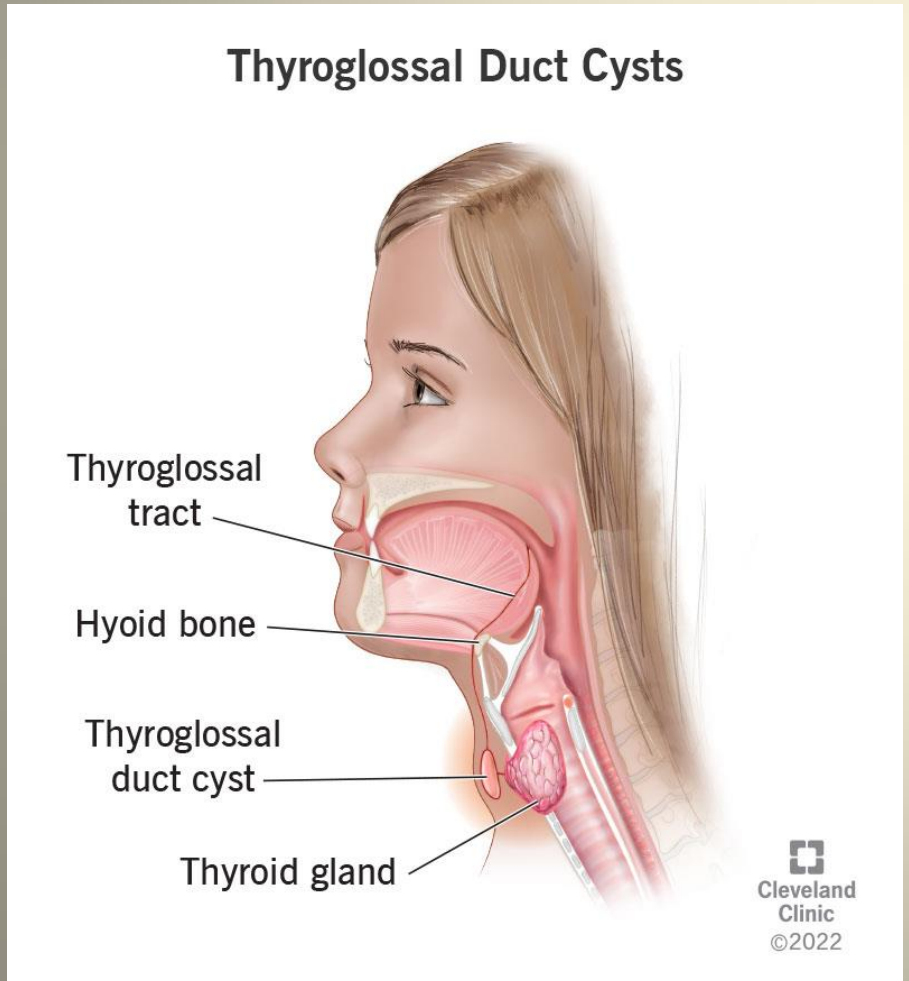



BRANCHIAL CYST

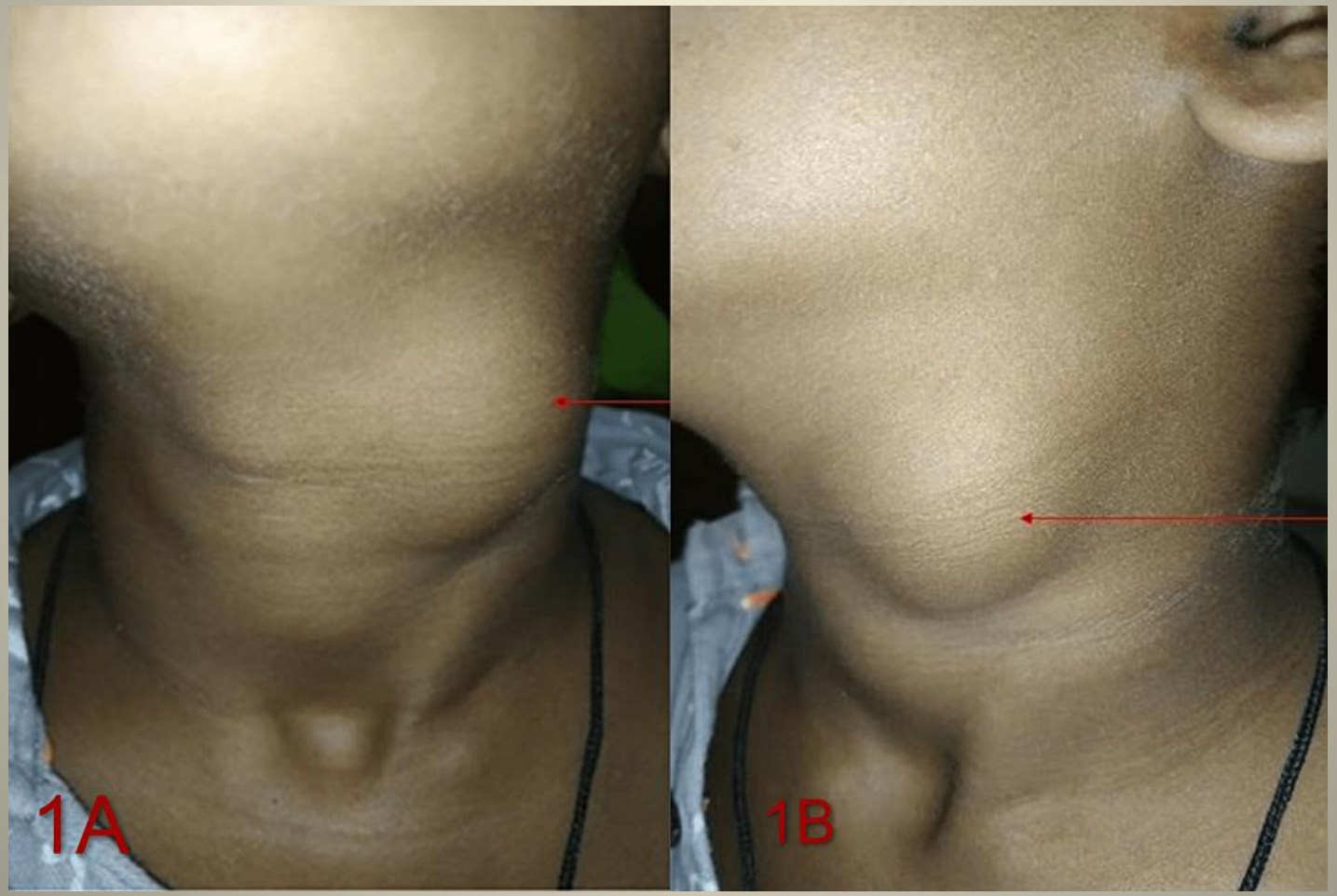

- Cysts of the jaws are treated using one of the following four basic methods:

(1) enucleation (cystectomy).

(2) marsupialization (conservative excision).

(3) a staged combination of the two procedures.

(4) enucleation with curettage.

ADJUNCTIVE TREATMENT

(Applies To Cysts With High Recurrence Rates)

- Peripheral ostectomy and curettage
- Theoretically, removing an additional 1 to 2 mm of bone peripherally with a carbide bur or curette can eliminate cells or daughter cysts beyond the osseous cavity. Consistent and complete removal can be aided by application of methylene blue to the cavity with bone removal until the dye is gone.
-
- Cryotherapy
- Application of liquid nitrogen to osseous cavities after enucleation has been shown to reduce recurrence rates and reduce the need for resection. Freezing the residual bony cavity in this

- Chemical Treatment:
- Carnoy’s solution.

- Topical 5-Fluorouracil

Cytotoxic chemotherapy drugs that inhibits DNA and RNA synthesis of cancer cells. It has been used recently in the treatment of Keratocysts.