Developmental cysts of the jaws

Cysts of Jaws

True cyst: ***Definition***: It is a pathological cavity contains lumen and lined by epithelium and surrounded by outer connective tissue wall (capsule).

The cystic cavity may contain fluid or semi-fluid material such as cellular debris, keratin or mucous material and usually grows from internal pressure generated by fluid being drawn into the cavity from osmosis (hydrostatic pressure).

Pseudo cysts: - Are cystic cavities that possess no epithelial lining e.g. traumatic bone cyst.

Most cysts of oral region are true cysts, either of **odontogenic or of non-odontogenic.**

Classification of cysts:-

True cyst

A- Developmental (odontogenic origin):

1- Dentigerous cyst.
2- Eruption cyst
3- Odontogenic kerato cyst.
4- Gingival (alveolar) cyst of new born
5- Lateral periodontal cyst.
6- Gingival cyst of adult.
7- Glandular odontogenic cyst.
8- Calcifying odontogenic cyst.

B- Inflammatory

1- Radicular (periapical)
2- Residual cyst.

C- **Developmental non – Odontogenic cysts:-**

1- Nasopalatine duct cyst.
2- Nasolabial cyst
3- Lympho epithelial cyst
4- Cervical lympho epithelial cyst
5- Thyroglossal duct cyst
6- Dermoid cyst
7- Epidermoid cyst

False cyst (pseudo)

1- Traumatic bone cyst.
2- Aneurysmal bone cyst.

Histogenetic classification of odontogenic cysts:-

Odontogenic cysts are derived from the following epithelial structures: **Rest of malassez**, **reduced enamel epithelium and remnants of dental lamina**. Cysts derived from **Rest of malassez**: - **Peri-apical cyst, residual cyst.**

Cysts derived from **reduced enamel epithelium: - Dentigerous cyst, eruption cyst.**

Cysts derived from **dental lamina**: - **Odontogenic keratocyst, lateral periodontal cyst**.

Dentigerous cyst :-

An odontogenic cyst surrounds the **crown of an impacted tooth**, caused by fluid accumulation between the reduced enamel epithelium and the crown of an unerupted tooth, resulting in a cyst in which the crown is located within the lumen and roots outside.

Clinically:- also called follicular cysts, are slow-growing benign and non-inflammatory odontogenic cysts it is usually a **symptomatic** but produce some swelling or pain when become large or inflamed.Smaller dentigerous cysts might not cause any symptoms. However, if the cyst grows larger than 2 centimeters in diameter may produce:

- **swelling**
- **tooth sensitivity**
- **tooth displacement**



It is associated clinically with impacted tooth most commonly an unerupted 3rd molar (mandibular- more than maxilla), then maxillary canines, rarely involve impacted deciduous teeth.

Radiographically:-

It appears as well **circumscribed radiolucency surrounding the crown of an impacted tooth.**



Histopathology:-

The cystic cavity of dentigerous cyst is lined by uniform layer of stratified squamous epithelium about 2-6 cells in thickness with lose fibrous C.T. and infiltration of chronic inflammatory cells. Sometimes the cystic lining contains numerous **Goblet cells**, Goblet cells are unicellular intraepithelial **mucous-secreting cells** scattered within simple epithelia. Their role is to **protect the surface of epithelium, lubricate it, and catch harmful particles.**

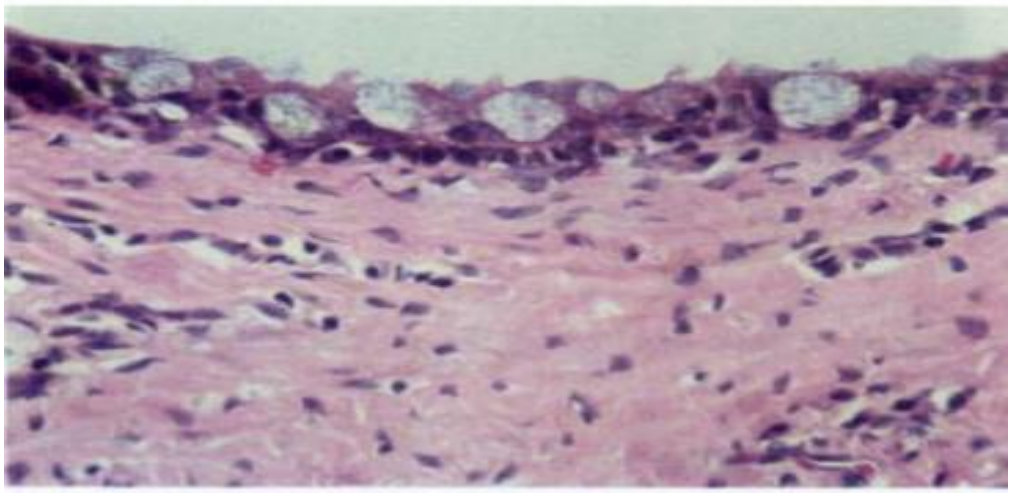

Treatment

Treating a dentigerous cyst depends on its size. If it's small, surgically removal of the cyst with the affected tooth. In other cases(large cysts), we use other technique

called **marsupialization**. Marsupialization involves cutting open in the cyst so it can drain. Once the fluid has drained, stitches are added to the edges of the incision to keep it open, and prevents cyst growing there.

When the cyst become small, surgical enucleation(removal) with the affected tooth will be done.

Eruption cyst (eruption hematoma) It is a **soft tissue** analogue of the dentigerous cyst, it is a **bluish swelling** that occurs on the soft tissue over an **erupting** tooth. It is usually found in children. An eruption cyst (eruption hematoma) is a developmental soft-tissue cyst of odontogenic origin that forms over an erupting tooth. Resulting from dilation of the follicular space around the crown of the erupting tooth, caused by the accumulation of fluid or blood. When the cystic cavity surrounding the crown of the tooth contains blood, the lesion is **called an eruption hematoma.**

Clinically • Soft fluctuant translucent swelling in the gingival mucosa overlying the crown of an erupting tooth .Common in children while rare in other ages and found in both dentition. • Forms superficially in the gingiva overlying the involved erupting tooth as **soft, rounded and bluish swelling.**



Radiographically

No x- ray picture. i.e soft tissue lesion.

Histopathology The epithelial lining of eruption cyst is similar to that of the dentigerous cyst (stratified squamous epithelium), so the eruption cyst is considered a **superficial dentigerous cyst.** The fibrous capsule shows inflammatory cells possibly as a result of trauma .The cystic cavity may contain blood in addition to the yellowish protein fluid as a result of trauma

Treatment

Not required, it ruptures spontaneously or sometime simple excision of cyst roof. The cyst roof may be drained with its fluid to allow the tooth to erupt although most of them burst spontaneously.

Odontogenic keratocyst :- is benign , locally aggressive developmental cyst. It most often affects the **posterior mandible** and most commonly presents in the third decade of life. Odontogenic keratocysts make up around 20% of jaw cysts.

Clinically :- Odontogenic keratocysts can occur at any age, however they are more common in the third decades. The male to female ratio is approximately 2:1. **The majority are found in the mandible(80%), with half occurring at the angle of the mandible.**

It grows in **anterio-posterior direction** within medullary cavity of the bone **without causing obvious bone expansion**.

This is useful to differentiate clinical and radiographic dentigerous and radicular cyst of similar size, which produce **bone expansion**.

Radiographically : Radiographs of odontogenic keratocysts show well-defined **radiolucent areas with rounded or scalloped margins** which are well demarcated.These areas can be **multilocular or unilocular**. The growth pattern of the lesion is very characteristic from which a diagnosis can be made as there is growth and spread both forward and backward along the medullary cavity with little expansion. **No resorption of teeth** or inferior dental canal and minimal displacement of teeth is seen**. Due to lack of expansion** of the odontogenic keratocyst, the lesion can be very large when radiographically discovered they can be seen as **unilocular or multilocular radiolucencies**. They can be mistaken for other cysts such as residual cysts or a dentigerous cyst if they occur over an unerupted tooth. Un erupted tooth is involved in the lesion in 25-40 % of cases.

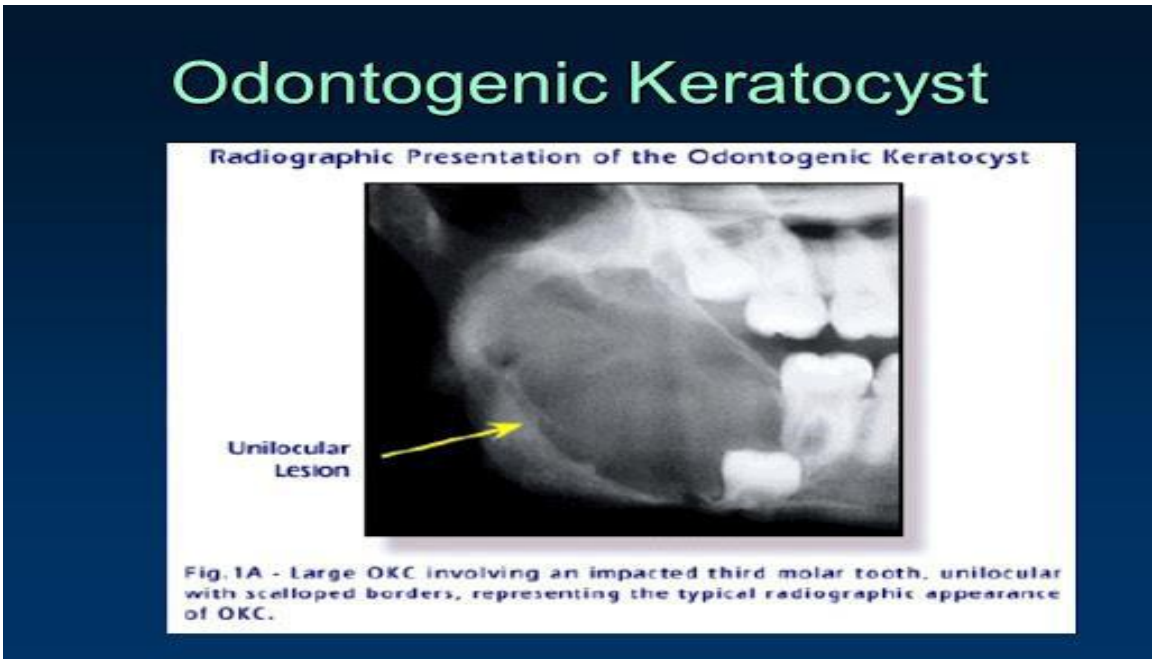

Histopathology

- Thin,Uniform epithelial lining 6 - 8 cells thickness.
- May have **artifactual clefting** between epithelium and underlying fibroconnective tissue.
- The C.T wall is often loose and free of chronic inflammatory cells ·
- **Daughter or satellite cysts (microcysts)** may present in the capsule wall**.**

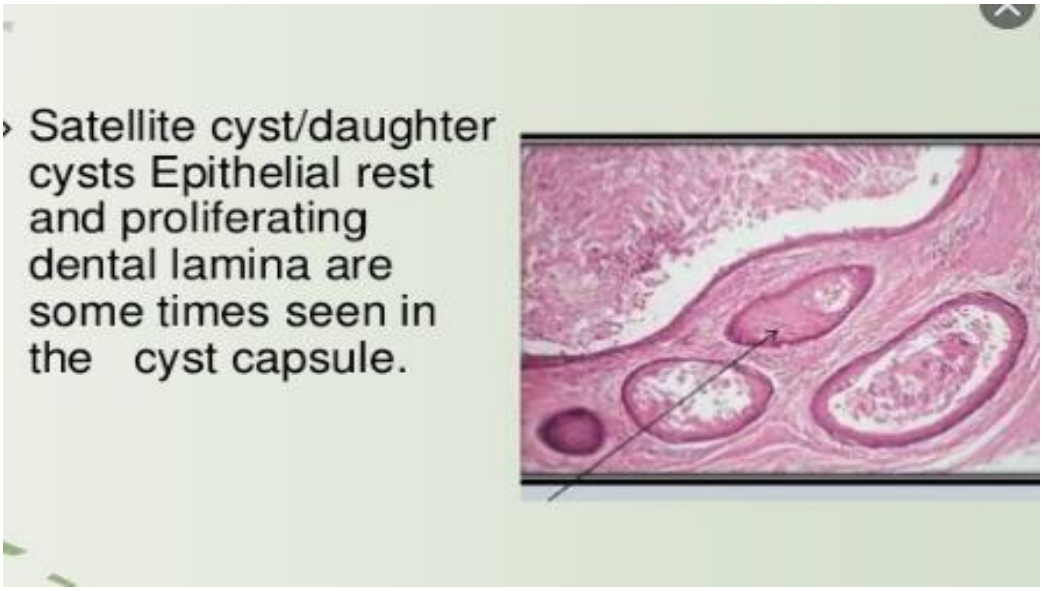

Treatment

Complete removal by **enucleation and curettage** it has tendency to **recur** because of friable nature of cyst wall that result in fragment or due to formation of new cysts from dental lamina (**daughter cysts**). **marsupialization has been ineffective** in reducing the size of the cyst.

Lateral periodontal cyst (LPC):-

Is an uncommon developmental odontogenic cyst located adjacent or lateral to the root of a **vital tooth**. Commonly reported in mandibular canine-premolar or maxillary anterior regions (between 2 and 3 teeth). They are commonly found along the lateral periodontium or within the bone (intraosseous) between the **roots of vital teeth**, around mandibular canines and premolars**.**

Clinically: Small, soft-tissue swelling found just below or within the interdental papilla. However, as it is usually **asymptomatic in nature**, LPCs are usually detected through radiography.



Radiographically: the LPC appears with a well-defined **round, oval** or sometimes tear-drop shape **radiolucency,** and enlargement of the periodontal ligament space**.**

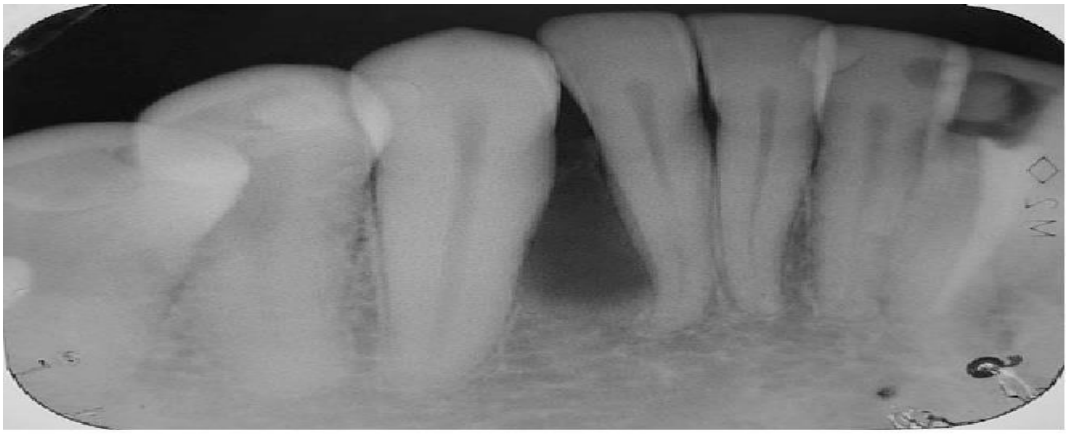

Histopathology: A cystic cavity with a thin layer of epithelium 1- 3 cells in thickness. In most cases no inflammatory cells are present ,but in some rare instances, inflammation in the fibrous capsule can be observed.

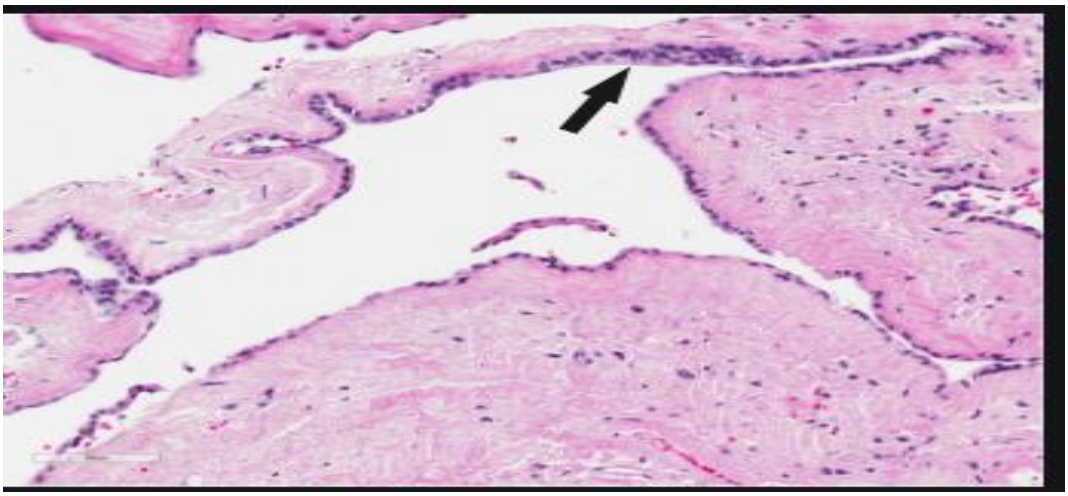

Treatment

Removed surgically by conservative enucleation or excision, and the patient should be followed radiographically for several years thereafter to monitor for recurrence.

Gingival cyst of the adult:-

It is considered the **extra-osseous form of lateral Period .cyst**. It is uncommon lesion. It occurs mostly in mandibular canine- premolar area about 60 -75 %, on facial gingiva or alveolar mucosa. It appears as small **painless swelling bluish – gray in color.**



Radiology

No radiographic picture.

Histopathology:- Resemble lateral periodontal cyst.
Treatment :- conservative surgical enucleation**.**

Gingival (alveolar) cysts of New-born (Infants)

Also known as dental lamina cysts or alveolar cysts, gingival cysts may occur in newborns **, they are true cysts** as they lined by thin epithelium and shows a lumen**.** They are formed from fragments of **dental lamina** that remains within the alveolar ridge mucosa during tooth formation (odontogenesis)**.**

Clinical presentation

In the newborn gingival cysts usually present as white to yellowish small round oval nodules of 2-3mm size in the alveolar ridge of the jawbones. They disappear spontaneously after weeks to a few months. Gingival cysts are extraosseous and more often found in the gingiva of the mandible than the maxilla.

Radiology : Since they are extraosseous cysts they do not show any radiographical appearance.



Histopathology

Histologically: gingival cysts are similar to lateral periodontal cysts

- Fibrous capsule with minimal inflammatory cells
- Double-layered odontogenic epithelial lining consisting of cuboidal and squamous cells.

Treatment

No treatment, in the newborn, they involute or rupture into the oral cavity .

Calcifying odotogenic cyst(COC)

Is a rare developmental lesion that comes from odontogenic epithelium.

Signs and symptoms

Most calcifying odontogenic cysts appear **asymptomatic**. They are normally presented as a **painless**, slow-growing mass on the mandible and/or the maxilla, mostly in the front of the mouth. Symptoms include swelling in the mouth, both inside the bone, in the tooth bearing areas, and outside the bone, in the gingiva. When a COC is located in the maxilla, individuals might complain of nasal stiffness, epistaxis, and headache. Sometimes it is associated with **impacted or unerupted teeth.**



Figure 3: Swelling obliterating buccal vestibule

Radiographic features

These calcifying odontogenic cysts are usually discovered using dental radiographs. They will appear as **unilocular** (one chamber), **multilocular** (multiple chambers) or **mixed radiolucencies** with some **radiopaque deposits of differing sizes and opacities**. Irregular calcifications may be seen in some cases. They are often located in a periapical or lateral periodontal relationship to adjacent teeth.

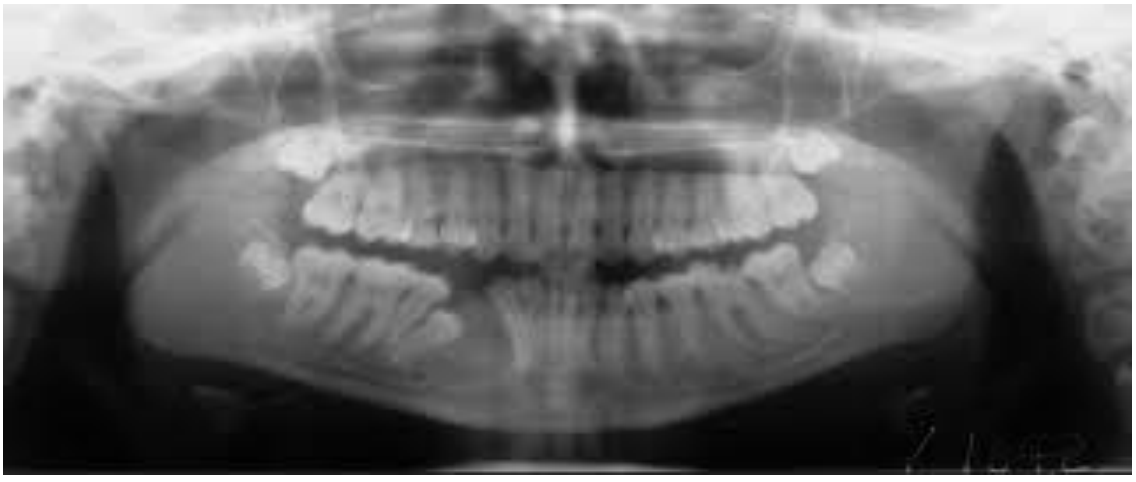

Histology

In general, the epithelium seen is of stratified squamous type and is 5–8 cells thick. Additionally, focal areas of stellate reticulum like cells are seen and near the basement membrane ameloblast-like cells may be seen.

Each type of calcifying odontogenic cyst shows special features of which there are three types:

1)Type A. **Ghost cells** and dentinoid are seen.

2)Type B. Formation of calcified tissues in the lumen of the cyst wall showing **dystrophic calcification**.

3)Type C. **Ameloblast-like proliferation** in the connective tissue and lumen of the cyst may be seen.

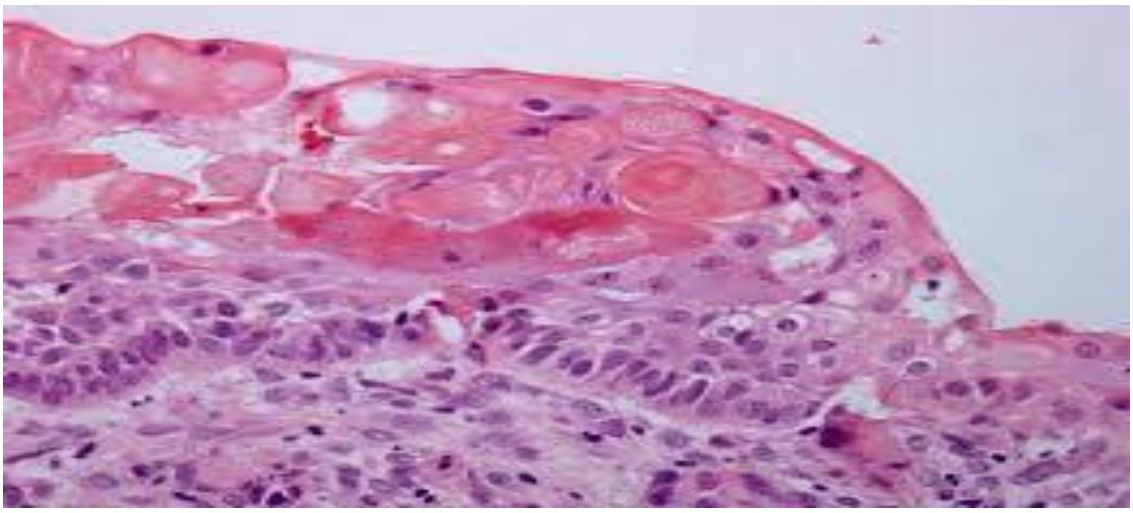

Treatment

The standard treatment of calcifying odontogenic cyst is **enucleation and curettage**, Recurrence following enucleation and curretage is rare.

Residual cysts : Residual cysts are **relatively rare inflammatory cysts of the jaws**. They are essentially radicular cysts without complete removal. These lesions have the ability to destroy bone within the jaws without any symptoms**.**

Clinical features

- Variable: range from asymptomatic and only incidentally detected on imaging, to expansion of affected jaw region, to pain and drainage

Radiology

Round to oval radiolucency of variable size within the tooth bearing regions of jaws at the site of a previous tooth extraction.

Residual Cysts

- It is a radicular cyst remaining after the tooth has been extracted.
- Usually asymptomatic. Usually small size (less than 1 cm in diameter).
- Unilocular, round or oval, well-defined, usually well-corticated.
- It can cause bone expansion and displacement of the adjacent teeth.

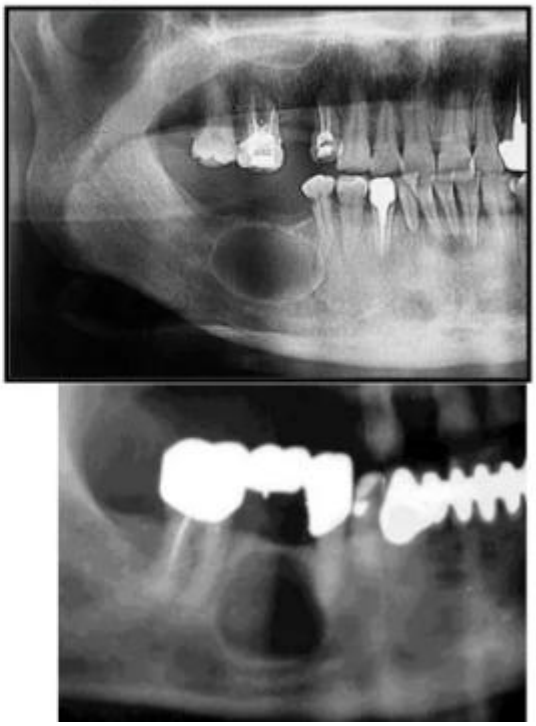

Histopathology: Resembles the radicular cysts**.**

Treatment: should be excised surgically, even in the absence of symptoms .Residual cysts do not recur after appropriate management