Arrangement of the artificial teeth

It's the placement of the teeth on a denture with definite objective in mind or it's the setting of teeth on temporary bases.

Rules of artificial teeth arrangement:

Maxillary cast

1- A line is drawn parallel to the frontal plane that touches the anterior margin of the incisive papilla aids in the positioning of the upper central incisors.

2- The midline follows the mid palatal suture and bisects the incisive papilla this line is perpendicular to line 1.

3- The canine eminence line is recorded on the cast when it's present.

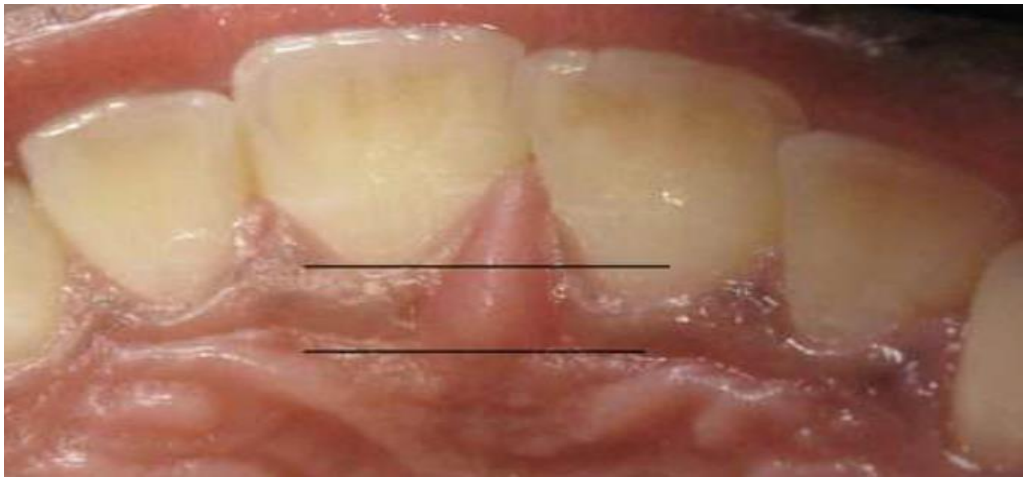

Mandibular cast

1- A line is drawn parallel to the frontal plane bisecting the residual ridge aids in positioning of the mandibular central incisors.

2- A point designates the distal of the mandibular canine

3- A line follows the crest of the residual ridge from the canine point to the middle of the retromolar pad aids in the buccolingual position of the mandibular posterior teeth.

4- A line that bisects the vertical height of the retromolar pad aids in establishing the vertical position of the occlusal surfaces of the posterior teeth.



Arrangement of anterior teeth

The anterior teeth should be arranged to provide:

1- Proper lip support.

2- Permit satisfactory phonetic.

3- Pleasing esthetic.

A. arrangement of the upper anterior teeth

1- Upper central incisor

- *In the frontal view:* the contact points between right and left central incisors should coincide with the midline of the cast. The incisal edge of each one should touch the occlusal plane. The long axis is perpendicular to the plane.
- *In the sagittal view*: should have slight labial inclination (5 degree)
- *In the occlusal plane (horizontal):* the two central incisors should be placed to give the beginning of the curvature of the arch. Generally, the labial surfaces of the two central incisors will be 8-10 mm anterior to the center of incisive papilla.

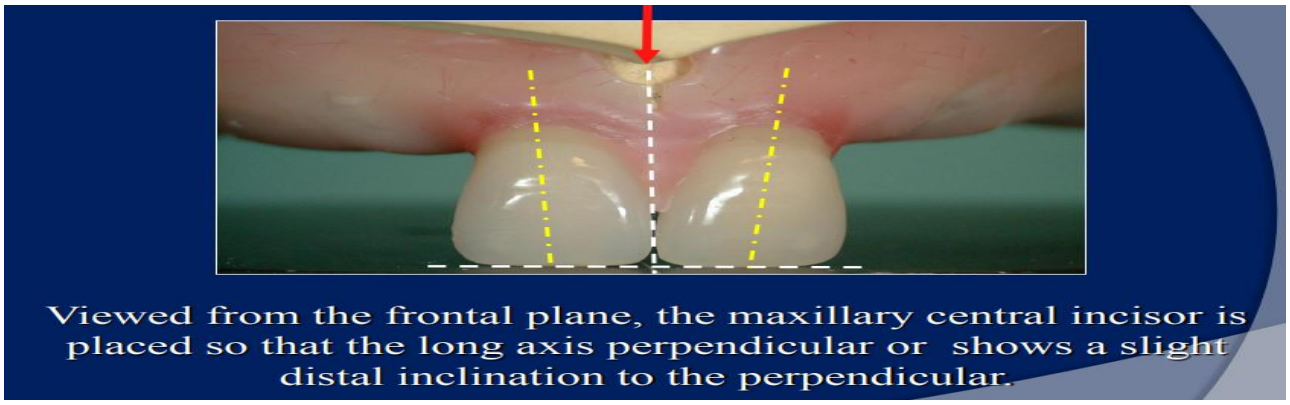

2- Upper lateral incisor

- *In frontal view:* the incisal edge is 1 mm above the occlusal plane and the long axis show little distal inclination.
- *In the sagittal view:* the upper lateral incisor should have slight labial inclination (10 degree).
- *In the horizontal view:* the cervical area is depressed more than the central incisors and the distal edge should be rotated to form the arch curvature.

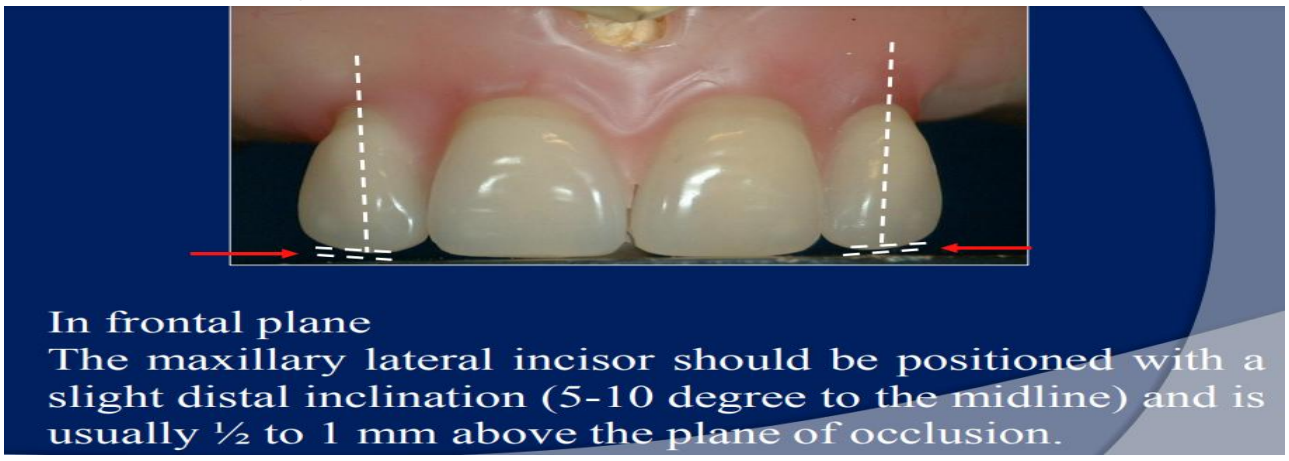

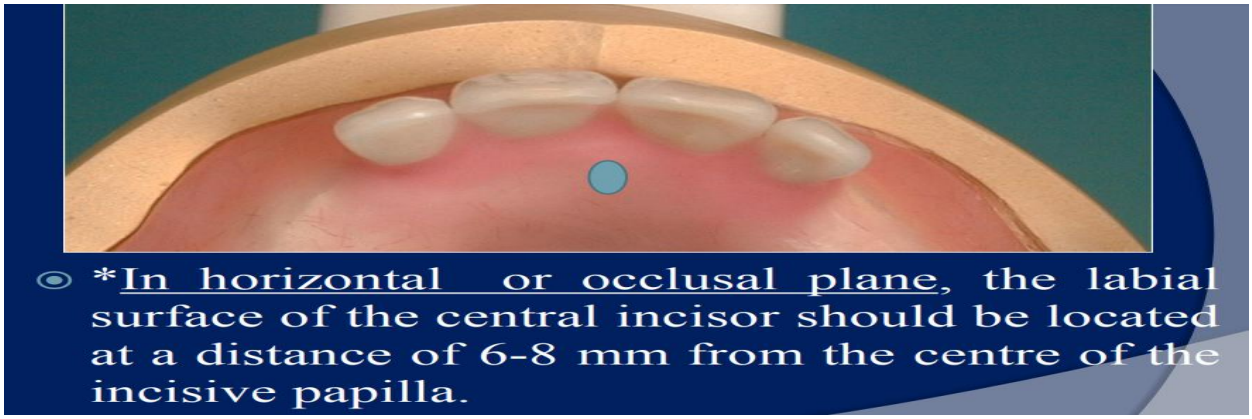

3- Upper canine

- *In frontal view:* the tip of the canine should touch the occlusal plane and the long axis is perpendicular to the plane.
- *In the sagittal view:* the long axis is vertical.
- *In the horizontal view:* The upper canine represents the upper corner of the mouth and the turning point of upper arch also it forms the transition from the anterior teeth to posterior teeth.

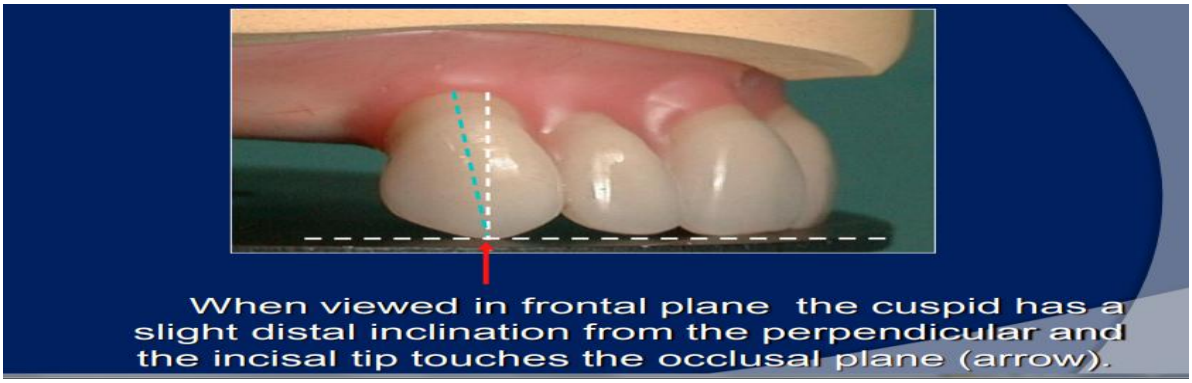



B. Arrangement of the lower anterior teeth

1- Lower central incisor

- *In frontal view:* the long axis is vertical and the midline of the lower centrals should coincide with the maxillary mid line.
- *In sagittal view:* should have slight labial inclination. The incisal edge should have

1 mm of vertical overlap (overbite) and 1mm of horizontal overlap (overjet) in respect to maxillary central incisor.

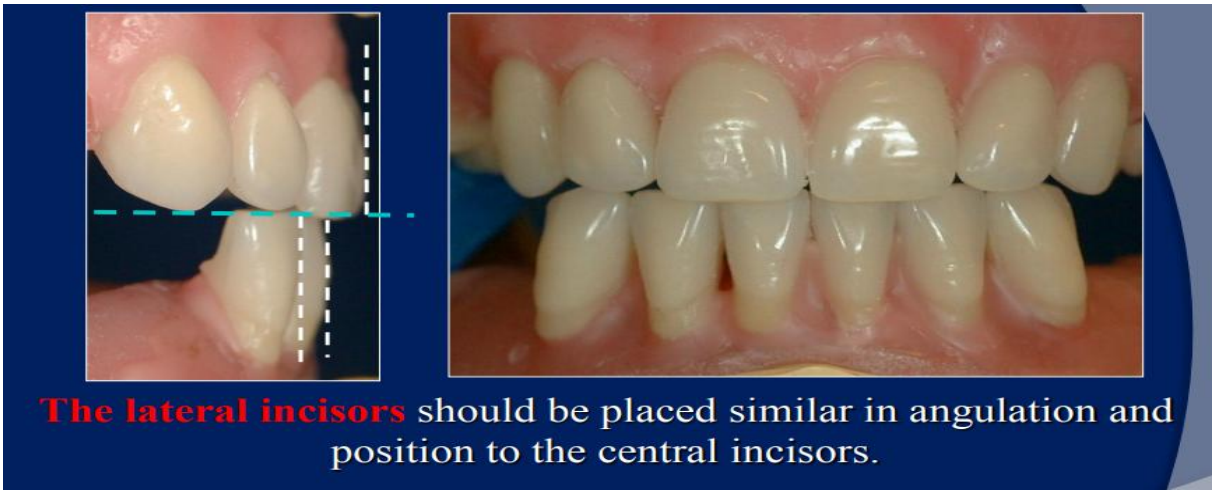

***Overbite (vertical overlap)**

It is the extension of the upper anterior teeth over the lower teeth in a vertical directionwhen the opposing posterior teeth are in contact in centric occlusion.

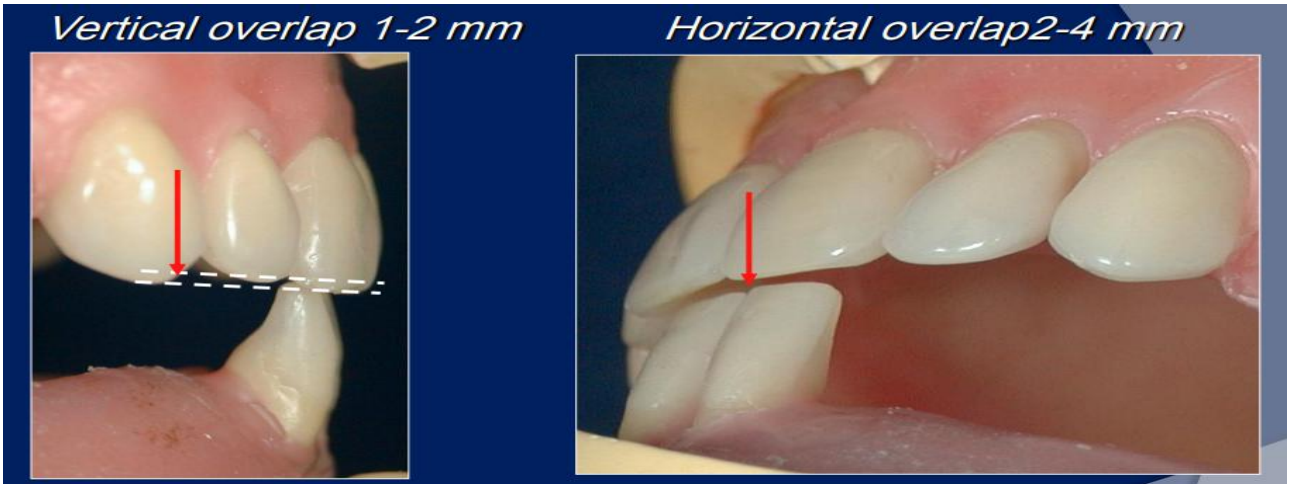

***Overjet (horizontal overlap)**

It is the projection of upper anterior teeth beyond their antagonists in a horizontaldirection.

2- Lower lateral incisor

- *In frontal view:* the long axis has slight distal inclination to the occlusal plane
- *In sagittal view:* is fairly upright and the incisal edge should be 1 mm of horizontal and vertical overlap in respect to central incisor.
- *In horizontal view:* the distal edge rotated lingually to have the arch curvature

3- Lower canine

- *In frontal view:* the long axis has slight distal inclination and the tip of lower canine should be placed in the embrasure between upper lateral and upper canine.
- *In sagittal view:* the long axis has slight lingual inclination.
- *In horizontal view:* the cervical area is prominent.

The arrangement of anterior teeth should follow the form of the arch which is either square, tapered or ovoid.

