Odontogenic Tumors Of The Jaws

Odontogenic tumors are derived from the epithelial and/or mesenchymal remnants of the tooth-forming apparatus. Therefore, they are found exclusively in the mandible and maxilla (and occasionally in the gingiva). The origin and pathogenesis of this group of lesions are unknown. Clinically, odontogenic tumors are typically asymptomatic, although they may cause jaw expansion, movement of teeth, root resorption, and bone loss.

AMELOBLASTOMA

The ameloblastoma is the most common clinically significant odontogenic tumor. Ameloblastomas are tumors of odontogenic epithelial origin. Theoretically they may arise from **rests of dental lamina** from a developing enamel organ, **from the epithelial lining of an odontogenic cyst**, or from the **basal cells of the oral mucosa**. Ameloblastomaare slow-growing locally invasive tumors that run a benign course in most cases.They occur in three different clinicoradiographic situations which deserve separateconsideration because of differing therapeutic considerations and prognosis.

Types of Ameloblastoma :

Ameloblastoma classified into three groups including:

Solid or multicystic , unicystic, and peripheral.

1- Conventional solid or Multicystic Intraosseous Ameloblastoma

Clinically: is the most clinically significant benign odontogentic tumor, mostly occurs in patients over the age of 30 years old, there is no significant gender predilection. About 85% of multicystic ameloblastomas occur in the **mandible,** most often in the **molars and ascending ramus area**. About 15% of ameloblastomas occur in the maxilla, usually in the posterior regions. The tumor is often **asymptomatic**, and smaller lesions are detected only during a radiographic examination. **A painless swelling or expansion of the jaw is the usual clinical presentation**. If untreated. The lesion may grow slowly to massive tumor. **Pain and paresthesia are uncommon**, even with large tumors.

Radiographic Feature

The most typical radiographic feature is that of a multilocular radiolucent lesion. The lesion is often described as having a"**honey combed**" appearance when the radiolucentloculations are large and as being "**soap bubble**" when the loculations are small. Buccal and lingual cortical expansion is frequently present. **Resorption of the roots** of teeth adjacent to the tumor is common. In many cases, an **unerupted tooth**, most often a mandibular third molar is associated with the radiolucent defect.

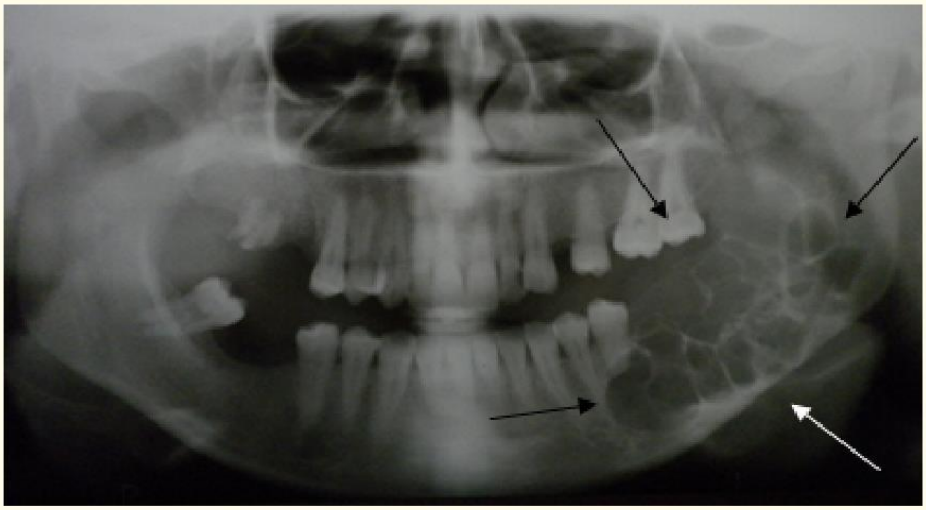

Figure 2: *Dental panoramic X-ray: appearance in "soap bubbles" of a multicystic ameloblastom*

Histopathological feature

The solid/multicystic ameloblastoma can histopathologically be divided into **follicular and a plexiform type (most common),** and Less common histopathologic patterns include the **acanthomatous**, **granular cell, desmoplastic, and basal cell types.**

Follicular pattern The follicular histopathologic pattern is the most common and recognizable. Islands of epithelium resemble **enamel organ epithelium** in a mature fibrous connective tissue stroma. The epithelial nests consist of a core of loosely arranged angular cells **resembling the stellate reticulum** of an enamel organ. A single layer of tall columnar **ameloblast-like cells surrounds this central core.** Cyst formation is common and may vary from microcysts. Which form within the epithelial islands, to large macroscopic cysts, may be several centimeters in diameter.

Plexiform pattern. The plexiform type of ameloblastoma consists of long, anastomosing cords or larger sheets of odontogenic epithelium. The cords or sheets of epithelium are bounded by **Ameloblast-like cells** surrounding more loosely arranged epithelial cells. The supporting stroma tends to be loosely arranged and vascular.

Cyst formation is relatively uncomm on in this variety.

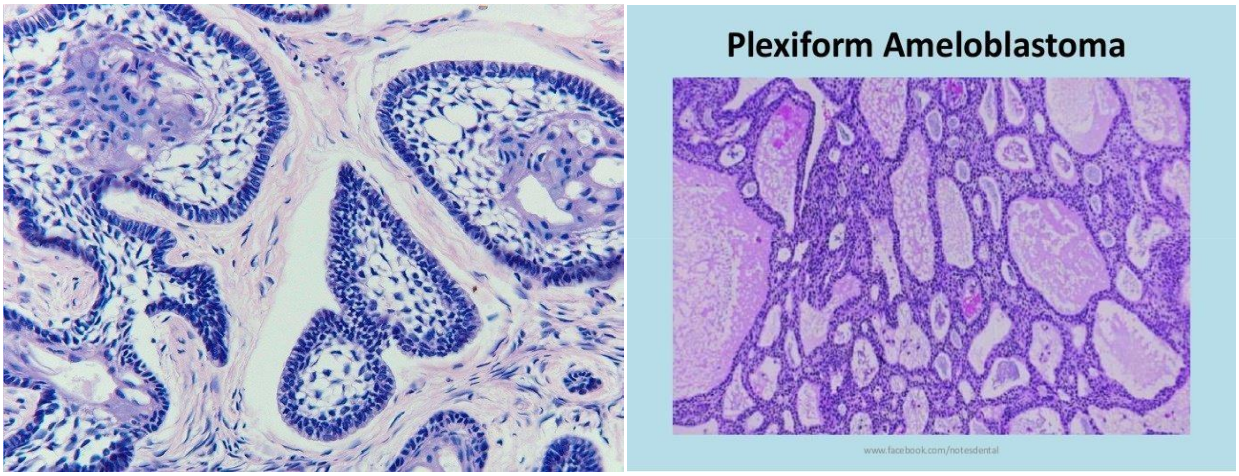

follicular ameloblastoma

Treatment and Prognosis. Patients with conventional solid or multicystic intraosseous ameloblastomas have been treated by a variety of means. These range from simple **enucleation and curettage to *enbloc* resection** . Attempts to remove the tumor by curettage often leave small islands of tumor within the bone, which later manifest as recurrences. Recurrence rates of 50% to 90% have been reported in various studies after curettage, Ameloblastomas of the posterior maxilla are particularly dangerous because of the difficulty of obtaining an adequate surgical margin around the tumor.

2- Unicystic Ameloblastoma

Clinically : More than 90% of unicystic ameloblastomas are found in the mandible, usually in the posterior regions. The lesion is often a **symptomatic**, although large lesions may cause a **painless swelling of the jaws** (slow-growing and relatively locally aggressive cystic lesion).

Radiographical Feature

Typically appears as a **unilocular radiolucency**, Approximately 50–80% of cases are associated with **an impacted or unerupted tooth**. Therefore, the clinical and Radiographic presentations of unicystic ameloblasto are sometimes **indistinguishable** from those of **dentigerous cysts** . In many patients, this lesion typically appears as a circumscribed radiolucency that surrounds the crown of an **unerupted mandibular third molar**, clinically resembling a **dentirogeus cyst**. Other tumors simply appear as sharply defined radiolucent areas and are usually considered to be a **radicular, or residual cyst,** depending on the relationship of the lesion to teeth in the area. In some instances, the radiolucent area may have scalloped margins but is still a unicystic ameloblastoma.

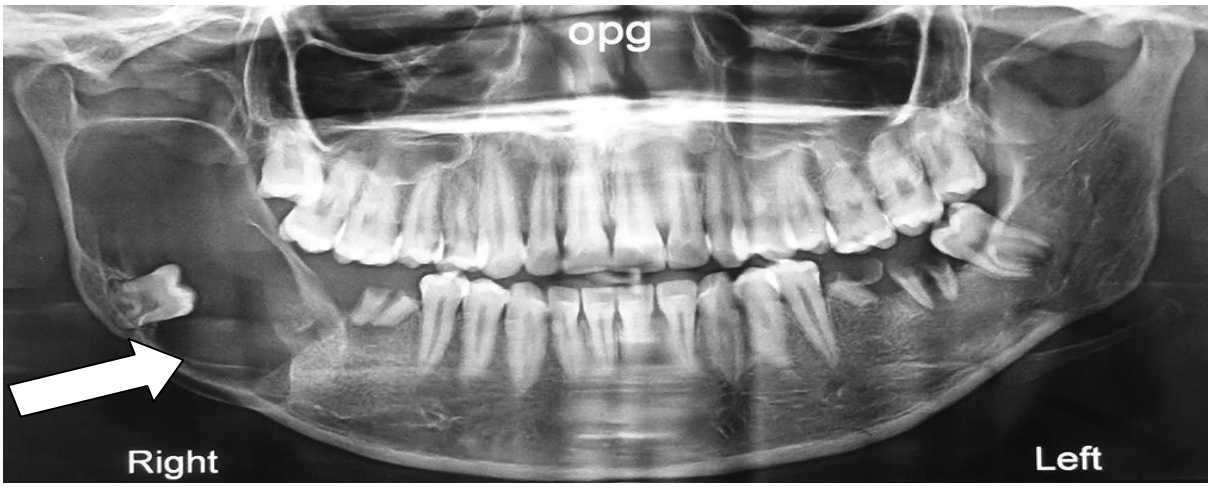

Histopathological features

Single cystic lesion lined by columnar ameloblastic epithelium,with supra-basal cells loosely arranged and resembles **satellite reticulum**.

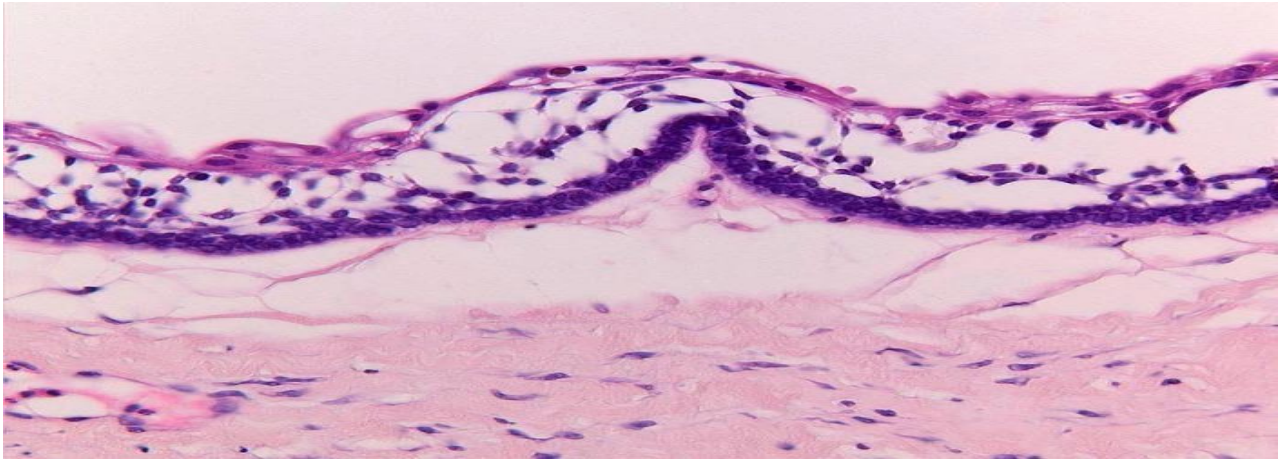

Treatment : Unicystic ameloblastomas may be treated less aggressively **,** ranging from **enucleation with curettage to resection** depending on the size of the tumor.

3- Peripheral (extraosseous) Ameloblastoma

Clinical Features

The peripheral ameloblastoma is uncommon and accounts for about 1 % of all ameloblastomas**.**it is usually a **painless , non ulcerated gingival lesion,** Most examples are smaller than 1.5 cm but larger lesions have been reported. commonly found on the posterior gingival and alveolar mucosa and they are somewhat more common in mandibular than in maxillary areas**.** This tumor probably arises from **rests of dental lamina** beneath the oral mucosa or from the basal epithelial cells of the surface epithelium.

Hislopathologic Features : Peripheral ameloblastomas have islands of epithelial tumor cells with ameloblastic feature **,** the features are the same described for the **intraosseous ameloblastoma; plexiform or follicular patterns.**

Treatment :The surgical treatment of choice for **PA** consists in conservative local excision without removing bone or teeth.

Adenomatoid odontogenic tumor

Adenomatoid odontogenic tumor (AOT) was formerly termed *adenoameloblastoma* because it was believed to be a subtype of ameloblastoma that contains duct like or gland like structures**,** Clinically, microscopically, and behaviorally, it is clearly **different from ameloblastoma**, and the term ***adenoameloblastoma*** **is not used**.

Clinical Features. AOTs lesions are often appear in the **anterior portion of the jaws**, more often in the **anterior maxilla**, generally in association with the **crowns of impacted teeth**. Three variants of this tumor have been identified: **follicular** (73% of cases), **extrafollicular** (24%), and **peripheral** (3%).

Radiographically, the **follicular AOT** is a well-circumscribed **unilocular lesion** that usually appears around the **crown of an impacted tooth**; the extrafollicular type usually presents as a well-defined unilocular radiolucency **above, between**, or **superimposed over the roots of an unerupted tooth**. When they are located between anterior teeth, divergence of roots may be seen. The peripheral type is characterized by **a painless, nontender gingival swelling**.

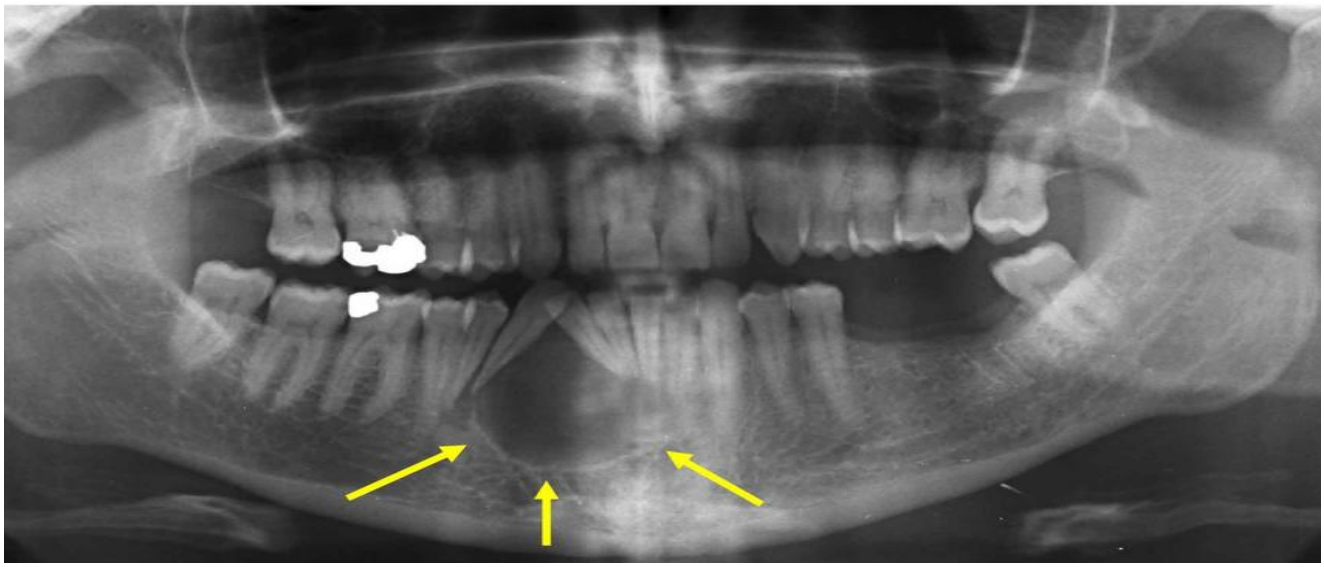

Histopathology. An intracystic epithelial proliferation is composed of **polyhedral to spindle cells**. **duct like structures of columnar epithelial cells give the lesion its characteristic microscopic features**.

Treatment. Conservative treatment (enucleation) is all that is required. AOTs are benign, encapsulated lesions that do not recur.

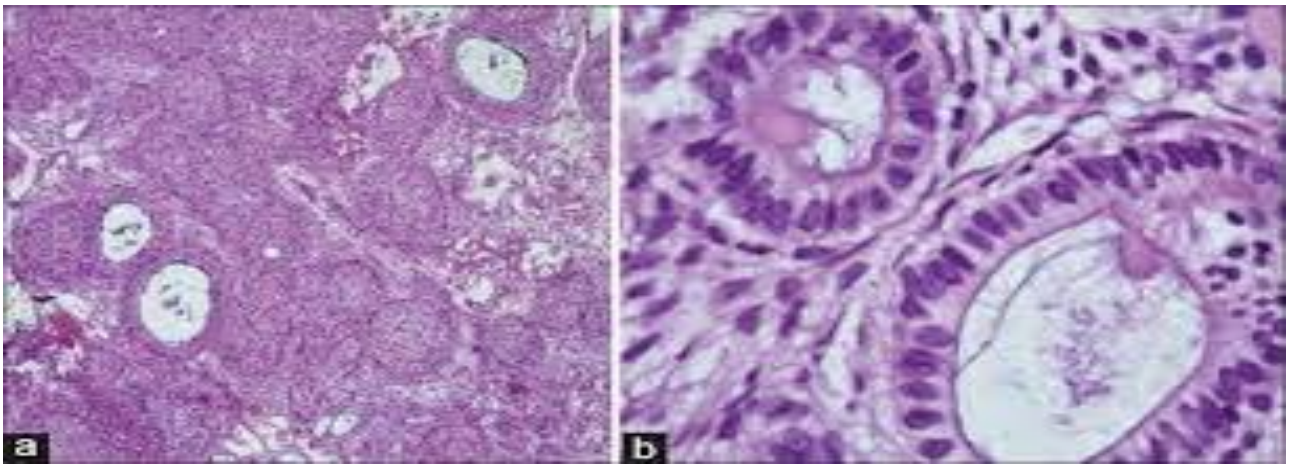

Calcifying epithelial odontogenic tumor (pindborg tumor)

Calcifying epithelial odontogenic tumor (CEOT), also known as ***Pindborg tumor*** after the oral pathologist who first described the entity, is a benign tumor of odontogenic origin that shares many clinical features with ameloblastoma**.**

***Clinical Features*:.** These tumors tend to be **slow-growing, locally invasive,painless masses involving the posterior portion of jaws**.The mandible is affected twice the maxilla**,with Jaw expansion.**

Radiographically:. , the lesions are often associated with **impacted teeth**. The lesions may be **unilocular or multilocular**. Small loculations in some lesions have prompted use of the term ***honeycomb*** to describe this lucent pattern. A CEOT may be completely **radiolucent, or it may contain opaque foci.**



Histopathology:. Large polygonal epithelial cells, arranged in sheets or islands**,** Other **characteristic findings** are the presence of eosinophilic **Amyloid-like substances** and **concentric calcified** areas**.**
Treatment. Various forms of surgery, ranging from enucleation to resection, have been used to treat CEOTs. The overall recurrence rate has been less than 20%.

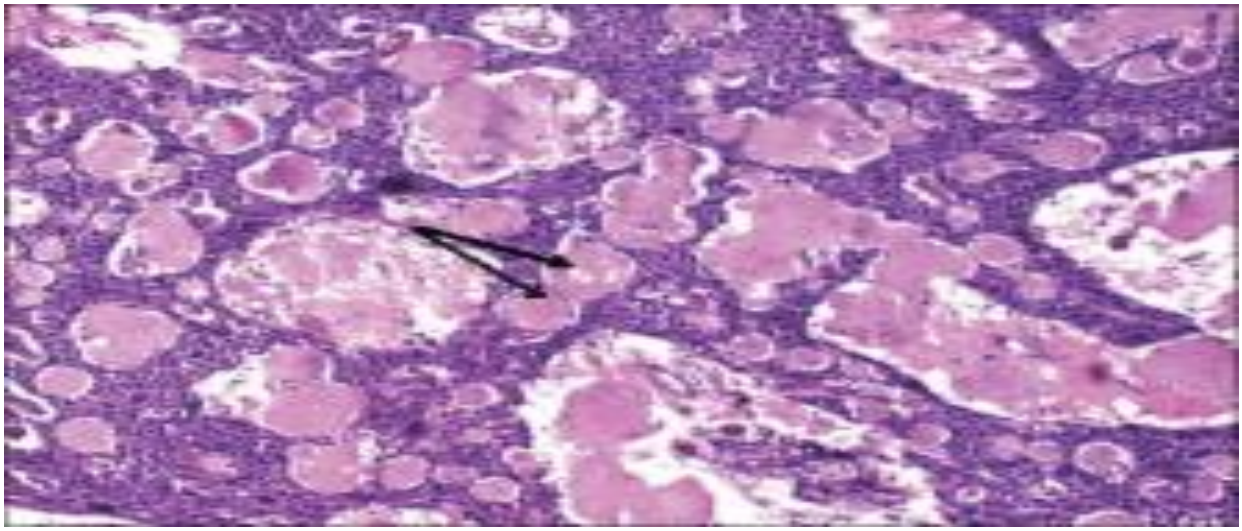

Odontoma ; is a benign tumour linked to tooth development, it is a dental hamartoma, meaning that it is composed of normal dental tissue that has grown in an irregular way, It includes both odontogenic hard and soft tissues, The average age of people found with an odontoma is 14 years old . The condition is frequently associated with one or more unerupted teeth and is often detected through failure of teeth to erupt at the expected time.

Types : There are two main types: **compound and complex**

Compound odontoma : consists of the four separate dental tissues (enamel, dentine, cementum and pulp) embedded in fibrous connective tissue and surrounded by a fibrous capsule. Compound odontomas are usually found in the **anterior maxilla** and are less than 20mm in diameter.

Complex odontoma : is unrecognizable as dental hard and soft tissues, usually

presenting as a radioopaque area with varying densities indicating presence of enamel. It generally appears in **the posterior mandible** and can grow to be several centimetres in size.

Clinical Feature

Odontomas usually asymptomatic and present as chance radiographic finding, often during childhood and adolescence when teeth do not erupt within the expected timeframe.

Occasionally odontomas can erupt into the mouth and this can lead to acute infections resembling a dental abscess.

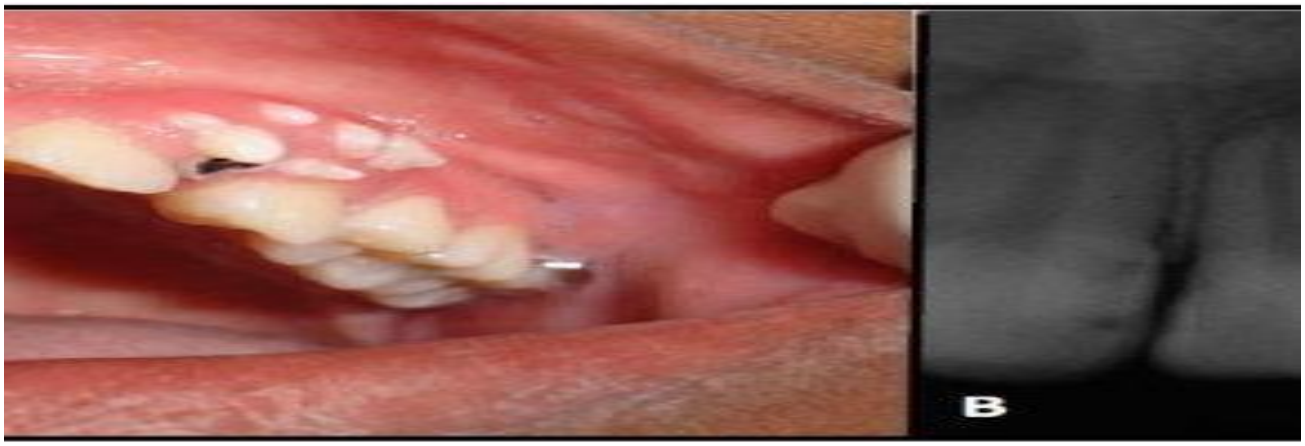

Radiographical Feature

compound odontomas : typically appear as **numerous tiny teeth**in a tooth-bearing area, between roots or over the crown of an impacted tooth. **Complex odontomas** appear in the same regions as **amorphous, opaque masses**

During the early stage of odontoma development**; radiolucen**t. At a later stage of development a dense **radioopaqu**e mass becomes visible as enamel and dentine forms.



complex odontoma



compound odontoma

Histopatology

Compound odontoma : are characterized by presence of dental tissue, demineralized enamel, dentin, cement and pulp, arranged in an **organized manner** of dental structures and partially surrounded by a connective tissue capsule.

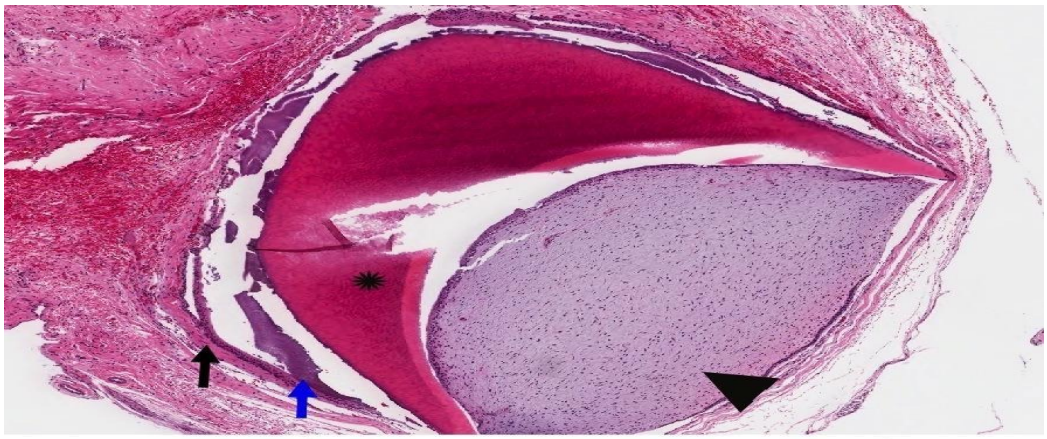

Higher magnification of compound odontoma. Follicular epithelium (black arrow), enamel matrix (blue arrow), mineralized dentin (star), dental pulp (arrowhead), 30x

Complex odontoma : exhibit a **disorganized mass** of hard dental tissue resembling the Dentine-like materials or the cementum .

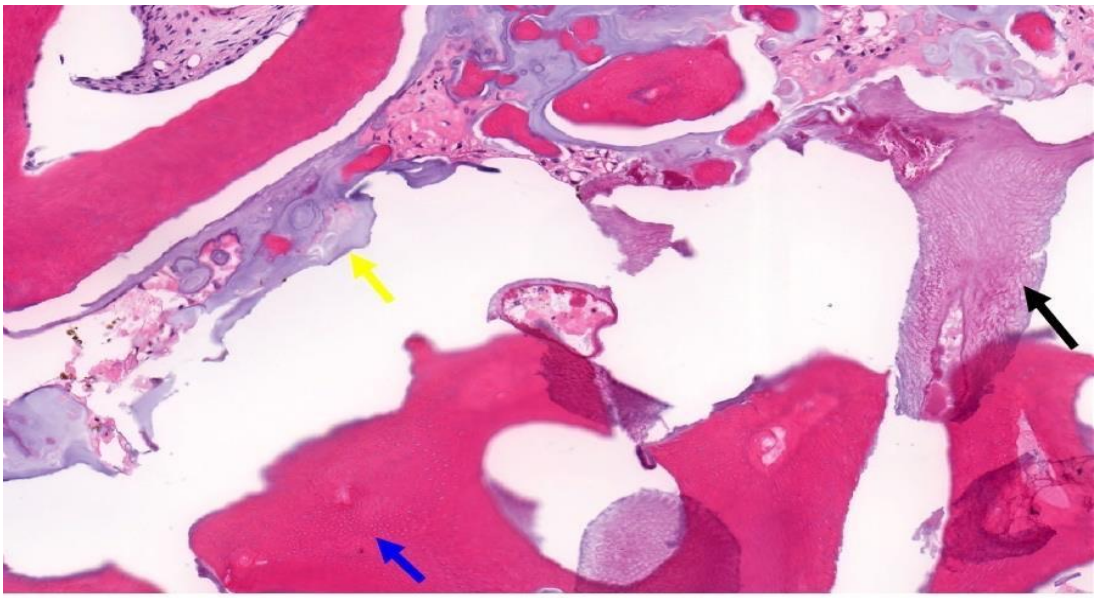

Elements of complex odontoma: enameloid matix (yellow arrow), dentin (blue arrow) and enamel (black arrow), 110x

Treatment

Treatment of choice consists in conservative surgical enucleation by means of the removal of the conjunctive tissue capsule that surrounds it.