Arrangement of posterior teeth

Maxillary posterior teeth arrangement

Maxillary first premolar: The facial surface of the maxillary first premolar must harmonize with the canine. The long axis of the premolar should be perpendicular to the occlusal plane and the **buccal and lingual cusp tips should touch the occlusal plane**.Its lingual cusp tip should contact the line inscribed on the lower occlusion rim indicating the crest of the lower residual ridge.

The same thing is done to maxillary second premolar.

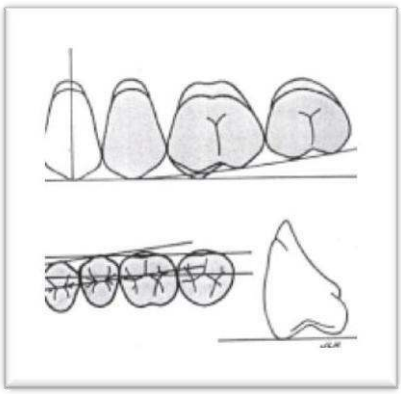

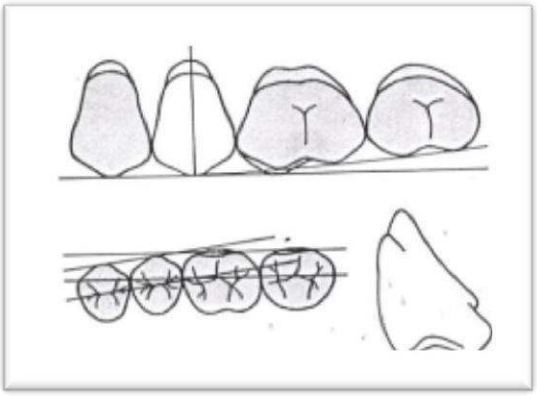



Maxillary first molar: **the mesio-lingual cusp tip of the 1st molar contacts the occlusal plane but the buccal cusps tips and the distolingual cusp tip are elevated about 0.5mm of the occlusal plane**, and the lingual cusps are over the crest of the mandibularridge. **The compensatory curve of Wilson and the compensatory curve of Spee begin at the 1st molar.**



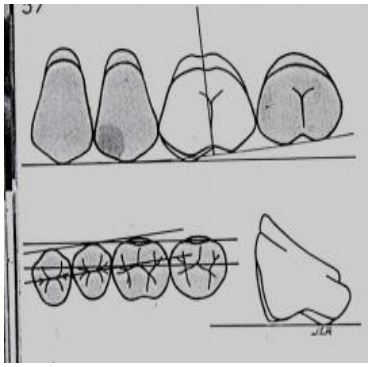

***Compensating curve:** is the anterio-posterior curvature of the occlusal surface of a complete denture teeth (in sagittal plane) and the mediolateral curvature in the frontal plane. The compensating curves are called so because they compensate for that present in natural dentition. Compensating curves may be increased or decreased in an artificial dentition to help achievement of balanced occlusion.

***Compensating curve for curve of Spee:** **is the curvature of the occlusal alignment ofthe teeth. It begins at the tip of the lower canine follows the buccal cusps of the premolars and molars and continues to the anterior border of the mandibular ramus**.

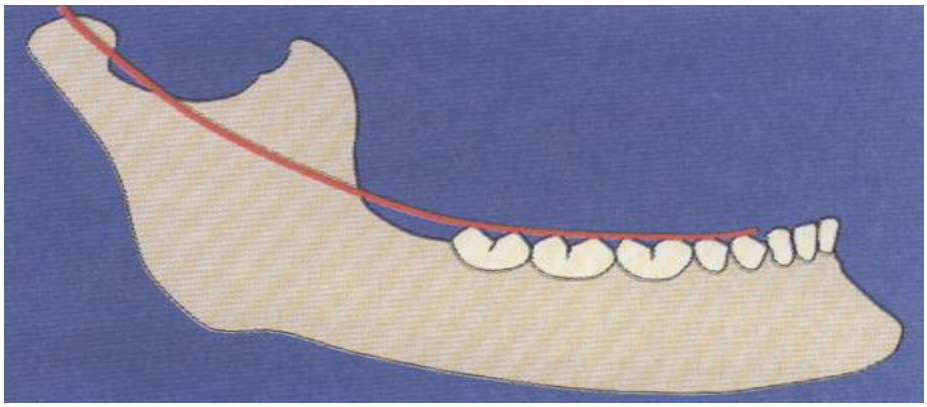

***Compensating curve for curve of Wilson:** **is the curvature in the frontal plane through the cusp tips of both the right and left molars.**

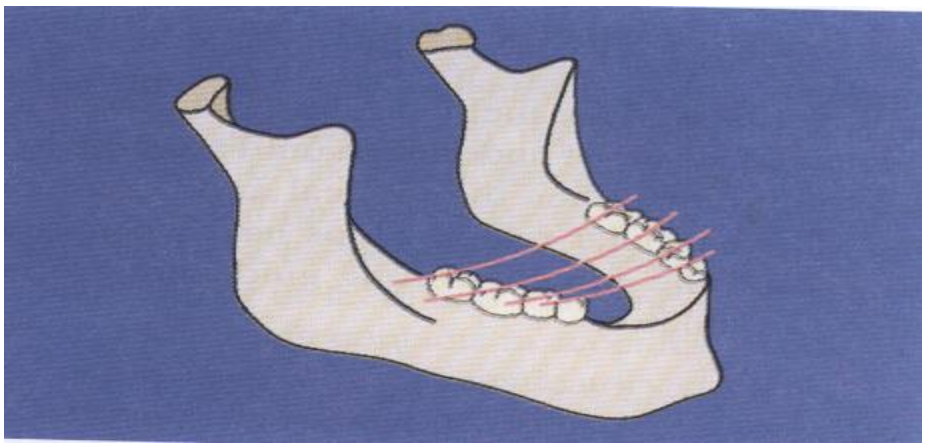

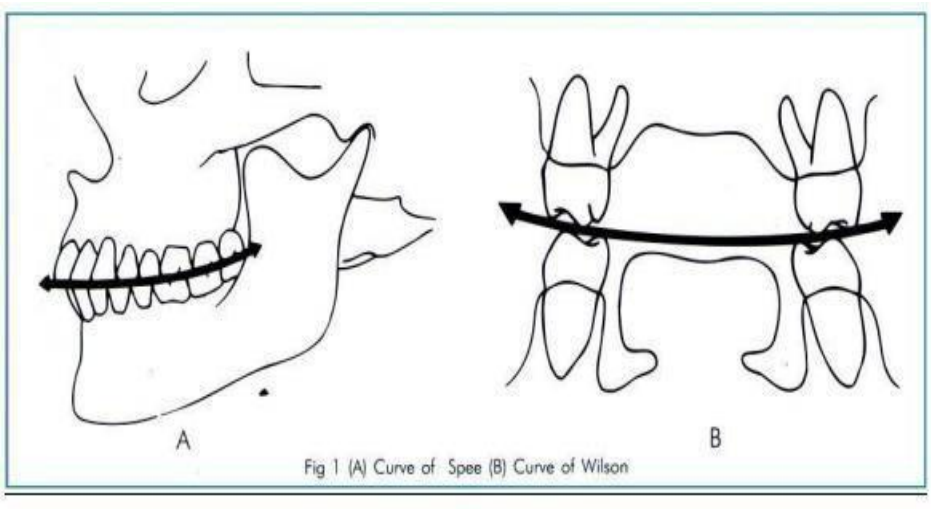

Fig 1 (A) Curve of Spee (B) Curve of Wilson

Maxillary second molar, the compensatory curve is continued by **elevating the 2nd molar above the plane of occlusion**. The 2nd molar is elevated to an even greater degree than the 1st molar, **about 15 degrees in the average patient, with a slight curveof Wilson.**



Mandibular posterior teeth arrangement

In which, their central fossa must coincide or placed over the crest of the lower residual ridge.

Mandibular first molar: is **first tooth set into centric occlusion** and checked carefully. **Its mesiobuccal cusp tip should engage the embrasure between the maxillary 1st molar and maxillary 2nd premolar**. Check the relationship from the lingual side. Make sure that the mesiolingual cusp of upper 1st molar engages the central fossa of the mandibular first molar & **mesiobuccal cusp of upper 1st molar should engage buccal groove of lower 1st molar.**



Mandibular second premolar: its buccal cusp should occlude with the adjacent marginal ridges of the maxillary 1st and 2nd premolars.

Mandibular first premolar: its buccal cusp should engage the mesial marginal ridge of the opposing 1st premolar.

Mandibular second molar: make sure that the lingual cusp of the maxillary 2nd molar properly occludes with the central fossa of the mandibular 2nd molar.



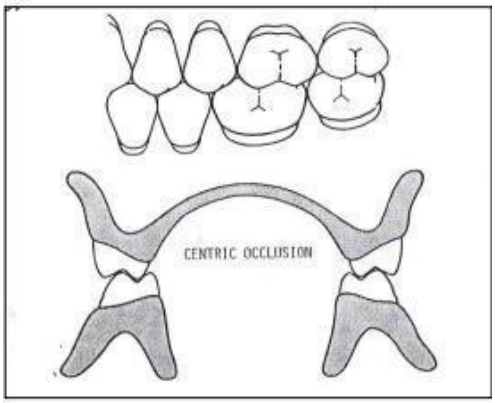

Keys of Occlusion

A- Canine Key of occlusion: **The distal of the lower canine should align with the mesial arm of the upper canine.**

B- Molar Key of occlusion :-The mesio-buccal cusp of the maxillary molars coincides with the mesio-buccal groove (buccal groove) of the mandibular molars .



C- Neutral zone

Tooth should be arranged in the neutral zone where the forces of the buccal musculature are compensated by the lingual musculature.

