Oral mucosal lesions and infections

The oral cavity is lined by a membrane composed of stratified squamous epithelium. This epithelium serves as a cover for the oral soft tissues as a barrier to the entry of external pathogenic factors.

In general, oral mucosal lesions could be divided into:

- Oral infections: Fungal, Bacterial and Viral.
- Vesiculobullous diseases.
- Ulcerative conditions.
- White lesions.

To better describe the appearances of lesions and communicate these features to others, the clinician should be familiar with the following terms:

Macule: Focal area of color change which is not elevated or depressed in relation to its surroundings.

Papule: Solid, raised lesion which is less than 5 mm in diameter.
Nodule: Solid, raised lesion which is greater than 5 mm in diameter.

Sessile: Describing a tumor or growth whose base is the widest part of the lesion.

Pedunculated: Describing a tumor or growth whose base is narrower than the widest part of the lesion.

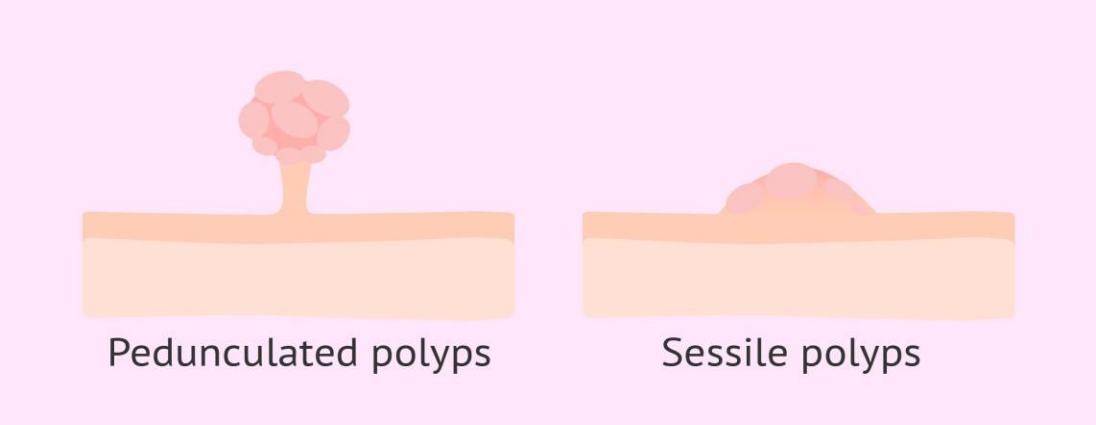

Papillary: Describing a tumor or growth exhibiting numerous surface projections.

Verrucous: Describing a tumor or growth exhibiting a rough, warty surface.

Vesicle: Superficial blister, 5 mm or less in diameter, usually filled with clear fluid.

Bulla: Large blister, greater than 5 mm in diameter.

Pustule: Blister filled with purulent exudate.

Ulcer: Lesion characterized by loss of the surface epithelium and frequently some of the underlying connective tissue. It often appears depressed or excavated.

Erosion: Superficial lesion. Often arising secondary to rupture of a vesicle or bulla, that is characterized by partial or total loss of the surface epithelium.

Fissure: Narrow, slit like ulceration or groove.

Plaque: Lesion that is slightly elevated and is flat on its surface.

Petechia: Round, pinpoint area of hemorrhage.



Ecchymosis: Nonelevated area of hemorrhage, larger than a petechia.

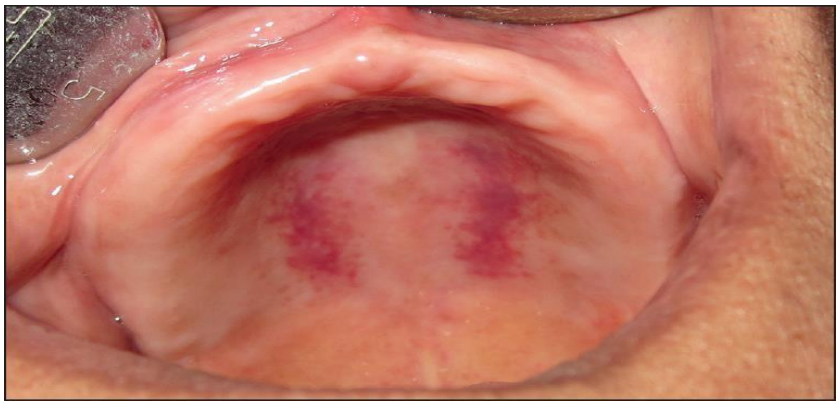

Oral Mucosal ulceration

Many lesions in the oral mucosa present as oral ulceration. An ulcer is a break in the continuity of the epithelium exposing the connective tissue to the oral environment, and there are many causes for oral ulceration:

Infective:

- Bacterial
- Viral
- Fungal

Traumatic:

- Mechanical- like tooth brush ulcer.

- Chemical- like aspirin burn ulcer.
- Thermal- like hot food or hot dental instruments and materials.
- Factitious injury
- Physical, like radiation- radiation mucositis- (radiotherapy of malignancies in oral cavity).

Idiopathic or immune mediated:

Recurrent aphthous stomatitis.
- minor aphthous ulcer
- major aphthous ulcer
- herpetiform ulcer

Associated with dermatological diseases:
- lichen planus
- lupus erythematous
- erythema multiforme
- vesiculobullous diseases

Associated with systemic diseases:
- haematological diseases
- GIT diseases. like chron's disease
- Behçet syndrome
- HIV infection

Neoplastic:
- Squamous cell carcinoma (SCC)
- Other malignant neoplasms

Traumatic ulcers:

Acute or chronic Trauma to the oral mucosa may result in surface ulcerations. The ulcerations may remain for extended periods, but most **usually heal within days**. In most cases, there is an adjacent **source of irritation**. Injury can result from mechanical damage, such as contact with sharp foodstuffs or accidental biting during mastication, overzealous tooth brushing (can create linear erosions along the free gingival margins). Simple chronic traumatic ulcerations occur most often on the **tongue, lips, and buccal mucosa- sites** that may be injured by the dentition. Lesions of gingiva, palate and muco-buccal fold may occur from other sources of irritation. The ulcer appears as area of **erythema surrounding a central area of yellow fibro-purulent membrane and painful**. Sometime, a large ulcer caused by biting the cheek or lip after a dental local anaesthetic.

Traumatic ulcers heal a few days after elimination of the cause. If they persist for more than 7 – 10 days, biopsy should be carried out.



Recurrent Aphthous stomatitis (Recurrent Aphthae RA)

Recurrent aphthae constitute **the most common oral mucosal disease** and affect as **much as 25 % of the population**, but many cases are mild and accepted with little complaint.

Possible etiological factors for recurrent aphthae are:

- Genetic predisposition
- Exaggerated response to trauma
- infections
- Immunological abnormalities
- Gastrointestinal disorders
- Haematological deficiencies ----- iron, B12, folic acid deficiencies.
- Hormonal disturbances
- Stress

Typical features of RA are:

- Onset frequently in childhood but peak in adolescence or early adult life.
- Attacks at variable but sometimes relatively regular intervals.
- Most patients are otherwise healthy
- Most patients are non – smokers
- Usually self – limiting eventually

Ulcers are of three clinically distinguishable types:

<u>Minor aphthae</u>

- The most common type.
- Painful.

- Ulcers are shallow, rounded**, 3 – 7 mm across with an erythematous marginand yellowish floor.**
- **Persist for 7-10 days**, **then heal without scarring**.
- One or several ulcers may be present.

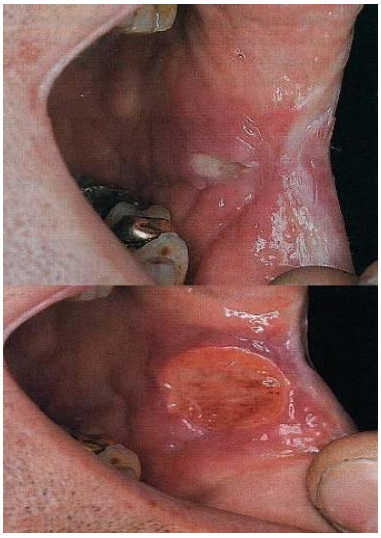

Major aphthae

- Uncommon.
- Sometimes mimic a malignant ulcer.
- Ulcers frequently **several centimetres** across.
- Ulcers **persist for several months**.
- **Scarring may follow healing**.

Herpetiform aphthae

- Uncommon.
- Ulcers are **1 – 2 mm across**.
- May **coalesce to form irregular ulcers**.
- Widespread bright **erythema surround the ulcers**.
- **Last for 10–14 days** and typically heal **without scarring**.



Treatment:

-Topical steroid 2-3 times daily.

- Mouth rinse with tetracycline 2-3 times daily.

- Chlorhexidine mouth rinse 2-3 times daily.

- Topical anesthetic paste to decrease the pain.

Behçet's Syndrom

Behçet's syndrome is a rare **multisystemic** inflammatory disease (**gastrointestinal, cardiovascular, ocular, CNS, pulmonary, dermal**) in which **recurrent oral aphthae are a consistent feature**. Although the oral manifestations are usually relatively minor, involvement of other sites, especially the eyes and CNS, can be serious.

Clinical Features.

The aetiology is unknown but is thought to be either an **infection or an immunological reaction to an infectious agent**. Behcet's disease might be an **autoimmune disorder**, which means the body's immune system mistakenly attacks some of its own healthy cells. It's likely that genetic and environmental factors play a role. Patients are usually young adult males between 20 and 40 years old. Patients suffer **one or four patterns of disease**, namely:

1. **Mucocutaneous (oral and genital ulceration)**

2. **Arthritis (joint involvement with or without mucocutaneous involvement)**
3. **Neurological .**
4. **Ocular .**

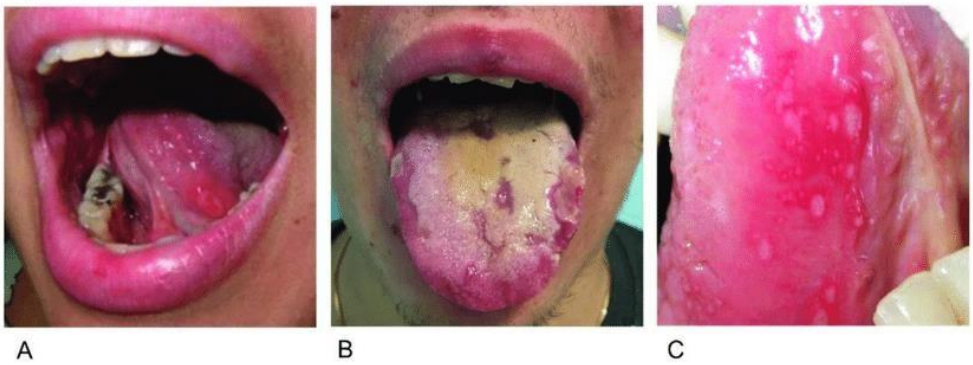

Lesions of Behçet's syndrome typically affect the **oral cavity (100% incidence)**, the **genitalia (62% of cases),** and the eyes. Other regions or systems are less commonly involved. **Recurrent arthritis** of the wrists, ankles, and knees may be associated. Cardiovascular manifestations are believed to result from vasculitis and thrombosis.

Oral manifestations of this syndrome appear identical to the ulcers of aphthous stomatitis. The ulcers are usually the **minor aphthous form**.

Ocular changes are noted in most patients with Behçet's syndrome.

Conjunctivitis, and retinitis are among the more common inflammatory processes.

Symptoms

Behcet's disease symptoms vary from person to person, can come and go or become less severe over time. Signs and symptoms depend on which parts of your body are affected. Areas commonly affected by Behcet's disease include:

Mouth. Painful mouth sores that look similar to canker sores are the most common sign of Behcet's disease. They begin as raised, round lesions in the mouth that quickly turn into painful ulcers. The sores usually heal in one to three weeks, though they do recur.

Skin. Some people develop acnelike sores on their bodies. Others develop red, raised and tender nodules on their skin, especially on the lower legs.

Genitals. Red, open sores can occur on the scrotum or the vulva. The sores are usually painful and can leave scars.

Eyes. Inflammation in the eye (uveitis) causes redness, pain and blurred vision, typically in both eyes. In people with Behcet's disease, the condition can come and go.

Joints. Joint swelling and pain often affect the knees in people with Behcet's disease. The ankles, elbows or wrists also might be involved. Signs and symptoms can last one to three weeks and go away on their own.

Blood vessels. Inflammation in veins and arteries can cause redness, pain, and swelling in the arms or legs when a blood clot results. Inflammation in the large arteries can lead to complications, such as aneurysms and narrowing or blockage of the vessel.

Digestive system. A variety of signs and symptoms can affect the digestive system, including abdominal pain, diarrhea and bleeding.

Brain. Inflammation in the brain and nervous system can cause headache, fever,

disorientation, poor balance or stroke.

Diagnosis. The diagnosis of Behçet's syndrome is based on clinical signs and symptoms associated with the various regions affected. No specific findings are noted in biopsy tissue, and no supportive laboratory tests are available.

Treatment. No standard therapy is known for Behçet's syndrome. Topical and Systemic steroids are often prescribed

Immunosuppressive drugs, such as chlorambucil and azathioprine, may be used instead of or in addition to steroids. Dapsone, cyclosporine, thalidomide, interferon, and biological anti–tumor necrosis factor (TNF) agents may play a role in the treatment of these patients, depending on the degree of disease severity.

Erythema Multiforme

Is a skin condition of unknown cause, EM is an acute self-limiting hypersensitivity reaction in the superficial microvasculature of the skin and oral mucous membrane that usually follows an infection or drug exposure. It is an uncommon disorder, With peak incidence in the second and third decades of life. The disorder has various forms or presentations, which its name reflects . **EM** usually resolving without complications. characterized by skin lesions and/or ulcerative oral lesions. It has been divided into two subtypes: a minor form, usually associated with an HSV trigger, and a major severe form, triggered by certain systemic drugs.



Causes

-Infections: bacterial, fungal,viral (HSV).
-Drug reactions, most commonly to: antibiotics(including, sulphonamides, penicillin),anticonvulsants (phenytoin, barbiturates), aspirin,-Physical factors: radiotherapy, cold, sunlight.EM minor is regarded as being triggered by HSV in almost all cases.

The basic cause of EM is unknown, although a hypersensitivity reaction is suspected.Other factors, such as malignancy, vaccination, autoimmune disease, and radiotherapy, are occasionally cited as possible triggers. Infections frequently reported include HSV infection (due to HSV types 1 and 2) and TB.

Signs and Symptoms:

EM is usually an acute, self-limited process that affects the skin or mucous membranes or both. Between 25% and 50% of patients with cutaneous EM have oral manifestations of this disease. The term erythema multiforme was coined to indicate the multiple and varied clinical appearances that are associated with cutaneous manifestations of this disease.

The condition varies from a mild, self-limited rash (E. multiforme minor) to a severe, life-threatening form known as erythema multiforme major that also involves mucous membranes.There are usually no symptoms in erythema multiforme minor. However, erythema multiforme major may be preceded by

mild symptoms such as fever or chills, weakness or painful joints.

Skin lesion: Typically in erythema multiforme, few to hundreds of skin lesions erupt within a 24-hour period The lesions are first seen on the backs of hands and/or tops of feet and then spread down the limbs towards the trunk. The upper limbs aremore commonly affected than the lower. Palms and soles may be involved. Theface, neck and trunk are common sites. The classic skin lesion of EM is the target or iris lesion. It consists of concentric erythematous rings separated by rings of near-normal color. Typically, the extremities are involved, usually in a symmetric distribution. Other types of skin manifestations of EM include macules, papules, vesicles, bullae, and urticarial plaques.

Orally, EM characteristically presents as an ulcerative disease, varying from a few aphthous-type lesions to multiple superficial, widespread ulcers in EM major.

Short-lived vesicles or bullae are infrequently seen at initial presentation. Any area of the mouth may be involved, with the lips, buccal mucosa, palate, and tongue being most frequently affected. Recurrent oral lesions may appear as multiple painful ulcers similar to those of the initial episode or as less symptomatic erythematous patches with limited ulceration. At the severe end of the EM spectrum (EM major), intense involvement of the mouth, eyes, skin, genitalia, and occasionally the esophagus and respiratory tract may be seen concurrently. This form of EM major, sometimes called Stevens-Johnson syndrome, Characteristically, the lips show crusting ulceration at the vermilion border that may cause pain. Superficial ulceration, often preceded by bullae, is common to all sites affected. Ocular inflammation (conjunctivitis and uveitis) may lead to scarring and blindness.



Treatment

In EM minor, symptomatic treatment, including keeping the mouth clean with bland mouth rinses, may be all that is necessary. In EM major, topical corticosteroids with antifungals may help control disease. The use of systemic corticosteroids remains controversial and is believed by some to be contraindicated,particularly as maintenance therapy. Acyclovir at 400 to 600 mg daily may be effective in preventing recurrences in patients who have an HSV-triggered disease, although the efficacy is not clear. Supportive measures, such as oral irrigation, adequate fluid intake, and use of antipyretics, may provide patients with substantial benefit.

Lupus erythematosus

Is a collection of autoimmune diseases in which the human immune system becomes hyperactive and attacks healthy tissues. Symptoms of these diseases can affect many different body systems, including joints, skin, kidneys, blood cells, heart, and lungs. The most common and most severe form is **systemic lupus erythematosus**.

Lupus is an autoimmune disease characterized by acute and chronic inflammation of various tissues of the body. Autoimmune diseases are illnesses that occur when the body's tissues are attacked by its own immune system. The immune system is a complex system within the body that is designed to fight infectious agents, such as bacteria and other foreign microbes. One of the ways that the immune system fights infections is by producing antibodies that bind to the microbes. People with lupus produce abnormal antibodies in their blood that target tissues within their own body rather than foreign infectious agents. These antibodies are referred to as autoantibodies. Because the antibodies and accompanying cells of inflammation can affect tissues anywhere in the body, lupus has the potential to affect a variety ofareas. Sometimes lupus can cause disease of the skin, heart, lungs kidneys, joints, and/or nervous system. When only the **skin is involved** by rash, the condition is called **lupus dermatitis** or **cutaneous lupus erythematosus**. A form of cutaneous lupus erythematosus that can be isolated to the skin, without internal disease, is called **discoid lupus erythematosus**. When internal organs are involved, the condition is referred to as **systemic lupus erythematosus** (SLE).

Both discoid lupus erythematosus and systemic lupus are more common in women than men (about eighttimes more common). The disease can affect all ages but most commonly begins from 20-45 years of age.

Discoid lupus affects the skin, causing a red, scaly rash with raised borders on areas of the body that are exposed to sunlight.

Signs and symptoms

Symptoms vary from person to person, and may come and go. Almost everyone with lupus has joint pain and swelling. Some develop arthritis. Frequently affected joints are the fingers, hands, wrists, and knees.Other common symptoms include:

- chest pain during respiration
- joint pain
- painless oral ulcer ulcers of the mouth and nose
- fatigue
- weight loss
- fever with no other cause
- general discomfort, uneasiness, or ill feeling (malaise)
- hair loss (Alopecia)
- sensitivity to sunlight
- a "butterfly" facial rash, seen in about half of people with SLE
- swollen lymph nodes



Systemic LE

In **discoid lupus**, only the skin is typically involved. The skin rash in discoid lupus often is found on the face and scalp. It usually is red and may have raised borders. Discoid lupus rashes are usually **painless and do not itch**, but scarring can cause permanent hair loss (alopecia). Over time, 5%-10% of those with discoid lupus may develop SLE. With discoid lupus, the immune system attacks healthy skin, causing sores that appear as a **disc-shaped rash**. It is most likely to appear on areas of the skin that are regularly exposed to sunlight, such as the face, neck, and backs of the hands. Over half of the people with SLE develop a characteristic red, flat facial rash overthe bridge of their nose. Because of its shape, it is frequently referred to as the "**butterfly rash"** of SLE. The rash is **painless** and does not itch. The facial rash, along with inflammation in other organs, can be precipitated or worsened by exposure to sunlight, a condition called photosensitivity. Typically, with treatment, this rash can heal **without** permanent scarring.

Most SLE patients will develop arthritis during the course of their illness. Arthritis from SLE commonly involves swelling, pain, stiffness, and even deformity of the small joints of the hands, wrists, and feet. Sometimes, the arthritis of SLE can mimic that of rheumatoid arthritis (another autoimmune disease). More serious organ involvement with inflammation occurs in the brain, liver, and kidneys. White blood cells can be decreased in SLE (referred to as leukopenia or leucopenia). Also, low blood-clotting factors called platelets (thrombocytopenia) can be caused by lupus. Leukopenia can increase the risk of infection, and thrombocytopenia can increase the risk of bleeding. Low red blood cell counts (hemolytic anemia) can occur.

Inflammation of muscles (myositis) can cause muscle pain and weakness. Inflammation of blood vessels (vasculitis), Inflammation of the lining of the lungs (pleuritis), inflammation of heart muscles(carditis), Kidney inflammation in SLE (lupus nephritis), With kidney failure, machines are needed to cleanse the blood of accumulated waste products in a process called dialysis. Brain involvement is referred to as lupus cerebritis which can cause personality changes, thought disorders (psychosis), seizures, and even coma.



Treatment

There is no permanent cure for SLE. The goal of treatment is to relieve symptoms and protect organs by decreasing inflammation and/or the level of autoimmune activity in the body. The precise treatment is decided on an individual basis. Many people with mild symptoms may need no treatment or only intermittent courses of anti-inflammatory medications. Those with more serious illness involving damage to internal organ(s) may require high doses of corticosteroids in combination with other medications that suppress the body's immune system.Treatment of systemic lupus erythematosus is directed toward decreasing inflammation and/or the level of autoimmune activity with anti inflammatory medications for those with mild symptoms and corticosteroids and/or cytotoxic drugs (chemotherapy) for those withmore severe lupus.