# Oral mucosal lesions and infections

## Viral infections of oral cavity

### Herpes simplex virus (HSVs)

Herpes simplex viruses more commonly known as herpes, are categorized into two types: herpes type 1 (**HSV-1**, or **oral herpes**) and herpes type 2 (**HSV-2**, or **genital herpes**). Most commonly, herpes type 1 causes sores around the mouth and lips (sometimes called fever blisters or cold sores). In HSV-2, the infected person may have sores around the genitals or rectum.Herpes simplex virus infections occur in two forms—**primary and secondary** . Both forms are self-limited, but recurrences of the secondary form are common because the virus can remain within ganglionic tissue in a latent state. Physical contact with an infected individual or with body fluids is the typical route of HSV inoculation and transmission.

During the primary infection, only a small percentage of individuals show clinical signs and symptoms of infectious systemic disease, whereas a vast majority experience only subclinical disease. After resolution of primary herpetic gingivostomatitis, the virus is believed to migrate, through some unknown mechanism, to the trigeminal ganglion.

Reactivation of virus may follow exposure to sunlight (“fever blisters”), exposure to cold (“cold sores”), trauma, physical or emotional stress, fatigue, or immunosuppression causing a secondary or recurrent infection.

### Primary herpetic gingivostomatitis (PHGS)

Represents the clinically apparent pattern of primary herpes simplex virus (HSV) infection; PHGS is caused predominantly by **HSV-1** and affects mainly children. General symptoms, such as fever, anorexia, irritability, malaise and headache, may occur in advance of disease. The disease presents **as numerous pin-head vesicles**, which rupture rapidly to form painful irregular ulcerations covered by yellow–grey membranes. Sub-mandibular lymphadenitis and halitosis are usual findings.

Intraorally, lesions may appear on any mucosal surface. This is incontradistinction to the recurrent form of the disease, in which lesions are confined to the lips, hard palate, and gingiva. The primary lesions are accompanied by fever, arthralgia, malaise, anorexia, headache, and cervical lymphadenopathy after the systemic primary infection runs its course of about 7 to 10 days, lesions heal **without scar** formation. By this time, the virus may have migrated to the trigeminal

ganglion to reside in a latent form. Secondary, or Recurrent, Herpes Simplex Infection represents the reactivation of latent virus.



Fig. 1. Multiple ulcerative lesions on lips, gum and tongue.

**Herpes Labailis**

Commonly known as **cold sores**, is a type of infection by the herpes simplex virus that **affects primarily the lip**. Symptoms typically include a **burning pain** followed by small blisters or sores. The first attack may also be accompanied by fever, sore throat, and enlarged lymph nodes. The rash usually heals within ten days, but the virus remains dormant in the trigeminal ganglion. The virus may periodically reactivate to create another outbreak of sores in the mouth or lip. The cause is usually herpes simplex virus type 1. Attacks can be triggered by sunlight, fever and psychological stress.



**Treatment**

Although there is no cure for herpes, treatments can relieve the symptoms. Medication can decrease the pain related to an outbreak and can shorten healing time. They can also decrease the total number of outbreaks. Antiviral drugs including Famvir, Zovirax( Acyclovir ), Valtrex with anesthetic ,zinc oxide , zinc sulfate creams are among the drugs used to treat the symptoms of herpes.

**Herpetic whitlow**

Is a viral condition where small blisters form on the fingers and the fleshy area around the fingertips. These sores or blisters are often painful and develop after direct contact with a contagious sore**.** This type of infection typically occurred in dental practitioners who had been in physical contact with infected individuals. Contact could result in a vesiculoulcerative eruption on the digit (rather than in the oral region), along with signs and symptoms of primary systemic disease. Pain, redness, and swelling are prominent with herpetic whitlow and can be very pronounced. Vesicles or pustules eventually break and become ulcers. The duration of herpetic whitlow is protracted and may be as long as 4 to 6 weeks.



**Treatment:** Symptomatic. In severe cases, systemic Acyclovir or valaciclovir.

## *Varicella-zoster virus infection*

**Primary** varicella-zoster virus (VZV) infection is known as **varicella or chickenpox**; **secondary** or reactivated disease is known as **herpes zoster or shingles**.

***Clinical features***

***Varicella***

Fever, chills, malaise, and headache may accompany a rash that involves primarily the trunk and head and neck. The rash quickly develops into a vesicular eruption that becomes pustular and eventually ulcerates. The infection is self-limiting and lasts several weeks. Oral mucous membranes may be involved in primary disease and usually demonstrate multiple shallow ulcers that are preceded by vesicles.


Copyright © 2007 Interactive Medical Media LLC. All rights reserved

***Herpes zoster:*** Herpes Zoster is essentially a condition of the older adult population and of individuals who have compromised immune responses. The sensory nerves of the trunk and head and neck are commonly affected. Involvementof various branches of the trigeminal nerve may result in unilateral oral, facial, or ocular lesions. After several days of prodromal symptoms of pain and/or paresthesiain the area of the involved dermatome, a well-delineated unilateral maculopapularrash appears. This may occasionally be accompanied by systemic symptoms. The rash quickly becomes vesicular, pustular, and then ulcerative. Remission usually occurs in several weeks.



**Treatment**

Antiviral drugs such as Acyclovir and Vidarabin given orally or intravenously depending on the severity of the cases.

## Herpangina

Herpangina is an acute viral infection caused by **Coxsackie type A virus**. It is transmitted by contaminated saliva, through droplets from sneezes or coughs and occasionally through contaminated feces. After a child gets herpangina, they usually develop a natural immunity to the virus that caused it.

***Clinical Features.*** Herpangina is usually endemic, with outbreaks occurring typically in summer or early autumn. It is more common in children than in adults. Those infected generally complain of malaise, fever, dysphagia, and sore throat after a short incubation period. Intraorally, a vesicular eruption appears on the soft palate, roof of the mouth , and tonsils and persists for 4 to 6 days. A diffuse erythematous pharyngitis is also present. No associated skin lesions are typically seen. Signs and symptoms are usually mild to moderate and generally last less than a week.



***Treatment.***

Because herpangina is self-limiting, is mild and of short duration, andcauses few complications, treatment usually is not required.

## Hand –Foot and mouth disease

Hand, foot, and mouth disease (HFMD) is a common infection in children that causes sores called ulcers inside or around their mouth and a rash or blisters on their hands, feet, legs, or buttocks. It can be painful, but it isn't serious.

The viruses that usually cause hand, foot, and mouth are named ***coxsackie virus A and enterovirus.***

Anyone can have the disease, but children under age 5 are most likely to get it. It tends to spread easily in the summer and fall

### Signs and symptoms

Malaise – fever-sore throat-painful blisters inside the mouth , in the hands and feet.




## Bacterial infections

### Necrotizing Ulcerative Gingivitis

Necrotizing ulcerative gingivitis (NUG) is a relatively rare specific infectious gingival disease of young persons. is a common, non-contagious infection of the gums with sudden onset. The main features are painful, bleeding gums, and ulceration of inter-dental papillae .The often severe gum pain that characterizes NUG distinguishes it from the more common chronic periodontitis which is rarely painful. Predisposing factors include poor oral hygiene, smoking, poor nutrition, psychological stress, and a weakened immune system.



**Causes**

**NUG** is caused by a **mixed bacterial infection** that includes anaerobes such as ***Prevotella intermedia*** and ***Fusobacterium*** as well as **Spirochetes**, such as ***Treponema*.**

**Signs and symptoms**

Three signs and symptoms must be present to diagnose this condition:

1- Severe gum pain.

2- Profuse gum bleeding.

3- Interdental papillae are ulcerated with dead tissue.

Other signs and symptoms may be present, but not always:-

Halitosis. Bad taste . Malaise, fever and/or cervical lymph node enlargement are rare.

**Treatment**

Oral hygiene instruction and the uses of mouth rinses and pain medication. If there is systemic involvement, then oral antibiotics may be given, such as metronidazole.

## Noma

Also known as , gangrenous stomatitis, or cancrum oris) is a rapidly progressive and often fatal infection of the mouth and face. This disease predominantly affects children between the ages of two and six years old in the least developed countries around the world.

## Causes

Noma is often reported as a sequela to acute necrotizing ulcerative gingivitis. ***Fusobacterium*** and ***Prevotella*** are important bacterial pathogens in this disease process, interacting with one or more other bacterial organisms (such as ***Treponema***, ***Staphylococcus aureus***, and certain species of ***Streptococcus***). Treatment of these organisms can help arrest the infection, but does not restore already-missing or disfigured tissue.

**Predisposing factors include :**

malnutrition
vitamin deficiency (particularly deficiencies of Vitamin A and Vitamin B)
contaminated drinking water
immunodeficiency
poor hygiene, particularly oral
recent illness (especially acute necrotizing ulcerative gingivitis, measles, malaria, and severe diarrhea)

## Signs & symptoms

The mucous membranes of the mouth develop ulcers, followed by rapid, painful tissue degeneration and necrosis of the tissues of the bones in the face.



## Syphilis

Is a sexually transmitted infection caused by the ***Treponema pallidum*****,** Syphilis may be acquired (common) or congenital (rare) ( transmitted from mother to baby during pregnancy or at birth, resulting in congenital syphilis) .

### *Clinical features*

The signs and symptoms of syphilis vary depending in which of the three stages it presents (primary, secondary, and tertiary).

**The primary stage** usually **three weeks** after the infection classically presents with **a single chancre** (a firm, painless, non-itchy skin ulceration usually between 1 cm and 2 cm in diameter) though there may be multiple sores. Oral chancre appears in about 5–10% of cases, and clinically presents as a **painless ulcer** with a smooth surface, raised borders, and. Regional lymphadenopathy is a constant finding.





**In secondary syphilis** begins **6–8 weeks** after the appearance of the chancre, and lasts for 2–10 weeks **, a diffuse rash** occurs, which frequently involves the **palms of the hands and soles of the feet**. There may also be sores in the mouth or vagina. Oral lesions are mucous patches with malaise, low-grade fever, headache, lacrimation, sore throat, weight loss,multiple arthralgias,and generalized lymphadenopathy.

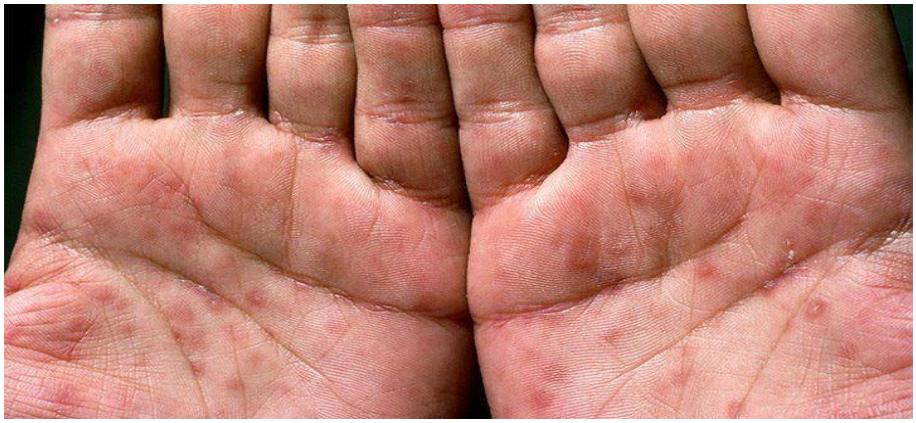

**In tertiary syphilis** begins after a period of **4–7 years**, Oral lesions **are gummas** (soft, non-cancerous growths), atrophic glossitis (smooth tongue), **Hutchinson's teeth**, and **Moon's** or **mulberry molars which are seen in the congenital syphilis**

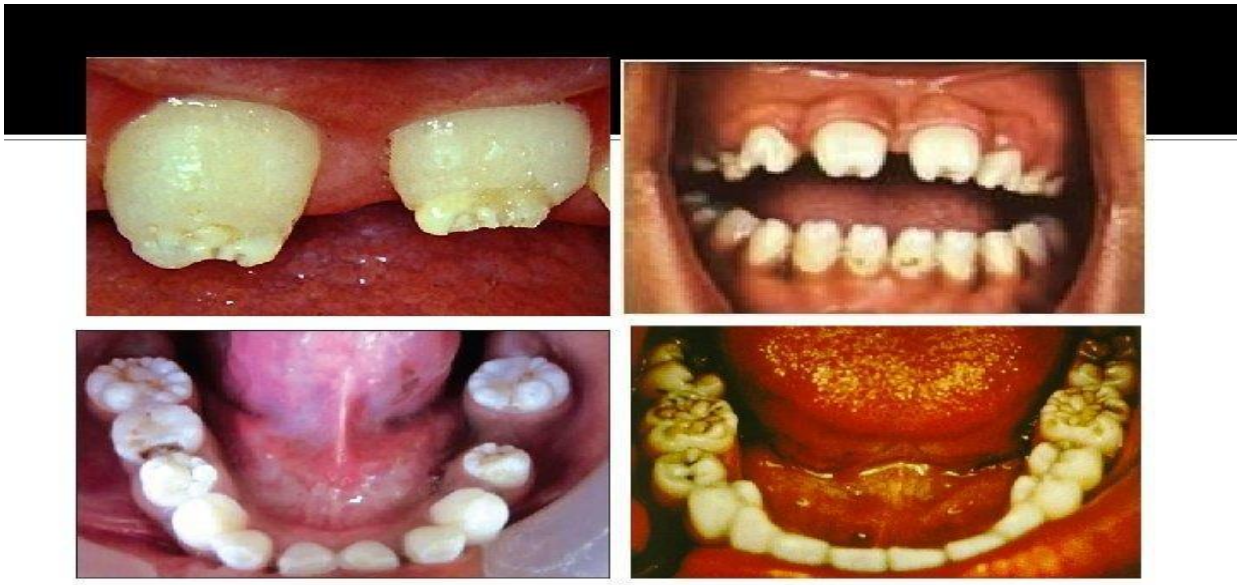

**Treatment.** Penicillin is the antibiotic of choice. Erythromycin or cephalosporins are good alternatives.

***Tuberculosis (TB)*** Is an infectious disease usually caused by ***Mycobacterium tuberculosis*** **(MTB) bacteria**.Tuberculosis generally affects the lungs, but can also affect other parts of the body.

**Clinical features** The classic symptoms of active TB are a chronic cough with blood-containing mucous, fever, night sweats, and weight loss. Infection of other organs can cause a wide range of symptoms.

The oral lesions are rare, and usually secondary to pulmonary tuberculosis. The **tuberculous ulcer** is the most common feature. Clinically**, the ulcer is painless** and irregular, with a thin undermined border, usually covered by a gray-yellowish exudate. The surrounding tissues are inflamed and indurated. The tongue is the most commonly affected site, followed by the lip, buccal mucosa, and palate. Osteomyelitis of the jaws, periapical granuloma, and regional lymphadenopathy, are less common oral manifestations.



**Histopathology**

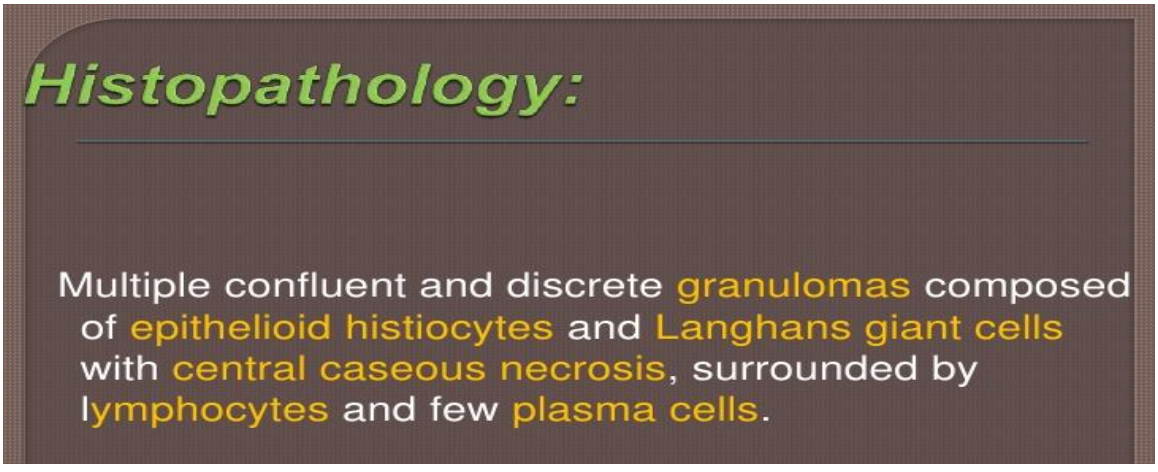

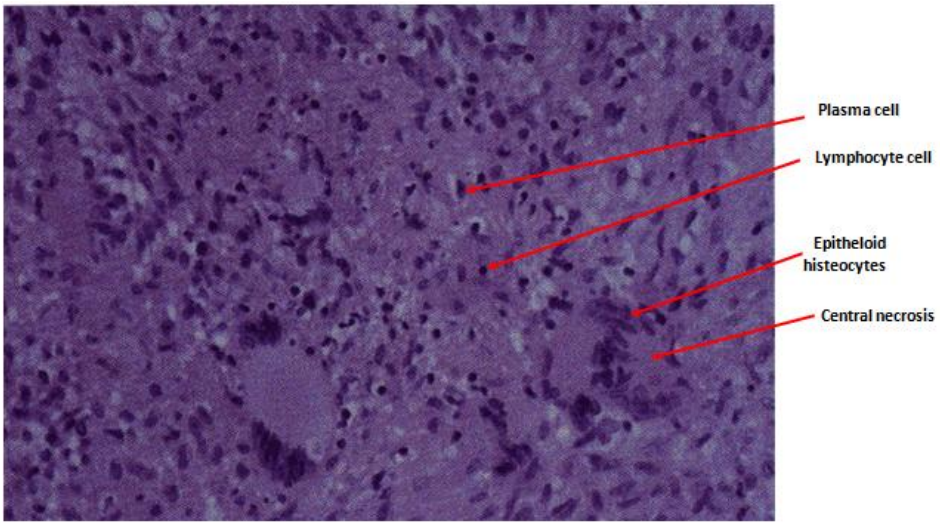


**Treatment**

It is very important that people who have TB disease are treated and take the drugs exactly as prescribed, and finish the medicine, If they stop taking the drugs too soon, they can become sick again; if they do not take the drugs correctly, the TB

bacteria that are still alive may become resistant to those drugs. TB that is resistant to drugs is harder and more expensive to treat.

TB disease can be treated by taking several drugs for 6 to 9 months. There are 10 drugs currently approved by the U.S. Food and Drug Administration (FDA) for treating TB. Of the approved drugs, the first-line anti-TB agents that form the core of treatment regimens are:

- isoniazid (INH)
- rifampin (RIF)
- ethambutol (EMB)
- pyrazinamide (PZA)

## Actinomycosis

Actinomycosis is a **chronic bacterial disease caused by Actinomyces israelii**, an anaerobic , gram-positive bacterium. Infection usually appears after trauma, surgery, or previous infection .

***Clinically*,** it typically presents as swelling of the mandible that may simulate a pyogenic infection. The lesion may become indurated and eventually may form **one or more draining sinuses**, leading from the medullary spaces of the mandible to the skin of the neck.

The clinical course ranges from acute to chronic. Pus draining from the chronic lesion may contain **small yellow granules**, known **as sulfur granules (diagnostic feature of Actinomycosis)**, which represent aggregates of ***A. israelii organisms***. Radiographically, this infection presents as a lucency with irregular and ill-defined margins.

***Treatment.*** Long-term, high-dose penicillin or penicillin analogs are the required antibiotic regimen for actinomycosis.



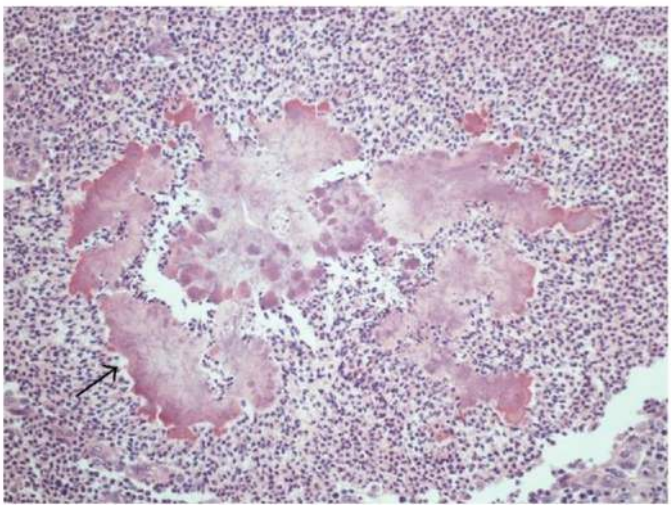

## Fungal infection

### Candidal infection (Candidiasis)

Candidiasis is the most common **oral fungal infection**. It is usually caused by **Candida albicans**. Predisposing factors are local (poor oral hygiene, xerostomia, mucosal damage, dentures, antibiotic mouthwashes) and systemic (broad-spectrum antibiotics, steroids, immunosuppressive drugs, radiation, HIV infection, hematological malignancies, neutropenia, iron-deficiency anemia, cellular immunodeficiency, endocrine disorders).

## Clinical features

Signs and symptoms include white patches on the tongue or other areas of the mouth and throat. Other symptoms may include soreness and problems swallowing. **Oral candidiasis**, also known as **oral thrush,** Most types of oral candidiasis are painless, but a burning sensation may occur in some cases**,** A burning sensation is more likely with erythematous (atrophic) candidiasis, Occasionally there can be dysphagia (difficulty swallowing), which indicates that the candidiasis involves the oropharynx or the esophagus,as well as the mouth. The trachea and the larynx may also be involved where there is oral candidiasis, and this may cause hoarseness of the voice**.**



## Treatment

Candidiasis is treated with antifungal medications**,** Mouth and throat candidiasis are treated with antifungal medication. Oral candidiasis usually responds to topical treatments; otherwise, systemic antifungal medication may be needed for oral infections.