Lec. 19

Soft Tissue Tumors

- Soft tissue is defined as complex of nonepithelial extra skeletal structure of body exclusive of supportive tissue of various organs and the hematopoietic/ lymphoid tissue.

- It is composed of fibrous tissue, adipose tissue, skeletal muscle, blood and lymph vessels and peripheral nerve.
- Most of the soft tissue derived from mesoderm with neuroectodermal contribution corresponding to peripheral nerve.

Irritation Fibroma



Irritation Fibroma
Reactive Fibrous Hyperplasia;
Traumatic Fibroma

- Smooth-surface
- Normal color
- Painless nodule
- May be pigmented
  - -- Melanosis of epithelium
- Maybe: frictional keratosis
- May be ulcerated (trauma)
- Usually sessile
  - -- May be pedunculated
- Usually <1 cm.
  - – May become 3-4 cm.
- Full size within 6 months
  - -- Minimal increase after
  - -- Does not go away
  - – No malignancy risk





Irritation Fibroma
Histopathology & Treatment

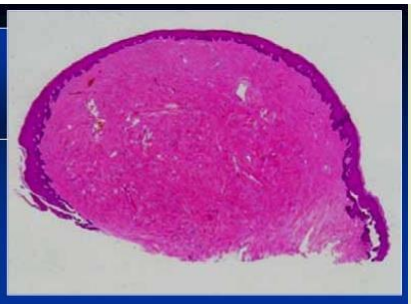

- Pedunculated or sessile
- Dense, avascular fibrous stroma
- No capsule
- Epithelium often atrophic
- Small numbers of lymphocytes in fibrous stroma, maybe
- Treat: conservative excision, otherwise lasts forever



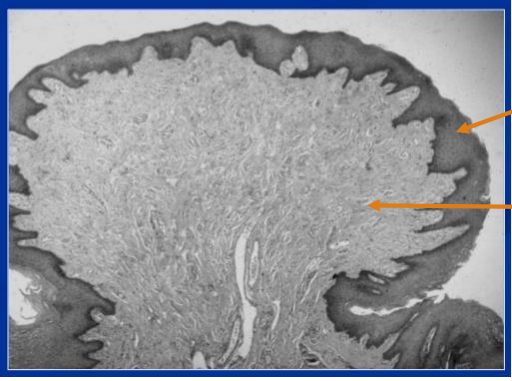

Leaf-Shaped Fibroma
Variant of Irritation Fibroma



- Grows under a denture base
- Flat, often with small papules along edges
- 6th most common mucosal lesion
  -- Prevalence = 7/1,000, with strong female predilection
- Problems: Cortical erosion; infarction (stalk gets twisted)
- Treat same as for regular irritation fibroma





Giant Cell Fibroma



Giant Cell Fibroma
Variant of Irritation Fibroma



- Etiology: unknown
  - -- Not related to trauma
- [redacted]
  - – Slight female
  - – Younger persons
  - -- 2-5% of fibrous oral masses
  - – 50% on gingiva
- Small, often lobulated
- Smooth or pebbled
- Painless nodule
- < 5 mm in size

Giant Cell Fibroma

Histopathology, Pathophysiology, Treatment

- Like irritation fibroma
- Large, stellate, subepithelial fibroblasts
- Sometimes multiple nuclei
- Remains indefinitely
- Treat: conservative surgical excision

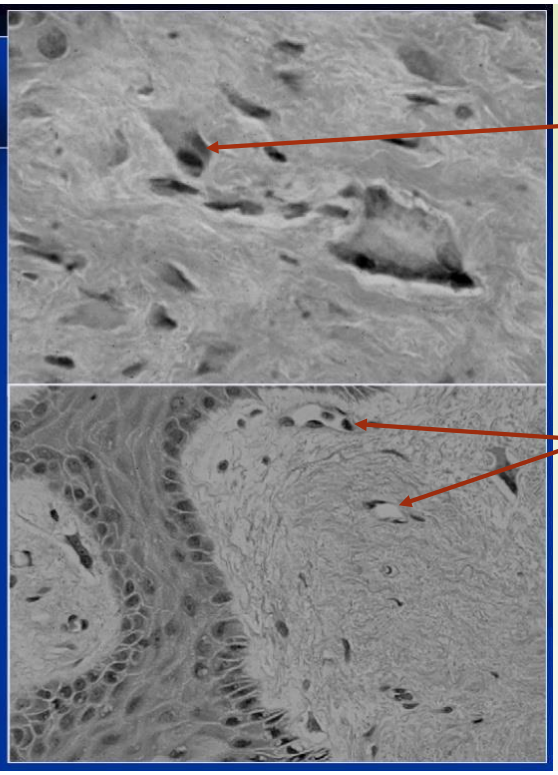

Epulis Fissuratum

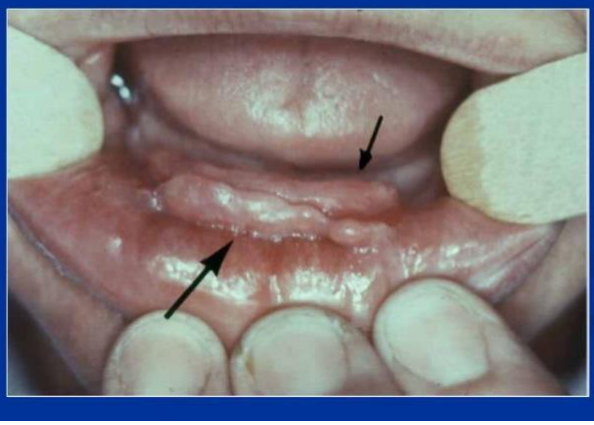

Epulis Fissuratum
Variant of Irritation Fibroma?

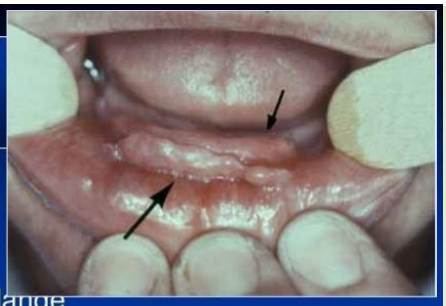

Reactive fibrous hyperplasia; inflammatory fibrous hyperplasia; denture injury tumor; denture epulis; redundant tissue

- ❑ Etiology: repeating trauma from denture flange
  - – None (but strong female in biopsied cases)
  - -- Middle-aged and older
  - – Anterior vestibule > posterior vestibule > anterior oral floor
  - -- 11th most common oral lesion
  - -- Prevalence = 4/1,000 adults

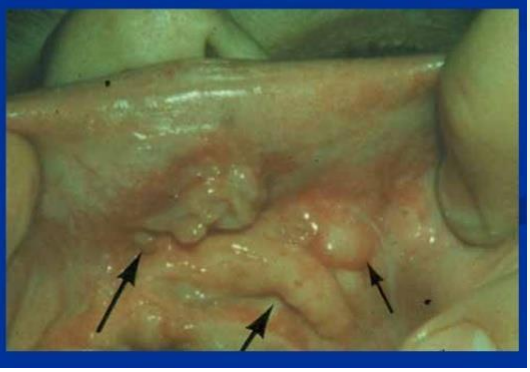

Epulis Fissuratum
Histopathology



- ❑ Like irritation fibroma
- ❑ More chronic inflammatory cells
- ❑ Acanthosis/degeneration
- ❑ May have surface ulcer (traumatic ulcer)
- ❑ May have inflammatory papillary hyperplasia of surface

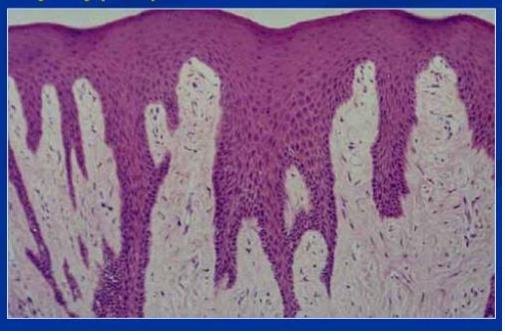

Epulis Fissuratum



- Maybe: pseudoepitheliomatous Hyperplasia
  - -- "Islands" of epithelium if cut tangentially or in cross section
  - -- Can look like: Squamous cell carcinoma

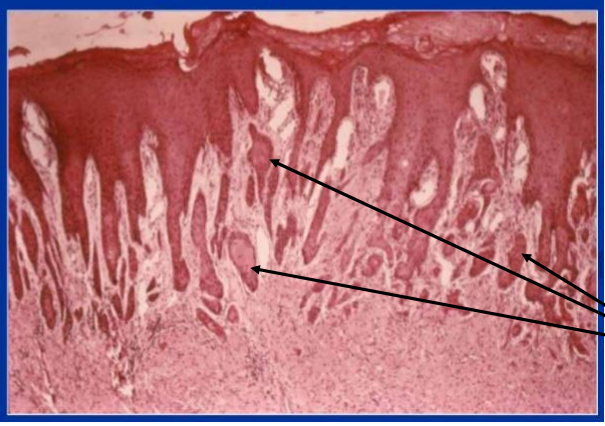

Pseudoepitheliom-atous hyperplasia

Inflammatory Papillary Hyperplasia



Inflammatory Papillary Hyperplasia
Papillary Hyperplasia of the Palate
Denture Papillomatosis



- Repeated trauma from denture base
  - -- Especially in persons who sleep with denture in place
  - -- Edema of connective tissue papillae
- May be seen in non-denture patients with:
  - -- High arched palate
  - -- Immune deficiency (e.g. AIDS)
- [redacted]
  - – 2x female
  - – Middle-age and older
  - – Hard palate, under denture
  - -- 15th most common mucosal lesion
  - -- Prevalence = 3/1,000 adults

Inflammatory Papillary Hyperplasia
Clinical Features



- Multiple painless fibrous papules
  - -- Scattered across hard palate
  - -- Concentrated in the midline
  - -- Burning? Candidiasis
- Early lesions are:
  - -- Edematous
  - -- Erythematous





Inflammatory Papillary Hyperplasia
Histopathology

- Old papules: like small irritation fibroma
- Early: edematous granulation tissue
  -- With chronic inflammatory cells
- Pseudoepitheliomatous hyperplasia:
  -- Can look like squamous cell carcinoma

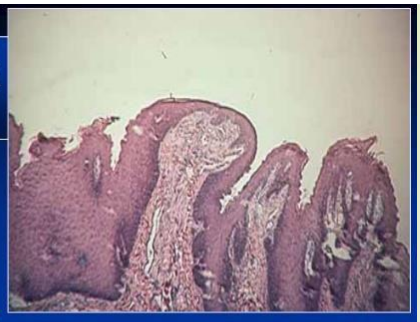

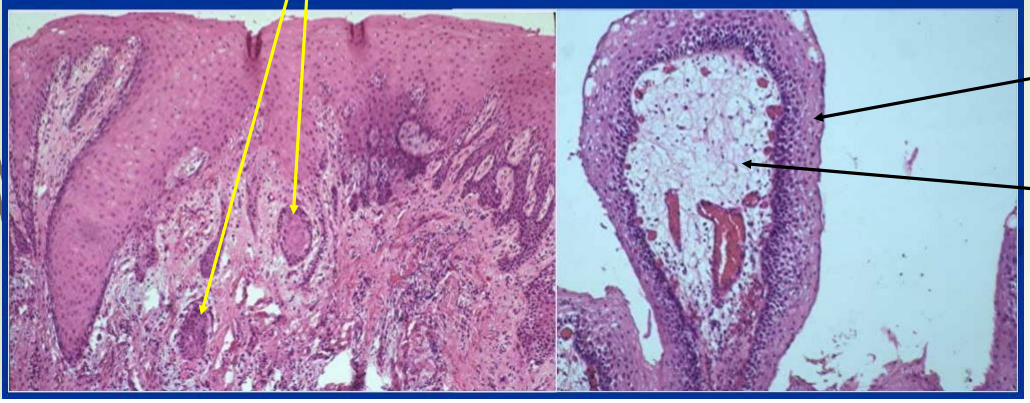

Pyogenic Granuloma

pyogenic granuloma is a common tumor like growth of the oral cavity that has been considered to be non-neoplastic in nature the pyogenic granuloma is thought to represent an exuberant tissue response to local irritation or trauma.

Clinically

The pyogenic granuloma is a smooth or lobulated mass that is usually pedunculated, although some lesions are sessile The surface is characteristically ulcerated and ranges from pink to red to purple, depending on the age of the lesion

They vary from small growths only a few millimeters in size to larger lesions that may measure several centimeters in diameter, the mass is painless, although it often bleeds easily because of its extreme vascularity, it may exhibit rapid growth

Gingiva is the most common site, it may occur at any age

Poor oral hygiene may be a precipitating factor.

Pyogenic granulomas of the gingiva frequently develop in pregnant women, so much so that the terms **pregnancy tumor or granuloma gravidarum** often are used. Such lesions may begin to develop during the first trimester, and their incidence increases up through the seventh month of pregnancy. The gradual rise in development of these lesions throughout pregnancy may be related to the increasing levels of estrogen and progesterone as the pregnancy progresses. After pregnancy and the return of normal hormone levels, some of these pyogenic granulomas resolve without treatment or undergo fibrous maturation and resemble a fibroma

Epulis granulomatosa: is a term used to describe hyperplastic growths of granulation tissue that sometimes arise in healing extraction sockets (Fig. 12-34). These lesions resemble pyogenic granulomas and usually represent a granulation tissue reaction to bony sequestra in the socket.

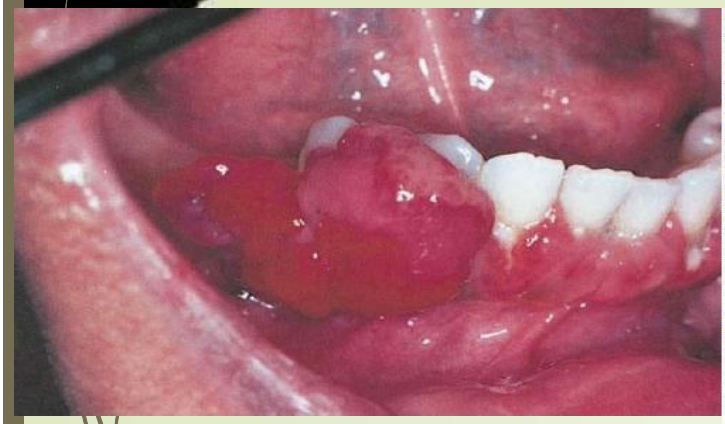

Pyogenic granuloma: erythematous hemorrhagic mass



Figure 12-34 • **Epulis granulomatosa.** Nodular mass of granulation tissue that developed in a recent extraction site.

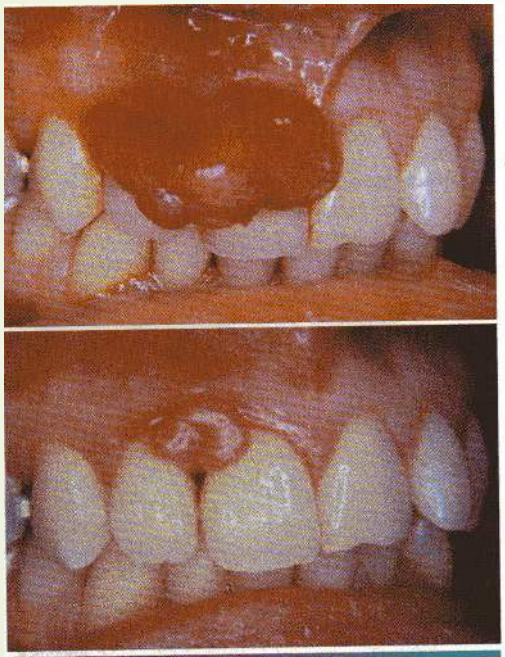

Figure 12-33 • **Pyogenic granuloma. A,** Large gingival mass in a pregnant woman just before childbirth. **B,** The mass has decreased in size and undergone fibrous maturation 3 months after childbirth. (Courtesy of Dr. George Blozis.)

HISTOPATHOLOGIC FEATURES

...cular proliferation that resembles granulation tissue (Figs.12-36).
...ous small and larger endothelium-lined channels are formed that are ...gorged with red blood cells.
A mixed inflammatory cell infiltrate of neutrophils, plasma cells, and lymphocytes

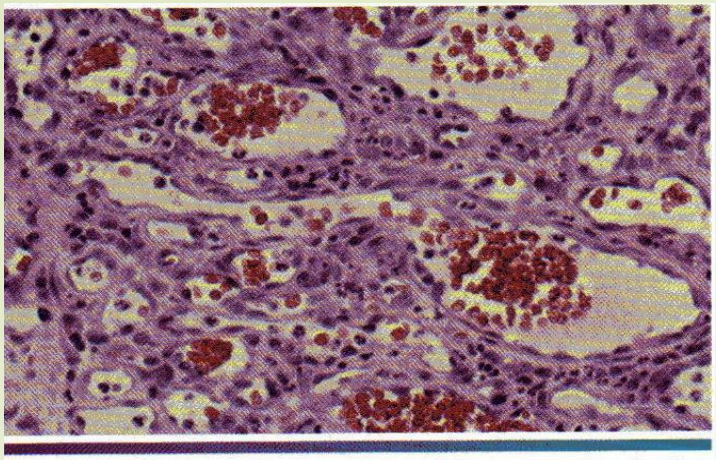

Figure 12-36 • **Pyogenic granuloma.** Higher-power view showing capillary blood vessels and scattered inflammation.

TREATMENT AND PROGNOSIS

Conservative surgical excision, occasionally, the lesion recurs.
For lesions that develop during pregnancy, usually treatment should be deferred unless significant functional or aesthetic problems develop.
The recurrence rate is higher for pyogenic granulomas removed during pregnancy, and some lesions will resolve spontaneously after parturition.

ripheral giant cell granuloma (PGCG)

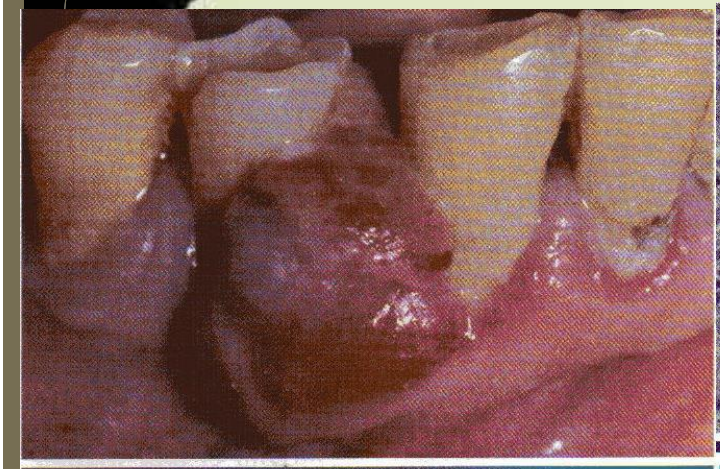

Figure 12-38 • **Peripheral giant cell granuloma.** Ulcerated mass of the mandibular gingiva.

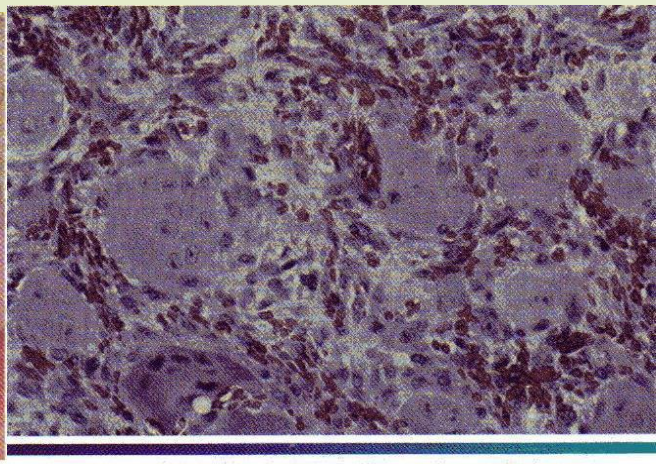

Figure 12-40 • **Peripheral giant cell granuloma.** High-power view showing scattered multinucleated giant cells within a hemorrhagic background of ovoid and spindle-shaped mesenchymal cells.

Peripheral ossifying fibroma

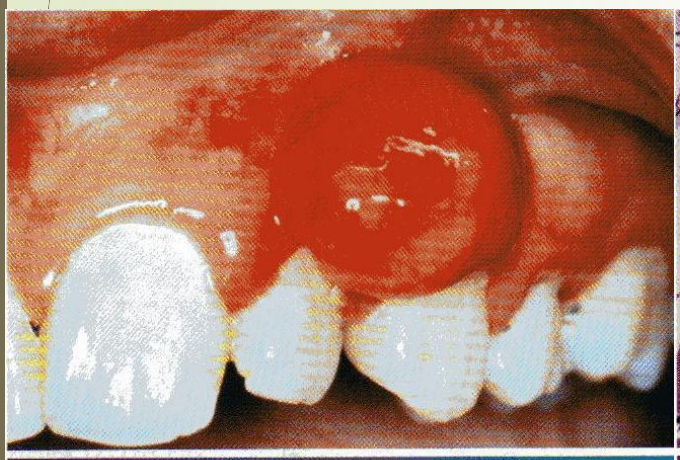

Figure 12-41 • **Peripheral ossifying fibroma.** Red, ulcerated mass of the maxillary gingiva. Such ulcerated lesions are easily mistaken for a pyogenic granuloma.

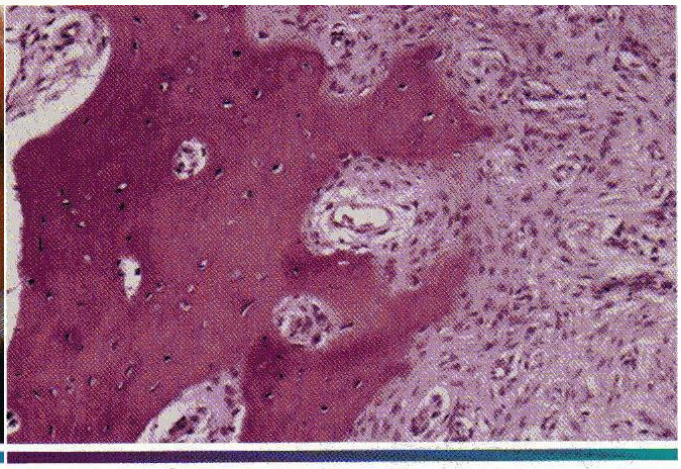

Figure 12-45 • **Peripheral ossifying fibroma.** High-power view showing formation of bone within a moderately cellular fibrous stroma.

Fat Lesion

- Lipoma:
  - Location: Buccal mucosa, tongue & floor of the mouth
  - Asymptomatic, yellowish submucosal mass
  - Overlying epithelium is intact
  - Superficial blood vessels are usually evident









Fat Lesion

- Lipoma:
  - Well circumscribed, lobulated mass of mature fat cells

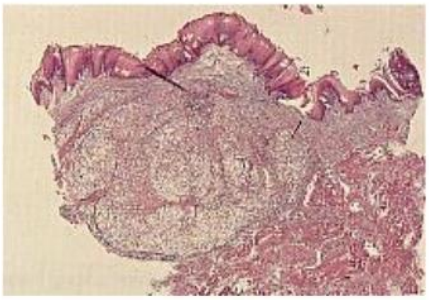

TREATMENT AND PROGNOSIS

Lipomas are treated by conservative local excision, and recurrence is rare

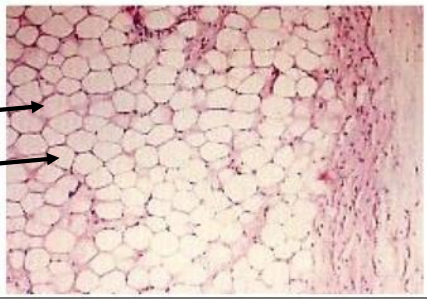

Fat cells

LYMPHANGIOMA

- Lymphangiomas are benign tumours of lymphatic vessels showing marked predilection for head and neck region.

Types of lymphangioma:
1-lymphangioma simplex (Capillary)
2- Cavernous lymphangioma
3- Cystic lymphangioma (Hygroma)

•They are extremely rare in the oral cavity.

• The common site of occurrence for lymphangioma in the oral cavity is the anterior dorsum and lateral border of tongue.



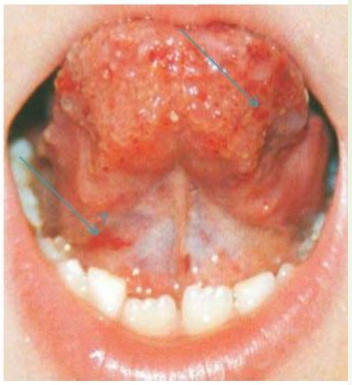

lymphangioma

cystic hygroma



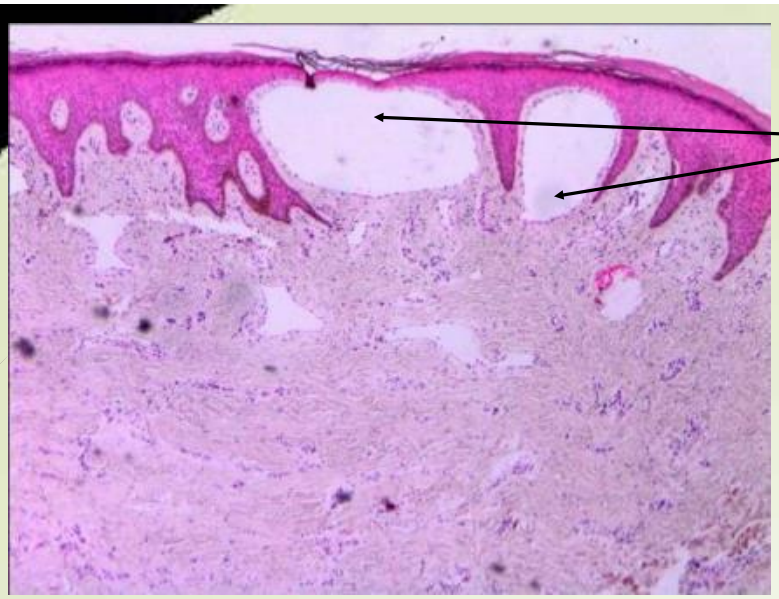

HISTOPATHOLOGIC FEATURES: composed of lymphatic vessels that may show marked dilatation (cavernous lymphangioma) or macroscopic cyst-like structures (cystic hygroma) (Fig. 12-110).

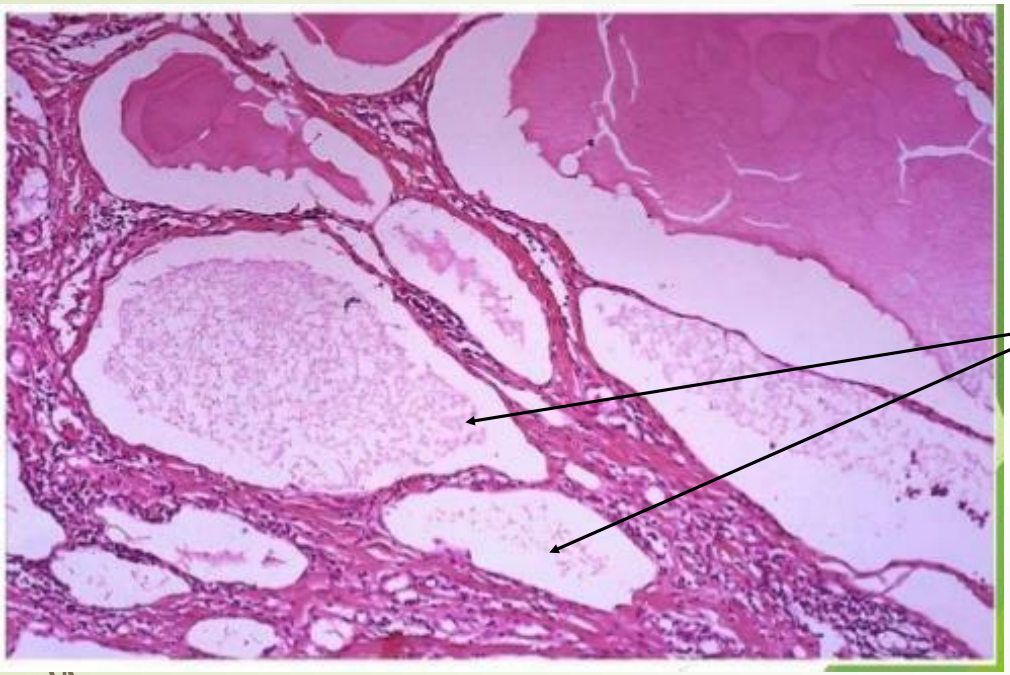

macroscopic cyst-like structures (cystic hygroma)

TREATMENT AND PROGNOSIS

The treatment of lymphangiomas usually consists of surgical excision, although total removal may not be possible in all cases because of large size or involvement of vital structures. Recurrence is common, especially for cavernous lymphangiomas of the oral cavity, because of their infiltrative nature.

Hemangioma

Definition

The term *hemangioma* was originally used to describe any vascular tumor-like structure, whether it was present at or around birth or appeared later in life

Definition

- Now, these conditions are categorized into two families:

1. a family of self-involuting lesions that eventually disappear.
2. another family of malformations, enlarged or abnormal vessels present at birth and essentially permanent

Classification

- Haemangioma are of three types based on the type of vessel involved. They are:
- Capillary Haemangioma
- Cavernous Heamangioma (also called Venous Haemangioma)
- Plexiform Haemangioma (also called Arterial Haemangioma

Read

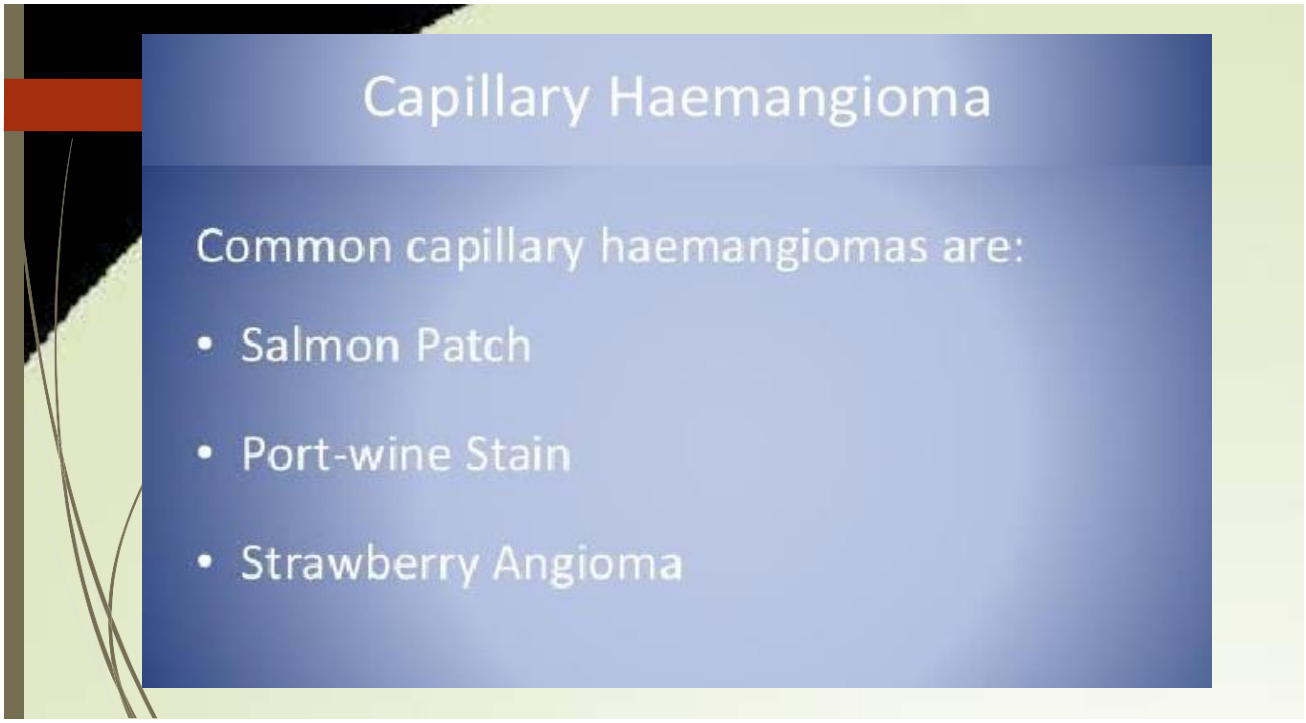
Capillary Haemangioma
Common capillary haemangiomas are:
• Salmon Patch
• Port-wine Stain
• Strawberry Angioma

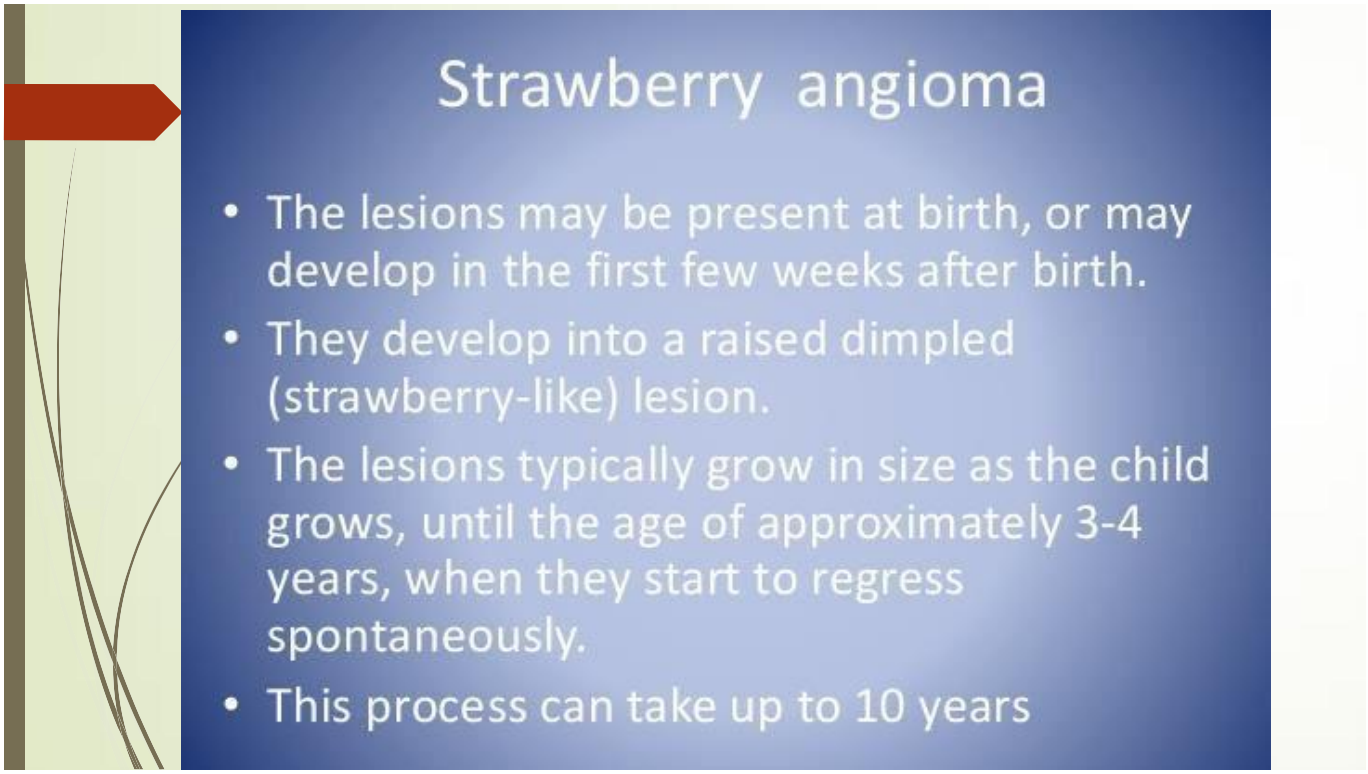
Strawberry angioma
• The lesions may be present at birth, or may develop in the first few weeks after birth.
• They develop into a raised dimpled (strawberry-like) lesion.
• The lesions typically grow in size as the child grows, until the age of approximately 3-4 years, when they start to regress spontaneously.
• This process can take up to 10 years

Strawberry angioma







Read

Salmon patches

- Salmon patches are pink or red, flat, irregularly shaped patches that appear on the baby's face or the back of the neck. On the face, they are commonly found between the eyebrows or on one of the eyelids.
- Salmon patches are never painful or itchy.
- Salmon patches are always present at birth
- salmon patches typically improve on their own.


Salmon patches

Read


Port-wine stain
• port-wine stain or nevus flammeus appears at birth
• port-wine stain ordinarily persist throughout life.The area of skin affected grows in proportion to general growth.
• Port-wine stain occur most often on Face, can appear anywhere on the body, particularly on the neck and upper trunk.
• Early stains are usually flat and pink in appearance. As the child matures, the color may deepen to a dark red or purplish color

Port-wine stain







Cavernous haemangiomas

- Cavernous haemangiomas can arise nearly anywhere in the body
- Cavernous haemangioma is a collection of dilated blood vessels forming a tumor.

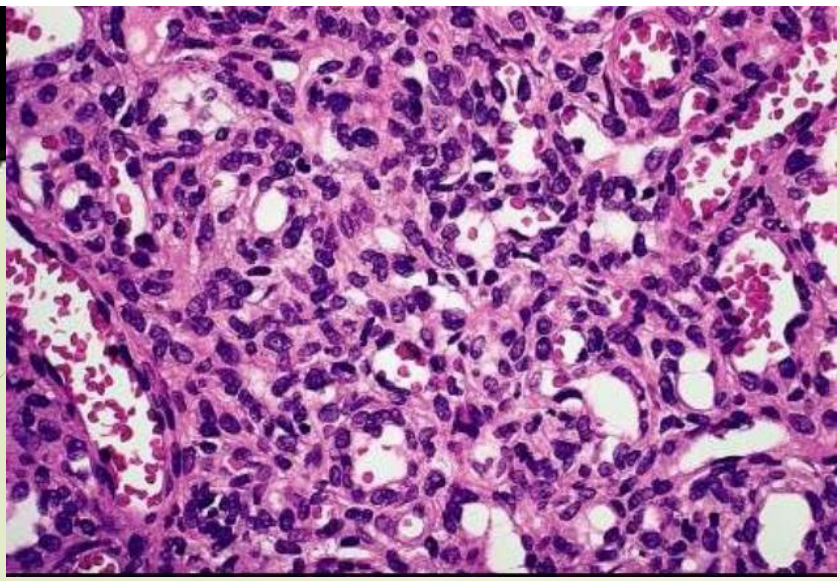

HISTOPATHOLOGIC FEATURES Early hemangiomas of infancy are characterized by numerous plump endothelial cells and often-indistinct vascular lumina, **called juvenile hemangioendothelioma**

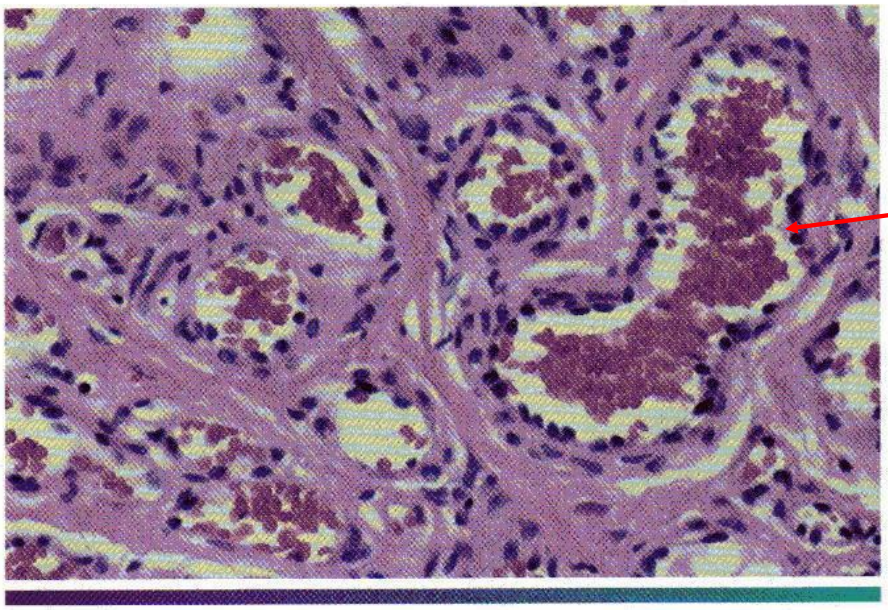

Blood vessel

Figure 12-95 • **Capillary hemangioma.** High-power photomicrograph demonstrating well-formed capillary-sized vessels.

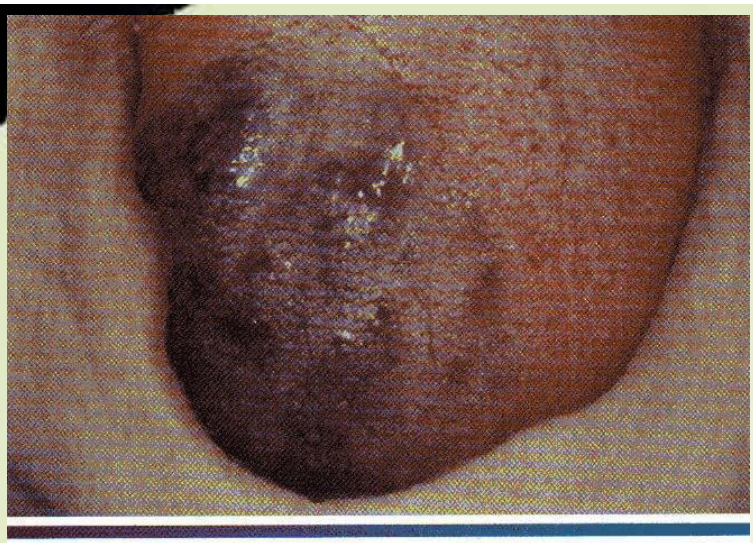

Figure 12-88 • **Venous malformation.** Bluish-purple mass of the anterior tongue.

Vascular malformations do not show active endothelial cell proliferation, and the channels resemble the vessels of origin

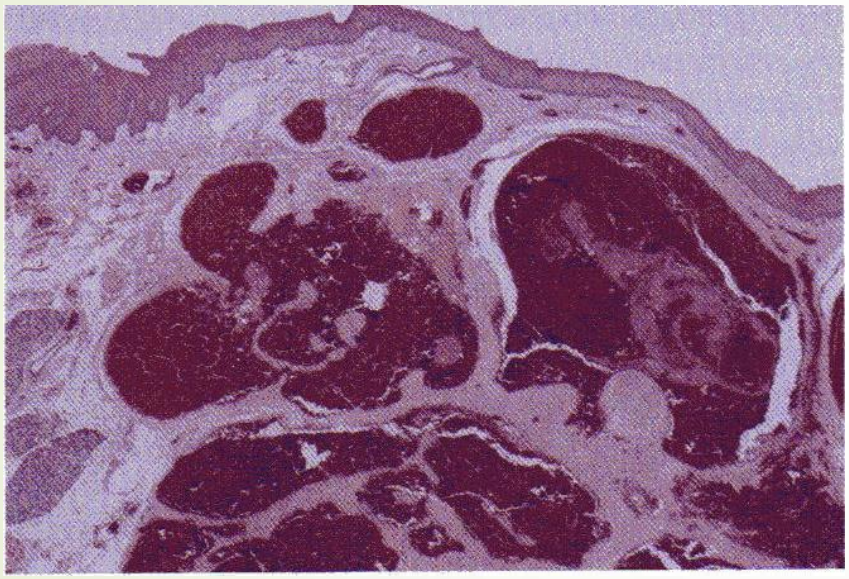

Vascular malformations do not show active endothelial cell proliferation, and the channels resemble the vessels of origin. venous malformations may show more dilated vessels.

Traumatic Neuroma

The traumatic neuroma is not a true neoplasm but a reactive proliferation of neural tissue after transection or other damage of a nerve bundle. After a nerve has been damaged or severed, the proximal portion attempts to regenerate and reestablish innervation of the distal segment by the growth of axons through tubes of proliferating Schwann cells. If these regenerating elements encounter scar tissue or otherwise cannot reestablish innervation, then a tumor-like mass may develop at the site of injury.

Traumatic neuromas of the oral mucosa are typically smooth-surfaced, non-ulcerated painful nodules. They can develop at any location but are most common in the mental foramen area, tongue, and lower lip. some lesions arise subsequent to tooth extraction or other surgical procedures.

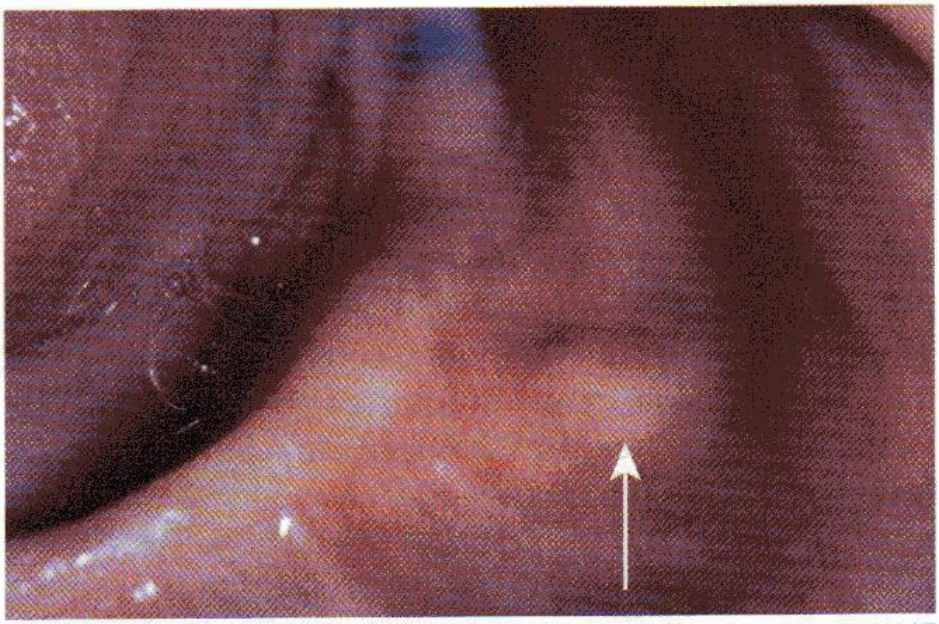

Figure 12-49 • Traumatic neuroma. Painful nodule of the mental nerve as it exits the mental foramen *(arrow)*.

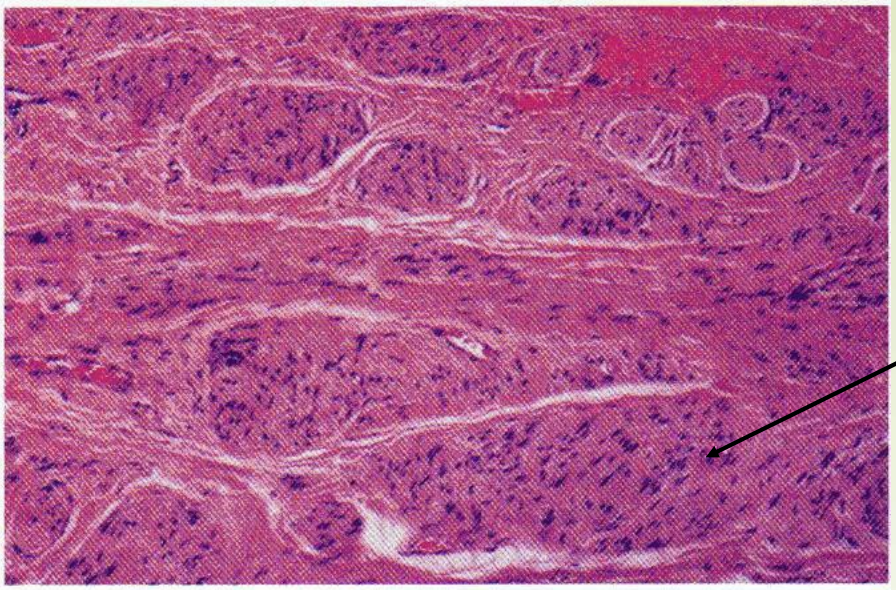

Figure 12-51 • **Traumatic neuroma.** Low-power view showing the haphazard arrangement of nerve bundles within the background fibrous connective tissue.

Read

NEURILEMMOMA

It is a benign neoplasm of schwann cell origin.

Clinical feature:

age:20-30yrs.

site:tongue.

Presentation:

asymptomatic,slow growing,encapsulated.

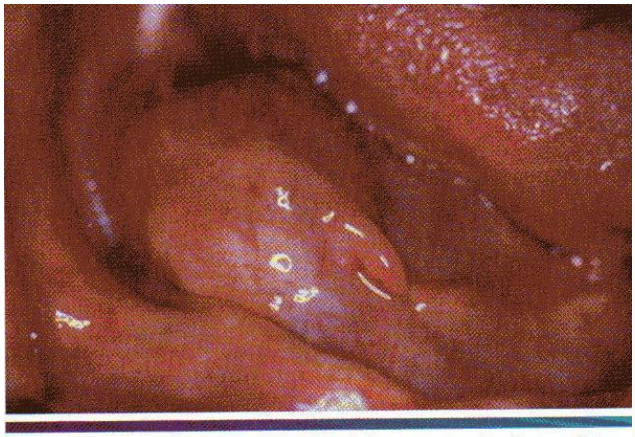

Figure 12-56 • **Neurilemoma.** Nodular mass in the floor of the mouth. (Courtesy of Dr. Art A. Gonty.)

Radiological feature:

unilocular (or) multilocular radiolucency.

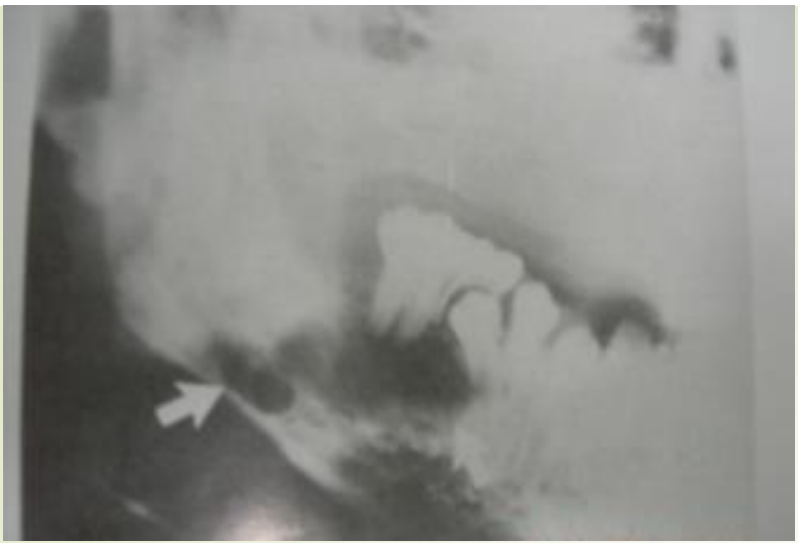

Read

HISTOLOGICAL FEATURE

Two pattern of cells

1.ANTONI TYPE A

2.ANTONI TYPE B

ANTONI TYPE A: streaming fascicles of spindle shaped schwan cells.

These cells surrounds central pale eosinophilic,acellular cells- VEROCAYBODIES

Sharma dental clinic

ANTONI TYPE B:

less cellular less organized.

Antoni A

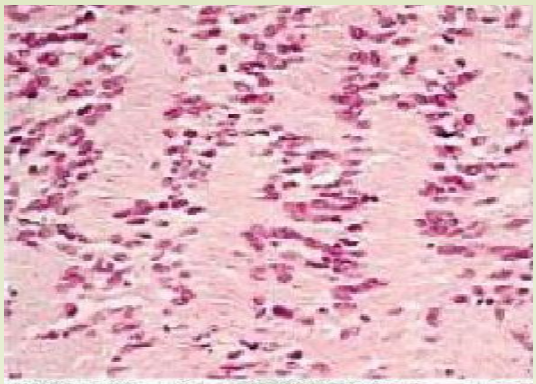

Antoni B

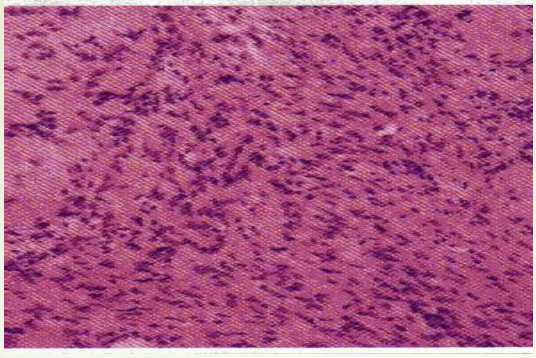

TREATMENT

SURGICAL EXCISION

NEUROFIBROMA

The most common peripheral nerve neoplasm.

Arise from schwan cells and perineural fibroblast.

Clinical features:

age:young adults

site: tongue,buccal mucosa.

Presentation:

painless

slow growing ,soft mass

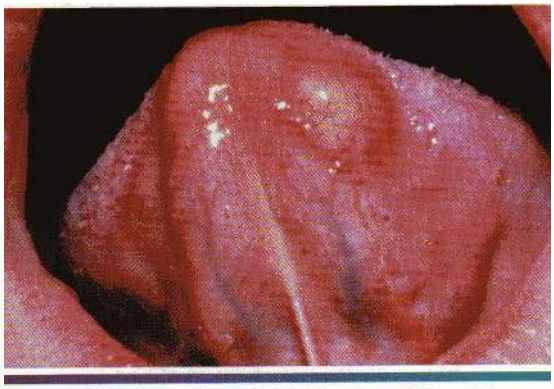

Figure 12-58 • **Neurofibroma.** Nodular mass of the anterior ventral tongue. (Courtesy of Dr. Lindsey Douglas.)

If intra-osseous

Radiological features:

Unilocular (or) multilocular radiolucency.



Figure 12-60 • **Neurofibroma.** Intraosseous tumor filling the right mandibular ramus. (Courtesy of Dr. Paul Allen.)

Read

HISTOLOGICAL FEATURES

SOLITARY NUEROFIBROMA:

Well circumscribed proliferation occur within the perineurium.

Tumor composed of spindle shaped cells with wavy nuclei.

Mast cells are numerous it is a diagnostic feature.

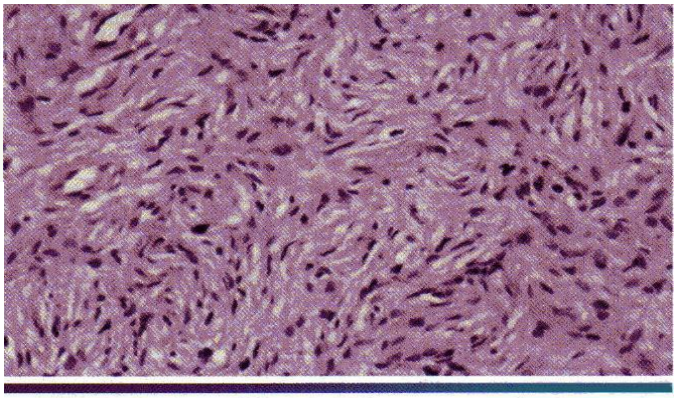

Figure 12-62 • **Neurofibroma.** High-power view showing spindle-shaped cells with wavy nuclei.

TREATMENT

LOCAL SURGICAL EXCISION

Soft Tissue Sarcomas

Definition



- Sarcomas are malignant tumors that arise from skeletal and extra-skeletal connective tissue, mesenchymal cells including:
  - adipose tissue
  - bone
  - cartilage
  - smooth muscle including vascular smooth muscle
  - skeletal muscle

Introduction

- Soft tissue sarcomas are rare and unusual neoplasms
  - about 1% of adult human cancers
  - 15% of pediatric malignancies
- Most commonly occur in the extremities(50%)
- Also common in the abdominal cavity / retro-peritoneum, trunk/thoracic region, and head and neck

Read

Liposarcoma

- It is the most frequent soft tissue sarcoma in adults.
- Liposarcomas are usually large and occur most frequently in the lower extremities (popliteal fossa and medial thigh); retroperitoneal, perirenal, and mesenteric region; and shoulder area.
- Grossly, liposarcomas are well circumscribed but not encapsulated.

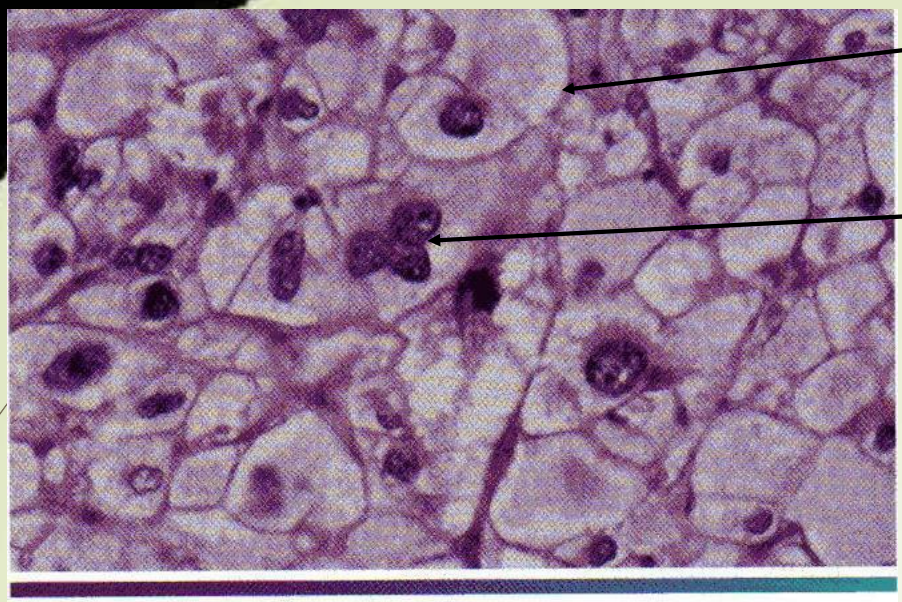

Figure 12-125 • **Liposarcoma.** High-power view showing vacuolated lipoblasts with pleomorphic nuclei.

Fibrosarcomas

Common tumors of adults, although they can occur in any age group and even be present as congenital neoplasms.

Fibrosarcomas can arise from superficial and deep connective tissues such as fascia, tendon, periosteum, and scar; grow slowly or rapidly; and often appear well circumscribed.

They usually are soft and cellular and may contain areas of necrosis and hemorrhage

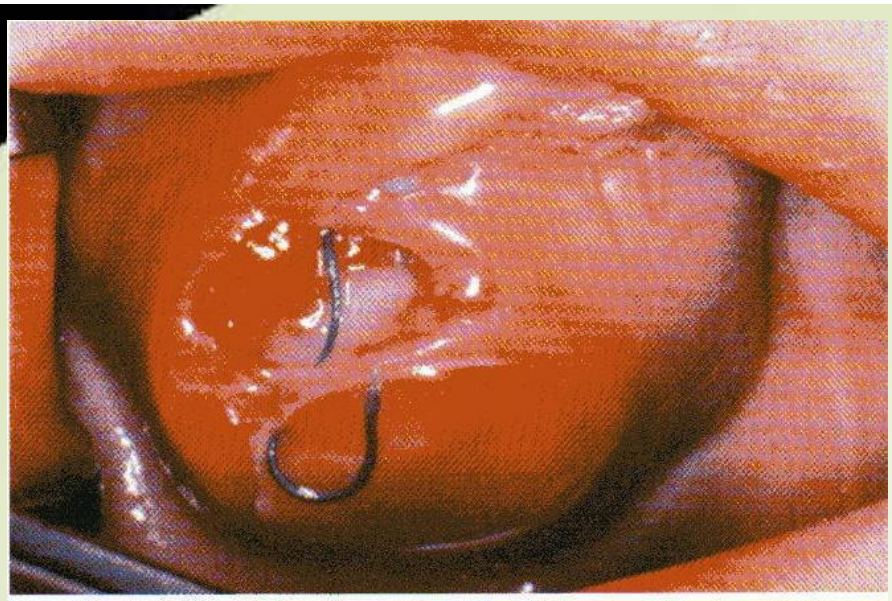

Figure 12-122 ◆ **Fibrosarcoma.** Child with a large mass of the hard palate and maxillary alveolar ridge. (Courtesy of Dr. John McDonald.)

- Microscopic- The cells are arranged in fascicles that intersect each other at acute angles, resulting in a herringbone appearance.
- The individual cells resemble normal fibroblasts, and a reticulin stain demonstrates abundant fibers *wrapped around each cell*.
- It should be differented from monophasic synovial sarcoma, liposarcoma, malignant

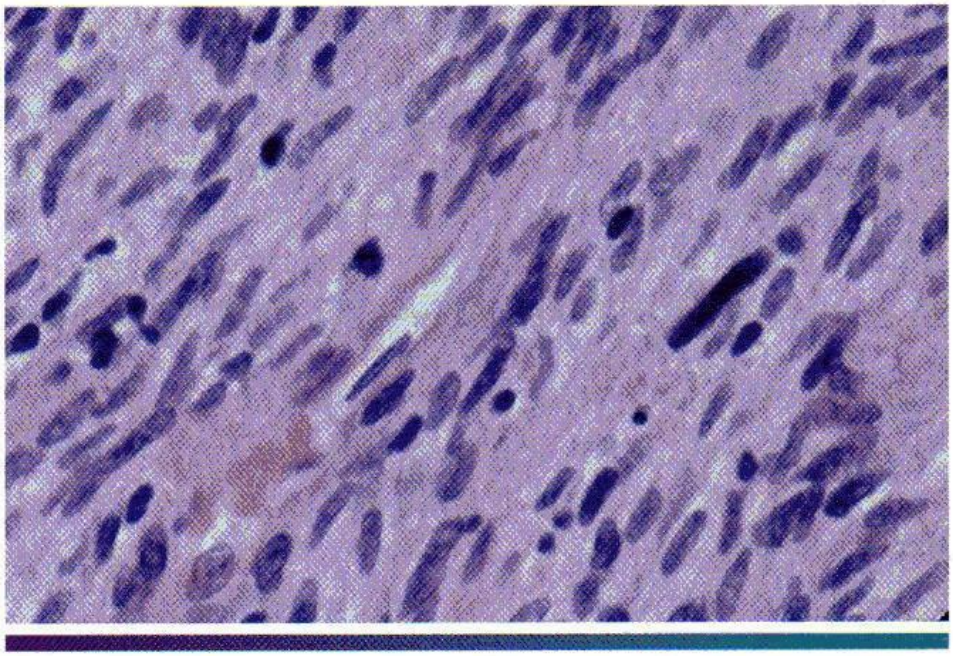

Figure 12-123 ◆ **Fibrosarcoma.** Cellular mass of spindle-shaped cells demonstrating mild pleomorphism.

