Dr.Mustafa Fadhil
PhD. Anatomy & Histology

The Face

Face extends superiorly to the hair line, inferiorly to the chin and base of the mandible, and on each side to the auricle.

Skin of the Face

The skin of the face possesses numerous sweat and sebaceous glands. It is connected to the underlying bones by loose connective tissue, in which are embedded the muscles of facial expression. **No deep fascia is present in the face.**
Wrinkle lines of the face result from the repeated folding of the skin perpendicular to the long axis of the underlying contracting muscles, coupled with the loss of youthful skin elasticity.
Surgical scars of the face are less conspicuous if they follow the wrinkle lines

Muscles of the Face (Muscles of Facial Expression)

The muscles of the face are embedded in the superficial fascia, and most arise from the bones of the skull and are inserted into the skin. The orifices of the face, namely, the orbit, nose, and mouth, are guarded by the eyelids, nostrils, and lips, respectively. It is the function of the facial muscles to serve as sphincters or dilators of these structures. **A secondary function** of the facial muscles is to modify the expression of the face. All the muscles of the face are developed from the second pharyngeal arch and are supplied by the facial nerve.

Muscles of the Eyelids

The sphincter muscle of the eyelids is the orbicularis oculi, and the dilator muscles are the levator palpebrae superioris and the occipitofrontalis.

Muscles of the Nostrils

The sphincter muscle is the compressor naris and the dilator muscle is the dilator naris.

Muscles of the Lips and Cheeks

The sphincter muscle is the orbicularis oris. The dilator muscles consist of a series of small muscles that radiate out from the lips.

Sphincter Muscle of the Lips: Orbicularis Oris

Origin and insertion: The fibers encircle the oral orifice within the substance of the lips. Some of the fibers arise near the midline from the maxilla above and the mandible below. Other fibers arise from the deep surface of the skin and pass obliquely to the mucous membrane lining the inner surface of the lips. Many of the fibers are derived from the buccinators muscle.
Nerve supply: Buccal and mandibular branches of the facial nerve
Action: Compresses the lips together

Dilator Muscles of the Lips

The dilator muscles radiate out from the lips, and their action is to separate the lips; this movement is usually accompanied by separation of the jaws. The muscles arise from the bones and fascia around the oral aperture and converge to be inserted into the substance of the lips.

The muscles are named as follows:

Levator labii superioris alaeque nasi, Levator labii superioris, Zygomaticus minor Zygomaticus major, Levator anguli oris (deep to the zygomatic muscles), Risorius Depressor anguli oris, Depressor labii inferioris, Mentalis

Nerve Supply: Buccal and mandibular branches of the facial nerve.

Muscle of the Cheek

Buccinator

Origin: From the outer surface of the alveolar margins of the maxilla and mandible opposite the molar teeth and from the pterygomandibular ligament.

Insertion: The muscle fibers pass forward, forming the muscle layer of the cheek. The muscle is pierced by the parotid duct. At the angle of the mouth the central fibers decussate, those from below entering the upper lip and those from above entering the lower lip; the highest and lowest fibers continue into the upper and lower lips, respectively, without intersecting. The buccinator muscle thus blends and forms part of the orbicularis oris muscle.

Nerve supply: Buccal branch of the facial nerve

Action: Compresses the cheeks and lips against the teeth

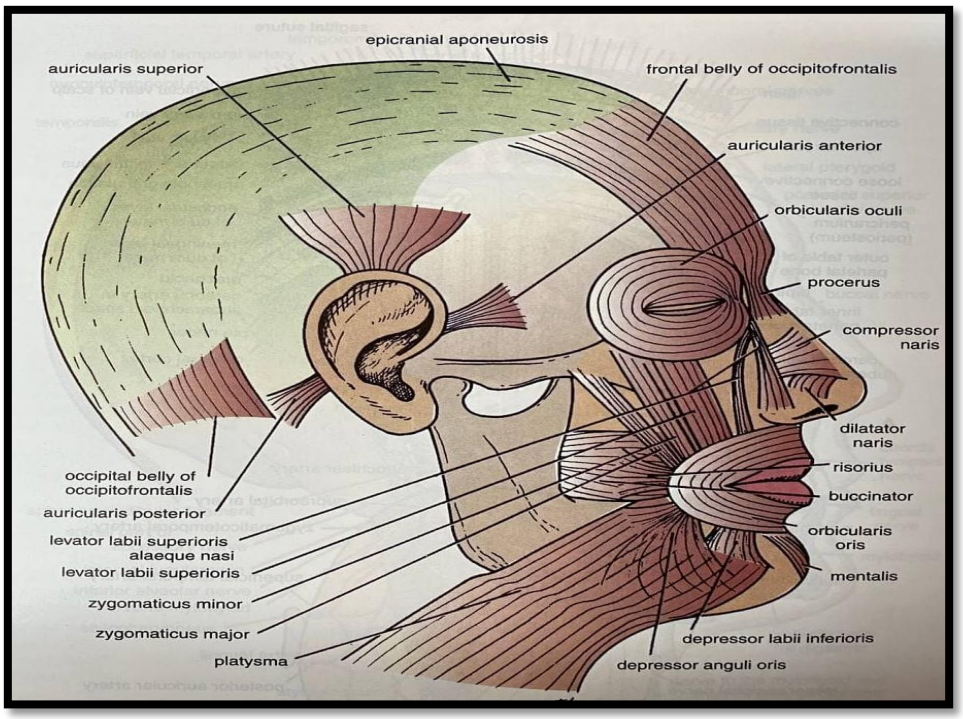

Muscles of Facial Expression

Sensory Nerves of the Face

The skin of the face is supplied by branches of the three divisions of the trigeminal nerve, except for the small area over the angle of the mandible and the parotid gland which is supplied by the great auricular nerve (C2 and 3). These nerves not only supply the skin of the face, but also supply proprioceptive fibers to the underlying muscles of facial expression. They are, in addition, the sensory nerve supply to the mouth, teeth, nasal cavities, and paranasal air sinuses.

1. Ophthalmic Nerve

The ophthalmic nerve supplies the skin of the forehead, the upper eyelid, the conjunctiva, and the side of the nose down to and including the tip. **Five branches of the nerve pass to the skin.**

1. The **lacrimal nerve** supplies the skin and conjunctiva of the lateral part of the upper eyelid.
2. The **supraorbital nerve** winds around the upper margin of the orbit at the supraorbital notch. It divides into branches that supply the skin and conjunctiva on the central part of the upper eyelid; it also supplies the skin of the forehead.
3. The **supratrochlear nerve** winds around the upper margin of the orbit medial to the supraorbital nerve. It divides into branches that supply the skin and conjunctiva on the medial part of the upper eyelid and the skin over the lower part of the forehead, close to the median plane.
4. The **infratrochlear nerve** leaves the orbit below the pulley of the superior oblique muscle. It supplies the skin and conjunctiva on the medial part of the upper eyelid and the adjoining part of the side of the nose.
5. The **external nasal nerve** leaves the nose by emerging between the nasal bone and the upper nasal cartilage. It supplies the skin on the side of the nose down as far as the tip.

2. Maxillary Nerve

The maxillary nerve supplies the skin on the posterior part of the side of the nose, the lower eyelid, the cheek, the upper lip, and the lateral side of the orbital opening. Three branches of the nerve pass to the skin.

1. The **infraorbital nerve** is a direct continuation of the maxillary nerve. It enters the orbit and appears on the face through the infraorbital foramen. It immediately divides into numerous small branches, which radiate out from the foramen and supply the skin of the lower eyelid and cheek, the side of the nose, and the upper lip
2. The **zygomaticofacial nerve** passes onto the face through a small foramen on the lateral side of the Zygomatic bone. It supplies the skin over the prominence of the cheek.
3. The **zygomaticotemporal nerve** emerges in the temporal fossa through a small foramen on the posterior surface of the zygomatic bone. It supplies the skin over the temple.

3. Mandibular Nerve

The mandibular nerve supplies the skin of the lower lip, the lower part of the face, the temporal region, and part of the auricle. It then passes upward to the side of the scalp. Three branches of the nerve pass to the skin.

1. The **mental nerve** emerges from the mental foramen of the mandible and supplies the skin of the lower lip and Chin.
2. The **buccal nerve** emerges from beneath the anterior border of the masseter muscle and supplies the skin over a small area of the cheek.
3. The **auriculotemporal nerve** ascends from the upper border of the parotid gland between the superficial temporal vessels and the auricle. It supplies the skin of the auricle, the external auditory meatus, the outer surface of the tympanic membrane, and the skin of the scalp above the auricle.

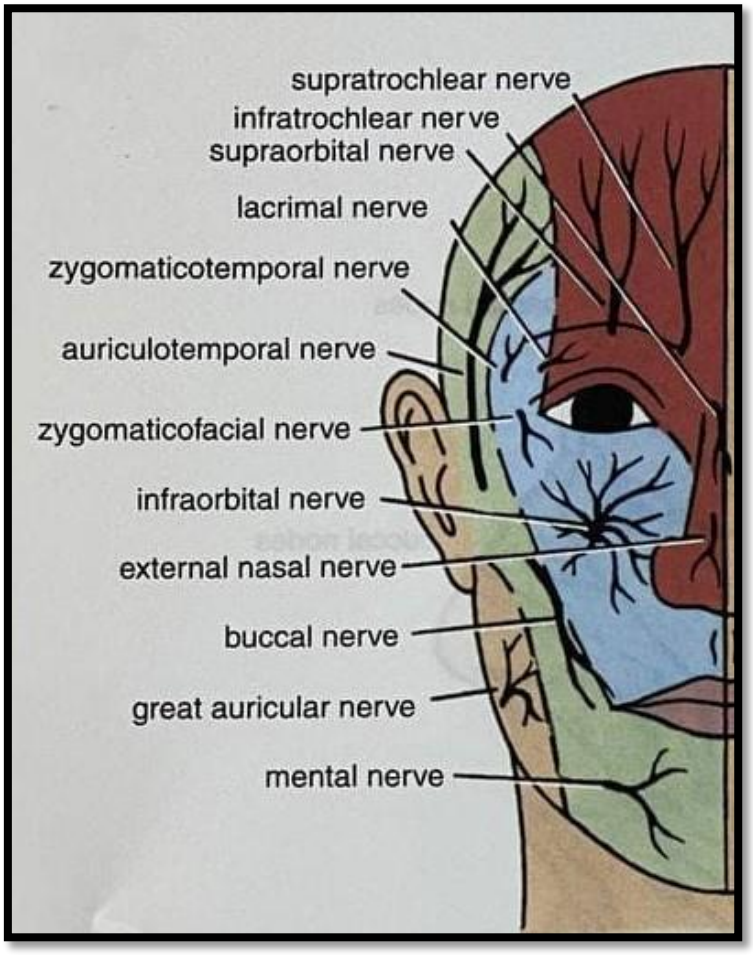

Sensory Nerve Supply of the Skin of the Face

Arterial Supply of the Face

The face receives a rich blood supply from two main vessels: **the facial** and **superficial temporal arteries**, which are supplemented by several small arteries that accompany the sensory nerves of the face.

- The **facial artery** arises from the external carotid artery. Having arched upward and over the submandibular salivary gland, it curves around the inferior margin of the body of the mandible at the anterior border of the masseter muscle. **It is here that the pulse can be easily felt**. It runs upward in a tortuous course toward the angle of the mouth and is covered by the platysma and the risorius muscles. It then ascends deep to the zygomaticus muscles and the levator labii superioris muscle and runs along the side of the nose to the medial angle of the eye, where it anastomoses with the terminal branches of the ophthalmic artery.

Branches of the facial artery

1. The **submental artery** arises from the facial artery at the lower border of the body of the mandible. It supplies the skin of the chin and lower lip.
2. The **inferior labial artery** arises near the angle of the mouth. It runs medially in the lower lip and anastomoses with its fellow of the opposite side.
3. The **superior labial artery** arises near the angle of the mouth. It runs medially in the upper lip and gives branches to the septum and ala of the nose.
4. The **lateral nasal artery** arises from the facial artery alongside the nose. It supplies the skin on the side and dorsum of the nose.

- The **superficial temporal artery**, the smaller terminal branch of the external carotid artery, commences in the parotid gland. It ascends in front of the auricle to supply the scalp. The **transverse facial artery,** a branch of the superficial temporal artery, arises within the parotid gland. It runs forward across the cheek just above the parotid duct.

- The **supraorbital** and **supratrochlear arteries,** branches of the ophthalmic artery, supply the skin of the forehead.

Venous Drainage of the Face

The **facial vein** is formed at the medial angle of the eye by the union of the supraorbital and supratrochlear veins. It is connected to the superior ophthalmic vein directly through the supraorbital vein. By means of the superior ophthalmic vein, the facial vein is connected to the cavernous sinus; this connection is of great clinical importance because it provides a pathway for the spread of infection from the face to the cavernous sinus. The facial vein descends behind the facial artery to the lower margin of the body of the mandible. It crosses superficial to the submandibular gland

and is joined by the anterior division of the retromandibular vein. The facial vein ends by draining into the internal jugular vein.

Tributaries

The facial vein receives tributaries that correspond to the branches of the facial artery. It is joined to the pterygoid venous plexus by the **deep facial vein** and to the cavernous sinus by the superior ophthalmic vein.

The **transverse facial vein** joins the superficial temporal vein within the parotid gland.

Lymph Drainage of the Face

Lymph from the forehead and the anterior part of the face drains into the submandibular lymph nodes. A few buccal lymph nodes may be present along the course of these lymph vessels. The lateral part of the face, including the lateral parts of the eyelids, is drained by lymph vessels that end in the parotid lymph nodes. The central part of the lower lip and the skin of the chin are drained into the submental lymph nodes.

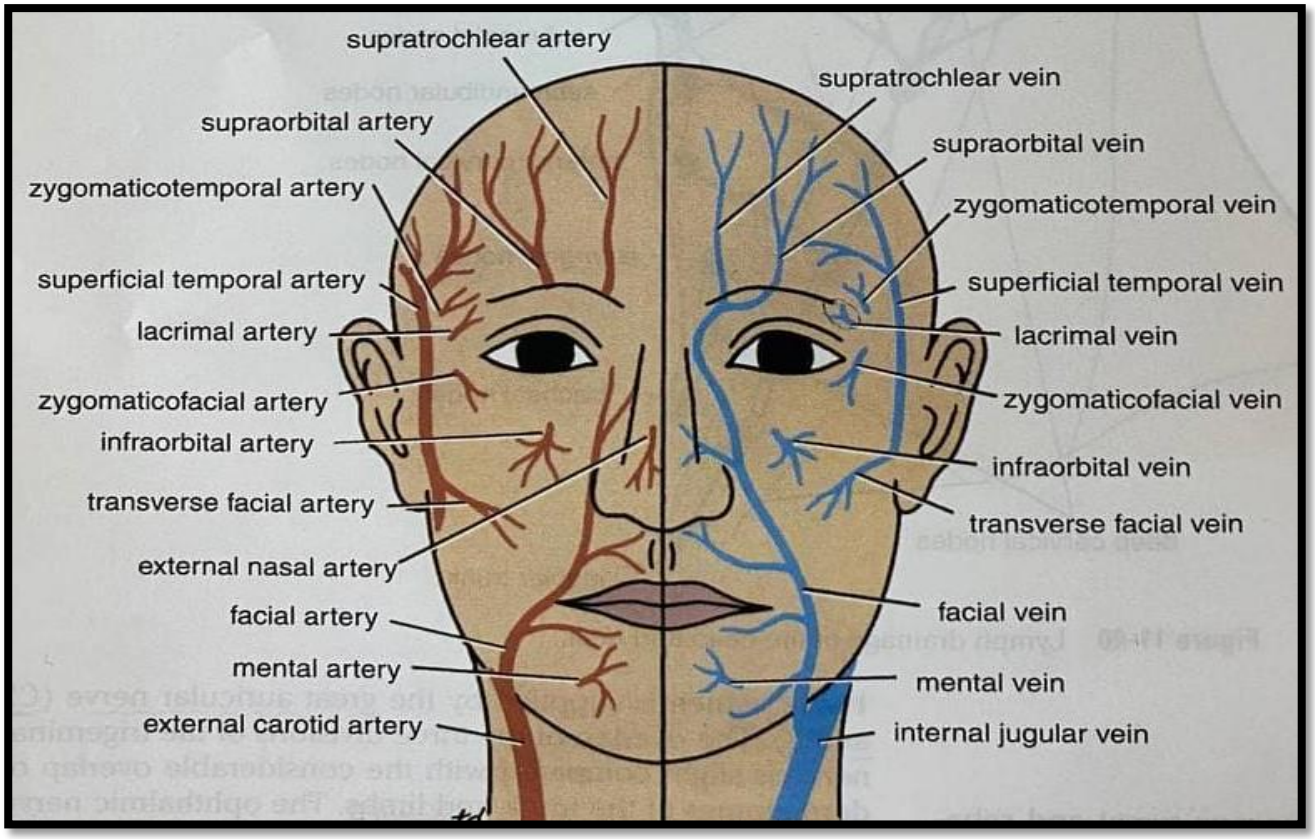

Arterial supply and venous drainage of the face.

Muscles of Facial Expression

Orbicularis oculi				
Palpebral part	Medial palpebral ligament	Lateral palpebral raphe	Facial nerve	Closes eyelids and dilates lacrimal sac
Orbital part	Medial palpebral ligament and adjoining bone	Loops return to origin	Facial nerve	Throws skin around orbit into folds to protect eyeball
Corrugator supercilii	Superciliary arch	Skin of eyebrow	Facial nerve	Vertical wrinkles of forehead, as in frowning
Compressor nasi	Frontal process of maxilla	Aponeurosis of bridge of nose	Facial nerve	Compresses mobile nasal cartilages
Dilator naris	Maxilla	Ala of nose	Facial nerve	Widens nasal aperture
Procerus	Nasal bone	Skin between eyebrows	Facial nerve	Wrinkles skin of nose
Orbicularis oris	Maxilla, mandible, and skin	Encircles oral orifice	Facial nerve	Compresses lips together
Dilator Muscles of Lips				
Levator labii superioris alaeque nasi Levator labii superioris Zygomaticus minor Zygomaticus major Levator anguli oris Risorius Depressor anguli oris Depressor labii inferioris Mentalis	Arise from bones and fascia around oral aperture and insert into substance of lips		Facial nerve	Separate lips
Buccinator	Outer surface of alveolar margins of maxilla and mandible and pterygomandibular ligament		Facial nerve	Compresses cheeks and lips against teeth

▪ Facial Nerve (the 7th cranial nerve)

As the facial nerve runs forward within the substance of the parotid salivary gland, it divides into its five terminal branches.

The motor fibers of the facial nerve provide innervation to the muscles of facial expression, occipital and auricular muscles, platysma muscle, posterior belly of the digastric muscle, and stylohyoid muscle. In addition, it supplies fibers for deep sensitivity of the face and for taste to the anterior two thirds of the tongue and palate. The facial nerve also transmits preganglionic visceral efferent fibers to the lacrimal gland, sublingual and submandibular glands, and other minor glands.

The facial nerve after exiting the stylomastoid foramen, which is situated posterolaterally to the styloid process, the nerve enters the substance of the parotid gland, where it divides into its upper and lower divisions just posterior to the mandible. The approximate distance from the lowest point of the external bony auditory meatus to the bifurcation of the facial nerve is 2.3 cm. Posterior to the parotid gland, the nerve is at least 2 cm deep into the skin surface. From this point, the two branches curve around the posterior mandible, where they form a plexus

between the parotid gland and masseter muscle. The terminal branches of the facial nerve then spread in a fanlike fashion as five separate nerves.

- The **temporal branch** emerges from the upper border of the gland and supplies the anterior and superior auricular muscles, the frontal belly of the occipitofrontalis, the orbicularis oculi, and the corrugators supercilii.
- The **zygomatic branch** emerges from the anterior border of the gland and supplies the orbicularis oculi.
- The **buccal branch** emerges from the anterior border of the gland below the parotid duct and supplies the buccinator muscle and the muscles of the upper lip and nostril.
- The **mandibular branch** emerges from the anterior border of the gland and supplies the muscles of the lower lip.
- The **cervical branch** emerges from the lower border of the gland and passes forward in the neck below the mandible to supply the platysma muscle; it may cross the lower margin of the body of the mandible to supply the depressor anguli oris muscle.

The facial nerve is the nerve of the second pharyngeal arch and supplies all the muscles of facial expression. **It does not supply the skin,** but its branches communicate with branches of the trigeminal nerve.

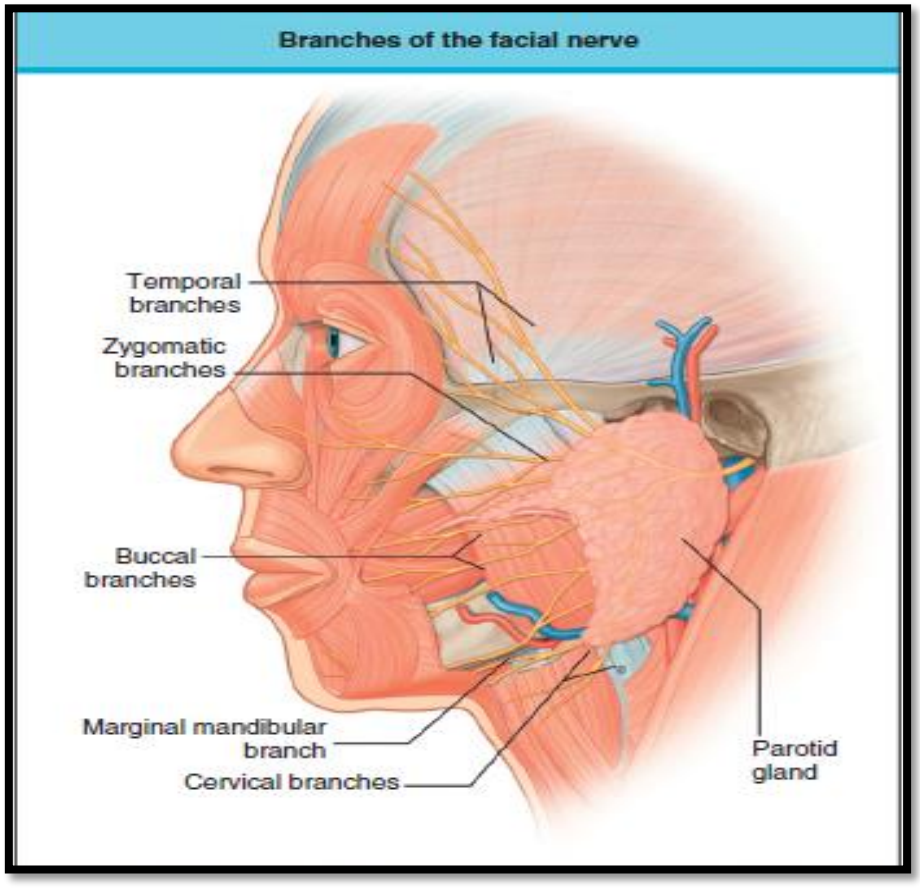

Expression	*Changes in skin of face*	*Muscle involved*
Surprise	• Transverse wrinkles of forehead. • Transverse wrinkles at bridge of nose.	• Frontalis • Procerus
Frowning	Vertical wrinkles of forehead	Corrugator supercilli
Anger	• Dilatation of anterior nasal aperture • Depression of lower part of nasal septum (columella)	• Dilator naris • Depressor septi
Laughing, Smiling	Angle of mouth is drawn upwards and laterally	Zygomaticus major
Sadness	Angle of mouth drawn downwards and laterally	Depressor anguli oris
Sorrow and grief	Accentuation of nasolabial furrow with elevation and eversion of upper lip	• Levator labii superioris • Levator anguli oris • Zygomaticus minor
Grinning	Retraction of angle of mouth	Risorius
Disdain/Doubt	Puckering of skin over chin with protrusion of lower lip	Mentalis
Whistling	Pressing the cheek against gum with pursing of mouth with small opening	Buccinator